

## CYST OF THE ROUND LIGAMENT OF THE LIVER.

BY M. S. HENDERSON, M.B.,

OF ROCHESTER, MINNESOTA,

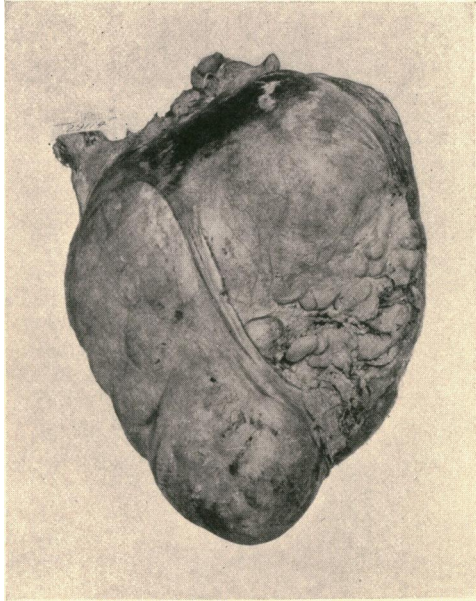
Surgical Assistant at St. Mary's Hospital.

AFTER a somewhat superficial search through the literature for data on the subject, the following report of a case is thought worthy of recording on account of its apparent rarity. Comparatively speaking, numerous references have been found of cysts of the round ligaments of the uterus but none of cysts of the round ligaments of the liver. This case is the only one of the kind that has been met with in the Mayo Clinic at St. Mary's Hospital.

E. A. M., male, aged 41, presented himself for examination January 13, 1909. His complaint was the presence of an abdominal tumor. The following history was given.

One morning, about eight years before, on attempting to straighten up after stooping to lace his shoes, he was seized with a violent cramp in the region of the umbilicus. He was unable to stand erect on account of the excruciating pain, and had considerable difficulty in getting to his bed. The pain gradually lessened, and after a good bowel movement, the result of an enema, he was free from discomfort. There was no nausea and no vomiting during the attack. This attack was the only one of the kind that he had; but his business affairs were exacting and his general health began to fail. Symptoms at this time were indefinite; he was treated for neurasthenia, and soon after, while being examined by his physician, an abdominal tumor about the size of a lemon was discovered, the exact nature of which was doubtful. Laparotomy was advised, but deferred. Under treatment for his nervous condition he improved, was able to resume his business, and as the tumor gave him no discomfort the operation was put off from year to year. The tumor gradually increased in size, however, until at the time of our examination it was about the size of a head.

FIG. 1.



Cyst of the round ligament of the liver.

Physical examination showed a rather thin, dark complexioned man. Heart and lungs negative, as were also the blood and urinary findings. On palpation of the abdomen a freely movable fluctuating tumor was to be felt. When left to assume the natural position, it was seen to be just to the right of the umbilicus and a little below it. It was not tender, there was no tympany over it, and it did not move with respiration. The movement downward was more limited than the upward and lateral movements, as it could be easily placed in either flank or be pushed up beneath the liver. A positive diagnosis could not be made, but an exploration was advised and accepted.

*Operation*, February 12, 1909, by Dr. W. J. Mayo: A median incision below the umbilicus was made, and upon opening the peritoneal cavity a straw-colored thin-walled cystic tumor about the size of a child's head presented immediately beneath the abdominal wall. The tumor was anterior to the omentum which was found tucked up behind it. Putting in the hand to explore for the site of the attachment, it was found to be intimately associated with the abdominal wall, just above the umbilicus. The incision was accordingly elongated to two inches above the latter, by which means the cyst could be partially delivered outside the abdomen. Gauze dissection was used in freeing it from its pedicle, causing very little hemorrhage, as there were no vessels of any size running to it. It was then seen that the cyst had its origin in the lower two inches of the round ligament of the liver, where the latter is closely attached to the abdominal wall. The cyst was removed without rupture. A photograph was taken which is shown herewith (Fig. 1).

The patient's recovery was uneventful. He left the hospital on the twelfth day, and for his home in three weeks from the time of operation.