

# Studies on the Immune Response and Pathogenesis of Sendai Virus Infection of Mice

## I. THE FATE OF VIRAL ANTIGENS

G. BLANDFORD\* AND R. B. HEATH†

\* *Department of Experimental Pathology, The University of Birmingham and*

† *Department of Virology, St. Bartholomew's Hospital, London*

(Received 3rd September 1971)

**Summary.** The distribution of viral antigens was determined in lungs, spleen and bronchial lymph nodes of a non-lethal primary Sendai virus infection of mice. Immunofluorescent staining showed that virus was initially confined to the bronchial mucosal columnar cells. Most antigen was present in this location between the 3rd and 5th days a finding which correlated well with infectivity assays. From the 3rd day desquamated mucosal cells in the bronchial lumen showed relatively weak staining for viral antigens. Alveolar macrophages were shown to contain viral antigens only after mucosal shedding had occurred. Viral antigens were found in bronchial lymph nodes between the 3rd to 9th days, and in the spleen from the 3rd day to 49th day after infection. Virus could not be grown from the spleen at any time.

It was shown that the intraluminal cellular debris which appeared to contain little virus was coated with immunoglobulin. More viral antigen could be detected in this location after acid and alkali elution and after prolonged incubation with a potent heterologous anti-viral antiserum. It was concluded that early mouse antibody was fixed to viral antigens in the lung 3 days after infection and 5 days before it could be detected in serum or bronchial secretions.

The significance of these findings was discussed.

## INTRODUCTION

It has previously been shown that a primary non-fatal infection of mice with Sendai virus could be usefully employed for the study of several aspects of the pathogenesis of respiratory viral infection (Robinson, Cureton and Heath, 1968) including the immune response (Blandford, Cureton and Heath, 1971).

Using an immunofluorescent technique, we have examined various tissues at intervals after infection for the distribution and fate of viral antigens. It was hoped that this study would help to indicate the site of priming of the lymphoid system which ultimately leads to the appearance of local antibody in respiratory mucus. Our findings, reported here, have shown that viral antigens were confined to the respiratory mucosa until infected cells

Correspondence: Dr G. Blandford, Rheumatism Research Wing, Department of Experimental Pathology, University of Birmingham, Birmingham, 15.

were shed into the bronchial lumen. This occurred first at the 3rd day, and simultaneously viral antigens were found in bronchial lymph nodes and spleen.

A consistent finding was that these desquamated cells fluoresced much less brightly for viral antigens than infected mucosal cells, *in situ*, on the bronchial basement membrane. Hers, Mülder, Masurel, Kuip and Tyrrell (1962), reported similar results in studies on influenza virus infection in mice. No satisfactory explanation for this was offered. We have previously shown (Blandford *et al.*, 1971) that increased numbers of immunoglobulin secreting cells have already appeared in the bronchial submucosa by the 2nd day of the infection. It therefore seemed possible that these cells could be making local antibody in the micro-environment of the infected cells and that mouse antibody could possibly be blocking our antiviral antiserum, resulting in less fluorescence. To test this hypothesis we used various techniques to remove or specifically displace antibody from the tissue sections before staining for viral antigens. In every case we showed that more viral antigen was revealed. We conclude that specific antibody to viral antigens had been produced and was fixed in the tissues as early as the 3rd day after infection.

The possible significance and source of this early specific antibody in the pathogenesis of respiratory virus infection is discussed.

## MATERIALS AND METHODS

### *Infection of mice*

Groups of specific pathogen free, Swiss Albino mice, 20–25 g, were infected by intranasal inoculation of approximately  $10^5$  EID<sub>50</sub> of Sendai virus under ether anaesthesia. Animals were killed before and at intervals after infection up to 50 days. Details of the techniques used for obtaining and testing specimens from these animals and conventional histological techniques have been described in previous reports (Robinson *et al.*, 1968, Blandford, *et al.*, 1971), which describe the titration of virus in monkey kidney tissue culture, and its detection there by the haemadsorption technique.

### *Antisera*

Antisera to human IgG (SAHG) and rabbit IgG (SARG) were prepared in sheep using purified IgG, and absorbed out with insolubilized reagents and were kindly provided by Dr D. Catty. These antisera were conjugated with fluorescein isothiocyanate according to the method of Nairn (1969). They were subsequently absorbed with Sendai virus to remove unwanted naturally acquired antibody, and with fresh liver homogenate to remove non-specific staining of tissue and were diluted prior to use. Antisera to Sendai virus (RAS) and Kunz virus (RAK) were raised in rabbits after repeated intraperitoneal inoculation with live virus. A normal human serum which had a haemagglutination-inhibition titre to Sendai virus of 1:512 after natural infection was also used (HAS). In some experiments a rabbit antiserum to mouse immunoglobulins previously defined (Blandford *et al.*, 1971) was used. An indirect staining technique was used throughout, and controls for the fluorescent staining are described below.

### *Immunofluorescent staining*

Initial attempts at tissue studies with cryostat lung sections gave unsatisfactory histology and tissues were therefore fixed in cold alcohol and embedded in paraffin wax (Sainte-Marie, 1962). Pairs of parallel sections of lungs and the spleen from each of three mice

on each day were mounted on single 3" × 1½" microscope slides together with pairs of sections of lung and spleen from an uninfected animal. A double longitudinal scratch was made along each slide between section pairs and lined by wax pencil. This method of slide preparation allowed staining of parallel sections with different reagents and enabled specific tests and controls to be accurately and rapidly compared.

The tissues were dewaxed in xylol and taken through alcohol to phosphate buffered saline, pH 7.4. Antisera and tissues were incubated for 30 minutes and then washed in two changes of buffer for 20 minutes each and mounted in buffered glycerol. Sections from infected and non-infected animals were stained with RAS and SARG. The specificity of the reaction was checked by staining other sections with the following combinations of reagents, (1) HAS and SAHG, (2) RAK and SARG, (3) HAS, then RAS and SARG, and (4) RAS, then HAS and SAHG. The procedure was considered specific if (1) was positive and the remainder were negative.

Slides were examined by UV dark ground fluorescence with a Reichert Fluorpan microscope (HBO 50 W mercury vapour lamp) with UG1 pass filter and combined GG13 and Wratten foil 2A absorption filter. Photographs were taken on Kodak High Speed Ektachrome (Daylight Type) film at uniform 3 minute exposures. The colour transparencies were transposed to black and white prints for publication.

#### *Dissociation of viral antibody complexes in tissues*

Preliminary experiments showed that complexes of Sendai virus and its specific antibody could be easily dissociated by acid buffer (0.05 M glycine-HCl, pH2) and by alkali buffer (0.05 M glycine-NaOH, pH12). A similar procedure was carried out on slides mounted with serial parallel sections. One half of each slide was immersed in either acid or alkali buffer for one hour and then washed. Both sides of the slide were then stained for viral antigens as described above.

#### *Displacement of mouse antibodies*

Displacement of a labelled antiserum by an unlabelled antiserum has been successfully used to check antibody specificity (McCormick, Page Faulk, Fox and Fudenberg, 1971). It was decided to use this approach in an effort to remove any possible specific mouse antibody in infected mouse lung sections with specific human or rabbit anti-viral antibody.

Parallel sections on one half of a microscope slide were covered with HAS or RAS for 24 hours. Sections on the control half of the slide were treated for 24 hours with human or rabbit serum from which all anti-Sendai antibody had been removed by adsorption. The whole slide was washed with buffer, covered with HAS for 30 minutes and then stained with SAHG or SARG as appropriate.

## RESULTS

Preliminary experiments employing viral infectivity techniques, indicated that virus titres in the lung were highest on the 4th day of the infection and then declined so that no virus was detected after the 8th day. Antibodies were detected by the haemagglutination-inhibition test in serum and in lung suspensions and secretions from the 8th day onwards. These findings were in accord with those previously obtained with this model (Robinson *et al.*, 1968).

Attempts were then made to detect viral antigens in tissues by immunofluorescent staining. Sections of lungs, bronchial lymph nodes and spleen were examined by this procedure.

*Distribution of viral antigens in the lung*

On the 1st day viral antigens were only detected on the luminal surface of bronchial-mucosal cells. By the 2nd day cytoplasmic staining was present in some of these cells, and this type of staining increased in intensity and affected more cells with the passage of time. It was apparent that virus tended to spread around and down continuous sheets of cells (Fig. 1). In this site most viral antigen was found between the 3rd to 6th days and none was detectable after the 9th day.

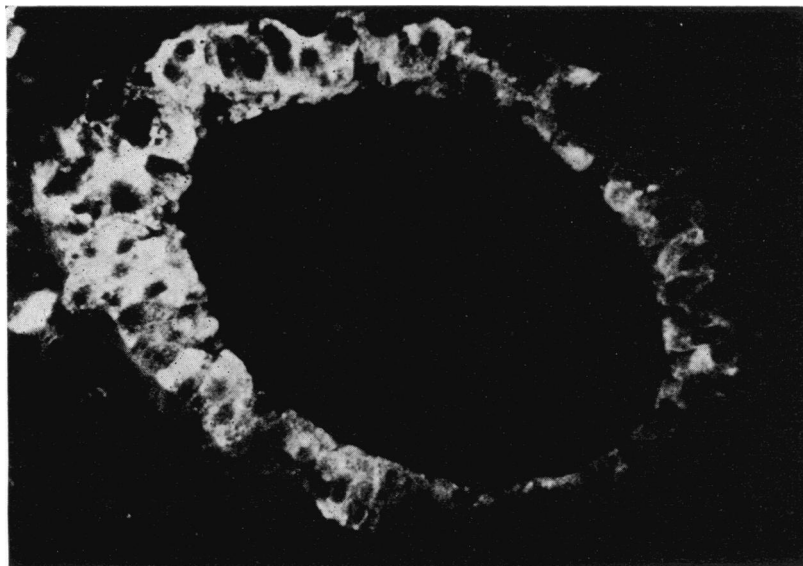


FIG. 1. Cross section of bronchus stained for virus, Day 3. Bright specks to left of bronchus are due to autofluorescence. Cytoplasmic fluorescence only is seen. Intense staining at upper left suggests infection has spread from this initial focus of infection with minimal surface staining of mucosa at lower right. ( $\times 750$ .)

From the 3rd day shedding of damaged cells into the bronchial lumen was noted and these cells appeared to contain less virus than intact cells on the basement membrane. This was evidenced by less bright fluorescence (Fig. 2). Increasing amounts of this cellular debris were found in the bronchial lumen until the 7th–8th day when very little virus was apparent. Further studies on tissues showing reduced fluorescence are described below.

We consistently failed to demonstrate viral antigens deep to the basement membrane of the bronchi and none was found in lung parenchyma until desquamation had occurred. At this time alveolar macrophages were found to contain virus although other alveolar cells in general were not infected (Fig. 3).

The infection in all lungs examined was invariably patchy (Fig. 4). The heaviest infection occurred in the trachea and main bronchi. Smaller bronchi often escaped infection completely. We did not examine the nasal passages and sinuses.

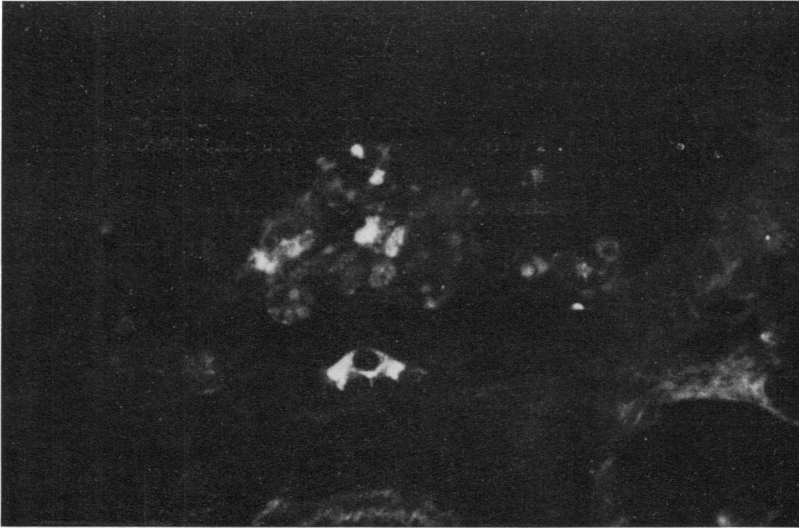


FIG. 2. Cross section of bronchus stained for virus, Day 3. Intact infected mucosal cell fluoresces brightly. Intraluminal cellular debris shows surprisingly little fluorescence. Regenerating uninfected cuboidal cells can be seen where original mucosa has been shed. ( $\times 750$ .)

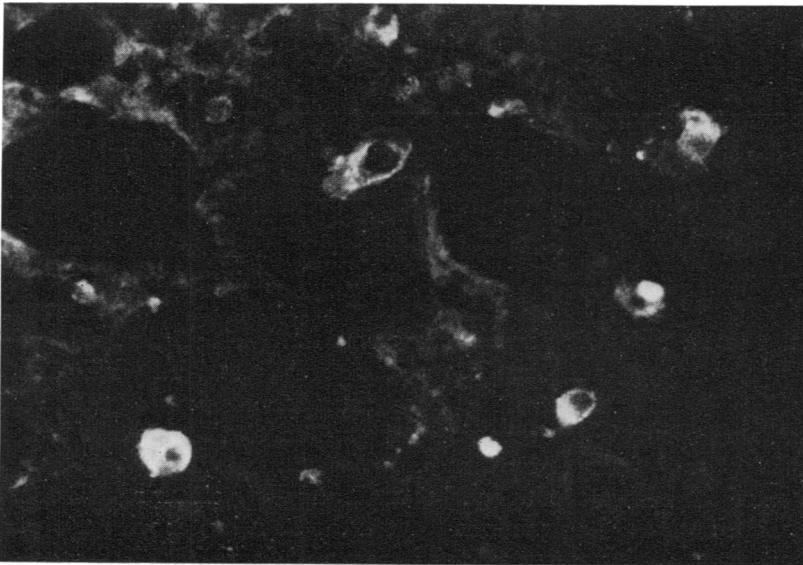


FIG. 3. Section through lung parenchyma stained for virus, Day 4. Alveolar macrophages contain viral antigens. Alveolar lining cells do not appear to be infected. ( $\times 750$ .)

*Staining of desquamated bronchial mucosa*

It was thought that the diminished fluorescence of shed mucosa might be due to the masking of viral antigens by early specific mouse antibody. Accordingly, parallel sections were treated either with the antiviral serum (RAS) or with an anti-mouse immunoglobulin antiserum and stained with SARG conjugate.

Desquamated cells apparently containing little viral antigen (Fig. 5a) were covered with immunoglobulin (Fig. 5b). Furthermore, when sections were stained in this way it was also apparent that cells containing immunoglobulin were present in the inflammatory oedema fluid adjacent to the basement membrane of the infected mucosal cells. (Fig. 6a, b). It thus seemed possible that either serum antibody in an inflammatory exudate or

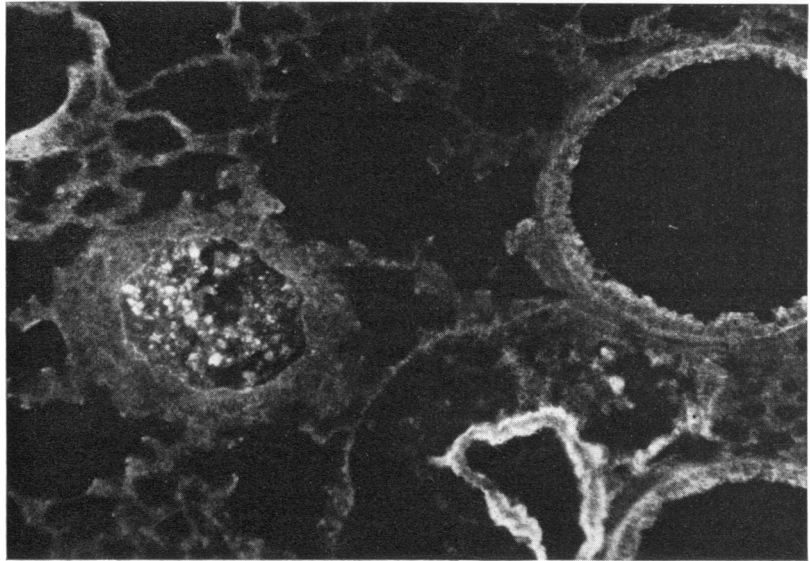


FIG. 4. Section of lung stained for virus, Day 4. Bronchus upper right and lower right are minimally infected. Bronchus, centre left, shows complete desquamation with a few bright specks of viral antigens. The blood vessel at bottom right has autofluorescent wall and perivascular oedema is clearly present. ( $\times 400$ .)

antibody produced locally by cells in the bronchial submucosa could be responsible for masking of viral antigens. Two approaches were used to investigate this possibility.

Treatment of sections showing areas of desquamated cells (Days 3–7) with either acid or alkali revealed more fluorescence when subsequently stained with anti-Sendai virus antisera (Fig. 7a, b). All the control fluorescent studies remained negative. It thus seems that more viral antigens had been revealed and could mean that mouse antibody had been eluted from the tissues by these procedures.

Sections treated for 24 hours with specific antibody from either rabbit or man revealed significantly more antigen than sections treated for 30 minutes with the same reagents. Control sections treated with serum containing no anti-Sendai antibody and subsequently stained for Sendai virus did not show increased fluorescence. We interpret this as indirectly confirming that mouse antibody had been attached to desquamated cells in the bronchial lumen.

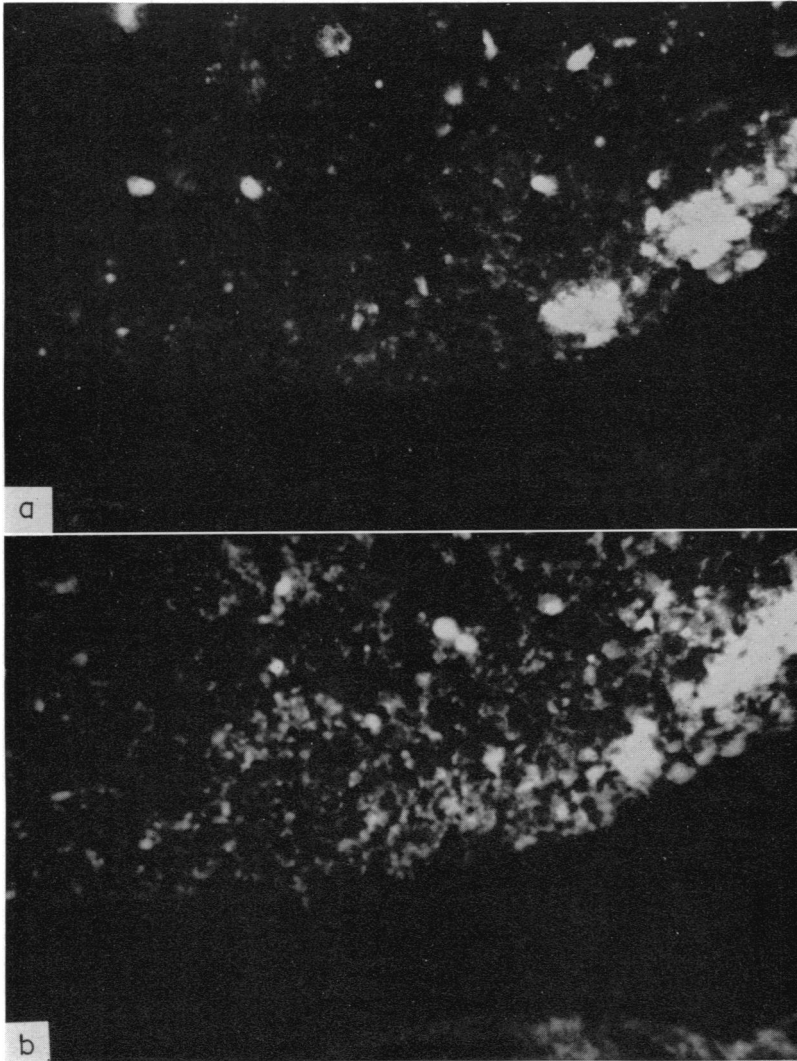


FIG. 5. Parallel cross sections of trachea, Day 4 (a) stained for virus and (b) stained for mouse immunoglobulin. The basement membrane is at the bottom, lumen above. Little positive staining for virus can be seen. There is generalized staining of the intraluminal cellular debris for immunoglobulin. The bright areas at right centre are autofluorescent. ( $\times 750$ .)

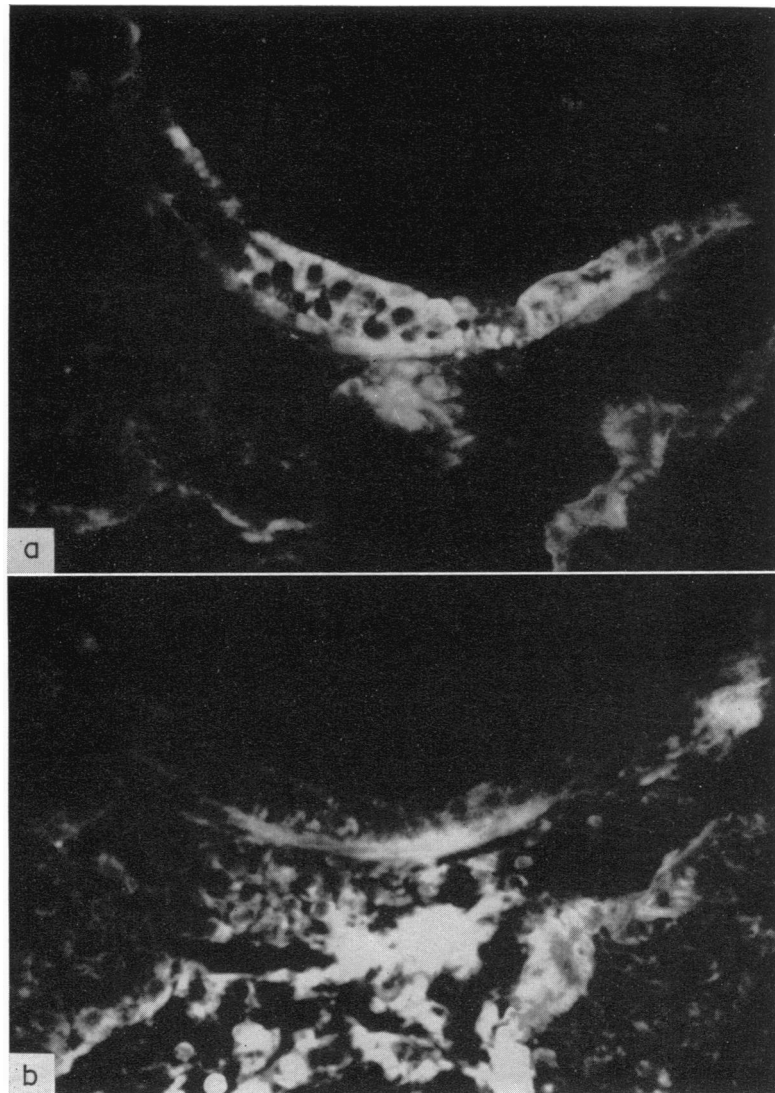


FIG. 6. Parallel cross sections of bronchus, Day 4 (a) stained for virus and (b) stained for mouse immunoglobulin. Virus is localized to mucosal cells and cells containing immunoglobulin are present in the adjacent peribronchial and perivascular oedema fluid. Blood vessel with autofluorescent wall is at bottom right. A small area of autofluorescence is also present deep to basement membrane at low centre. ( $\times 750$ .)



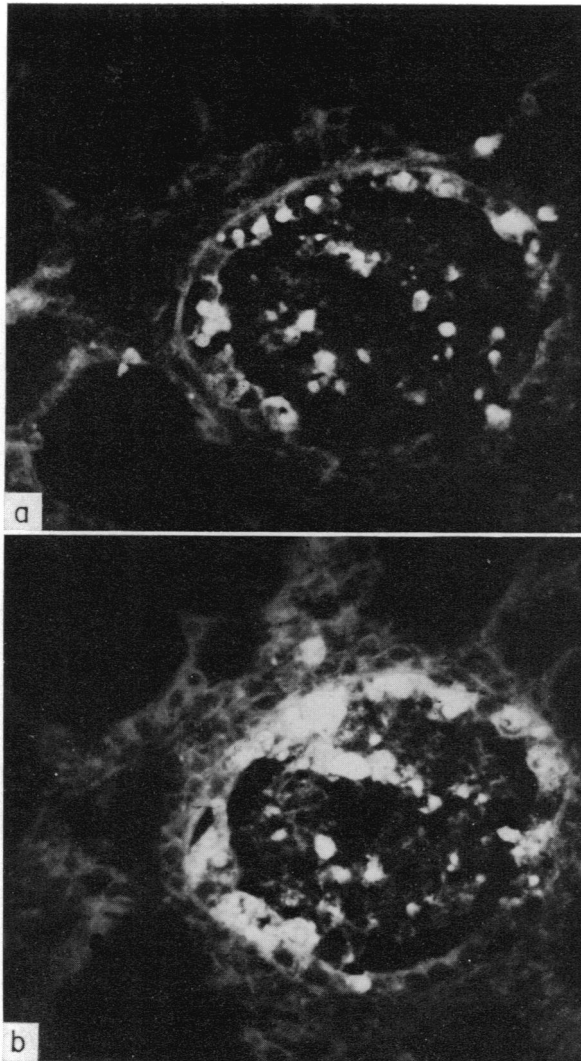


FIG. 7. Parallel sections of lung, Day 3, stained for virus (a) without and (b) with previous treatment of the section with acid buffer, pH 2, for 1 hour. There is clearly more staining for viral antigen in the cellular debris and of damaged cells still attached to the basement membrane in the treated section. Treatment with alkali buffer, pH 12, or prolonged incubation with a heterologous antiviral antiserum gave similar results. ( $\times 750$ .)

In some sections it was also noted that there was an increase in the amount of viral antigen detected by both techniques in some intact mucosal cells. It is intended to use sequential fluorescent staining methods to study this observation further.

It should be emphasized that we have by these indirect means shown that mouse antibody was already present by the 3rd day of the infection. This is at least 5 days before antibody was detectable in serum or secretions. Furthermore, as viral antigens were always present in untreated sections it is clear that mouse antibodies were fixed in the tissues in the presence of excess viral antigens.

#### *Distribution of viral antigens in bronchial lymph nodes*

Bronchial lymph nodes were often difficult to find, even in transverse sections through the hilum of the lung. They were always small structures in which it was usually impossible to distinguish discrete lymphoid follicles. Single cells, presumably macrophages, containing

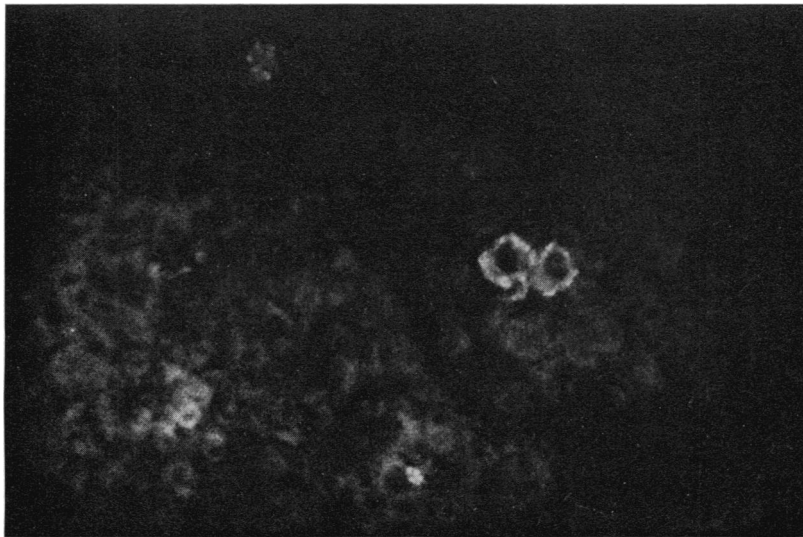


FIG. 8. Section of bronchial lymph node stained for virus, Day 6. Macrophages containing viral antigens can be clearly seen. There is a small area of more diffuse specific fluorescence at the lower left. Such findings were present from 3rd to 9th day. ( $\times 750$ .)

viral antigens were occasionally found between the 3rd and 9th days of the infection (Fig. 8). Rarely viral antigen appeared to be present free in lymph nodes and in afferent lymphatics.

#### *Distribution of viral antigens in the spleen*

Attempts to recover infectious virus from spleen suspensions at varying times after inoculation were always unsuccessful. However, by means of immunofluorescent staining it was possible to detect viral antigens in the spleens of all animals from the 3rd to the 21st day of the infection and occasionally after this time up to the 49th day. Macrophages containing viral antigen were often seen in the red pulp close to medullary cords (Fig. 9). Rarely, free antigen was found on the circumference of lymphoid follicles. (Fig. 10). It

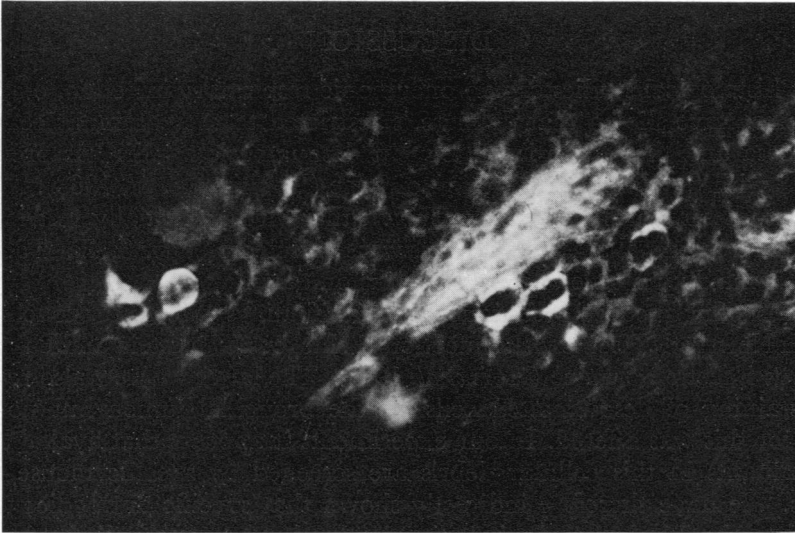


FIG. 9. Section of spleen stained for virus, Day 5. Several macrophages can be seen to contain viral antigen. Similar findings were present from the 3rd to 49th day. The medullary cord autofluoresces. ( $\times 750$ .)

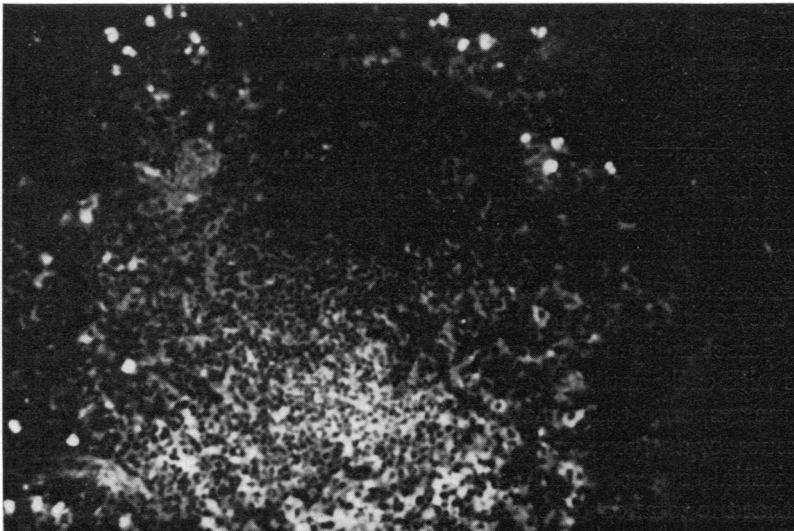


FIG. 10. Section of spleen stained for virus, Day 6. Apparently free viral antigen is present close to and partly surrounding a germinal centre. This finding was uncommon and was never seen before the 3rd or after the 8th day. ( $\times 400$ .)

thus appears that non-replicating viral components are localized in the spleen on the 3rd day and that some may persist for up to 49 days.

## DISCUSSION

Numerous histological studies of non-pneumonic respiratory infection, employing conventional stains, have shown that damage is restricted to the columnar cells of the respiratory mucosa and that there is subsequent desquamation. This has previously been demonstrated with Sendai virus infection of mice (Robinson, *et al*, 1968). The immunofluorescence studies reported here have shown that virus is initially restricted to these mucosal cells and maximal amounts of virus were detected on days 3, 4 and 5. This corresponded with a maximum titre of infective virus on day 4.

Using immunofluorescence techniques, similar findings affecting bronchi have been reported with Newcastle disease virus infection of chickens (Burnstein and Bang, 1957) and influenza virus infection of mice (Hers *et al*, 1962). The latter workers also reported weak fluorescent staining of desquamated cells on the bronchial lumen but no satisfactory explanation for this was offered. In our experiments it appears that available viral antigenic determinants in this cellular debris are screened by specific mouse antibody to Sendai virus. We have therefore indirectly shown that specific antibodies were present from the 3rd to the 7th day of the infection in the desquamated cells in the presence of antigen excess.

Studies by many workers on respiratory virus infections in man and animals have shown that antibody is first detectable in serum and secretions 6–9 days after a primary infection. A similar sequence of events has been reported in the model used here. (Robinson *et al*, 1968; Blandford *et al*, 1971).

Data in support of an earlier systemic antibody response has been presented by Schwenk and Lehmann-Grübe (1970). They have shown, using a Jerne plaque technique, that mouse spleen cells were making specific antibody to influenza virus ribonucleoprotein 24–36 hours after intranasal influenza virus infection. The detectable serum antibody response occurred at 6 days. It seems clear that special techniques must therefore be employed to detect early antibody present, in the intact animal, in antigen excess. This situation must be common with all replicating antigens.

It is not known whether the early antibody detected on the desquamated cells was locally or systemically manufactured. The large numbers of immunoglobulin secreting cells which appeared in the bronchial submucosa by the 2nd day offer the attractive possibility that they could be the source.

Failure to detect antigen away from the bronchial mucosa until desquamation, which synchronizes with early antibody production, has occurred, might suggest that the priming of the immune response takes place in the lungs. We did not however, examine all the lymphoid tissues for antigen, and in particular the lymphatic drainage of the nasopharynx could be an initial route of priming. Nevertheless, the lungs are in a peculiar anatomical situation in that the total cardiac output is pumped through the lung capillaries with each heart beat. Thus, in this situation there would be a maximum opportunity for an antigen-responsive circulating lymphocyte to meet its appropriate antigen. Similarly small amounts of free antigens would be maximally diluted and dispersed so that the chances of detecting such antigens would be remote with the methods used in this study.

Speculation as to the function of this early formed antibody must remain. Clearly it

could be vitally important in limitation of and recovery from the primary infection. Robinson, Cureton and Heath (1969), using this model, showed that when animals were treated with an immunosuppressive agent they developed massive pneumonic changes which frequently proved fatal. This outcome was found to be associated with depressed antibody production and failure to eradicate virus. The coincidence of desquamation of cells with the appearance of antibody could suggest a cause and effect relationship. Complement-fixing antibody could both damage cells with budding virus on their surface and mediate a local Arthus reaction, as antigen excess is demonstrably present.

The finding that viral antigen was frequently present in the spleen long after recovery from infection is interesting. It would support the currently held view that the long term serum antibody response after some viral infections is likely to be associated with persistence of viral antigens within the animal.

It seems likely that this model system could help to elucidate many of these problems.

Finally, we would like to suggest that acid or alkali treatment of sputum smears in respiratory infections could improve the chances of defining the infecting agent when fluorescent antibody techniques are being used.

#### ACKNOWLEDGMENTS

We wish to thank Mrs B. Hill for her excellent technical assistance and Mr R. Stuckey for preparing the black and white photographs. Part of this work was supported by a Medical Research Grant (962/263/B) to one of us (G.B.).

#### REFERENCES

- BLANDFORD, G., CURETON, R. J. R. and HEATH, R. B. (1971). 'Studies of the immune response in Sendai virus infection of mice'. *J. Med. Microbiol.*, **4**, 351.
- BURNSTEIN, T. and BANG, F. B. (1958). 'Infection of the upper respiratory tract of the chick with a mild (vaccine) strain of Newcastle Disease Virus. II. Studies of the pathogenesis of the infection'. *Bull. Johns Hopk. Hosp.*, **102**, 135.
- HERS, J. F. PH., MÜLDER, J., MASUREL, N., KUIP, L. V. D. and TYRRELL, D. A. J. (1962). 'Studies on the pathogenesis of influenza virus pneumonia in mice'. *J. Path. Bact.*, **83**, 207.
- MCCORMICK, J. N., PAGE FAULK, W., FOX, H. and FUDENBERG, H. H. (1971). 'Immunohistological and elution studies of the human placenta'. *J. exp. Med.*, **133**, 1.
- NAIRN, R. C. (1969). Fluorescent Protein Tracing (Ed. by R. C. Nairn), p. 303, E. & S. Livingstone Ltd., London.
- ROBINSON, T. W. E., CURETON, R. J. R. and HEATH, R. B. (1968). 'The pathogenesis of Sendai virus infection in the mouse lung'. *J. Med. Microbiol.*, **1**, 89.
- ROBINSON, T. W. E., CURETON, R. J. R. and HEATH, R. B. (1969). 'The effect of cyclophosphamide on Sendai virus infection of mice'. *J. Med. Microbiol.*, **2**, 137.
- SAINTE-MARIE, G. (1962). 'A paraffin embedding technique for studies employing immunofluorescence'. *J. Histochem. Cytochem.*, **10**, 250.
- SCHWENK, H. V. and LEHMANN-GRÜBE, F. (1970). 'The localized hemolysis-in-gel method adapted to the detection of spleen cells releasing virus-specific antibodies'. *J. Immunol.*, **104**, 1184.