

# Increased Myocardial Perfusion by Internal Mammary Artery Implant: \*

## Vineberg's Operation

DONALD B. EFFLER, M.D., LAURENCE K. GROVES, M.D., F. MASON SONES, JR., M.D.  
EARL K. SHIREY, M.D.

*From the Department of Thoracic Surgery, and the Cardiac Laboratory,  
The Cleveland Clinic Foundation, Cleveland, Ohio*

EFFORTS to improve coronary insufficiency by surgical means began more than three decades ago. It is not the scope of this report to list the various procedures nor to give credit to the many authors who have contributed to this phase of surgical investigation. This report is concerned with only one method that improves myocardial blood flow—albeit a method that has been viewed with skepticism since its initial presentation in 1946.<sup>4</sup>

The disappointments that followed successive waves of *surgical* enthusiasm have closed some minds to the possibility that coronary arterial disease can be improved by operation. Thus, the status of the surgical treatment for coronary arterial disease is in virtual disrepute in most medical centers today. The surgeons themselves are not entirely responsible for this unhappy situation. Clinical methods for appraisal of the patient with coronary arterial disease have been far from exact. As a result, the diagnosis itself of coronary arterial disease has had various meanings in individual medical minds. There is little future for any operative treatment of coronary insufficiency unless organic arterial disease can be evaluated precisely before and after operation.

### Rationale

The idea of implanting the internal mammary artery into the myocardium of the

left ventricle was conceived by Vineberg.<sup>4</sup> He believed that this systemic artery could revascularize, at least in part, the ischemic myocardium. Although an arterial implant in skeletal muscle results in hematoma and probable occlusion of the artery, in the muscle of the heart it may remain functional. There is a great difference between cardiac muscle and skeletal muscle. Vineberg<sup>5</sup> points out that ventricular myocardium is a spongelike mass in which arteries, arterioles, sinusoids, capillaries, and unique veins provide a peculiar circulatory pattern (Fig. 1). Blood or other physiologic fluids injected into healthy ventricular myocardium demonstrate a remarkable capacity for runoff. Unlike skeletal muscle, it is virtually impossible to create hematoma within healthy ventricular myocardium. It was this simple observation and Wearn, Mettier, Klumpp, and Zschiesche's<sup>7</sup> demonstration of the remarkable pattern of sinusoidal vessels that stimulated Vineberg's concept of internal mammary artery implant as a method of revascularization.

Experimental work, first reported in 1946,<sup>4</sup> proved that the implant can remain patent, and that it can contribute to the intramyocardial circulation of the left ventricle. When progressive myocardial ischemia was experimentally created in animals,<sup>1</sup> it was observed that the incidence of successful internal mammary artery implants increased. The influence of myocardial ischemia upon the development of collateral circulation has been recognized by other

---

\* Presented before the American Surgical Association, Phoenix, Arizona, April 3-5, 1963.

workers. Sewell<sup>2</sup> has shown conclusively that collateral arterial supply is most likely to occur when an arterial gradient exists in the involved region. It seems well established that new vascular growth is most likely to occur in a region of localized arterial insufficiency.

Our interest in Vineberg's experimental work began in 1959. The laboratory demonstrations at McGill University were most impressive; the survival of experimental animals with internal mammary artery implants which were then subjected to progressive coronary arterial occlusion, offered experimental proof of Vineberg's thesis. In the matter of clinical application, however, there were two factors of concern to us: 1) the lack of a method of establishing patency of the implanted artery within the living patient; and 2) selection of the patient for Vineberg's operation required clinical information that was not possible to obtain at that time.

Survival alone, after internal mammary artery implantation, is not evidence that the implant is open and contributing to the intramyocardial circulation. Postmortem corrosion-cast studies are helpful, but are available more often in the surgical failures than successes. There was need for a method, applicable to the living patient, which demonstrates communication between the viable implant and the intramyocardial circulation.

Selection of the patient who could benefit by Vineberg's operation was to us a matter of great concern. The revascularization provided by a successful internal mammary artery implant would according to our thinking have definite limits of application. The patient most likely to benefit from this operative procedure would be one who had ischemia of the left ventricle. Logical selection of the patient for Vineberg's operation required specific diagnostic methods capable of demonstrating disease predominantly in the major branches of the left coronary artery. Improper applica-

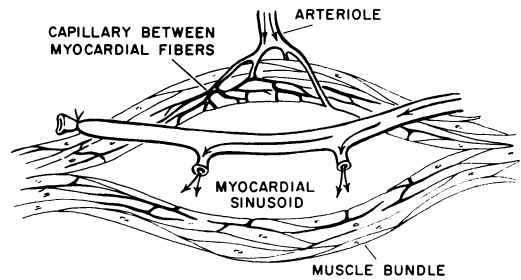


FIG. 1. Schematic illustration of the arterial implant with open side branches. Initial runoff from the implanted internal mammary artery enters the myocardial sinusoid. (After Vineberg, A.: *Canad. M.A.J.*, 78:3, 1958.)

tion of this imaginative approach for relief of myocardial ischemia would strengthen the popular misconception that coronary arterial disease is a nonsurgical entity.

In 1960 the Sones<sup>3</sup> technic of selective coronary arteriography received clinical application. Utilizing high-speed cinephotography it offered a precise method of demonstrating occlusive coronary artery disease. A technic was now available that permitted appraisal of coronary arterial disease in living patients and, equally as important, provided an objective method of evaluating attempts to increase myocardial perfusion. Sones and his associates had the opportunity to study patients in whom various operative procedures had been performed for relief of myocardial insufficiency. Early in 1962, two patients with internal mammary artery implants of five and six years' duration were studied. Direct injection of the left internal mammary artery substantiated Vineberg's contention—the implant was patent, and in each instance it supplemented coronary blood flow.

Selective coronary arteriography has provided the information that we required before undertaking clinical application of Vineberg's work. This technic provides a method for selecting patients for surgical treatment, and, furthermore, offers a method of determining success or failure of the internal mammary artery implant in the living patient.

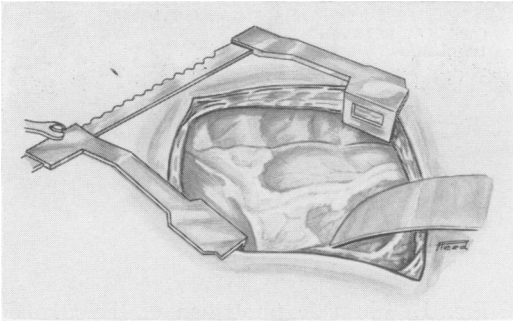


FIG. 2. The left pleural space is entered through the sixth interspace; the lung is retracted posteriorly to expose the anterior chest wall and the left side of the pericardial sac.

### Experience

Our first internal mammary artery implant in a patient with coronary insufficiency was performed in May, 1962. Since then 45 operations of this type have been performed in the Cleveland Clinic Hospital. One patient died four and one-half hours after surgery from apparent myocardial infarction; the other 45 patients are living.

Our selection of the patients for internal mammary artery implant is limited by our understanding of the operation's potential. Every such patient has been studied by coronary arteriography. The operation is

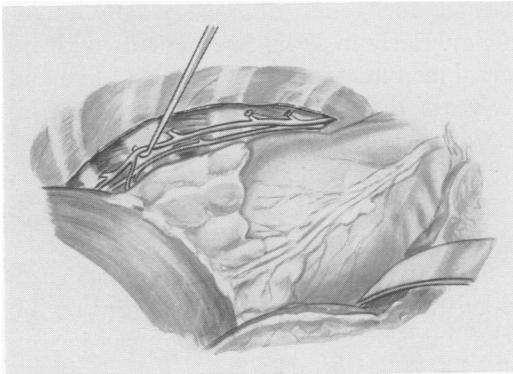


FIG. 3. Initial mobilization of the left internal mammary artery requires partial removal of the overlying parietal pleura and the sternocostal muscle. The side branches at the third and fourth costal cartilages are isolated and divided; whereas, dissection is continued; the vessel below the fourth cartilage is left intact.

restricted to those patients who: 1) demonstrate significant incapacity attributable to myocardial ischemia; 2) have arteriograms that demonstrate predominant involvement of the anterior descending branch of the left coronary artery; and 3) have not suffered major myocardial infarction of the anterior left ventricle.

As stated before: the limitations of successful internal mammary artery implant are by no means determined. In light of our present knowledge we are reluctant to implant an artery in ventricular myocardium that has undergone extensive fibrosis. This reluctance is based on the fear that scarring of ventricular myocardium will destroy the vascular sponge and drastically reduce the chance for future arborization of the arterial implant. Additional experience will help us to decide whether or not this is a valid objection.

### Technic

The operation for internal mammary artery implant although simple in concept involves meticulous details. Experience with 46 operative procedures has enabled us to set up a standardized operative technic.

The left pleural space is entered through the sixth interspace; the conventional posterolateral incision extends anteriorly beyond the nipple (Fig. 2). Both the lung and pericardial fat pad are retracted posteriorly to expose the left internal mammary bundle. The internal mammary artery is visible down to the third or fourth interspace; there it passes behind the sternocostal muscle.

The sternocostal muscle is incised from the sixth to the third interspaces, and is dissected medially from the chest wall as a flap to expose the underlying artery. The internal mammary artery is freed of overlying pleura, fascia, and muscle from the second to the sixth interspaces.

Mobilization of the internal mammary artery may be a tedious procedure (Fig. 3). Preferred instruments for dissection in-

clude: blunt nerve hooks, long-handled scissors, smooth forceps, and a long-handled right-angle clamp. Serrated or toothed instruments are never used on the artery itself. Initial mobilization of the artery begins at the third and fourth interspaces; here the intercostal branches are isolated, are ligated with fine silk, and are divided. Neither metal clip nor electric coagulation is used on the side branches of the parent artery. Dissection of the artery at the fifth and sixth cartilages is then undertaken, and all branches at that level are preserved. At that level, each side branch is considered as a potential source of revascularization, and as such is zealously guarded. At the sixth interspace the internal mammary artery branches then continue to join the superior epigastric artery; either the main vessel or an adjacent branch is selected for future use as the *drag branch*.

The mobilized internal mammary artery is left in continuity on the chest wall. The vessel is covered by gauze sponge previously soaked in a solution of papaverine (grs. iv). Papaverine affords effective relief of the vasospasm that accompanies the extensive dissection (Fig. 4). Attention is then directed to the pericardial fat pad, which is dissected away from the underlying pericardium. The fat pad is taken down from the base of the heart, and is freed down to the junction of the pericardium and the diaphragm; it is used later as a living graft.

The denuded pericardium is incised, and a large window is created by excising an elliptic segment of the sac (Fig. 5). The interior of the sac is then abraded by a surgical rasp to remove the lining endothelium. A counterincision approximately from 5.0 to 6.0 cm. in length is made in the extreme posterior aspect of the pericardial sac, permitting drainage into the left pleural space. Some abrasion of the right ventricle and the posterior aspect of the left ventricle is undertaken; the extent of this varies with the individual operation.

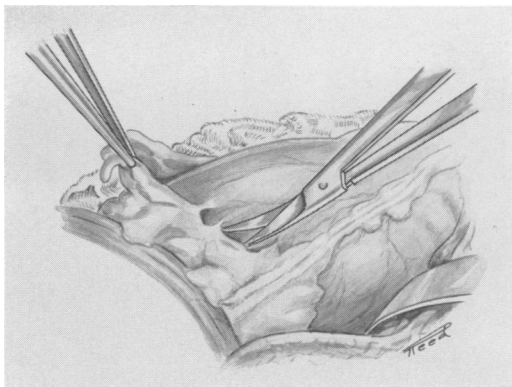


FIG. 4. The pericardial fat pad is dissected away from the pericardial sac anteriorly to the left phrenic bundle. Attachments of the fat pad to the diaphragm and the lower aspect of the left phrenic bundle are left intact to maintain at least partial blood supply. The papaverine-soaked sponge rests between the pericardium and the chest wall in contact with the mobilized internal mammary artery.

Selection of the tunnel site is determined mainly accordingly to the contour of the heart and an estimation of the plane the artery will follow when it is diverted from the chest wall to the tunnel. The location of the tunnel will also be affected by the distribution of the subepicardial vessels lateral to the anterior descending branch of the left coronary artery (Fig. 6). The length of the myocardial tunnel ranges between 2.5

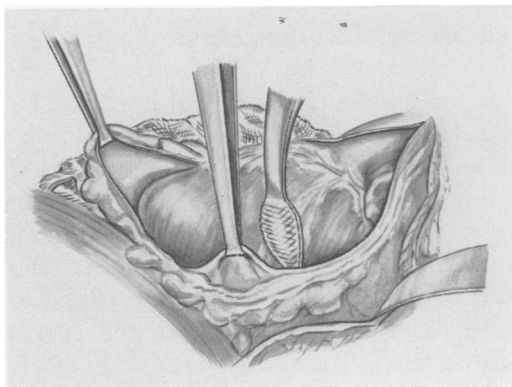


FIG. 5. Entry into the pericardial sac is made by a long, elliptic incision over the anterior aspect of the left ventricle. Abrasion of the interior aspect of the pericardial sac and the epicardium overlying the right ventricle and part of the left ventricle is then undertaken.

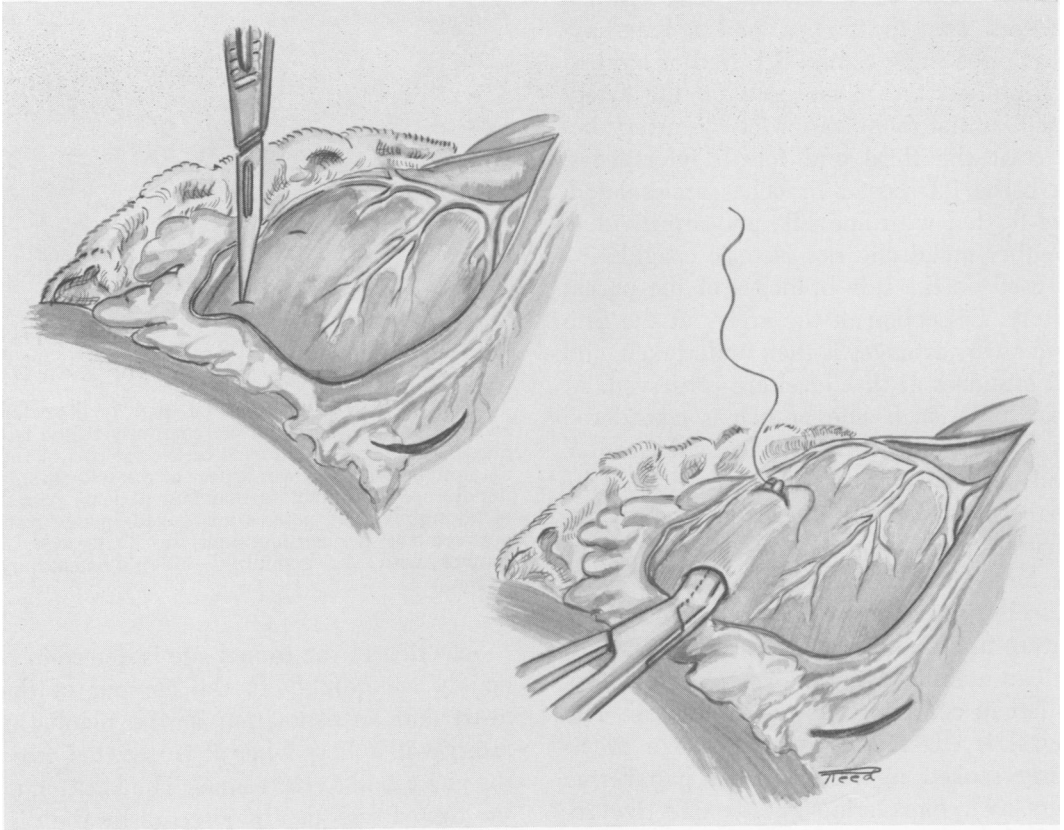


FIG. 6. Selection of the tunnel site is of utmost importance. As mentioned in the text, this will be determined by the position of the heart, the contour of the heart, and the distribution of the epicardial vessels. The tunnel is constructed in a plane that permits implantation of the artery with least chance for unfavorable angulation. The length and axis of the tunnel are designated by the two stab wounds that establish its position and limits. In the lower figure the dissecting instrument emerges from the proximal end of the tunnel to grasp the ligature affixed to the terminal *drag branch* of the artery.

and 5.0 cm. (our tunnels are longer than those advocated by Vineberg<sup>6</sup>). The axis and the length of the tunnel are fixed by two stab wounds in the ventricular myocardium. The tip of a long-handled hemostat is inserted into a distal stab wound, and the instrument is guided to the proximal stab wound. As the hemostat advances, the blades are alternately spread and closed to separate myocardial layers. In the course of dissection, if the ventricular chamber is entered, the instrument is promptly withdrawn and a more superficial plane of dissection is selected.

After preparation of the tunnel, the surgeon returns to the prepared internal mam-

mary artery, selects the *drag branch* and divides this between ligatures (Fig. 7). A long silk tie is left at the tip of this branch. The mobilized artery is then drawn away from the chest wall, and the protected side branches are now cut as far away from the parent vessel as possible. The typical implant has two or three actively bleeding branches. Implantation of the artery is accomplished by introducing the dissecting instrument through the full length of the tunnel, grasping the ligature on the *drag branch*, and drawing the artery with its bleeding side branches into the myocardial tunnel until its extreme tip is exteriorized at the exit point. Between chest wall and

tunnel the artery should be slack, but not excessively so; undue angulation at either end is not desirable. When the surgeon is satisfied with the position of the implanted artery, a mattress suture is placed around the projecting tip, and it is secured to the epicardium of the left ventricle. Any bleeding from the proximal or entrance point of the tunnel is controlled by light pressure over a gauze sponge.

After arterial implant the pericardial fat pad is drawn over the anterior aspect of the left ventricle below the tunnel entrance, and is inserted within the pericardial sac until its tip emerges from the previously prepared counterincision. The intrapericardial position of the fat pad prevents herniation of the heart; it may contribute addi-

tional blood supply to ischemic ventricular myocardium. Throughout this procedure the surgeon takes particular care that nothing disturbs or impinges against the exposed portion of the internal mammary artery (Fig. 8).

The chest incision is closed in conventional fashion with waterseal suction drainage. Supporting blood transfusions are given as indicated according to continuous appraisal of the surgical blood loss. The postoperative care is basically the same as that of any patient who has undergone cardiac surgery.

### Discussion

Before 1962 only a few operations were performed in the Cleveland Clinic Hos-

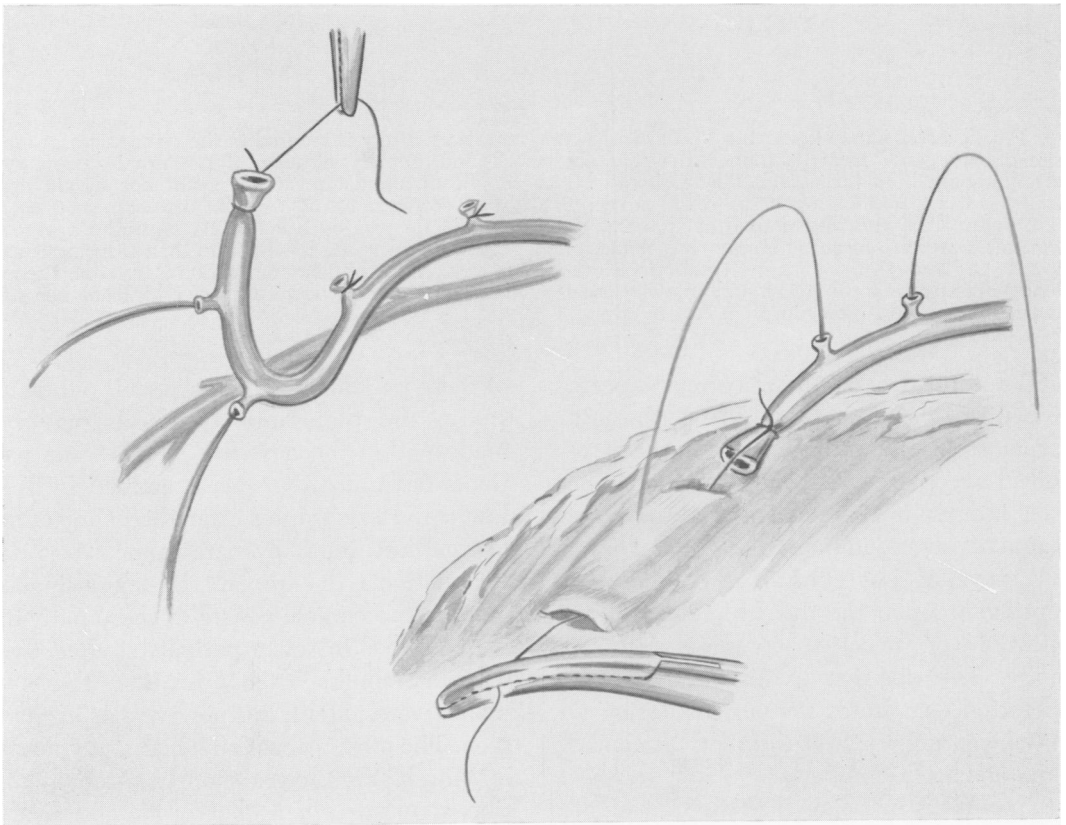


FIG. 7. The local application of papaverine upon the mobilized internal mammary artery may be impressive as the vessel is cut away from the chest wall; bleeding from the selective side branches can be forceful. The lower right-hand figure suggests the appearance of the mobilized artery and its bleeding branches as it is about to enter the proximal end of the prepared tunnel.

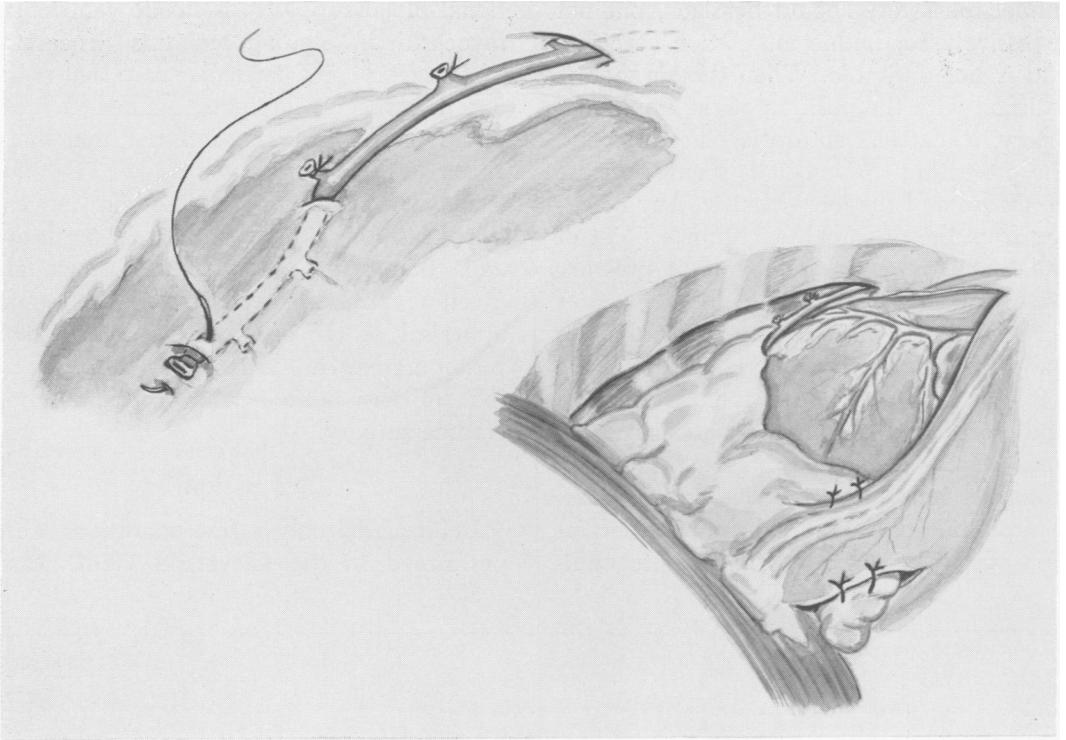


FIG. 8. After implantation the tip of the internal mammary artery is secured to the epicardium at the site of emergence from its tunnel. Between chest wall and tunnel entrance, the internal mammary artery should be a little slack. There should be no significant angulation at any point nor should extraneous tissue impinge upon the vessel in such a way as to compromise its internal diameter. The bottom figure illustrates our method of applying the pericardial fat pad by bringing it across the apex of the left ventricle, inserting it into the pericardium beneath the phrenic bundle, and then securing it as it emerges through the posterior counterincision. In this way danger of acute herniation is averted. If the living graft can contribute blood supply to the ischemic ventricular myocardium, an additional benefit is derived from this procedure.

pital for the treatment of coronary occlusive disease. There was little enthusiasm for most of the procedures that have received acceptance elsewhere. As stated before, interest in the concept of the internal mammary artery implant dates back a number of years, but clinical acceptance was contingent upon the development and application of selective coronary arteriography. The decision to utilize Vineberg's operation constitutes for our institution an initial venture in the surgical treatment of coronary arterial disease.

No effort is made at this time to evaluate the series of 45 patients who have survived this operation. The time factor itself does not yet permit this. It is our hope that each

of these patients will have careful follow up study, and that valid appraisals may be made within the next few years. Some patients have already been examined by follow up arteriography after direct injection of the left internal mammary artery. In two patients the implant is obviously occluded; the clinical course of these patients is unaltered. In seven patients studied two to four months after operation, the implants were patent, but new vessels are not seen. The most recent follow up study made in March, 1963, eight months after operation, shows excellent arborization and visual run-off into the intramyocardial circulation (Fig. 9). A period of six or more months is required for demonstration of new ves-



sels. This is consistent with Vineberg's investigational work.<sup>6</sup>

We have emphasized the importance of attention to details in the execution of this operative procedure. The fate of the implanted artery may be influenced by many factors, some of which might seem inconsequential. Reflecting upon our own experience it is obvious that the early operations left much to be desired from the standpoint of technic. It is therefore gratifying to know that despite our technical shortcomings apparently success was achieved in most instances. Surgeons who intend to utilize this operative procedure will find that the great amount of time spent in

preliminary indoctrination is indeed a sound investment.

### Conclusion

Vineberg's internal mammary artery implant operation can provide improved myocardial perfusion in patients with coronary insufficiency who have been clinically so selected by coronary arteriography. The limitations of improvement in coronary perfusion are not established.

Forty-six patients have undergone internal mammary artery implantation at the Cleveland Clinic Hospital; all but one patient survived. The time factor does not permit clinical appraisal of this patient group.

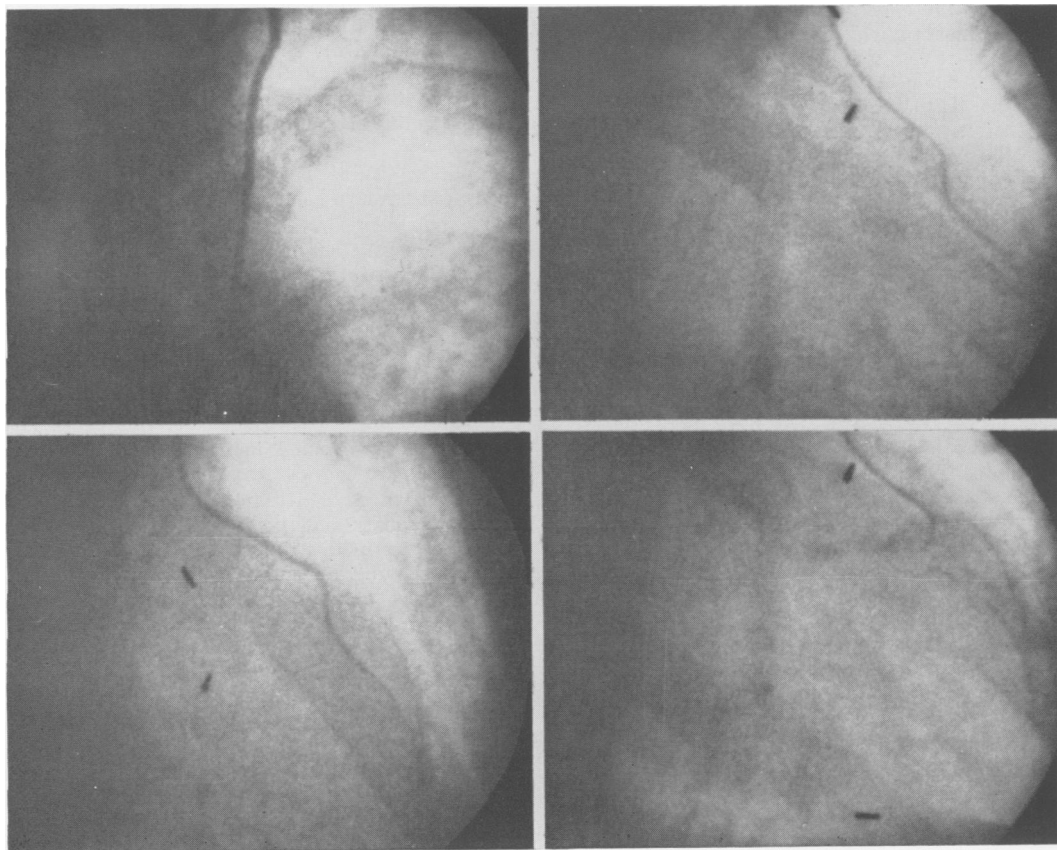


FIG. 9. Follow up arteriograms made eight months after internal mammary artery implant. Direct injection of contrast medium opacifies the full length of the left internal mammary artery. Selected frames taken from the film record demonstrate the arterial implant and its runoff into the ventricular myocardium with opacification of local coronary veins.



## References

1. Litvak, J. and A. Vineberg: Experimental Gradual Arterial Occlusions With *in vitro* and *in vivo* Observations. *Surgery*, **46**:953, 1959.
2. Sewell, W. H. and P. A. Davalos: Factors Influencing Collateral Arterial Formation from Pedicles on the Surface of the Hearts of Dogs. *Angiology*, **13**:231, 1962.
3. Sones, F. M., Jr. and E. K. Shirey: Cine Coronary Arteriography. *Mod. Concepts Cardiovas. Dis.*, **31**:725, 1962.
4. Vineberg, A. M.: Development of an Anastomosis Between the Coronary Vessels and a Transplanted Internal Mammary Artery. *Canad. M.A.J.*, **55**:117, 1946.
5. Vineberg, A. M.: Coronary Vascular Anastomoses by Internal Mammary Implantation. *Canad. M.A.J.*, **78**:871, 1958.
6. Vineberg, A. M.: Personal Communication, Nov. 1962.
7. Wearn, J. T., S. R. Mettier, T. G. Klumpp and L. Zschiesche: The Nature of the Vascular Communications Between the Coronary Arteries and the Chambers of the Heart. *Am. Heart J.*, **9**:143, 1933.

## DISCUSSION

DR. WILLIAM P. LONGMIRE, JR. (Los Angeles): I would first certainly like to compliment Dr. Effler and his associates for this beautiful demonstration of the effectiveness of the Vineberg procedure. I must say we have been among those who have been rather skeptical of this operation, not that it has not been demonstrated on a number of occasions that the vessel will remain open but skeptical in regard to the volume of blood that might be carried through this vessel and into the myocardium. It certainly seems that some of the studies such as Dr. Effler has presented here today would go a long way toward supporting the idea that a significant volume of blood may be transported to the myocardium by this manner.

I would like at this time to review the various technics which have been utilized over the last five years at the U.C.L.A. Hospital by Dr. Albert Kattus, Dr. Jack Cannon and myself in a series of 21 different patients. A variety of procedures have been utilized, however, we have not used the Vineberg technic.

(Slide) The majority of these cases have been coronary endarterectomies performed through one of the major coronary vessels, either the right or the left anterior descending. In the more recent cases a vein patch graft has been placed over the site of the incision in an attempt to prevent the narrowing of the vessel at this point.

(Slide) In two cases the internal mammary artery has been anastomosed end-to-end, once to the left anterior descending and once to the right main coronary. One of these we know was unsuccessful; the other is in doubt. The anastomosis has not been studied in a manner such as Dr. Effler and his colleagues have studied their implants.

(Slide) Two cases have been approached through the root of the aorta. In one of them it was possible successfully to remove a thickened intimal core such as is indicated in these diagrams, the advantage of this technic being that it is not

necessary to make an incision into the coronary vessel itself. In one additional case, without performing an endarterectomy the vessel has merely been opened.

(Slide) In this case the left main coronary was opened and the incision extended into the anterior descending and the circumflex. The thickened core was quite pliable and in this case it was possible to spread the vessel, place in a roof graft such as is seen in this diagram, and get a good flow through the vessel.

(Slide) Table 1 summarizes the various procedures that have been performed.

(Slide) As Dr. Effler implied, certainly this type of surgery has been fraught with many hazards and heartbreaks. Up to this time 11 patients have died; 10 patients have survived. Six of these have been lost at the time of operation, 3 have died postoperatively while still in the hospital, and 2 patients succumbed after operation, one as late as 2 years after operation (Table 2).

(Slide) Of the patients surviving, 1 is considered unimproved, 4 improved, and in 5 cases the results are considered good.

We have studied some of these patients with repeat coronary angiograms but do not have complete studies in this regard, and this evaluation is made primarily on subjective symptoms and the performance of the patients on treadmill exercise tests.

DR. FRANK COLE SPENCER (Lexington, Kentucky): I was particularly interested in Dr. Effler's enthusiasm for the Vineberg procedure, because in 1957 Dr. Sabiston and Dr. Blalock reported studies in 34 dogs in which the common carotid artery, which is larger than the internal mammary, was implanted into the wall of the left ventricle. This vessel remained open in most of the dogs, but flow studies after a few months showed that only a very small amount of blood, an average of about 5 ml./min., would flow through this vessel at a mean perfusion pressure of about 150 mm. Hg.