

# Clinical Experience with Management of the Infected Dacron Graft \*

MAJ. SAMUEL C. CARTER,\*\* MC, USA, LT. COL. ARTHUR COHEN,\*\*\* MC, USA,  
LT. COL. THOMAS J. WHELAN,† MC, USA

*From the General Surgery and Peripheral Vascular Surgery Service, Walter Reed  
General Hospital, Walter Reed Army Medical Center, Washington 12, D. C.*

## Introduction

SINCE the addition of the procedures of vascular replacement or bypass to the surgical armamentarium and the advent of synthetic prostheses for use with these procedures, there have been many reports concerning various ramifications of this technic but relatively few have dealt specifically with the complications of infection.<sup>1, 8, 9</sup> Since the experience of any single investigator or group is limited with regard to this problem, it is believed that a report of the experience at Walter Reed General Hospital with seven cases of infected or exposed Dacron grafts is justified. That infection surrounding a Dacron graft does not necessarily lead to hemorrhage, extrusion or thrombosis will be emphasized in this paper. The problem of infection has far reaching implications both in military and civilian surgery, notably in this heyday of trauma. Although the cases to follow are not in themselves associated with trauma, the principles outlined have application not only as presented but also as applied to

traumatic situations where contamination is inevitable.

Two incompletely-answered questions with reference to this aspect of vascular surgery are: 1) A specific wholly satisfactory method of treating established infection surrounding a synthetic fabric prosthesis; and 2) The immediate fate of a prosthesis placed in an infected or potentially infected site.

The opinion generally held concerning the first of these questions suggests that, by and large, it is necessary to remove the prosthesis in established deep infection to effect ultimate wound healing lest the graft potentiate the infection by acting as a persistent foreign body. The consensus in regard to the second question is that grafts so placed, that is, in contaminated areas, are destined to failure.

The following cases are offered to cite the Walter Reed General Hospital experience with infection in association with synthetic fabric prostheses and to show that, with aggressive surgical debridement, coverage of the graft with healthy tissue, topical and systemic antibiotic therapy, and delayed subcutaneous and skin closure, sound healing about the prosthesis may be effected.

## Case Reports

**Case 1.** J. N., a 51-year-old man, was admitted to Walter Reed General Hospital for the fourth time in November 1960 with a chronic draining

\* Submitted for publication October 12, 1962.

\*\* Assistant Resident, General Surgery Service, Walter Reed General Hospital.

\*\*\* Formerly, Chief, General Surgery Service and Peripheral Vascular Surgery Service, Walter Reed General Hospital. Presently, Chief of Surgery, U. S. Army Hospital, Munich, Germany.

† Chief, General Surgery Service and Peripheral Vascular Surgery Service, Walter Reed General Hospital.

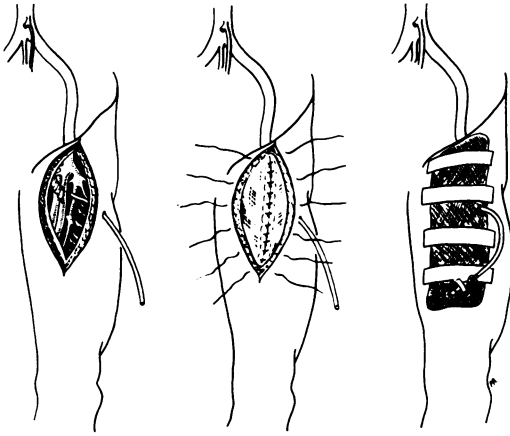


FIG. 1. (left) Catheter placed through normal skin to region of graft. (middle) Closure of deep fascia over graft with skin sutures left long for later closure. (right) Dressing and the catheter.

sinus in the right femoral region. He had bilateral intermittent claudication of the thighs and calves in January 1955 and in November 1955 a homograft bifurcation bypass graft was inserted from distal aorta to both common femorals with initial good results and relief of claudication. This graft thrombosed and return of claudication necessitated replacement by a Dacron bypass graft in 1958. Good function of this graft obtained until April 1960 at which time the patient presented with a false aneurysm of the right common femoral artery at the site of the suture line between the distal limb of the bypass graft and the femoral artery. Disruption of the distal suture line had occurred, the sutures having pulled out of the host vessel. The distal end of the graft was clamped and transected and the common femoral, deep femoral, and superficial femoral arteries where they were confluent and contiguous with the aneurysm were ligated. A Dacron tube was then inserted between the previously transected distal limb of the graft end-to-end and end-to-side to the superficial femoral artery. The patient was given chloramphenicol postoperatively, 4.0 Gm. a day for three days then 1.0 Gm. a day for a total of 14 days. The anastomoses worked well but the patient developed cellulitis and an abscess of the right femoral incision two weeks later. There was only partial response to parenteral penicillin and incision and drainage. He was left with a chronic draining sinus for which he sought treatment on his fourth admission in November 1960. Peripheral pulses were present and of good quality at this time. The sinus tract was dissected down to and beneath the lateral aspect of the graft where it led into a granulation-lined cavity which

was excised laying bare an area approximately 2.0 × 1.5 cm. on the lateral aspect of the graft. The wound was irrigated with sterile saline. A small polyethylene catheter was led through a laterally-placed stab wound and sutured into place beside the graft with 3-0 plain catgut sutures. The deep fascia was then loosely approximated over the graft with 3-0 plain catgut sutures. Fine stainless steel wire sutures were placed in the skin but the sutures at the midportion of the wound, where the sinus tract had existed, were left loose and tied 48 hours later when the wound was clean (Fig. 1).

Postoperatively the patient was treated with erythromycin and streptomycin parenterally and 2.5 cc. of a solution of 1.0 per cent neomycin and 2.5 cc. of bacitracin in a concentration of 1,000 units per cc. were instilled into the polyethylene catheter every three hours for three days. Cultures of the sinus tract grew *Micrococcus tetragenus* which was sensitive to the antibiotics used. All antibiotics were discontinued at ten days and the wound healed without evidence of residual infection. The patient one year later has a solidly healed wound and a patent graft. Treatment in this case is a prototype of that employed in this series except for Case 7 and will be referred to through the remainder of the case reports.

**Case 2.** L. H., a 47-year-old man, was admitted to Walter Reed General Hospital on 17 June 1960 for the second time for treatment of a thrombosed Dacron graft with associated infection. He had previously undergone lumbar sympathectomy and had a Dacron aortic bypass graft inserted, one limb end-to-side into the left common femoral artery and the other limb side-to-side into the right common femoral artery and end-to-side to the right popliteal artery. He developed an infection in the popliteal region which apparently began as a stitch abscess. This progressed despite local conservative care and incision and drainage of an infected hematoma. Culture grew *Streptococci*. The patient subsequently bled from a false aneurysm with laminated clot where the graft had separated from the popliteal artery. The graft was ligated proximal to the aneurysm and the patient was transported by air to Walter Reed General Hospital. Upon arrival the right lower extremity was in no immediate danger of loss of viability. Wound infection of the right popliteal area was treated prior to definitive operation. He was given 2.0 Gm. of chloramphenicol per day for a two-week period before operation. The Dacron graft on the right was removed and replaced by a sleeve graft from the right common femoral artery to the distal popliteal artery. A polyethylene catheter was inserted into the wound as described in Case 1 for postoperative instilla-

tion of antibiotics. The catheter was irrigated twice a day for three days with 1.0 per cent chloramphenicol and the patient was given 2.0 Gm. chloramphenicol per day orally for an additional five days. The wound healed *per primam*. A year later the right limb of the graft from aortic bifurcation to the popliteal artery thrombosed, necessitating replacement of the segment from aorta to femoral artery. No attempt was made to replace the lower segment of graft.

**Case 3.** J. A., a 47-year-old man, was admitted to the Walter Reed General Hospital with a long-standing history of intermittent claudication. Arteriography showed arteriosclerotic involvement of the aortic bifurcation and the right and left common iliac arteries. A Dacron aortic bifurcation bypass graft was inserted end-to-side into the aorta, the left limb end-to-side into the common femoral and the right, side-to-side into the common femoral artery opposite the profunda femoris artery and end-to-side into the popliteal artery. The right limb of the graft thrombosed and at subsequent operation it was noted that the distal end of the graft had torn loose from the artery at the anastomotic site. The thrombosed portion of graft was replaced by a Dacron sleeve graft which in turn thrombosed and was replaced by a second Dacron sleeve. This worked well for ten days at which time infection and subsequent dehiscence of the right inguinal incision occurred. The prosthesis was visible within the separated wound. Granulation tissue which formed the walls of a seroma were excised until healthy bleeding tissue was encountered. The wound was irrigated copiously with sterile saline and closed as described in Case 1. To cover the graft, it was necessary to undermine skin and subcutaneous tissue at the level of the fascia. A stab wound was made from beneath the lateral flap in the skin of the thigh and a small catheter was placed through this stab wound and into the area of previous wound separation. Culture of the wound grew hemolytic *Staphylococcus aureus* and *Aerobacter aerogenes*. The wound was treated four times daily with 4.0 to 5.0 cc. of 1.0 per cent chloramphenicol instilled into the catheter. The patient also received 2.0 Gm. of chloramphenicol per day orally. Irrigations were continued for six days and oral antibiotics for ten days. The wound healed with no evidence of residual infection. The right limb of the graft, however, again clotted several months later despite anticoagulant therapy. No further operation was attempted.

**Case 4.** A. K., a 51-year-old man, had progressively increasing claudication for which an aortic bypass procedure was performed using a Dacron

graft. Five months later he developed a saddle embolus to the aortic bifurcation. Embolectomy was done under local anesthesia due to the risk of general anesthesia. He was given anticoagulant drugs and developed a large hematoma and slough of the lateral skin edge at the upper pole of the femoral incision. It was believed that the wound would not heal and the graft would become exposed if the incision were left in this manner. The previous incision was therefore excised to normal skin and subcutaneous tissues. Following excision, a large hematoma cavity was exposed and a culture was taken. The hematoma was evacuated and the wound was irrigated. The hematoma extended to and around the graft and the femoral artery. There was no gross infection and no bleeding from the graft or suture line. Following evacuation of clots and irrigation, 300 mg. of chloramphenicol in solution was instilled and left in place. A polyethylene catheter was brought through a separate laterally-placed stab wound and laid in the depths of the wound for instillation of chloramphenicol solution. Five hundred mg. were instilled twice daily for four days. Other systemic antibiotics consisted of penicillin, chloramphenicol, erythromycin, and tetracycline given at different times, guided by culture and sensitivity studies. Culture of the wound grew *Streptococcus fecalis*, *Paracolon sp.* and *Proteus vulgaris*. Closure was as in Case 1. Healing was by secondary intention in the superficial portions of the wound. Eight months later without evidence of sepsis in the wound, the Dacron graft thrombosed. It was impossible to establish flow and a mid-thigh amputation became necessary.

**Case 5.** A. P., a 62-year-old man, was admitted to Walter Reed General Hospital in January 1960 for treatment of intermittent claudication. A bifurcation graft was inserted from the aorta to the right femoral artery side-to-side, thence to the popliteal artery end-to-side. The left limb of the graft extended down through the groin without anastomosis to the femoral artery because of extensive disease of this artery. Anastomosis was made end-to-side to the left popliteal artery. The left leg remained edematous following operation due to deep venous thrombosis and after a week, the left inguinal wound was noted to exude serous fluid. The wound edges subsequently separated, revealing obvious wound infection, 25 days following the appearance of exudate. The patient was given penicillin and streptomycin at that time, in doses of 600,000 units twice a day and 0.5 Gm. twice daily, respectively. Local treatment of daily soaks with sterile saline and hydrogen peroxide flushing failed to induce healing. More

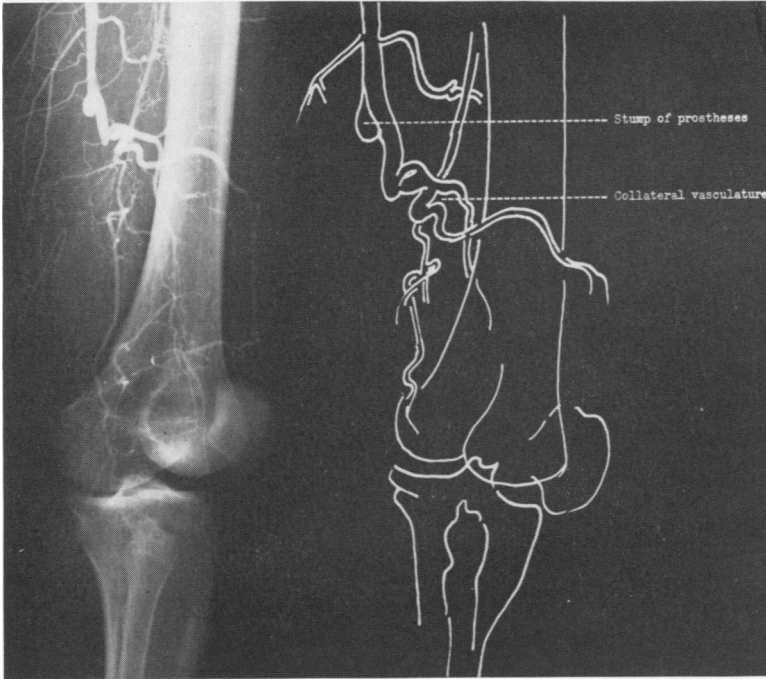


FIG. 2. Arteriogram depicting collateral vasculature and proximal patent prosthetic stump (Case 6).

aggressively the wound was debrided under local anesthesia. The wound edges were excised down to uninvolved subcutaneous tissue and local debris was cleaned out by alternate curetting and sharp dissection. The graft was not disturbed and could be seen lying free in the bottom of the wound. A polyethylene catheter was placed as described in Case 1 and the wound was closed. The pathologic report of material from the infected wound and around the graft was "active chronic and acute purulent inflammation of skin with ulceration and pyogenic granulation tissue." Chloramphenicol, 250 mg. in solution, was instilled into the catheter twice a day for three days. The wound healed in two weeks without evidence of residual infection. He died three months later of causes unrelated to his vascular disease. The graft was patent at death and there was sound healing in the left femoral incision.

**Case 6.** G. Y., a 34-year-old man, was admitted to Walter Reed General Hospital on 31 January 1961 with a draining sinus in an incision on the medial aspect of the left thigh. While serving in Korea, he developed intermittent claudication of the left hip and calf approximately seven months prior to this admission. A left femoral arteriogram had revealed a sharp interruption in continuity of the femoral artery 14 cm. above the knee. At operation on 26 September 1960 at a U. S. Army

Hospital in Korea an organizing thrombus occluding the distal femoral artery was found. Thrombectomy was performed and a Dacron bypass graft was inserted from the femoral to the popliteal artery. The wound was drained. Postoperatively, the patient developed thrombophlebitis of the deep veins of the calf, and a hematoma of the operative area of the thigh. The hematoma was evacuated but a draining sinus tract persisted and was present on admission to Walter Reed General Hospital. Culture of the drainage from this sinus grew *Micrococcus tetragenus*. A small catheter was inserted into the sinus tract which was irrigated with a solution containing 1.0 per cent neomycin with bacitracin in a concentration of 500 units per cc. three times per day. Femoral arteriography showed a block of the superficial femoral artery with extensive collaterals and reconstitution of the posterior tibial and peroneal arteries without demonstration of the popliteal artery (Fig. 2). A small proximal stump of graft was visualized. Drainage persisted from the sinus despite irrigations. At operation the graft was thrombosed and free of attachment distally in the region of the popliteal artery. A tract exuding purulent material in the distal portion of the wound led to a retained gauze sponge. The proximal attachment of the graft was intact and because collateral vessels had been shown on the arteriogram to arise adjacent to the anastomosis, the graft was not separated from its

femoral attachment but was transected just below the anastomosis and closed. It was handled in this manner so as not to impinge upon the orifices of the main collateral channels. (Pace, Craig, and Watman reported a case of aneurysm formation following removal of an infected graft without closure of an open end of the artery.<sup>6</sup>) Following irrigation of the wound, a polyethylene catheter was inserted as described in the preceding cases and the fascia and subcutaneous tissue were closed loosely over the catheter. The skin was left open for secondary closure. Antibiotic irrigations were continued and the patient received chloramphenicol and erythromycin. Secondary closure was accomplished three weeks following the removal of the thrombosed graft and the wound healed without residual infection. Healing occurred despite the small proximal stump of Dacron graft which was purposely left *in situ*. At follow up in August 1962 the thigh wound was healed. Further reconstructive arterial surgery has been attempted but there was no run-off below the knee and no attempt at bypass was made.

**Case 7.** M. B., a 53-year-old man, was admitted to Walter Reed General Hospital in June 1961. Two weeks prior to admission he had colicky mid-abdominal and epigastric pain following his noon meal. Associated with this pain was low grade fever. The pain persisted to the following day with onset of general malaise. The patient was hospitalized at another installation where extensive examination, including proctoscopy and gastroscopy, showed no significant abnormalities. On upper gastro-intestinal x-ray series, there was

a suggestion of a pancreatic mass impinging on the duodenum. During hospitalization, there was a daily temperature rise to 38.8° C. Blood, sputum, and urine cultures were consistently negative. He was transferred to Walter Reed General Hospital where slightly tender fullness in the left lower quadrant and mid-abdomen was found. It was believed this was either an abdominal aortic aneurysm or a pancreatic tumor. At operation a false aneurysm of the abdominal aorta with evidence of recent leakage was disclosed. The aneurysm was resected and replaced by a tube Dacron graft. Cultures of the aneurysm grew *Salmonella choleraesuis* var. *Kunzendorf* and later agglutination tests showed high titers to *Salmonella choleraesuis* (1:640). The patient was given chloramphenicol 2.0 Gm. daily for two weeks, then tetracycline 2.0 Gm. daily for three weeks. Blood and stool cultures remained sterile. The wounds healed *per primam*, and the graft has continued to function satisfactorily. One year later at the time of cholecystectomy, the wound about the graft was found healed.

**Comment.** In this case, although there was no frank pus around the rupture due to invasive *Salmonella choleraesuis*, positive cultures were obtained from the area in which a large Dacron graft was placed. Knowledge of the offending organism and prompt specific antibiotic therapy based on sensitivity studies brought about a successful result. This case has previously been re-

TABLE 1

Case	Organism	Systemic Antibiotic	No. Days Treated	Topical Antibiotic	No. Days Treated
1. J. N.	<i>Micrococcus tetragenus</i>	Erythromycin 0.5 Gm. qid streptomycin 0.5 Gm. qid	10	2.5 cc. of 1% neomycin with bacitracin 1,000 u/cc. of solution.	
2. L. H.	<i>Streptococcus</i>	Chloramphenicol 0.5 Gm. qid	19	1% solution of chloramphenicol—bid irrigations.	3
3. J. A.	Hemolytic <i>Staphylococcus aureus</i> , <i>Aerobacter aerogenes</i>	Chloramphenicol 0.5 Gm. qid	10	1% solution of chloramphenicol—qid irrigations.	6
4. A. K.	<i>Streptococcus fecalis</i> , <i>Paracolon</i> species, <i>Proteus vulgaris</i>	Penicillin 600,000 u bid. Chloramphenicol 0.5 Gm. qid Erythromycin 0.5 Gm. qid Tetracycline 0.5 Gm. qid	14 5 14 14	Chloramphenicol 500 mg. in sterile saline bid.	4
5. A. P.	Unknown	Penicillin 600,000 u bid Streptomycin 0.5 Gm. bid	24	Chloramphenicol 250 mg. in sterile saline solution bid.	3
6. G. Y.	<i>Micrococcus tetragenus</i>	Chloramphenicol 0.5 Gm. qid Erythromycin 0.5 Gm. qid	28	1% solution of neomycin with bacitracin 500 u/cc. of solution.	40
7. M. B.	<i>Salmonella choleraesuis</i>	Chloramphenicol 0.5-0.75 Gm qid Tetracycline 0.5 Gm. qid	14 21	— —	— —

ported and found to be the first successfully treated ruptured aorta due to a *Salmonella* suppurative aortitis.<sup>10</sup>

### Discussion

This paper is concerned with a limited experience with infections in association with synthetic fabric prostheses and the management of these infections. As was pointed, it has been contended that deep infection in association with synthetic fabric prostheses usually requires removal of the prosthesis to effect healing. This did not prove to be true in the cases cited. It was possible, by aggressive local wound care, wound debridement, topical antibiotics, delayed skin closure, and appropriate, adequate, systemic, antibiotics to bring about healing of infected wounds containing Dacron grafts.

Pulaski<sup>7</sup> observed, "The chief aim of topical therapy is to obtain a persistent effect with repeated but widely spaced applications. One achieves this only by providing adequate contact between appropriate drug and microbe, as well as optimal conditions for wound repair." It was his belief that "topical therapy could succeed only in superficial lesions in which the drug could flood and penetrate the whole area. This is accomplished by incision and drainage and debridement to achieve adequate exposure and removal of all nonviable tissues."

One finds experimental refutation of the need to remove prostheses in infected sites in the work of Foster and associates.<sup>2, 3</sup> In their experiment, grafts were implanted in dogs in the presence of deliberately induced infection. Those animals protected with antibiotics pre- and postgrafting did best in terms of healing and survival as opposed to control groups which received no antibiotics and succumbed in a period of four to five days of peritonitis and hemorrhage from disruption of the suture line. Three- to five-year follow up on animals in which control of infection was achieved

revealed good function of the graft without evidence of residual infection on sacrifice of the animals. Harrison noted similar results in the same kind of experiment.<sup>5</sup> Hardy *et al.*<sup>4</sup> concluded on the basis of experimental data that "the use of Dacron grafts in contaminated wounds may be acceptable if thorough and active debridement of infection is done."

Prevention of infection in noncontaminated cases in which fabric prostheses are implanted is of the utmost importance. Toward this end, pHisoHex baths three times daily for four to five days prior to operation, meticulous surgical technic, avoidance of drains to the graft, prompt evacuation of hematomas and prophylactic antibiotics are all important. Schramel and Creech<sup>8</sup> and Crawford, DeBakey and Cooley<sup>1</sup> reported primary healing of wounds containing infected synthetic fabric prostheses utilizing essentially the same measures here outlined.

Although it was possible to effect wound healing in the cases presented it is to be emphasized that an acute suppurative arterial process is exceedingly serious and is, in most cases, attended by catastrophic consequences from either hemorrhage, disruption or thrombosis of the graft or adjacent vessels. Grafts have been found lying free in a pool of pus in the process of being extruded by the body as with most foreign bodies. The importance of our experience, along with that of Schramel and Creech, is that the disastrous consequences secondary to infected grafts may be prevented with early and aggressive therapy.

### Summary

Seven cases of infection associated with arterial fabric prostheses are presented.

Healing of wounds containing synthetic prostheses with established infections was effected by local vigorous wound care, topical antibiotics instilled by means of a polyethylene catheter, delayed wound closure

and the appropriate systemic antibiotic therapy.

### Addendum

Since submission of this paper for publication, Case 7 (M. B.) has been rehospitalized on two occasions for treatment of further infections about his graft. Nineteen months following hospital discharge, he presented with an aorto-duodenal fistula involving the proximal suture line of the graft. The old graft was excised along with the fistula and a new sleeve graft was inserted. Three months later he presented with an aorto-ileal fistula involving the distal suture line with an associated false aneurysm. The second graft was excised and a third Dacron graft, bifurcation type, was inserted from a site on the aorta proximal to the old graft and anastomosed to the external iliacs distally. This graft was placed posterior to the left colon mesentery thus avoiding placement in the original infected aortic bed. *Klebsiella-Aerobacter* was cultured from the clot surrounding the aneurysm. A successful result was achieved and the patient has experienced no further difficulty during a three-month observation period. This patient is 25 months from his original aortic surgery and has required three aortic grafts.

### Bibliography

1. Crawford, E. S., M. E. DeBakey and D. A. Cooley: Surgical Considerations of Peripheral Arterial Aneurysms. Analysis of One Hundred Seven Cases. *Arch. Surg.*, **78**:226, 1959.
2. Foster, J. H., T. Berzins and H. W. Scott, Jr.: An Experimental Study of Arterial Replacement in the Presence of Bacterial Infection. *Surg., Gynec. & Obst.*, **108**:141, 1959.
3. Foster, J. H., C.-A. Ekman and W. H. Scott, Jr.: Late Behavior of Vascular Substitutes. Three to Five Year Follow Up of Arterial Homografts and Synthetic Prostheses in Experimental Animals. *Ann. Surg.*, **151**:867, 1960.
4. Hardy, R. W., L. A. Perales, G. A. Boughton, E. F. Geever, R. T. Sherman and W. H. Moncrief: The Effect of Whole-Body Radiation and Infection on Arterial Replacement. *Ann. Surg.*, **151**:359, 1960.
5. Harrison, J. H.: Influence of Infection on Homografts and Synthetic (Teflon) Grafts. A Comparative Study in Experimental Animals. *Arch. Surg.*, **76**:67, 1958.
6. Pace, W. G., T. V. Craig and R. N. Watman: Formation of Pseudoaneurysm. Occurrence after Removal of Synthetic Arterial Prosthesis. *Am. J. Surg.*, **101**:373, 1961.
7. Pulaski, E. J.: Current Concepts in Therapy. Topical Antimicrobial Therapy. *New Engl. J. Med.*, **261**:555, 1959.
8. Schramel, R. J. and O. Creech, Jr.: Effects of Infection and Exposure on Synthetic Arterial Prostheses. *Arch. Surg.*, **78**:271, 1959.
9. Smith, R. F. and D. E. Szilagyi: Healing Complications with Plastic Arterial Implants. *Arch. Surg.*, **82**:14, 1962.
10. Sower, N. and T. J. Whelan: Acute Suppurative Arteritis due to *Salmonellae*. *Surgery*, **52**:851, 1962.