

# Insulin Secreting Tumors of the Pancreas \*

ERIC W. FONKALSRUD, M.D., RALPH B. DILLEY, M.D., WILLIAM P. LONGMIRE, JR., M.D.

*From the Department of Surgery, UCLA Center for the Health Sciences, Los Angeles 24, California*

ALTHOUGH a pancreatic islet cell tumor was first described by Nicholls,<sup>9</sup> in 1902, it was not until the discovery of insulin by Banting and Best,<sup>1</sup> in 1922, and the subsequent concept of hyperinsulinism by Harris,<sup>6</sup> in 1924, that Wilder and associates,<sup>13</sup> in 1927, were able to establish at operation a correlation between endogenous hyperinsulinism and an islet cell carcinoma with metastases. Graham,<sup>5</sup> in 1929, achieved the first recorded cure of organic hyperinsulinism by removing an islet cell adenoma. Since these early reports the number of recognized cases of organic hyperinsulinism has increased rapidly. In a review of the world literature in 1950, Howard, Moss, and Rhoads<sup>7</sup> collected 222 case histories of islet cell tumors associated with hyperinsulinism. In a more recent report, Moss and Rhoads<sup>8</sup> recorded a total of 549 case histories of functioning islet cell tumors collected from the literature prior to January 1958. Only 56 of the functioning tumors were found to be malignant.

The present report is a review of ten cases of insulin secreting islet cell tumors of the pancreas operated upon at the University of California Medical Center at Los Angeles. The following patients included in this group have presented interesting and unusual therapeutic problems and results:

---

\* Presented before the Southern Surgical Association, Hot Springs, Virginia, December 10-12, 1963.

Work supported in part by the scholar program of the John and Mary R. Markle Foundation.

A patient with functioning malignant islet cell carcinoma and metastases in whom the hypoglycemic symptoms currently have been relieved by the administration of cortisone, glucagon, and nitrogen mustard.

A 13-month-old hypoglycemic infant with hyperplasia and hypertrophy of the islet cells whose blood sugar levels have returned to normal following the resection of the body and tail of the pancreas.

Three patients in whom a small tumor was finally found buried within the head of the gland. A second stage total pancreatectomy was required in two of these patients to excise the functioning islet cell adenoma. These experiences have led us to question the advisability of performing a *blind* distal pancreatectomy, as has been generally recommended, in adults in whom an insulin secreting pancreatic adenoma is strongly suspected but cannot be located at operation.

## Physiology and Pathology

The symptoms characteristic of endogenous hyperinsulinism are a result of the hypoglycemia that results from the excessive secretion of insulin by the tumor. When the glycemic level falls sufficiently below the critical point to permit normal metabolism of the brain, a burst of nervous activity or convulsion may ensue, followed by a marked depression of the brain or coma. Permanent cerebral damage or even death may occur if frequent severe attacks of hyperinsulinism are allowed to recur untreated. The brain has a limited capacity to store glycogen and when subjected to an acute reduction in circulatory glucose, anoxia of the tissues occurs. The adverse effects of the hypoglycemia upon the central nervous system make it imperative to establish the diagnosis early and to treat

the condition expeditiously by appropriate surgical means.

The insulin secretory response of functioning islet cell tumors is not controlled by normal physiologic mechanisms, and it varies in response to unknown stimuli. The mechanism for spontaneous reversal of the hypoglycemic attack is thought to be the release of epinephrine, which then liberates glucose from areas of glycogen storage. If a hypoglycemic attack is severe and continues untreated, spontaneous recovery may not ensue and the changes in the central nervous system may become irreversible. Repeated episodes of hypoglycemia may result in a variety of nervous system symptoms from mild to severe personality changes to paralysis, epilepsy, speech disturbances, and peripheral neuromuscular atrophy.

Most of these patients develop severe hunger during the early phases of an attack, and they learn that eating will usually prevent the advanced symptoms. Consequently many patients gain weight and are obese when initially examined.

Insulin secreting islet cell tumors may be classified as, 1) benign islet cell adenomas; 2) suspiciously malignant tumors; 3) islet cell carcinoma; and 4) diffuse hyperplasia of the islet cells without localized tumor. Benign islet cell adenomas occur most frequently in patients in the fourth, fifth, and sixth decades of life and are slightly more common in women than in men. The adenoma usually is 1 to 3 cm. in diameter and reddish brown in color. A very thin capsule is present and the consistency is usually the same as the adjacent normal pancreatic tissue so that in many instances its location is concealed from the surgeon. The frequency of occurrence of adenoma in the tail, body, and head of the gland is about the same, proportional to their share of the pancreatic tissue. Fifteen cases of ectopic islet cell tumors have been reported, the most common sites being near the duodenum, in the

gastrosplenic omentum, and in the retroperitoneal area. Approximately 14 per cent of patients with islet cell tumors have multiple lesions. Microscopically the morphology of the cells within the adenoma is similar to the cells in normal islands of Langerhans, although there is usually compression of the adjacent pancreatic tissue.

An occasional tumor is classified histologically as a suspiciously malignant islet cell adenoma. The preponderance of such tumors have not recurred after initial removal; however, in some instances regional and hepatic metastases have appeared at a later date.

Functioning islet cell carcinomas usually grow rapidly, and death ensues one to two years after the diagnosis has been established. Only 56 cases of carcinoma have been reported.<sup>8</sup> Metastases usually occur in the regional lymph nodes and the liver. In addition to the functioning carcinoma within the pancreas, the metastatic lesions may secrete insulin. Even following removal of the primary tumor, the metastases may continue to function and maintain the hypoglycemic state.

Although functioning islet cell tumors are rarely encountered in children, hyperinsulinism is occasionally found with hyperplasia of the islet cells in this age group, and it is almost never seen in adults.<sup>10</sup> There are hyperplastic or hypertrophic cells within the islands of Langerhans scattered throughout the pancreas in these cases. Return to a normal glyceic state usually occurs after removing approximately 75 per cent of the gland.

#### Clinical Evaluation of Hypoglycemia

The results from the surgical treatment of hyperinsulinism are directly proportional to the accuracy of the clinical diagnosis. Adherence to the diagnostic criteria outlined by Whipple<sup>12</sup> is most helpful in selecting the appropriate surgical candidate: 1) spontaneous hypoglycemia accompanied

by central nervous system or vasomotor system symptoms; 2) repeated fasting blood sugar determinations below 50 mg.% and 3) relief of symptoms by the oral or intravenous administration of glucose.

The etiology of hypoglycemia encompasses a wide range of medical and surgical disorders which have been enumerated by Freark and DePeyster.<sup>4</sup> Routine laboratory tests and careful history and physical examination will successfully exclude a number of diagnostic considerations in adults. The most valuable laboratory aid is to repeat frequently determinations of the blood sugar level after various periods of fasting or vigorous exercise. The most reliable specific diagnostic aid for the detection of insulin secreting tumors is the tolbutamide tolerance test proposed by Fajans and Conn.<sup>2</sup> An additional laboratory aid is the blood sugar response to the oral administration of the levo isomer of the amino acid leucine.<sup>3</sup> The mechanism of action of both of these drugs is believed to be as a stimulus to the increased elaboration of insulin by the tumor cells. Other diagnostic studies of possible value in the diagnosis of hypoglycemia include the glucose tolerance, insulin sensitivity, epinephrine, glucagon, and other tests. It is important not to delay surgical exploration when adequate criteria for the diagnosis are present.

### Clinical Experience

During the past eight years, ten patients have been explored for hypoglycemia at the University of California Medical Center at Los Angeles (Table 1). A single adenoma was found in seven patients, and from another patient, two separate adenomas were removed. In four of these eight patients, the tumors were found in the head of the gland. Although there was no definite age predilection, the majority of patients were in the young to middle-age range, with males and females being equally affected. All the patients had had

recurrent symptomatic episodes of hypoglycemia and met the criteria of Whipple's triad. Gastro-intestinal roentgenograms were helpful by excluding the presence of other intestinal pathologic conditions. No patients in this series had evidence of peptic ulcer disease. One patient was found to have an insulin secreting metastatic carcinoma of the pancreas (Case 2). An infant with severe hypoglycemia had hyperplasia and hypertrophy of the islet cells (Case 1). There were no deaths in this series of cases, either at operation, shortly after, or in the later follow up period, although a few complications were encountered.

In the present series, the adenomas of the body and tail of the gland were quite easily found, whereas detection of tumors in the head and uncinata process was much more difficult. The histologic appearance of each adenoma was that of a benign tumor well confined within a thin capsule. In two patients a *blind* resection of the body and tail of the gland was performed after a painstaking examination of the pancreas and possible ectopic sites did not disclose an adenoma. Both patients continued to have severe hypoglycemia and each underwent resection of the remaining pancreas at a later date with subsequent relief of symptoms. An adenoma was found in the head of each of these glands; however, both patients are now diabetic and have symptoms of pancreatic insufficiency. One of these patients had a subphrenic abscess and draining enteric fistula following the second operative procedure. In a third case, detailed below, a small adenoma which was completely buried in the head of the gland was located with considerable difficulty.

The blood sugar values in most patients rapidly became elevated to levels of 200 to 300 mg.% following operation and then gradually returned to normal values three to five days later. This temporary diabetic state is a rebound phenomenon due to suppression of normal islet cells by prolonged

TABLE 1. *Exploratory Operations for Insulin Secreting Tumors*

Patient	Age Sex	Duration	Symptoms		Whipple's Triad	Lowest Blood Sugar (mg.%)	Location	Treatment	Type	Result	Last Blood Sugar (mg.%)	Follow up
			Character	Character								
E. A.	51WF	1½ yr.	Dizziness, blackouts, coma, diplopia		+	42	(1) Tail (2) Body	(1) Enucleation (2) Enucleation	(1) 0.5 cm adenoma	Excellent	85	7½ yr.
J. B.	36WM	2 yr.	Stupor, coma, athetoid movements, diplopia		+	37	Head	Blind resection of body and tail	No tumor found	Persistent hypoglycemia	300	4½ yr.
A. J.	66WM	5 mo.	Second operation 13 months later		+	38	Head	Pancreatico duodenectomy (total pancreatectomy)	1.3 cm adenoma	Recurrent diabetic acidosis; pancreatic insufficiency	95	6 yr.
A. J.	66WM	5 mo.	Convulsions, unconscious episodes		+	38	Tail	Resection of tail of pancreas	1.1 cm adenoma	Excellent	95	6 yr.
S. C.	46WF	7 mo.	Blackouts, coma		+	19	Head	Blind resection of body and tail	No tumor found	Persistent hypoglycemia	150	5 yr.
D. W.	44WF	2 yr.	Second operation 2 months later		+	21	Head	Pancreatico duodenectomy (total pancreatectomy)	1.3 cm adenoma	Recurrent diabetic acidosis; pancreatic insufficiency	75	4½ yr.
D. W.	44WF	2 yr.	Epilepsy, unconscious episodes, confusion		+	21	Tail	Enucleation	1.3 cm adenoma	Excellent	75	4½ yr.
N. N.	17WF	10 yr.	Blackouts, unconsciousness, convulsions, psychiatric disturbances		+	24	Tail	Enucleation	1.8 cm adenoma	Good; continue personality disturbances	80	2 yr.
W. S.	31WM	5 mo.	Convulsions, blackouts, headaches, bizarre behavior		+	32	Head	Enucleation	1.2 cm adenoma	Excellent	76	1 yr.
J. B.	54WM	2½ yr.	Convulsions, unconsciousness, memory loss		+	40	Head	Enucleation	1.5 cm adenoma	Excellent	94	4 mo.
F. N.	65WF	1 yr.	Unconsciousness, irritability, forgetfulness		+	30	Body and head	Biopsy mesenteric lymph node and liver nodule	Islet cell carcinoma	Improved with cortisone, glucagon and nitrogen mustard	70	4 mo.
L. V.	13WF	9 mo.	Convulsions, unconsciousness		+	19	Entire pancreas	Resection of body and tail, (75% pancreatectomy)	Diffuse islet cell hyperplasia	Excellent	75	3 mo.

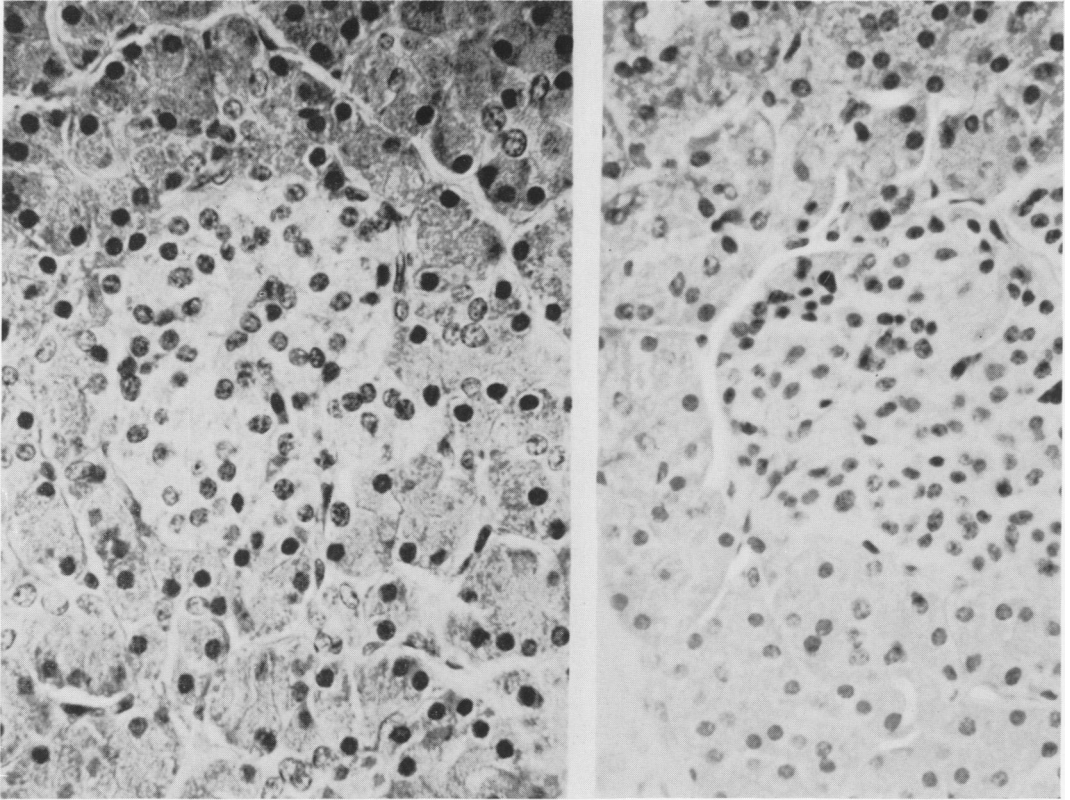


FIG. 1. Normal islet of Langerhans (right). Section of islet of Langerhans from patient with hypertrophy of islet cells (Case 1). Note enlarged nuclei (left).

hyperinsulinism. The maintenance of relatively normal blood sugar levels in most instances well into the late follow-up period is very gratifying.

**Case 1.** Repeated episodes of coma and generalized body seizures since the age of four months led to the diagnosis of hypoglycemia in L. V., a 13-month-old Caucasian female infant. There was no evidence of intracranial tumor or congenital anomaly. Physical examination revealed a slightly obese, normal appearing infant. A blood sugar of 19 mg.% was recorded and the criteria for Whipple's triad were met. The tolbutamide tolerance test was characteristic of an islet cell tumor. At surgical exploration the pancreas was diffusely enlarged and firm with no localized nodules in any area. There was no evidence of ectopic pancreatic tissue. A 75 per cent resection was performed; the body and tail of the gland were removed but the spleen was preserved. Following initially elevated determinations of blood sugar in the first three postoperative days, normal gly-

cemic values have been found consistently. At histologic examination, hypertrophy and hyperplasia of the islet cells in each of the islands of Langerhans were found (Fig. 1). The infant has had no episodes of coma or convulsion during the three months since operation.

**Case 2.** F. N., a 65-year-old Caucasian woman was admitted to the University of California Medical Center at Los Angeles with an eight-month history of recurrent episodes of unconsciousness. One year prior to admission, she began to experience mild lightheadedness when standing up suddenly or walking quickly. She subsequently experienced frequent episodes of coma with exercise. The periods of unconsciousness first occurred in the nocturnal hours and later a few hours postprandially, and they would last from 30 minutes to two hours. She found that she could abort these episodes by drinking orange juice and eventually found it necessary to set her alarm clock to awaken her every two hours during the night in order to take orange juice. A blood sugar taken

during one of her weak spells was 30 mg.% and accordingly she was admitted to the hospital.

On physical examination, the patient was found to be a well developed, obese, elderly Caucasian woman who appeared bright and alert. No scleral icterus was present. There was no significant lymphadenopathy. The liver was palpable at the right costal margin. There was no abdominal tenderness or palpable masses. Deep tendon reflexes were diminished. The result of physical examination were otherwise unremarkable.

A repeat blood sugar of 30 mg.% was recorded in the hospital during an episode of somnolence. On the basis of the history and spontaneous hypoglycemia relieved by glucose, the tentative diagnosis of an insulin secreting tumor was made. Prior to operation she was given a high calorie diet with hourly feedings. During the night, an intravenous infusion of 10 per cent dextrose solution was administered. On March 20, 1963 an exploratory laparotomy was performed, and a large mass was found in the head and body of the pancreas. Metastatic lymph nodes were pres-

ent in the gastrocolic, gastrohepatic, and hepato-duodenal ligaments as well as in the retroperitoneal area. The liver contained numerous 1 to 3 cm. discrete firm metastatic nodules throughout its parenchyma. Histologically the lymph node and liver biopsies were compatible with islet cell carcinoma of the pancreas (Fig. 2). There was no intestinal obstruction and in view of the widespread disease it was believed that resection should not be undertaken.

Postoperatively she was given an intravenous infusion of 10 per cent dextrose solution and later a continual drip of a blended 3,300 calorie diet through a nasogastric feeding tube. She was given prednisone 40 mg./day with a subsequent consistent elevation in blood sugar levels. A trial dose of glucagon hydrochloride 1 mg. subcutaneously produced a marked elevation in blood sugar levels and accordingly she was given glucagon in gel suspension, 2 mg./day. Two and one-half weeks following operation she was given a total of 30 mg. of nitrogen mustard over a two-day period. She was discharged from the hospital four weeks

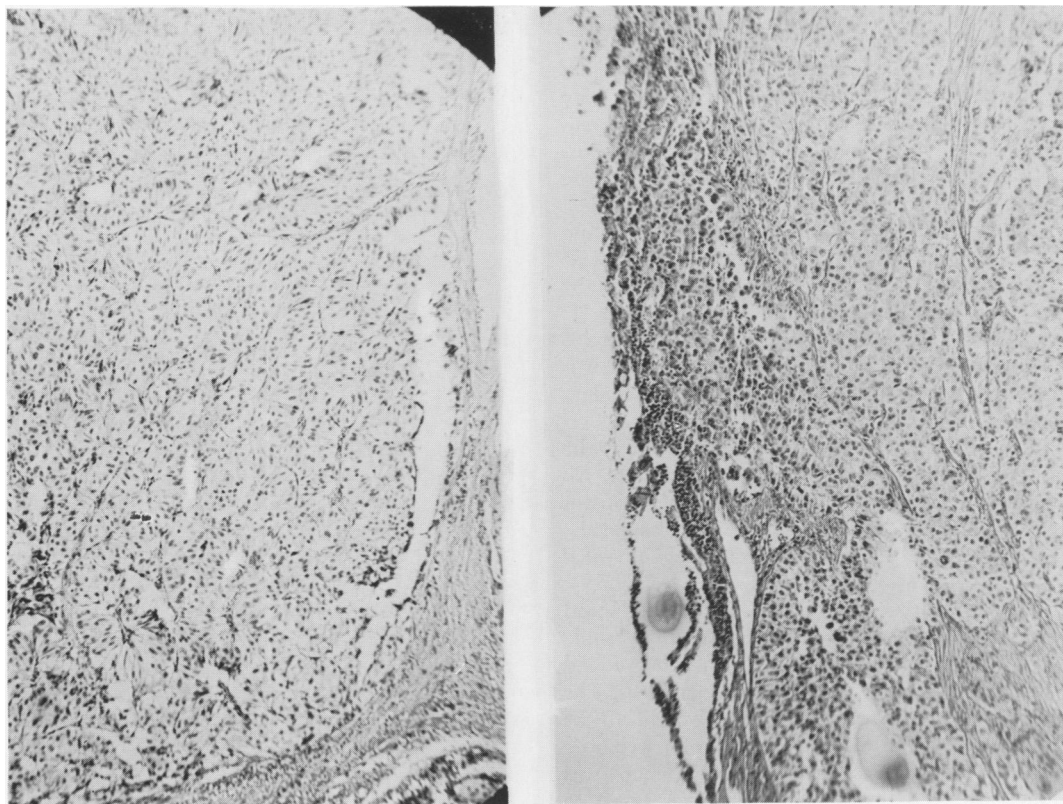


FIG. 2. Benign islet cell adenoma from Case 3 (left). Section from gastrohepatic lymph node showing metastatic islet cell carcinoma from Case 2 (right).

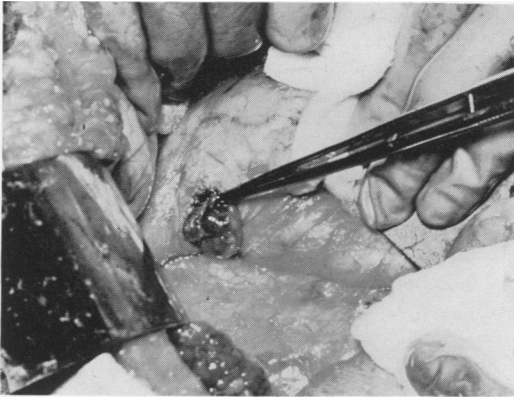

FIG. 3. Removal of islet cell adenoma from uncinate process of pancreas with duodenum reflected upward (Case 3).

postoperatively asymptomatic on a 3,300 calorie diet with frequent feedings and glucagon as above, as well as prednisone 20 mg./day.

The patient has been asymptomatic with an increase in strength and alertness since discharge from the hospital.

**Case 3.** J. B. is a 54-year-old Caucasian man who experienced increasingly frequent episodes of lightheadedness, memory loss, and weakness over a 2½-year period. His symptoms were most prominent in the very early and late morning hours and were accompanied by diaphoresis and bizarre behavioral changes. He later developed transient episodes of unconsciousness from which he could not be aroused. Early in the course of his disease he found that the episodes could be avoided by ingestion of orange juice and various foods. He was found to have a blood sugar level of 45 mg.% during one of his somnolent periods and was subsequently admitted to the hospital for evaluation.

At physical examination he was found to be husky, healthy appearing, and mentally alert. No lymphadenopathy was detected. The abdomen was free of masses, tenderness, and organomegaly. The neurological examination was within normal limits.

While he was in the hospital, a fasting blood sugar of 40 mg.% was obtained. The tolbutamide tolerance test was characteristic of that found with insulin secreting tumors of the pancreas. The bizarre personality changes were thought to be a result of organic disease and not of psychiatric disturbance. An insulin secreting tumor was strongly suspected and the patient was taken to the operating room on March 13, 1963. The entire body and tail of the pancreas were carefully

mobilized, palpated, and inspected, but no tumor could be identified. A localized firm area in the head of the gland was excised as a wedge biopsy, however, histological examination revealed normal pancreas. After further prolonged inspection and examination of the head and uncinate process, an incision was made over the uncinate process with the duodenum retracted medially. Approximately 3 mm. beneath the surface of the gland, a soft, violet colored, glutinous lump, 2 cm. in diameter, was encountered and enucleated (Fig. 3). Histologically this tumor had the appearance of an islet cell adenoma (Fig. 2). No other tumors were found.

The patient's blood sugar level became elevated to 172 mg.% during the first two postoperative days but remained steady at 97 mg.% one week after operation. The patient's convalescence was uneventful and he was discharged eight days following operation tolerating a regular diet well. He has remained asymptomatic with normal blood sugar values for four months after operation.

### Discussion

At surgical exploration a very thorough inspection and mobilization of the pancreas and adjacent tissues is essential. The entire gland should be carefully palpated between two fingers and examined on both anterior and posterior surfaces (Fig. 4, 5), even after one adenoma is found, for multi-

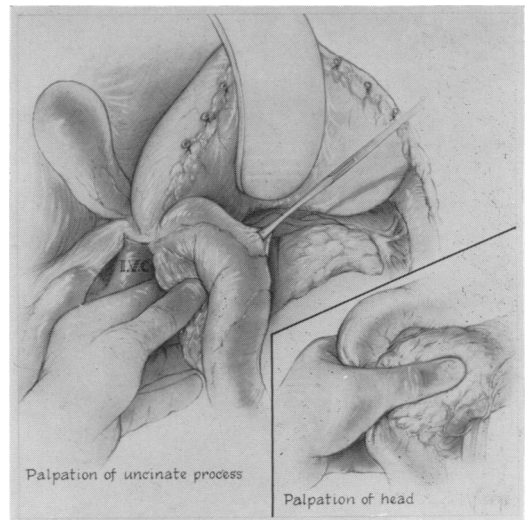


FIG. 4. Technic of inspection and palpation of body and tail of pancreas. Gastrocolic ligament has been opened widely.

ple tumors have been found in 14 per cent of cases.<sup>8</sup> Since the adenoma is usually of the same consistency as the adjacent pancreatic tissue and may be surrounded by normal gland on all sides, identification of the tumor may be quite difficult. The head and uncinate process of the pancreas are the most difficult areas to evaluate because of the increased bulk and thickness compared to the body and tail which can be readily palpated and inspected.

When no adenoma is found after a thorough search, it has been advised to perform a *blind* distal pancreatectomy to remove the body and tail of the gland.<sup>8</sup> However, from our experience it appears that the head of the gland is most apt to be the site of an occult tumor, and, therefore, a pancreaticoduodenectomy should be considered if the adenoma can not be located and the surgeon is convinced of its presence. Diffuse hyperplasia of the islet cells is rarely found in adults and 75 per cent pancreatectomy is not as likely to alleviate hypoglycemia as in infants. When the adenoma is not found in the specimen from the blind distal pancreatectomy, and hypoglycemia persists, the subsequent operation is technically difficult, is prone to postoperative drainage and infection, and leaves the patient with the hormone and enzyme deficiencies that ensue after total pancreatectomy. It would not be as difficult to resect the body and tail of the gland if the adenoma had not been removed by a previous "blind" pancreaticoduodenal resection. Moss and Rhoads<sup>8</sup> report a 33 per cent mortality rate associated with secondary total pancreatic resection for persistent hyperinsulinism following initial subtotal excision of the body and tail of the gland.

Islet cell tumors are uncommon in infants and children with spontaneous symptomatic hypoglycemia. Thompson and Welch<sup>10</sup> in a review of the literature up to 1960 report 39 patients with islet cell tumors up to the age of 15 years. Twenty-one had benign adenomas where nine had

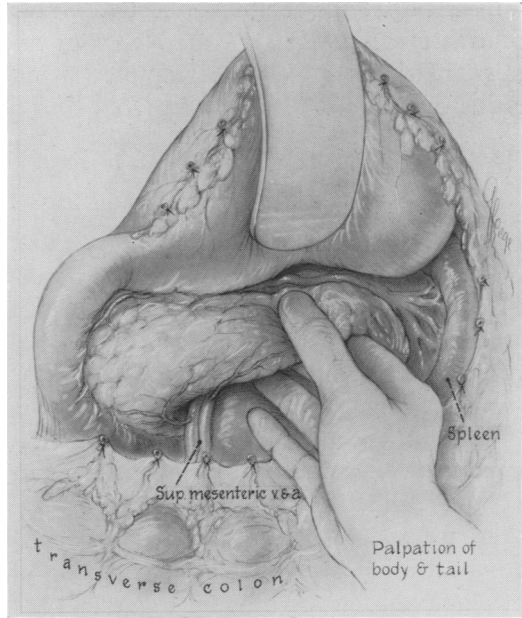


FIG. 5. Palpation of uncinate process of pancreas. Duodenum has been reflected anteriorly. Inset: Technic of careful palpation of head of pancreas.

vague cellular abnormalities and showed tumorlike areas of islet cell hyperplasia and hypertrophy. Distal pancreatectomy in which approximately 75 per cent of the gland was removed has been successful in alleviating hypoglycemic symptoms in most infants, as in Case 1, when diffuse islet cell hyperplasia is present.

Between 10 and 12 per cent of hyperfunctioning islet cell tumors are malignant and evidence of metastases is found at the time of operation or necropsy.<sup>11</sup> The lapse of time from the onset of symptoms to death is usually less than one year, although isolated case of long survival with demonstrable metastases have been reported. Metastatic tumors are frequently locally invasive, cellular, vascular, and insulin secreting. Alloxan may show preference for the remaining normal beta cells in the pancreas rather than for the functioning tumor cells and thus be therapeutically ineffectual. Steroids, glucagon, and nitrogen mustards used on conjunction



appear to provide the most effective means of treatment presently available, with remission of hypoglycemic symptoms being rather dramatic as in Case 2 reported above.

### Summary

A review of ten cases of insulin secreting islet cell tumors of the pancreas operated upon at the University of California Medical Center, at Los Angeles, has been presented. Several patients in this group have presented interesting and unusual therapeutic problems.

One patient with a functioning malignant islet cell carcinoma and metastases has obtained relief from hypoglycemic symptoms for over three months following the administration of cortisone, glucagon and nitrogen mustard. Only 56 cases of this malignant tumor have been reported and this is the first patient to receive the described therapeutic regimen.

The blood sugar values of a hypoglycemic infant with hyperplasia and hypertrophy of the islet cells returned to normal following resection of the body and tail of the pancreas. Eleven cases of islet cell hyperplasia have been reported and only eight successfully treated by pancreatic resection.

In three patients a functioning pancreatic adenoma was finally found buried within the head of the gland. Two of these patients required a second stage total pancreatectomy to excise the tumor. These experiences have led us to question the advisability of performing a *blind* distal pancreatectomy as has been generally recommended in adults in whom an insulin secreting adenoma is strongly suspected but cannot be located at operation.

### DISCUSSION

DR. H. WILLIAM SCOTT, JR. (Nashville): I want to bring out a point of interest about the incidence of islet adenoma in adults versus chil-

### References

1. Banting, F. G. and C. H. Best: The Internal Secretion of the Pancreas. *J. Lab. & Clin. Med.*, 7:251, 1922.
2. Fajans, S. S. and J. W. Conn: Intravenous Tolbutamide Test. *J. Lab. & Clin. Med.*, 54:811, 1959.
3. Flanagan, G. C., T. B. Schwartz and W. G. Ryan: Studies on Patients with Islet Cell Tumors, Including the Phenomenon of Leucine Induced Accentuation of Hypoglycemia. *J. Clin. Endocrinol.*, 21:401, 1961.
4. Freemark, R. J. and F. A. DePeyster: Progress in the Diagnosis and Surgical Treatment of Insulin Secreting Tumors of the Pancreas. *Surg. Clinics N. America*, 43:79, 1963.
5. Graham, R. R. Quoted by Howland, G., W. R. Campbell, E. J. Maltby and W. L. Robinson: Dysinsulinism. *J.A.M.A.*, 93:674, 1929.
6. Harris, S.: Hyperinsulinism and Dysinsulinism. *J.A.M.A.*, 83:729, 1924.
7. Howard, J. M., N. H. Moss and J. E. Rhoads: Hyperinsulinism and Islet Cell Tumors of the Pancreas. *Internat. Abstr. Surg.*, 90:417, 1950.
8. Moss, N. H. and J. E. Rhoads: Hyperinsulinism and Islet Cell Tumors of the Pancreas. In Howard, J. M. and G. L. Jordan: *Surgical Diseases of the Pancreas*. Philadelphia, J. B. Lippincott Co., 1960, pp. 321-441.
9. Nicholls, A. G.: Simple Adenoma of the Pancreas Arising from an Island of Langerhans. *J. Med. Res.*, 3:385, 1902.
10. Thompson, S. and K. J. Welch: Surgery of the Pancreas. In Benson, C. D., W. T. Mustard, M. M. Ravitch, W. H. Snyder, Jr. and K. J. Welch: *Pediatric Surgery*. Chicago, Year Book Medical Publishers, Inc., 1962, pp. 629-637.
11. Warren, K. W.: Islet Cell Tumors and Hyperinsulinism. *Surg. Clinics N. America*, 42:709, 1962.
12. Whipple, A. O. and V. K. Frantz: Adenoma of Islet Cells with Hyperinsulinism, a Review. *Ann. Surg.*, 101:1299, 1935.
13. Wilder, R. M., F. N. Allan, M. H. Power and H. E. Robertson: Carcinoma of the Islands of the Pancreas. Hyperinsulinism and Hypoglycemia. *J.A.M.A.*, 89:348, 1927.

dren. About three years ago, Dr. Virginia Frantz, who has followed all of Dr. Allen Whipple's original cases and all others that have been encountered at the Presbyterian-Columbia Medical Cen-