

Stab Wound of the Heart *

DONALD G. MULDER, M.D.

*From the Department of Surgery, UCLA Center for the Health Sciences,
Los Angeles, California*

PENETRATING CARDIAC injuries may cause sudden death because of massive hemorrhage, pericardial tamponade, damage to the conduction system or cardiac valves, or laceration of a coronary artery. Less severe injuries may not be immediately lethal, and prompt treatment may be life-saving. Occasionally, residual intracardiac defects (ventricular septal defect, aortico-right atrial fistula, and aortico-right ventricular fistula) have been diagnosed in patients who survived the original trauma.

This report concerns a case of unique cardiac injury caused by stabbing. An aortico-right ventricular fistula was created; in addition, the aortic valve was lacerated and aortic regurgitation ensued. The left-to-right shunt between the aorta and the right ventricle was demonstrated on cardiac catheterization and retrograde aortography. However, the damage to the aortic valve was unsuspected until surgical exploration ten years later, at which time both lesions were successfully repaired.

Case Report

J. C., a 22-year-old man, was hospitalized on April 7, 1952, after sustaining multiple stab wounds of the left and right chest. He was in shock, with a blood pressure of 80/40 mm. Hg. A right hemopneumothorax was found on a chest film and the heart was seen to be slightly enlarged. A Grade IV continuous murmur was heard over the entire precordium. A systolic thrill was noted, which was of maximum intensity in the third left interspace in the parasternal region. A Corrigan brachial pulse was reported to be present. With supportive measures the blood pressure rose to 122/50 mm. Hg, and the patient's general condition improved.

On cardiac catheterization on May 20, 1952,

slight pulmonary hypertension and a left-to-right shunt at the ventricular or pulmonary artery level was revealed. A diagnosis of traumatic aortic-pulmonary fistula was made. On May 27, 1952, exploratory thoracotomy was carried out. At the time of operation a localized thrill could be felt over the high right ventricular outflow tract. No communication between the aorta and the pulmonary artery could be found. It was presumed that the patient had a traumatic ventricular septal defect and nothing further was done.

For the next ten years the patient avoided vigorous physical exertion and had no cardiac complaints. He was lost to medical observation until April, 1962, when he developed a *Streptococcus viridans* endocarditis. This responded promptly to antibiotic therapy, and his clinical condition remained unchanged. The loud continuous murmur over the precordium originally heard in 1952 was still present, and the blood pressure was 130/40-50 mm. Hg. Moderate cardiomegaly and increased pulmonary vascular markings were seen on chest roentgenograms. A retrograde aortogram on July 26, 1962, demonstrated a left-to-right shunt between the root of the aorta and either the right ventricle or possibly the pulmonary artery (Fig. 1). Repair of the traumatic fistula was believed to be indicated, because of the large shunt and the hazard of future bouts of bacterial endocarditis.

Operation

On October 31, 1962, the thorax was explored through a median sternotomy incision. A systolic thrill was palpated readily over a localized area high in the right ventricular outflow tract, where the knife apparently had entered the heart. With digital intracardiac exploration, a 1 centimeter defect in the ventricular septum was found just below the pulmonary valve. Occlusion of this opening caused an elevation of the diastolic blood pressure which established the diagnosis of aortico-right ventricular fistula (Fig. 2a, b). The patient was placed on extracorporeal circulation and cooled to 30 degrees C. The aorta was cross-clamped to obtain a dry operative field. With insertion of a clamp through the defect and into the root of the aorta it was demonstrated that the

* Submitted for publication August 20, 1963.

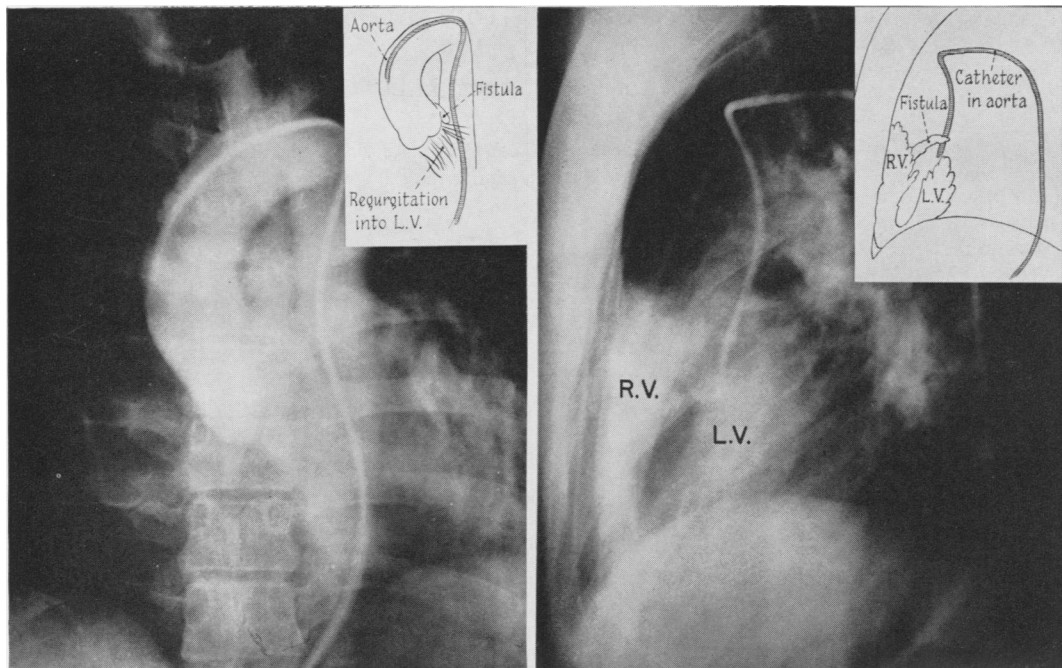


FIG. 1. Retrograde aortogram (PA and lateral) demonstrates communication between root of aorta and high right ventricle. Some radiopaque material is also seen in left ventricle, indicating aortic insufficiency as well.

fistulous tract was short, although the valve cusps were not visible. The firm, fibrous margin of the defect was readily closed with interrupted 3-0 silk

sutures (Fig. 3). After extracorporeal circulation was discontinued, it was apparent from the arterial pressure tracing that there was still signifi-

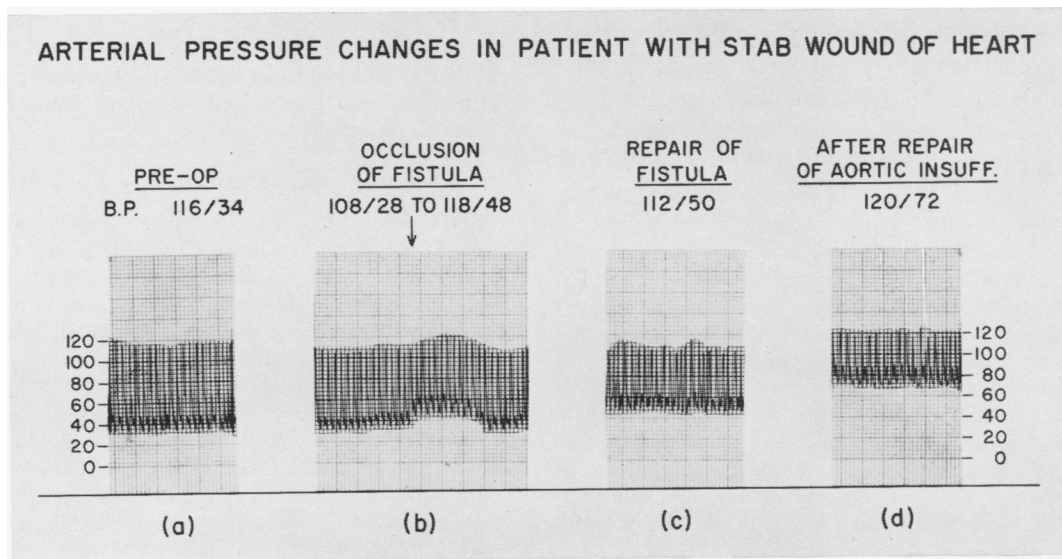
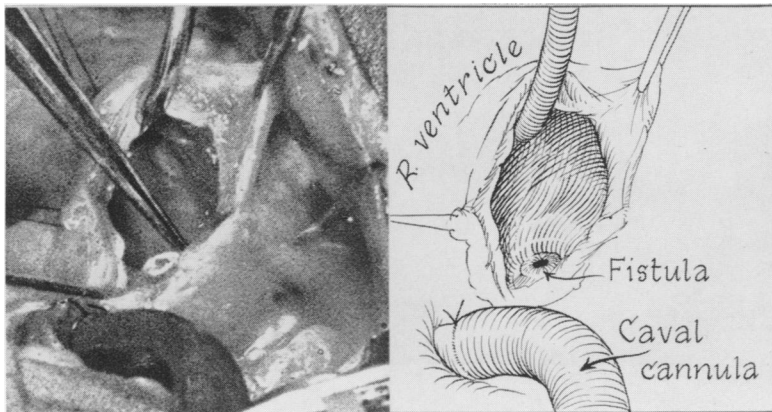


FIG. 2a, b. Peripheral arterial tracing during operation, showing elevation of diastolic pressure when the aortico-right ventricular fistula was occluded by the finger inserted in the heart. c. Significant aortic insufficiency remained after complete closure of the aortico-right ventricular fistula, as evidenced by wide pulse pressure and low diastolic pressure. d. Peripheral arterial tracing following completed repair of both lesions is normal.

FIG. 3. Traumatic fistula between aorta and right ventricle was approximately 1 centimeter in diameter and had a tough fibrous margin.



cant aortic insufficiency (Fig 2c). A Grade III diastolic thrill (previously not palpable) could now be felt at the base of the aorta, which further confirmed valvular incompetence. Bypass circulation was reinstated and an ascending aortotomy was carried out. The right aortic cusp was found to be deformed by marked fibrosis and calcification. The left cusp was also thickened and deformed and had a large central fenestration. It was apparent that the fistulous tract had entered the aortic root in the right coronary sinus near the base of the valve. Both right and left cusps had been injured by the knife (Fig. 4). The non-coronary cusp was somewhat thickened but otherwise relatively normal. The destroyed valve cusps were totally excised and replaced by Teflon (Bahnsen) cusps (Fig. 5). After restoration of circulation no thrills could be felt over the heart and great vessels, and the contour of the arterial pressure tracing was normal (Fig. 2d). The patient's hospital course was unremarkable, and he was discharged on the eighth postoperative day. At that time no murmurs could be heard, and his blood pressure was 120/70 mm. Hg.

Discussion

Stab wound of the heart is not an uncommon injury. As a cause of intracardiac defects, however, it is extremely rare since an injury of this magnitude is usually fatal. Beall and associates¹ reported that in 399 cases of penetrating cardiac wounds, there were only five survivors with intracardiac defects—2 with aortico-right ventricular fistulae, and two with ventricular septal defects. VonBerg¹¹ reported 102 stab wounds of the heart; one survivor had an aortico-right ventricular fistula and another a ventricular septal defect. No such residual

intracardiac defects were reported in a series of 133 cases published by Isaacs.⁴

Despite the rarity of such acquired lesions the literature now contains reports of successful surgical repair of traumatic ventricular septal defects,¹ aortico-right atrial fistulae,⁹ aortico-right atrial-pulmonary artery fistulae,⁸ and aortico-right ventricular fistulae.^{5, 6, 10} However, no instance has been found in which a patient survived both an intracardiac injury and valvular trauma. It is in this respect that the case reported here is unique.

Gerbode² reported a somewhat similar

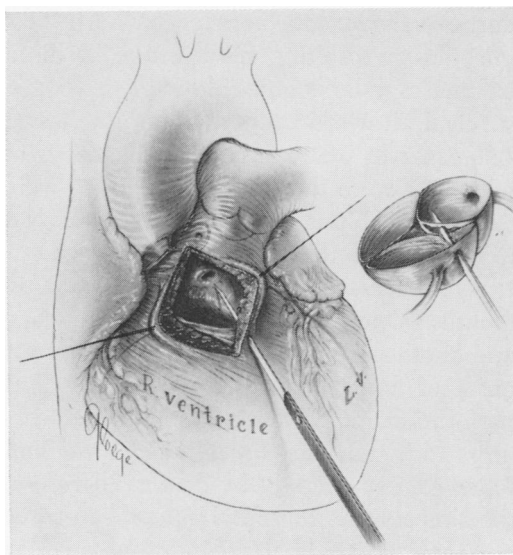


FIG. 4. Diagram depicting course of knife as it pierced the right ventricle, ventricular septum, aortic root, and aortic cusps.

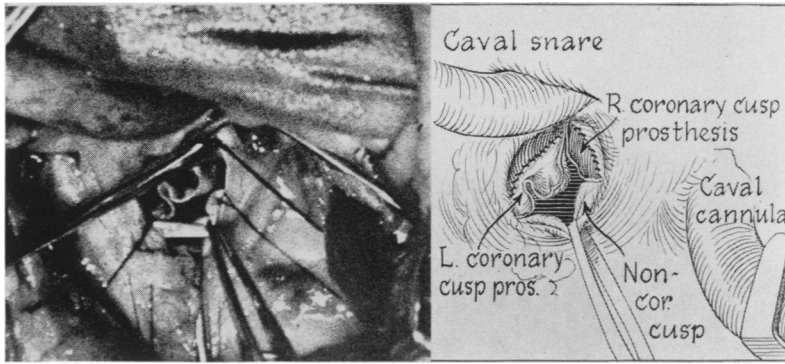


FIG. 5. The right and left cusps were replaced by two Teflon (Bahnsen) prosthetic cusps.

case, in which the patient sustained a penetrating missile wound of the heart, which caused an aortico-right atrial fistula and laceration of an aortic valve leaflet. An exploratory thoracotomy was performed, but the precise diagnosis was not made, and the patient died. The lethal nature of injuries involving the heart valves has been further emphasized by Parmley.⁷ He reported that in 456 cases of penetrating cardiac wounds examined at necropsy (121 stab, 335 missile), "there were several instances in which the heart valves were injured, and in all death ensued within several days of injury."

In contrast to the invariably fatal consequences of penetrating injuries which cause aortic valvular incompetence, aortic regurgitation resulting from *strain*, or blunt trauma may be compatible with prolonged survival. Howard³ reported on a series of 133 cases of acute aortic insufficiency, of which 66 were due to *strain*, and 47 were caused by blunt trauma. Mean survival time of 13 of these patients found at autopsy to have aortic valve lesions was 40 months. One patient survived ten years, and another 11 years. Similarly, the abrupt onset of aortic regurgitation due to cusp perforation in subacute bacterial endocarditis, although life-threatening, is seldom followed immediately by death. Therefore, the almost uniformly fatal outcome in cases of penetrating cardiac wounds and valvular trauma seems most likely to be due to extensive myocardial or great vessel lacera-

tion, rather than to the resulting acute hemodynamic alterations of valvular incompetence.

Although it appears that the aortic valvular insufficiency in the case under discussion was due to direct trauma to the right and left cusps, it is conceivable that this lesion resulted from the patient's bout of subacute bacterial endocarditis in April, 1962 (ten years after the injury). This seems improbable, however, since following the febrile illness there was no significant change in the patient's clinical condition (i.e., no difference in the cardiac murmurs was reported, there was no change in the previously-noted wide pulse pressure, and the patient remained relatively asymptomatic). The types of lesion found in the valve cusps are compatible with either etiology. It is of interest that no bacterial growth was found on examination of the excised cusps.

Appropriate diagnostic studies should be performed on patients suspected of having traumatic defects in the heart or great vessels. It may be extremely difficult to be aware of the full extent of injury on exploration alone. The additional information gained from catheterization and angiographic procedures will usually define the lesions. In our case, the large left-to-right shunt high in the right ventricular outflow tract detected by catheterization and the demonstration of radiopaque material refluxing from the aortic root into the right ventricle, clearly established the diagnosis

of aortico-right ventricular fistula. Subsequent more critical review of the aortogram suggests that there was also regurgitation into the left ventricle. It is surprising indeed that this was not more obvious, in view of the rather striking lesions in the valve cusps. In keeping with this inconsistency was the fact that no diastolic thrill could be felt over the aortic root until after the aortico-right ventricular fistula had been closed, at which time the thrill was quite pronounced. From these observations, it might be inferred that the resistance to the regurgitant aortic flow was less through the fistula than through the deformed valve cusps. However, the cross-sectional area of aortic valvular tissue deficiency (left cusp perforation and right cusp scarring and shortening) seemed greatly to exceed the orifice size of the fistula, so that such a hemodynamic explanation was unlikely. It is postulated that this apparently preferential flow was a result of the ability of the right ventricle to distend with a lower filling pressure than could the left ventricle.

One other interesting feature of the patient's illness was his relative lack of symptoms. Patients with congenital heart disease are frequently quite symptomatic as a result of lesions which are much less dramatic. It appears certain, however, that the patient would eventually have manifested more cardiac symptoms; and the history of a bout of subacute bacterial endocarditis was further indication for operative intervention. To the best of our knowledge, this is the first report of survival following traumatic aortico-right ventricular fistula and aortic valvular insufficiency with successful repair of both lesions.

Summary

1. Penetrating cardiac wounds are a rare cause of intracardiac defects.

2. A case is presented in which a patient was stabbed in the heart and survived for

ten years with the resulting aortico-right ventricular fistula and aortic valvular insufficiency.

3. The fistulous communication was documented by preoperative right heart catheterization and retrograde aortography, but the aortic insufficiency was unsuspected until operation. At that time, both lesions were successfully repaired.

References

1. Beall, A. C., Jr., J. L. Ochsner, G. C. Morris, D. A. Cooley and M. E. DeBakey: Penetrating Wounds of the Heart. *J. Trauma*, 1: 195, 1961.
2. Gerbode, F.: Surgical Treatment of Emergencies of the Heart and Vessels in the Thorax. *J.A.M.A.*, 154:898, 1954.
3. Howard, C. P.: Aortic Insufficiency Due to Rupture by Strain of a Normal Aortic Valve. *Canad. M. A. J.*, 19:12, 1928.
4. Isaacs, J. P.: Sixty Penetrating Wounds of the Heart: Clinical and Experimental Observations. *Surgery*, 45:696, 1959.
5. King, H. and H. B. Shumacker, Jr.: Surgical Repair of a Traumatic Aortic-Right Ventricular Fistula. *J. Thor. Surg.*, 35:734, 1958.
6. Morris, G. C., Jr., P. F. Riley, J. R. Dunn and D. A. Cooley: Traumatic Aortico-Ventricular Fistula: Report of Two Cases Successfully Repaired. *Am. Surg.*, 24:883, 1958.
7. Parmley, L. F., T. W. Mattingly and W. C. Manion: Penetrating Wounds of the Heart and Aorta. *Circulation*, 17:953, 1958.
8. Sawyers, J. L., J. E. Adams and H. W. Scott, Jr.: Surgical Treatment For Aneurysms of the Aortic Sinuses with Aortico-Atrial Fistula: Experimental and Clinical Study. *Surgery*, 41:26, 1957.
9. Swanepoel, A., V. Schire, M. Nellen, L. Vogelpoel and C. Bernard: Traumatic Aortico-Right Atrial Fistula: Report of a Case Corrected by Operation. *Am. Heart J.*, 61:120, 1961.
10. Smyth, N. D. P., P. C. Adkins, G. A. Kelsner and J. Calatayud: Traumatic Aortic-Right Ventricular Fistula. *Surg., Gynec. & Obst.*, 109:556, 1959.
11. VonBerg, V. J., L. Moggi, L. F. Jacobson, P. Jordan, Jr. and C. G. Johnston: Ten Years' Experience with Penetrating Injuries of the Heart. *J. Trauma*, 1:186, 1961.