

# Gardner's Syndrome: \*

## Report of a Case

E. J. DUNNING, M.D., K. S. IBRAHIM, \*\* M.D.

*From the Department of Surgery, Charlotte Memorial Hospital, Charlotte, N. C.*

GARDNER,<sup>7-10, 22</sup> a geneticist, and his co-workers have described a fascinating triad of findings in many members of a large family. When these features of subcutaneous tumors, osteomas, and intestinal polyposis appear in one person, the disease is now properly called Gardner's syndrome. In the case reported in this paper, the presence of osteomas and multiple epidermoid cysts stimulated a search for colonic polyps in the patient and led to the investigation of his family for similar cases.

### Case Report

A 36-year-old Negro man entered the outpatient clinic with the complaint of progressive weakness of three months' duration. He also had dizzy spells, breathlessness, and the passage of some fresh blood per rectum on several occasions recently. When questioned about his surface tumors he stated that these had been present for as long as he could remember and that all the tumors had gradually increased in size.

On examination there were many small and large subcutaneous masses over the scalp, torso and arms (Fig. 1). Also, there were bony nodules over the scalp and mandible. All mucosal surfaces were very pale. Sigmoidoscopic examination to 25 cm. showed extensive polyposis with clustering of the polyps. Some polyps were as large as 2 cm. in diameter.

Hemoglobin was 4.6 Gm./100 ml. and hematocrit 20. A preparation for sickling was negative. The first stool specimen was negative for occult blood.

Skull x-ray films showed osteomas over both rami of the mandible (Fig. 2). A barium enema x-ray revealed numerous discrete filling defects throughout the colon (Fig. 3). No polyps of the small bowel were demonstrated on a special barium

study. On the right mid-femur, by x-ray, there was a ridge of cortical thickening along the long axis of the bone 1 cm. wide and 12 cm. long (Fig. 4).

At the first operative procedure all of the rectal polyps were removed through the sigmoidoscope. None of these polyps were malignant by histologic examination. The following day it was obvious that the rectum had been perforated, either by one of the excisions or by cauterization of a polyp base. The rectal perforation was sutured transabdominally and a sigmoid colostomy performed. Subsequently, total colectomy and ileoproctotomy were performed in one stage. Polyps from the remainder of the colon were diagnosed on microscopic study as adenomatous without evidence of malignancy. One subcutaneous tumor removed from the forehead was diagnosed histo-

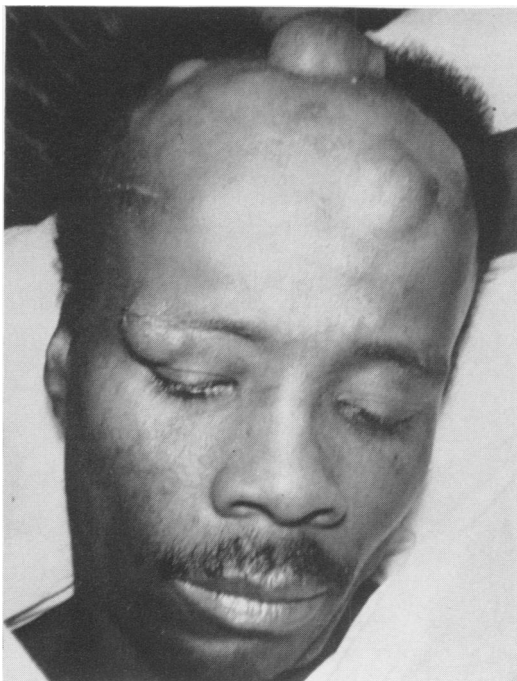


FIG. 1. Photograph showing soft and hard tumors.

\* Submitted for publication May 11, 1964.

\*\* Resident in Surgery.

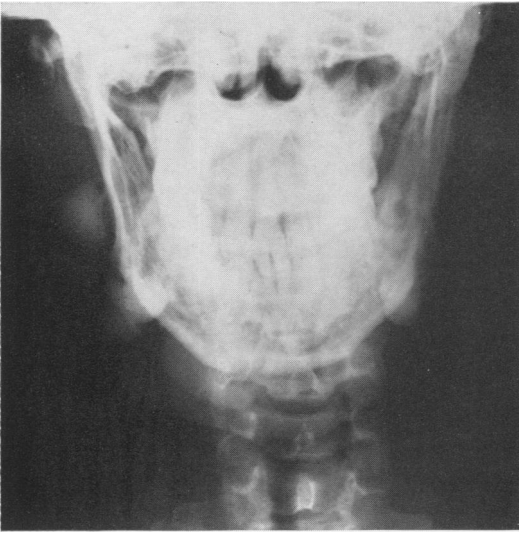


FIG. 2. X-ray of mandible demonstrating many osteomas.

logically as an epidermal inclusion cyst. The patient has remained well since operation.

This patient's father died of "cancer of the stomach" after he was "up in years." His mother is living and well with no surface tumors and no bowel symptoms. His maternal grandfather died with a "stroke" and his maternal grandmother died with "dropsy." The patient had four half

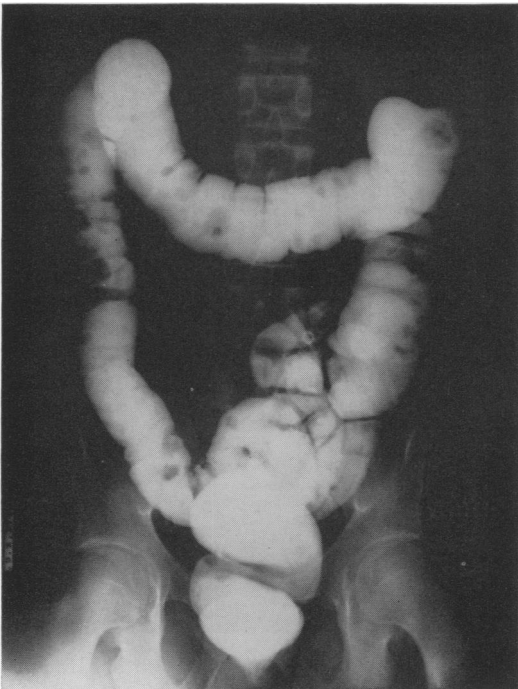


FIG. 3. Multiple colon polyps revealed by barium enema x-ray.

brothers by his father and one of these had "lumps," but nothing can be learned about possible gastro-intestinal symptoms. The patient has four children. One son, 17 years of age, has both epidermoid cysts of the scalp and osteomas of the mandible (Fig. 5), and one daughter, age 11, has an epidermoid cyst of the forehead. Two other children present no surface features of Gardner's syndrome. None of the children admit to any gastro-intestinal symptoms and none would submit to gastro-intestinal studies.

### Discussion

After Gardner's thorough study of one family, kindred 109, in which he found six living members with intestinal polyposis, osteomas and soft tumors, a retrospective review of the literature revealed such a case reported by Devic and Bussey in 1912<sup>5</sup> and another, a Cabot case, reported in 1935.<sup>2</sup> The mother of the Cabot case had died at an early age with carcinoma, and all of the females for three previous generations had had "lumps" similar to the patients'. In the case of Devic and Bussey, there was no family history suggestive of surface tumors or intestinal polyps. Since Gardner's reports, Weiner and Cooper<sup>28</sup> Gumpel and Carballo,<sup>13</sup> Laake,<sup>15</sup> Lazar *et al.*,<sup>17</sup> Smith,<sup>25</sup> Gorlin and Chaundhry,<sup>12</sup> Staley,<sup>27</sup> McKusick<sup>19</sup> and Bochetto *et al.*<sup>1</sup> have reported a total of 17 cases exhibiting the three distinctive features of Gardner's syndrome. Some of these authors<sup>28, 13, 25, 12</sup> together with Miller and Sweet,<sup>18</sup> Fitzgerald,<sup>6</sup> Pugh and Nesselrod,<sup>23</sup> Guptill,<sup>14</sup> Clark and Parker,<sup>3</sup> Oldfield,<sup>21</sup> O'Brien and Wells,<sup>20</sup> Laberge, Sauer, and Marjo,<sup>16</sup> Collins,<sup>4</sup> Shiffman,<sup>24</sup> and Gordon, Rast, and Whelan<sup>11</sup> have reported a total of 50 cases of familial polyposis with one other feature of Gardner's syndrome but not both surface features in the same patient.

Plenk and Gardner<sup>22</sup> made a special study of bone changes in patients with multiple polyposis. In the family studies, the same kindred 109, there were six living patients with osteomas; all had polyposis, and two had adenocarcinoma of the colon. Bowing and an irregular cortical thickening of the cortex of some long bones were also found in three cases. Six of the 14 decreased

members of this family were reported to have had osteomas; all six died from carcinoma of the colon. Oldfield<sup>21</sup> studied familial sebacystomatosis in one family and concluded that multiple sebaceous cysts seem to be inherited as a Mendelian dominant. Later, as he followed this family, three members were found to have colon polyposis and two of these developed carcinoma of the colon. No anomalies of bone were reported. Smith<sup>26</sup> was impressed by the tendency of patients with familial polyposis to form desmoids in their operative wounds and other areas. He reviewed 150 cases of familial polyposis who had undergone operation a long enough time previously for desmoids to form and found that 3.5 per cent developed this problem, a much higher incidence of desmoids than seen after other abdominal operations. Schiffman<sup>24</sup> has collected from the literature a large number of cases of colon polyposis with just soft tumors, another group with polyposis and hard tumors, and a third group with all three characteristics of Gardner's syndrome.

Gardner<sup>10</sup> felt that the inheritance pattern of colon polyposis and osteomas could be explained by a single defective dominant gene or by two separate but closely linked genes. He expressed more reticence in associating the soft subcutaneous lesions with the other two features although the "correlation was impressive." He suggested that some fundamental gene-controlled process gave rise to all three conditions or that three or more closely linked genes produced the syndrome. McKusick<sup>19</sup> postulated that a single gene was responsible for all three features and added that there are at least six genetically distinct forms of intestinal polyposis of which Gardner's syndrome is one. Smith,<sup>25</sup> on the other hand, proposed that Gardner's syndrome is the full blown manifestation of a variety of possible changes which might be present in any patient with multiple polyposis and therefore does not constitute a special sub-

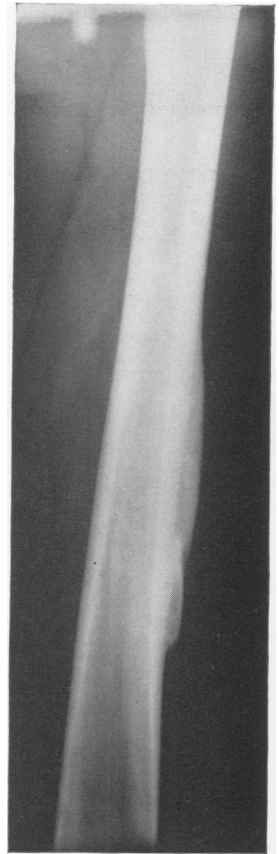

FIG. 4. Cortical thickening in the long axis of right femur.

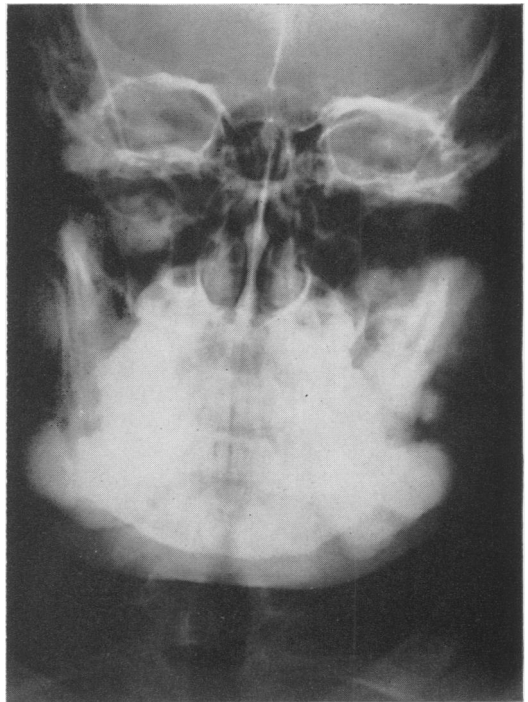


FIG. 5. X-ray of mandible of 17-year-old male son of patient. Numerous osteomas are seen.

group. He suggested that a variation in penetrance might best explain the presence or absence of all three features. Also, Smith reported a patient (Case 9) with multiple colon polyps and a postoperative desmoid but no other features of Gardner's syndrome. Two of this patient's four children had multiple colon polyps, and one (Case 10) had all three characteristics of Gardner's syndrome, although his only soft tumor was an epidermoid cyst on the lower leg.

### Summary

A case of Gardner's syndrome has been reported in which the presence of intestinal polyposis was suspected on the basis of the patient's surface features. A study of the patient's family history, although difficult to compile, revealed a death from cancer in the father and surface lumps in a sibling and two of the patient's four children.

The literature on Gardner's syndrome has been reviewed and summarized. Hypotheses as to the mode of inheritance of this syndrome are: a single dominant gene, a variation in penetrance of a single gene or three closely linked genes.

### References

- Bochetto, J. F., J. F. Raycroft and L. W. De Innocentes: Multiple Polyposis, Exostosis and Soft Tissue Tumors. *Surg. Gynec. & Obstet.*, 117:489, 1963.
- Case Records of the Massachusetts General Hospital. *New Engl. J. Med.*, 212:263, 1935.
- Clark, F. B. and J. M. Parker: Familial polyposis of the colon. *J. Maine Med. Ass.*, 41:331, 1950.
- Collins, D. C.: The Frequent Association of Other Body Tumors with Familial Polyposis. *Amer. J. Gastroent.*, 31:376, 1959.
- Devic and Bussy: Un Cas De Polypose Adenomeuse Generalisee A Tout L'Intestin. *Arch. Mal. Appar. Dig.*, 6:278, 1912.
- Gitzgerald, G. M.: Multiple Composite Odontomas Coincidenta with other Tumorous Conditions; Report of a Case. *J. Amer. Dent. Ass.*, 30:1408, 1943.
- Gardner, E. J. and F. E. Stephens: Cancer of the Lower Digestive Tract in one Family Group. *Amer. J. Hum. Genet.*, 2:41, 1950.
- Gardner, E. J.: Genetic and Clinical Study of Intestinal Polyposis, Predisposing Factor for Carcinoma of Colon and Rectum. *Amer. J. Hum. Genet.*, 3:167, 1951.
- Gardner, E. J. and H. P. Plenk: Hereditary Pattern for Multiple Osteomas in Family Group. *Amer. J. Hum. Genet.*, 4:31, 1952.
- Gardner, E. J. and R. C. Richards: Multiple Cutaneous and Subcutaneous Lesions Occurring Simultaneously with Hereditary Polyposis and Osteomatosis. *Amer. J. Hum. Genet.*, 5:139, 1953.
- Gordon, W. C., Jr., M. F. Rast and T. J. Whelan, Jr.: Gardner's Syndrome. *Ann. Surg.*, 155:538, 1962.
- Corlin, R. J. and A. P. Chaudhry: Multiple Osteomatosis, Lipomas, and Fibrosarcomas of the Skin and Mesentery, Epidermoid Inclusion Cysts of the Skin, Leiomyomas and Multiple Intestinal Polyposis: A Heritable Disorder of Connective Tissue. *New Engl. J. Med.*, 263:1151, 1960.
- Gumpel, R. C. and J. D. Carballo: A New Concept of Familial Adenomatosis. *Ann. Intern. Med.*, 45:1045, 1956.
- Guptill, P.: Familial Polyposis of Colon. Two Families, Five Cases. *Surgery*, 22:286, 1947.
- Laake, H.: Polyposis Coli, Osteomas, Cutaneous Fibromas and Epidermoids; A Case Report. *Gastroenterologia (Basel)*, 87:393, 1957.
- Laberge, M. Y., W. G. Sauer and C. W. Mayo: Soft-tissue Tumors Associated with Familial Polyposis; Report of a Case. *Proc. Mayo Clin.*, 32:749, 1957.
- Lazar, H. P., N. S. Crow and B. G. Brogdon: External Manifestations of Multiple Polyposis; Report of a Case with a Negative Family History. *Arch. Int. Med.*, 100:290, 1957.
- Miller, R. H. and R. H. Sweet: Multiple Polyposis of the Colon; a Familial Disease. *Ann. Surg.*, 105:511, 1937.
- McKusick, V. A.: Genetic Factors in Intestinal Polyposis. *J.A.M.A.*, 182:271, 1962.
- O'Brien, J. P. and P. Wels: The Synchronous Occurrence of Benign Fibrous Tissue Neoplasia in Hereditary Adenosis of the Colon and Rectum. *New York J. Med.*, 55:1877, 1955.
- Oldfield, M. C.: The Association of Familial Polyposis of the Colon with Multiple Sebaceous Cysts. *Brit. J. Surg.*, 41:534, 1954.
- Plenk, H. P. and E. J. Gardner: Osteomatosis (Leontiasis Ossea); Hereditary Disease of Membranous Bone Formation Associated in One Family with Polyposis of the Colon. *Radiology*, 62:830, 1954.
- Pugh, H. L. and J. P. Nesselrod: Multiple Polypoid Disease of Colon and Rectum. *Ann. Surg.*, 121:88, 1945.
- Shiffman, M. A.: Familial Multiple Polyposis Associated with Soft-tissue and Hard-tissue Tumors. *J.A.M.A.*, 179:514, 1962.
- Smith, W. G.: Multiple Polyposis, Gardner's Syndrome and Desmoid Tumors. *Dis. Colon Rectum*, 1:323, 1958.
- Smith, W. G.: Desmoid Tumors in Familial Polyposis. *Proc. Mayo Clin.*, 34:31, 1959.
- Staley, C. J.: Gardner's Syndrome. Simultaneous Occurrence of Polyposis Coli, Osteomatosis, and Soft Tissue Tumors. *Arch. Surg.*, 82:420, 1961.
- Weiner, R. A. and P. Cooper: Multiple Polyposis of the Colon, Osteomatosis and Soft-Tissue Tumors: Report of a Familial Syndrome. *New Engl. J. Med.*, 253:795, 1955.