

Detection of HB_sAg in fixed liver tissue—use of a modified immunofluorescent technique and comparison with histochemical methods

B. PORTMANN, R. M. GALBRAITH, A. L. W. F. EDDLESTON, A. J. ZUCKERMAN, AND ROGER WILLIAMS

From the Liver Unit, King's College Hospital and Medical School, Denmark Hill, London, and The London School of Hygiene, Keppel Street, London

SUMMARY A modified immunofluorescent technique was used for the detection of HB_sAg in formalin-fixed liver tissue, thereby allowing retrospective examination of paraffin sections and avoiding the need to split the sample at the time of biopsy. Comparison with two other methods, involving either orcein staining or standard haematoxylin and eosin (H and E) preparation for ground glass hepatocytes, showed slightly fewer positive hepatocytes in individual biopsies with the latter stain, but the specificity of both methods was high.

In a series of 146 seropositive and 74 seronegative patients with a variety of liver disorders, hepatocytes positive for HB_sAg were found in only one of 55 patients with acute hepatitis type B, whereas larger numbers of positive cells were seen in all 22 healthy carriers of the surface antigen. In the 69 patients with chronic persistent or chronic aggressive hepatitis, the frequency of positive biopsies was 86% and 85% respectively. The positive cells in these cases were, in comparison with healthy carriers of HB_sAg, much fewer in number and were scattered in random fashion throughout the lobule rather than occurring in discrete clumps or sheets. This variation in the intrahepatic expression of HB_sAg may reflect differences in the immune response to hepatitis B viral antigens.

Increasingly sensitive techniques are being evolved for the detection of the hepatitis B surface antigen (HB_sAg) in serum. However, the demonstration of HB_sAg in liver tissue has proved to be a more difficult undertaking. Both the techniques previously available, immunofluorescence and electromicroscopy, are complex and require fresh liver tissue. Attention has therefore turned to methods for demonstrating the antigen in fixed paraffin sections, since these are not only more readily available, but may also be studied retrospectively. Hadziyannis *et al.* (1973), described hepatocytes which, on routine haematoxylin and eosin (H and E) staining, displayed a 'ground glass' appearance of the cytoplasm, and which were shown to contain the surface antigen by specific immunofluorescence. Subsequently, Shikata *et al.* (1974) reported that such hepatocytes are clearly demonstrated by several histochemical methods, of which the most satis-

factory was the orcein stain. Most recently, HB_sAg has been identified in fixed liver tissue using a modified fluorescent technique (Ray and Desmet, 1975) or an immunoperoxidase method (Burns, 1975). In the present paper, we have used immunofluorescence on fixed liver tissue from both seropositive and seronegative patients and have compared this method both with respect to specificity and sensitivity with the orcein and ground glass procedures. In addition, we report data concerning the intrahepatic distribution of HB_sAg, as well as the frequency of positive biopsies in various disease categories, using the orcein stain.

Methods

Needle liver biopsy material from 220 patients was included in the study. The seropositive group comprised a consecutive series of 146 patients in whom the serum was positive for HB_sAg by radioimmunoassay at the time of biopsy. Twenty-two were chronic healthy carriers of the surface antigen.

No histological abnormality was evident in 15 and, in the other seven, minor changes of nonspecific reactive hepatitis or focal parenchymal necrosis were found. Fifty-five patients had acute hepatitis type B. The remaining 69 patients had either chronic persistent hepatitis (14) or chronic aggressive hepatitis (55). Of the latter, 38 had established cirrhosis; 11 of these had developed a hepatocellular carcinoma and in another patient a cholangiocarcinoma was discovered at necropsy. Material from a second needle specimen taken during life or immediately after death was studied in 16 patients with chronic aggressive hepatitis. In four of these, a larger piece of liver taken at necropsy was also available. Thus, in total, 166 liver specimens from 146 seropositive patients were examined. A second biopsy was also performed in three of the patients with acute hepatitis type B who had eliminated the antigen from the serum, but in whom serum aminotransferase levels remained persistently elevated.

The seronegative group consisted of 74 patients in whom the serum was negative for HB_sAg by all techniques, including radioimmunoassay. In 28 patients the diagnosis was acute hepatitis, and in the 37 with chronic liver disease, the diagnoses were chronic persistent hepatitis (six cases), chronic aggressive hepatitis (19), of whom 13 had established cirrhosis, primary biliary cirrhosis (six), and alcoholic cirrhosis with prominent hyaline inclusions (six). The remaining patients consisted of two with haemochromatosis, three with Gilbert's disease, three who were persistently positive for the surface antibody (anti-HBs) and one with the typical PAS-positive diastase-resistant cytoplasmic inclusions of homozygous alpha-1 antitrypsin deficiency.

IMMUNOFLUORESCENCE

This was performed initially on fresh liver obtained from 10 patients (two healthy carriers, two with acute hepatitis type B, two with chronic persistent hepatitis, and four with chronic aggressive hepatitis and cirrhosis). The material was snap-frozen in liquid nitrogen, 10 cryostat sections were cut from each biopsy and, after addition of rabbit anti-HBs (Hoechst Laboratories), diluted 1 in 3, were incubated at 37°C for 30 minutes. The sections were washed twice for 10 minutes in phosphate-buffered saline (PBS: pH 7.2) and treated with fluoresceinated sheep anti-rabbit immunoglobulin for 30 minutes at room temperature. The slides were then mounted in Uvinert mountant aqueous (Gurr Ltd) and examined under a Gillett and Sibert microscope with a darkground fluorescence assembly.

For immunofluorescent examination of formalin-fixed material, sections of paraffin-embedded liver were cut 5-7 μ thick, allowed to float on the surface

of warm water (40°C), and mounted on clean slides with no adhesive. The slides were dried with blotting paper and placed on a hot plate (40°C) for 15 minutes. Paraffin was then removed with xylene and, after passage through absolute alcohol, the sections were washed in PBS for at least two hours. Immunofluorescent examination was then carried out as for fresh liver tissue. Appropriate controls were performed, including specific abolition of fluorescence by absorption of the rabbit anti-HBs with known HB_sAg and pretreatment of sections with unlabelled anti-HBs raised in a different species. After photographing the slides, the coverslips were carefully removed and two sections from each biopsy were then stained with H and E and orcein respectively.

GROUND GLASS AND ORCEIN

Sections stained with H and E were examined for hepatocytes in which the cytoplasm was paler than normal with a glazed or 'ground glass' appearance, as described by Hadziyannis *et al.* (1973). Adjacent sections from the same blocks were then placed in a 1% solution of orcein (BDH) in 70% alcohol for four hours, differentiated in absolute alcohol, passed through xylene and mounted. As in the study of Shikata *et al.* (1974), better results were obtained by prior oxidation in a 0.15% solution of potassium permanganate and sulphuric acid for five minutes, followed by decolourizing in 1.5% oxalic acid solution. With this technique, the cytoplasm of cells containing HB_sAg stained dark purplish-brown against a background of much lighter brown negative cells.

All slides were read 'blind' without knowledge of the serum HB_sAg or the clinical history. The number of positive cells found by each of these techniques was compared. After this, the intrahepatic distribution of HB_sAg was correlated with the histopathological diagnosis in each case.

Results

Specific fluorescence of HB_sAg was obtained in eight of the 10 seropositive cases in whom fresh liver tissue was available, the exceptions being the two patients with acute hepatitis type B. The results obtained in the same 10 patients using the modified test on fixed material were identical, and, although the intensity of fluorescence was slightly less, the fixed sections were somewhat easier to interpret in that histological detail was better preserved and nonspecific background fluorescence related to freezing artefacts was not present. The staining of the positive cells was shown to be immunologically specific, being abolished both by absorption of the

anti-HBs by known HB_sAg and by prior incubation of the sections with horse or human anti-HBs.

Immunofluorescent examination using the modified technique was carried out in biopsies from 65 of the 146 seropositive patients, and 20 of the 74 seronegative cases, and the results compared with those obtained using the histochemical stains. The seropositive group consisted of 11 healthy carriers, 20 patients with acute hepatitis B, five with chronic persistent hepatitis, and 29 with chronic aggressive hepatitis. Twenty of the latter had established cirrhosis, and four of the nine patients with hepatocellular carcinoma were included among these. The seronegative group comprised three patients with Gilbert's disease, seven with acute hepatitis type A, two with chronic persistent hepatitis, and eight with chronic aggressive hepatitis, of whom five had established cirrhosis. With regard to specificity, only those biopsies from the seropositive group which were positive for HB_sAg by specific immunofluorescence gave positive reactions with orcein or contained true ground glass cytoplasm. Equally, all biopsies from

the seronegative group were negative by all techniques. No difficulty was experienced in distinguishing the cytoplasmic inclusions of alcoholic cirrhosis and of alpha-1 antitrypsin deficiency from true ground glass cells and these inclusions were subsequently shown to be negative by immunofluorescence and orcein staining. Furthermore, although iron pigment in patients with haemochromatosis took up the orcein stain in the form of coarse, dark brown granules and exhibited reddish autofluorescence, both these appearances were clearly different from those seen with HB_sAg.

With regard to sensitivity, the number of biopsies containing positive hepatocytes was identical by all three techniques. However, the contrast between positive and negative hepatocytes was greatest with immunofluorescence and least with the ground glass method. Thus, in some biopsies where the total number of cells containing the surface antigen was small, ground glass cells were sometimes difficult to identify.

Much of the fixed material had been stored for up

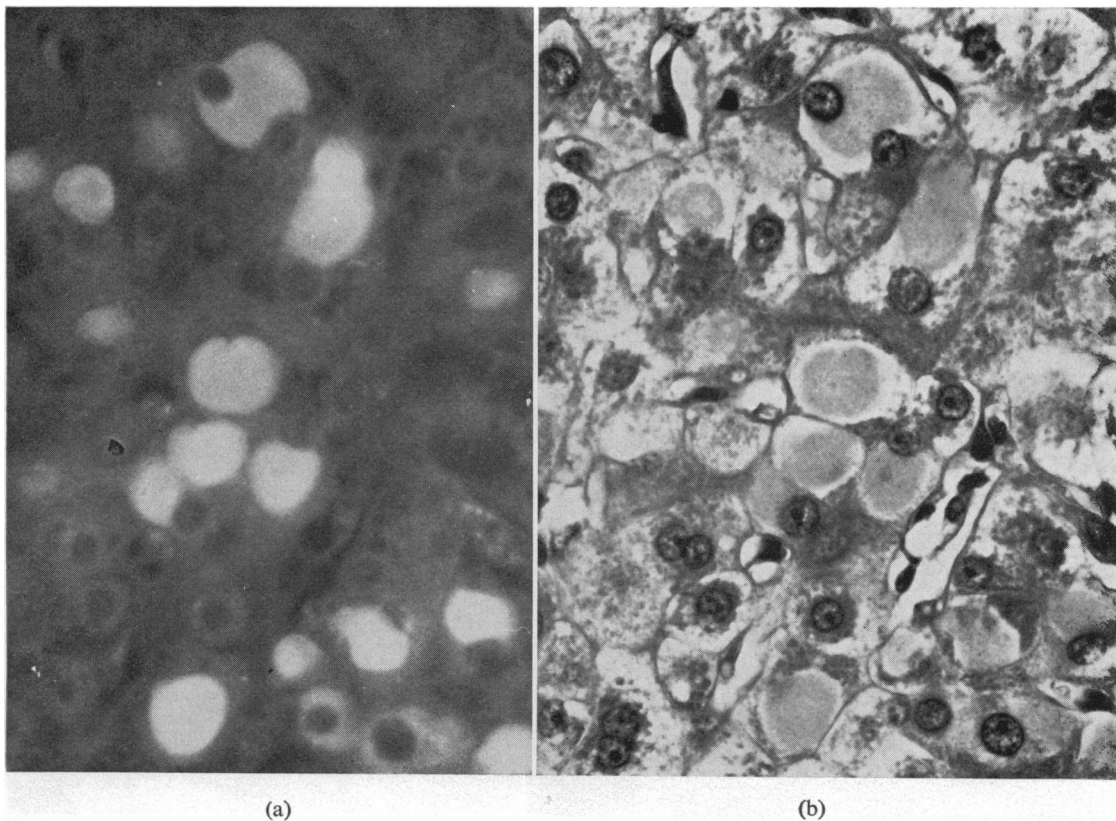


Fig. 1 HB_sAg containing liver cells scattered within a cirrhotic regeneration nodule, shown by (a) immunofluorescence and (b) H and E. $\times 800$

to three years before being processed, but the results with both immunofluorescence and orcein were technically satisfactory in every case. Serum was found to be positive for HB_sAg in all these patients at the time of biopsy. We also examined one biopsy which dated from 1955 and was not included in the series since serum was not available. The finding of extensive ground glass transformation in this specimen prompted us to examine further sections from the paraffin block, both by immunofluorescence and by orcein staining, revealing large numbers of positive hepatocytes in this material which had been stored for 20 years. Demonstration of intrahepatic HB_sAg is also possible both by immunofluorescence and orcein staining, even when formalin fixation is not carried out immediately. In one of the patients, tissue was not obtained until more than 48 hours after death, and, although interpretation of the H and E slides was rendered impossible by marked autolysis, positive cells were seen both by immunofluorescence and with the orcein stain. The overall excellent correlation between the immunofluorescent and histochemical techniques can be seen in Fig. 1,

where the same section has been processed for immunofluorescence and then stained with H and E, and in Fig. 2, where immunofluorescent examination has been followed by orcein staining.

FREQUENCY AND DISTRIBUTION OF HEPATOCYTE HB_sAg

Chronic carriers

All biopsies in this group were found to contain large numbers of positive hepatocytes (Table), the

<i>Disease category</i>	<i>Patients (no.)</i>	<i>Ground glass and orcein positive (%)</i>
Chronic carriers	22	100
Acute hepatitis type B	55	2
Chronic liver disease		86
Chronic persistent hepatitis	14	86
Chronic aggressive hepatitis		
without cirrhosis	17	88
with cirrhosis	38	84

Table *Seropositive patients—percentage of positive biopsies related to disease category*

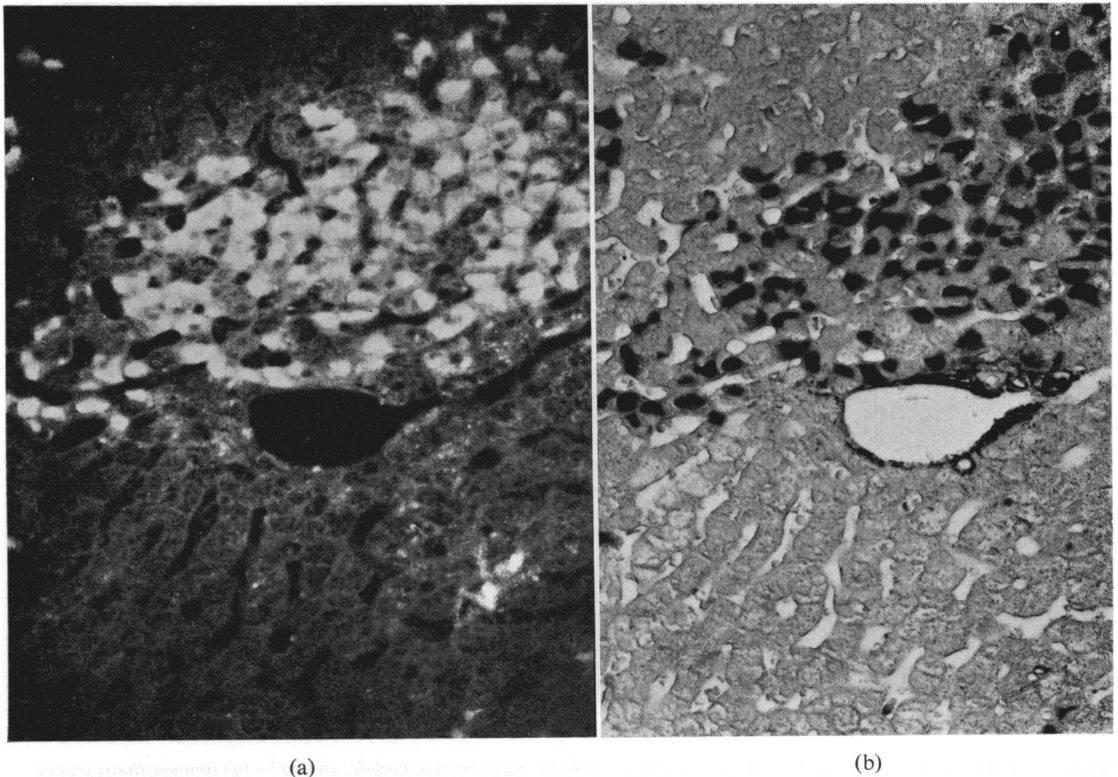


Fig. 2 *Liver biopsy from a healthy carrier of HB_sAg, processed by (a) immunofluorescence and (b) orcein. × 500*

percentage of affected cells varying from 10% to 50% with an average of 20%. Positive cells tended to occur in clumps or large sheets with intervening areas of negative hepatocytes (Fig. 2). The quantity of HB_sAg in the cytoplasm of individual cells varied somewhat from cell to cell. In most, the antigen was distributed diffusely throughout the cytoplasm, while, in a few, it was localized in the form of a few discrete inclusion bodies. The nuclei did not contain HB_sAg and stood out as negatively staining filling defects. No difference was observed on comparing the appearances found in those carriers with normal histology and those with nonspecific reactive hepatitis or focal parenchymal necrosis. Furthermore, there was no correlation between the serum titre of HB_sAg and the number of positive cells found.

Acute hepatitis type B

Although HB_sAg was present in the serum in all cases, the antigen could be demonstrated in only one

biopsy (Table). It was obtained from a patient who died only four days after the onset of fulminant hepatic failure, and was the earliest biopsy examined in the present series. This biopsy was also found to be positive by specific immunofluorescence. Interpretation of the distribution of the few positive cells which were observed in the biopsy specimen was not possible, since gross disorganization of the architecture was present with very few surviving hepatocytes.

A second biopsy was obtained from three patients who had eliminated HB_sAg from the serum but in whom progression to chronic liver disease was suspected. Two patients had had persistently raised serum aminotransferase levels in association with hypergammaglobulinaemia and the repeat biopsy showed chronic aggressive hepatitis. In the third, the aminotransferase levels had also remained elevated, but the histological appearances were of chronic persistent hepatitis. No positive hepatocytes were seen in any of these biopsies.

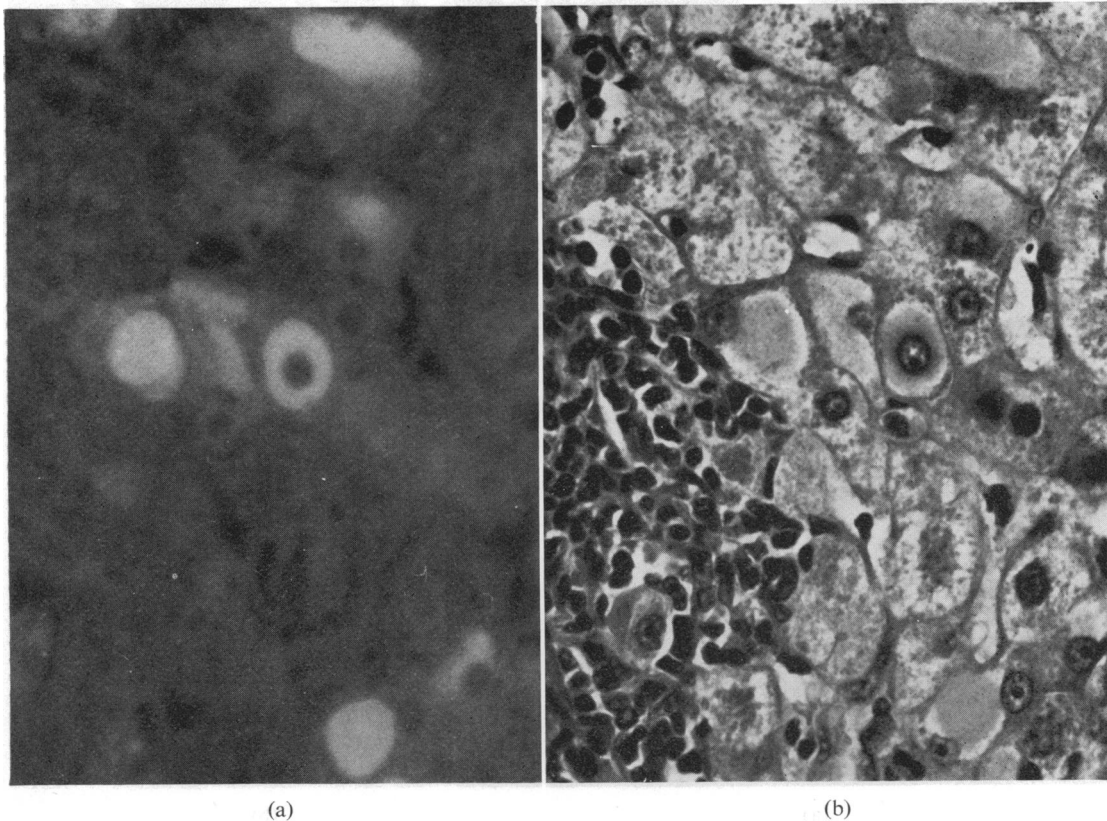


Fig. 3 *Chronic aggressive hepatitis: HB_sAg positive hepatocytes in an area of piecemeal necrosis. (a) Indirect immunofluorescence; (b) H and E. × 800*

Chronic liver disease

Positive hepatocytes were observed in 12 (86%) of the 14 specimens showing chronic persistent hepatitis, in 15 (88%) of the 17 with chronic aggressive hepatitis, and in 32 (84%) of the 38 with chronic aggressive hepatitis and cirrhosis (Table). No difference could be found in the serum titre of HB_sAg or in the clinical features between those patients with positive and those with negative biopsies. Nine of the 11 specimens in which hepatocellular carcinoma was demonstrated were positive. A second needle specimen was available for study in 16 of the patients with chronic aggressive hepatitis. A hepatocellular carcinoma had developed in three, and the biopsy from one patient previously negative for HB_sAg had become positive, but, of the remaining 12, 10 remained positive and two negative. In one of the latter, a much larger specimen taken at necropsy

did in fact contain a few positive hepatocytes, but, in three others, results were no different from those obtained with needle specimens.

The number and distribution of positive hepatocytes in these three categories of chronic liver disease were very similar and were not related to the serum titre of HB_sAg. However, there were marked differences between the findings in these patients and those in the chronic carriers. Thus, in patients with chronic liver disease, the maximum number of positive hepatocytes in any biopsy was 5%, and the average was less than 1%. Furthermore, positive hepatocytes were not clumped together, but were scattered in random fashion throughout each lobule, although frequently, where the total number of positive cells was small, some lobules were negative. We were unable to confirm the previous observation (Shikata *et al.*, 1974; Deodhar *et al.*, 1975) of an

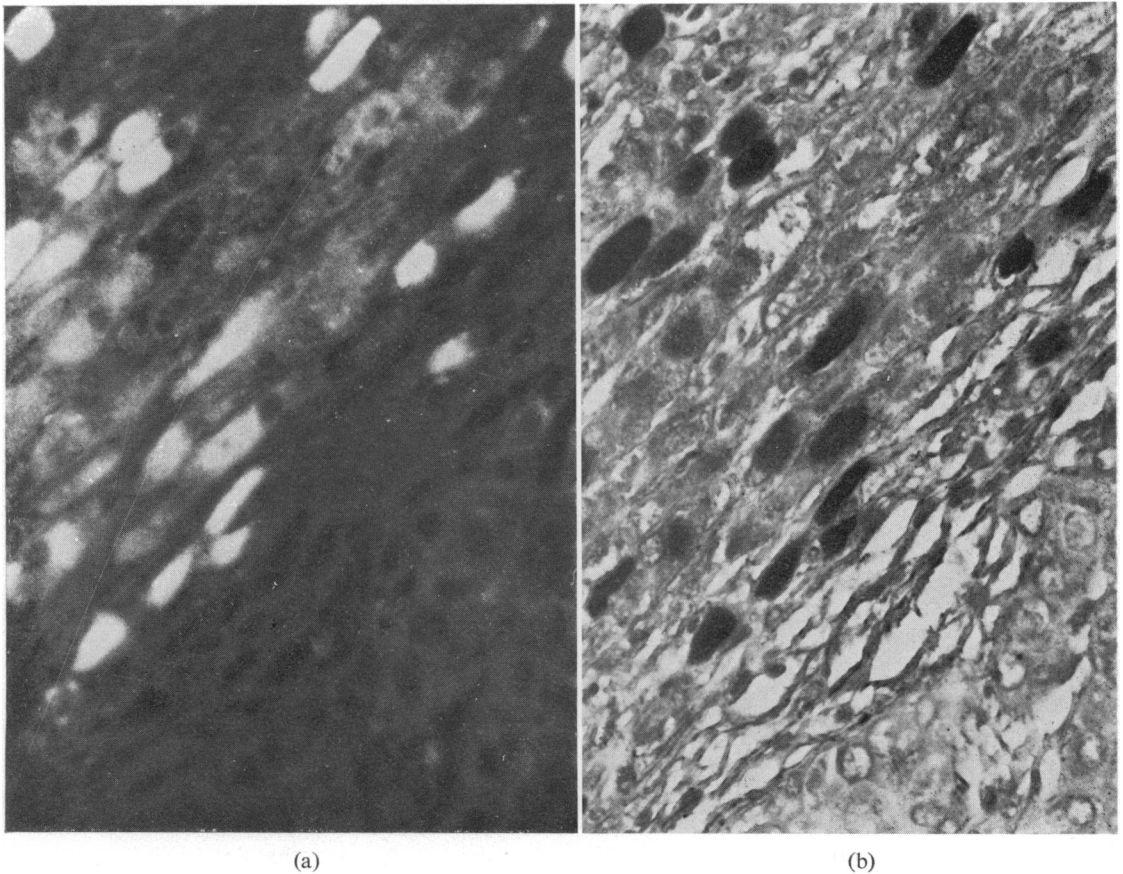


Fig. 4 Area of parenchyma (top left) compressed by hepatoma (bottom right), $\times 800$. Immunofluorescence (a); orcein (b).

inverse relationship between cells containing HB_sAg and areas of piecemeal necrosis (Fig. 3).

Primary hepatic tumours

A very high frequency of malignant tumours was found in patients with HB_sAg-positive active chronic hepatitis at a cirrhotic stage. Of the 38 patients studied, hepatocellular carcinoma was found in seven patients at the time of presentation and developed in a further four cases during the course of the illness. One other patient who died shortly after diagnosis was found to have a cholangiocarcinoma. Tumour cells did not stain positively with immunofluorescence or orcein in any of these biopsies. However, in most cases, cytoplasmic inclusions were seen on H and E which were occasionally confused with ground glass appearances, although both the common hyaline and the rarer globular variety stained darker than the cytoplasm of surrounding hepatocytes. In addition, some tumour cells were seen which, although negative by specific immunofluorescence and orcein, had the typical homogeneous and lighter staining cytoplasm of true ground glass cells. The surrounding non-neoplastic tissue was positive in all but two patients, one with a hepatoma at the time of presentation and the other who developed the tumour during the course of his follow-up. In one of the other seven patients, as noted above, positive hepatocytes were seen in a larger surgical specimen taken at necropsy, although a smaller needle specimen taken immediately postmortem contained no HB_sAg-positive cells.

The number and distribution of those liver cells containing HB_sAg was very similar to that found in the other cases with chronic liver disease, except that around nodules of expanding tumour, adjacent cirrhotic liver was often compressed so that positive hepatocytes were in rather closer contact (Fig. 4). This pattern was also seen in the tissue surrounding rapidly expanding regeneration nodules in some of the other patients with cirrhosis.

Discussion

Until recently, immunofluorescence was the only reproducible technique available for the detection of HB_sAg in hepatocytes. However, this technique has the major drawback of requiring fresh liver tissue and the amount of biopsy material available for fixation in formalin and histological interpretation is considerably reduced. The ability to perform immunofluorescence on paraffin-embedded sections means that the whole biopsy can now be fixed in formalin and also allows retrospective examination of such tissue for HB_sAg.

Our results with the orcein stain showed no

falsely positive hepatocytes as compared with specific immunofluorescence, and the sensitivity was almost as high. However, the differentiation of true ground glass appearances from other cytoplasmic inclusions was sometimes difficult, and the sensitivity was noticeably less than that of the immunofluorescent technique. Of the three techniques, immunofluorescence was the most demanding and suffers from the disadvantage that sections once processed cannot be readily stored for repeated examination in the future. Therefore, although immunofluorescence of paraffin-embedded liver tissue may be a useful tool for the intrahepatic localization of other antigens, such as the hepatitis B core, orcein staining is, in our view, the procedure of choice overall for the demonstration of the surface antigen.

The previous localization of the surface antigen within positive hepatocytes has been the subject of much debate. In early studies, HB_sAg was apparently found mainly in the nuclei (Coyne *et al.*, 1970; Nielsen and Elling, 1971), whereas, more recently, it has been observed only in the cytoplasm (Hadziyannis *et al.*, 1972; Shikata, 1973). It now seems likely that the antisera employed in the earlier immunofluorescent studies also contained antibodies directed at the hepatitis B core-antigen (HB_cAg) or against nuclear proteins (Gerber and Paronetto, 1974). Moreover, nuclear staining has never been observed with orcein (Shikata *et al.*, 1974; Deodhar *et al.*, 1975). The quantity of HB_sAg in the cytoplasm varied somewhat from cell to cell and in some, was distributed diffusely, while in others, the pattern was more discrete. The latter, according to Shikata, may represent damaged hepatocytes which have released most of the antigen contained in their cytoplasm (Shikata *et al.*, 1974). In support of this, he found the diffusely positive type of cell to be commoner in chronic carriers of HB_sAg with no evidence of hepatocyte necrosis histologically, whereas the discrete pattern occurred in patients with chronic liver disease. In the present study, however, such a distribution was not apparent. Nevertheless, there was a difference in the number of HB_sAg-containing hepatocytes. Only one of the patients with acute hepatitis type B had positive cells, whereas large numbers were present in all the chronic carriers. This finding can be related to the wide variations which may occur in the immunological response to infection with the hepatitis B virus (Gudat *et al.*, 1975). In acute hepatitis type B, most patients develop evidence of immunity to the surface antigen (Knolle *et al.*, 1974). Since HB_sAg is known to be present on the surface of hepatocytes during the early stages of acute hepatitis type B (Alberti *et al.*, 1975), this immunological reaction would be expected to effect prompt destruction of

all infected hepatocytes, leading to release of cytoplasmic antigen and negative results with orcein. The period of time necessary for clearance of HB_sAg from the liver is not known, but is likely to be less than a week from the onset of jaundice, since the only positive biopsy in this series, which was also the earliest, was performed on only the fifth day, whereas two other biopsies taken from similar patients on the eighth and ninth day respectively were negative. In contrast, this sequence of events would be most unlikely to occur in healthy carriers of the surface antigen, since immune responses to HB_sAg are not detectable in these patients (Lee *et al.*, 1975b), and infected hepatocytes would not therefore be eliminated. Both cellular and humoral immunity to the surface antigen have been found in patients with HB_sAg-positive active chronic hepatitis (Lee *et al.*, 1975a), and it is surprising, therefore, that antigen-containing hepatocytes are not all destroyed as in acute hepatitis type B. However, recent studies have shown that, in contrast with the findings in acute hepatitis type B, liver cells from patients with antigen-positive chronic aggressive hepatitis do not have HB_sAg on the surface membrane (Alberti *et al.*, 1975), and it is possible that cells with positively-staining cytoplasm are at an early stage of viral replication and have not yet developed external viral determinants. As soon as these do appear, the cell is vulnerable to immune lysis and is promptly destroyed.

The distribution of positive hepatocytes in chronic carriers was also very different from that found in HB_sAg-positive chronic aggressive hepatitis. The larger clumps of positive cells found in the chronic carrier may be the result of direct cell-to-cell spread of virus, as can occur in other viral infections when paresis of the immune system is artificially induced (Notkins, 1974). In contrast, the continuing but incomplete destruction of antigen-containing hepatocytes in HB_sAg-positive chronic aggressive hepatitis will lead to the steady release of mature viruses into the serum. If adequate neutralization by appropriate antibody does not take place, recirculation and infection of further hepatocytes in a random distribution will occur, as has been suggested during infection with the herpes simplex virus (Notkins, 1974).

An inverse relationship at a morphological level in chronic liver disease between the presence of orcein-positive hepatocytes and areas of necrosis was reported both by Shikata *et al.* (1974) and by Deodhar *et al.* (1975). A similar distribution was noted previously using immunofluorescent techniques in two other studies (Hadziyannis *et al.*, 1972; Shikata, 1973). This may be due to release of the surface antigen from damaged cells as intimated

above, and Shikata (1973) noted in several such biopsies that neighbouring Kupffer cells were positive, suggesting recent phagocytosis of material containing HB_sAg. In the present study, no relationship, direct or inverse, could be detected between the presence of positive cells and areas of piecemeal necrosis. However, the total number of cells containing the surface antigen in chronic aggressive hepatitis was often very small, which would effectively obscure any such relationship. Positive Kupffer cells were only rarely detected in our patients and they bore no obvious relationship to areas of piecemeal necrosis.

The lack of a correlation between the serum titre of HB_sAg and the number of positive hepatocytes is not surprising. Although the titre in the serum is presumably dependent upon the quantity of antigen released from infected hepatocytes undergoing immune lysis, the quantity of neutralizing antibody available in the serum is also likely to be important.

We are indebted to the Wellcome Trust, the Research Committee of King's College Hospital and Medical School, the World Health Organization, the Medical Research Council, and the Department of Health and Social Security for support, and to Fabienne Kuhn, Helen Cullens, and George Harwood for expert technical assistance.

References

- Alberti, A., Realdi, G., Tremolada, F., and Cadrobbi, P. (1975). HB_sAg on liver-cell surface in viral hepatitis (Letter). *Lancet*, **1**, 346.
- Burns, J. (1975). Immunoperoxidase localisation of hepatitis B antigen (HB) in formalin-paraffin processed liver tissue. *Histochemistry*, **44**, 133-135.
- Coyne, V. E., Millman, I., Cerda, J., Gerstley, B. J. S., London, T., Sutnick, A., and Blumberg, B. S. (1970). The localization of Australia antigen by immunofluorescence. *Journal of Experimental Medicine*, **131**, 307-320.
- Deodhar, K. P., Tapp, E., and Scheuer, P. J. (1975). Orcein staining of hepatitis B antigen in paraffin sections of liver biopsies. *Journal of Clinical Pathology*, **28**, 66-70.
- Gerber, M. A., and Paronetto, F. (1974). Hepatitis B antigen in human tissues. In *The Liver and its Diseases*, pp. 54-63. Edited by F. Schaffner, S. Sherlock, and C. M. Leevy. Intercontinental Medical Book Corporation: New York.
- Gudat, F., Bianchi, L., Sonnabend, W., Thiel, G., Aenis-haenslin, W., and Stalder, G. A. (1975). Pattern of core and surface expression in liver tissue reflects state of specific immune response in hepatitis B. *Laboratory Investigation*, **32**, 1-9.
- Hadziyannis, S., Vissoulis, C., Moussourous, A., and Afroudakis, A. (1972). Cytoplasmic localisation of Australia antigen in the liver. *Lancet*, **1**, 976-979.
- Hadziyannis, S., Gerber, M. A., Vissoulis, C., and Popper, H. (1973). Cytoplasmic hepatitis B antigen in 'ground-glass' hepatocytes of carriers. *Archives of Pathology*, **96**, 327-330.
- Knolle, J., Meyer zum Büschenfelde, K. H., Bolte, J. P., and Berger, J. (1973). Cellular immune response to hepatitis-associated antigen and homologous liver-specific protein

- in acute HAA-positive hepatitis. *Klinische Wochenschrift*, **51**, 1172-1174.
- Lee, W. M., Reed, W. D., Mitchell, C. G., Galbraith, R. M., Eddleston, A. L. W. F., Zuckerman, A. J., and Williams, R. (1975a). Cellular and humoral immunity to hepatitis-B surface antigen in active chronic hepatitis. *British Medical Journal*, **1**, 705-708.
- Lee, W. M., Reed, W. D., Mitchell, C. G., Woolf, I. L., Dymock, I. W., Eddleston, A. L. W. F., and Williams, R. (1975b). Cell-mediated immunity to hepatitis B surface antigen in blood donors with persistent antigenaemia. *Gut*, **16**, 416-420.
- Nielsen, J. O., and Elling, P. (1971). Investigations of liver biopsies for Australia antigen by immunofluorescent technique. *Clinical and Experimental Immunology*, **9**, 699-705.
- Notkins, A. L. (1974). Immunopathology of viral infections. In *Progress in Immunology II*, volume 4, pp. 141-150.
- Edited by L. Brent and J. Holborrow. North-Holland: Amsterdam.
- Ray, M. B., and Desmet, V. J. (1975). Immunofluorescent detection of hepatitis B antigen in paraffin-embedded tissue. *Journal of Immunological Methods*, **6**, 283-289.
- Shikata, T. (1973). Australia antigen in liver tissue—An immunofluorescent and immuno-electron microscopic study. *Japanese Journal of Experimental Medicine*, **43**, 231-245.
- Shikata, T., Uzawa, T., Yoshiwara, N., Akatsuka, T., and Yamazaki, S. (1974). Staining methods of Australia antigen in paraffin section—detection of cytoplasmic inclusion bodies. *Japanese Journal of Experimental Medicine*, **44**, 25-36.
- Woolf, I. L., Jones, D. M. Tapp, E., and Dymock, I. W. (1975). Electron microscopy of serum of healthy hepatitis B antigen carriers. *Journal of Clinical Pathology*, **28**, 260-262.