

Hyperoxaluria correlates with fat malabsorption in patients with sprue¹

G. B. McDONALD¹, D. L. EARNEST, AND W. H. ADMIRAND

From the Divisions of Gastroenterology and the Departments of Medicine at the University of Washington, Seattle (GBM), and the University of California, San Francisco (DLE, WHA), and the Medical Service, San Francisco General Hospital, San Francisco, California, USA

SUMMARY The effect of fat malabsorption on the absorption and renal excretion of dietary oxalate was studied in four patients with sprue and in two patients with dermatitis herpetiformis and sprue-like jejunal histology. Hyperoxaluria was present in all patients with sprue when fat malabsorption was severe. Urinary oxalate excretion decreased in two of the three patients with coeliac sprue when their fat malabsorption had improved after three months of dietary gluten restriction. Neither patient with dermatitis herpetiformis and sprue had steatorrhoea. In these patients, urinary oxalate excretion was always within normal limits. A significant positive linear relationship ($y = 28.25 + 4.84x$; $r = 0.82$; $P < 0.01$) was demonstrated between faecal fat and urinary oxalate excretion. The results of this study support the concept that severe malabsorption of dietary fat plays a primary causative role in enteric hyperoxaluria.

Patients with extensive ileal resection or disease absorb excessive amounts of oxalate from their diet (Chadwick *et al.*, 1973; Stauffer *et al.*, 1973; Earnest *et al.*, 1974). This leads to increased urinary excretion of oxalate and results in increased risk of calcium oxalate nephrolithiasis. In such patients, factors that are positively associated with increased intestinal oxalate absorption and hyperoxaluria include the length of ileal resection (Stauffer *et al.*, 1973; Earnest *et al.*, 1974), the quantity of dietary oxalate (Chadwick *et al.*, 1973; Stauffer *et al.*, 1973; Earnest *et al.*, 1974), and an intact colon (Earnest *et al.*, 1974). The exact mechanism responsible for enhanced intestinal oxalate absorption in patients with severe ileal dysfunction is not well defined. We tested the hypothesis that excessive absorption of

dietary oxalate is associated primarily with malabsorption of dietary fat. We studied patients with sprue because the severity of their disease and fat malabsorption can be changed by altering the gluten content of their diet.

Methods

SUBJECTS STUDIED

Urinary oxalate excretion was measured in six adults who had histological changes in jejunal mucosa compatible with the diagnosis of sprue, and also in 18 normal individuals. Three of the patients (nos. 1, 2, and 3) were considered to have coeliac sprue, as in each of these persons fat malabsorption had been shown previously to decrease during a gluten-free diet. In the other two patients (nos. 5 and 6), the flat jejunal mucosa was considered to be a manifestation of dermatitis herpetiformis. One additional patient (no. 4) did not respond to a gluten-free diet and was considered to have 'refractory sprue'. Informed consent was obtained from all subjects.

COMPOSITION OF ALL DIETS

All studies were performed in a metabolic ward to assure rigid dietary control and accurate collection of urine and faeces.

¹This study was supported by the following grants from the National Institutes of Health: Research Grant AM 16059, Gastroenterology Research Training Grant AM 05099, and General Clinical Research Center Grant RR-37, University of Washington; Research Grants AM 70287 and AM 13857, and General Clinical Research Center Grant RR 00083-14, University of California, San Francisco. This work was presented at the 76th Annual Meeting of the American Gastroenterological Association (*Gastroenterology*, 68, 949, 1975). (Abstract.)

²Address for reprint requests: Dr. George B. McDonald, Veterans Administration Hospital, Medical Service, 4435 Beacon Avenue South, Seattle, Washington 98108, USA.

Received for publication 10 December 1976.

High oxalate diet

All subjects ate diets containing gluten at home for two to four weeks before the study. During their six days in the metabolic ward, all subjects received daily diet containing gluten, 70 to 100 g fat, and 100 g fresh-frozen spinach. This amount of spinach contains approximately 3.6 mmol (458 mg) oxalate (Zaremski and Hodgkinson, 1962). The gluten (60 g daily) was supplied to patients nos. 5 and 6 as specially prepared bakery goods. Dietary gluten for the other four patients and for the normal volunteers was provided in the regular hospital bread, cakes, and gravies. Medications containing calcium and ascorbic acid were discontinued during the study. Estimated calcium content of all diets was 12.5 to 20 mmol (500 to 900 mg) per day.

Gluten-free diet

After the initial study period, gluten was removed from the diet. After two to four weeks of a gluten-free diet at home, all patients were readmitted and studied on a gluten-free diet containing the same amount of fat, calcium, and spinach as in the high oxalate diet.

Repeat gluten-free diet

The three patients with proved coeliac sprue (nos. 1, 2, and 3) were readmitted after three additional months of gluten restriction at home and studied while on the same constant gluten-free high oxalate diet. This duration of gluten restriction was necessary to correct fat malabsorption in two of the three patients.

TECHNIQUES

Faecal fat balances

Stools of each patient were pooled in 72-hour collections and analysed for fat by established methods. Mean faecal excretion of fat in grams per day and the coefficient of fat absorption were calculated for each of the 15 study periods

Measurement of urinary oxalate, calcium, and phosphorus

Twenty-four-hour urine specimens were collected and refrigerated in plastic bottles containing 10 ml concentrated hydrochloric acid. After thorough mixing, 100 ml aliquots were frozen until analysed by a previously reported isotope dilution technique (Hockaday *et al.*, 1965; Earnest *et al.*, 1974). This method recovers an average of 98% of oxalic acid added to control aliquots of the same 24-hour urine specimen. Urinary concentrations of calcium and phosphorus were measured by a standard autoanalyser technique. In this report, urinary

oxalate, calcium, and phosphate concentrations, expressed as millimoles (and milligrams) per 24 hours, are the means of a minimum of three consecutive daily measurements in each dietary period.

Small bowel biopsies

Jejunal mucosa was obtained at the ligament of Treitz with the multipurpose suction biopsy tube during the first dietary period in all patients to confirm the presence of the characteristic histological changes of sprue. Three patients (nos. 1, 4, and 5) had additional biopsies during the period of dietary gluten exclusion. The one patient (no. 4) with refractory sprue underwent laparotomy a month after the studies were completed. Both ileal and jejunal mucosal biopsies from this patient confirmed persistence of severe histological change with absent villi.

Statistical methods

Urinary oxalate and calcium and faecal fat excretion were correlated by least squares linear regression analysis (Goldstein, 1964). All values for urinary oxalate, calcium, and phosphate are expressed as the mean of consecutive 24-hour urine collections.

Results

URINARY OXALATE, CALCIUM, AND PHOSPHATE EXCRETION

Urinary excretion of oxalate, calcium, and phosphate in the six patients with sprue is shown in the Table. All four patients who had severe fat malabsorption (nos. 1, 2, 3, and 4) also had hyperoxaluria. Urinary oxalate excretion did not change appreciably after two to four weeks of a gluten-free diet. After three months of a gluten-free diet, urinary oxalate excretion decreased significantly ($p < 0.05$) in two of the three patients with coeliac sprue (nos. 2 and 3). However, hyperoxaluria persisted in the patient with refractory sprue. The two patients with dermatitis herpetiformis and flat jejunal mucosa had normal urinary levels of oxalate (0.21 ± 0.05 mmoles (26.9 ± 6.8 mg) per 24 hours) during all diet periods.

In the 18 normal subjects, mean daily urinary oxalate excretion was 0.52 ± 0.03 mmol (65.57 ± 4.05 mg, SD 17.2). Excretion of this quantity of oxalate in urine is greater than that previously reported for normal subjects eating either *ad libitum* or low oxalate diets and reflects the constant high dietary oxalate intake (Chadwick *et al.*, 1973; Stauffer *et al.*, 1973; Earnest *et al.*, 1974).

FAT MALABSORPTION

Mean daily faecal excretion of fat in the four sprue

Table Data from six patients with sprue during three diet periods

Diet and substance measured	Patients with proved coeliac sprue responsive to gluten restriction			Patient with refractory sprue	Patients with dermatitis herpetiformis and sprue	
	1	2	3		4	5
High oxalate diet containing gluten						
Urine*						
Oxalate	199, 166, 234 (200) (1.59)	100, 97, 35, 71 (76) (0.60)	70, 454, 157, 111 (198) (1.57)	30, 95, 57, 92 (69) (0.55)	6, 8, 27, 9 (13) (0.10)	61, 59, 15 (45) (0.36)
Calcium	20, 19, 18 (19) (0.47)	27, 32, 8, 18 (21) (0.52)	32, 14, 16, 28 (23) (0.57)	18, 21, 19, 40 (25) (0.62)	—	48, 122, 73 (81) (2.02)
Phosphate	986, 955, 969 (970) (10.21)	600, 779, 805, 545 (683) (7.19)	923, 1140, 809, 1117 (997) (10.50)	366, 435, 236, 248 (321) (3.38)	—	671, 1052, 1004 (909) (9.57)
Faecal fat†	46.8	16.7	37.6	16.3	5.8	9.2
(CA)‡	(57%)	(84%)	(62%)	(79%)	(95%)	(93%)
Gluten-free diet for 2-4 weeks						
Urine*						
Oxalate	178, 258, 219 (218) (1.73)	86, 200, 162, 181 (157) (1.25)	253, 255, 155, 258 (230) (1.82)	174, 172, 83 (143) (1.13)	5, 18, 6, 5 (9) (0.07)	82, 50, 26 (53) (0.42)
Calcium	11, 8, 9 (9) (0.22)	39, 12, 34, 18 (26) (0.65)	17, 13, 9, 20 (15) (0.37)	23, 45, 23 (30) (0.75)	—	24, 71, 72 (56) (1.40)
Phosphate	1034, 950, 1079 (1021) (10.75)	1037, 1357, 1376 (1257) (13.24)	932, 749, 656, 981 (830) (8.74)	661, 259, 493 (471) (4.96)	—	694, 816, 763 (758) (7.98)
Faecal fat†	40.2	21.2	19.5	25.7	0.5	9.1
(CA)‡	(65%)	(86%)	(81%)	(72%)	(99%)	(91%)
Gluten-free diet for 14-16 weeks						
Urine*						
Oxalate	184, 284, 271, 258 (249) (1.98)	32, 45, 60 (46) (0.36)	177, 93, 86, 71 (107) (0.85)	—	—	—
Calcium	9, 12, 17 (13) (0.32)	55, 22, 88 (55) (1.37)	22, 32, 26, 34 (29) (0.72)	—	—	—
Phosphate	734, 1217, 1428 (1126) (11.86)	1007, 792 (900) (9.48)	880, 814, 1063, 949 (927) (9.76)	—	—	—
Faecal fat†	27.6	4.7	5.8	—	—	—
(CA)‡	(69%)	(93%)	(92%)	—	—	—

*expressed as mg/24 h; consecutive values (mean value in mg/24h) (mean value in mmol/24h).
 †expressed as g/24 h.
 ‡coefficient of absorption (%).

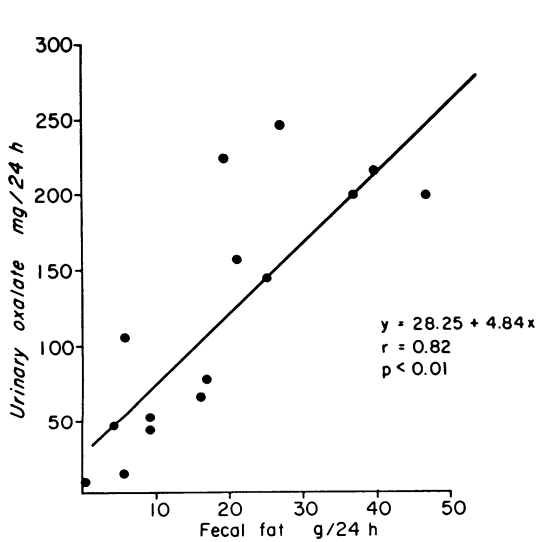


Fig. 1 Comparison of faecal fat excretion with daily urinary oxalate excretion in six patients with sprue.

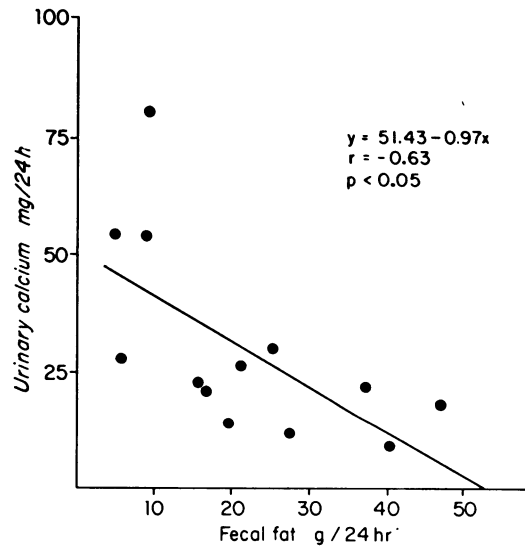


Fig. 2 Comparison of faecal fat and urinary calcium excretion in five patients with sprue.

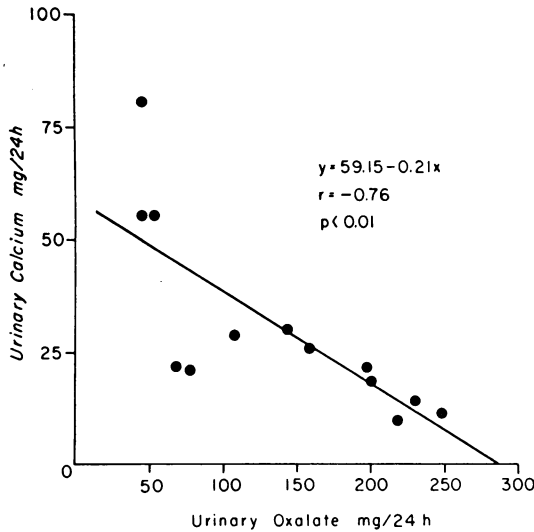


Fig. 3 Comparison of urinary oxalate excretion with urinary calcium excretion in five patients with sprue.

patients was raised (29.4 ± 7.7 g per 24 hours) during the first dietary period and remained abnormal (26.7 ± 4.7 g per 24 hours) after two to four weeks on a gluten-free diet (Table). Fat malabsorption was markedly decreased (12.7 ± 7.5 g per 24 hours) in patients nos. 1, 2, and 3 after three months on a gluten-free diet. In contrast, faecal fat excretion was always within normal limits or only slightly increased in the two patients with dermatitis herpetiformis.

RELATIONSHIP BETWEEN FAECAL FAT AND URINARY OXALATE AND CALCIUM EXCRETION
Regression analysis of faecal fat versus urinary oxalate excretion for the 15 balance periods in the six patients demonstrated a significant positive linear relationship ($r = 0.82$; $P < 0.01$) (Fig. 1). A significant negative linear relationship ($r = -0.63$; $P < 0.05$) was observed between the amount of fat in the stool and the quantity of calcium excreted in urine (Fig. 2). Mean urinary calcium excretion in the four patients with sprue was low (0.50 ± 0.04 mmol (20.0 ± 1.8 mg) per 24 hours) during periods when fat malabsorption was most severe, but it increased (1.32 ± 0.21 mmol (52.9 ± 8.5 mg) per 24 hours) when fat absorption improved ($P < 0.01$).

A significant negative linear relationship ($r = -0.76$; $P < 0.01$) was also present between the amounts of calcium and oxalate excreted in urine daily (Fig. 3). Thus, patients with hyperoxaluria had the most severe fat malabsorption and lower urinary calcium excretion.

Discussion

Dietary oxalate is poorly absorbed from the normal intestinal tract (Archer *et al.*, 1957). Paradoxically, resection of an extensive amount of distal ileum results in increased oxalate absorption and hyperoxaluria (Chadwick *et al.*, 1973; Stauffer *et al.*, 1973; Earnest *et al.*, 1974). Hyperoxaluria has also been described in other patients with a variety of intestinal diseases, including small bowel bypass (Dickstein and Frame, 1973; O'Leary *et al.*, 1974; Fikri and Casella, 1975), pancreatic insufficiency (Stauffer *et al.*, 1974), intestinal pseudo-obstruction (Smith *et al.*, 1972), Crohn's disease (Dowling *et al.*, 1971; Smith *et al.*, 1972; Earnest *et al.*, 1973), and coeliac sprue (Smith *et al.*, 1972; Stauffer *et al.*, 1974). In this diverse group of diseases, malabsorption of fat appears to be the common denominator associated with excessive absorption of dietary oxalate. Our study has specifically confirmed this relationship in that, during a metabolic constant diet, hyperoxaluria developed in patients with coeliac sprue only when severe steatorrhoea was present.

In our sprue patients, increased intestinal absorption and renal excretion of dietary oxalate did not occur until fat excretion exceeded approximately 18 to 20 g daily. (Fig. 1) The two patients with dermatitis herpetiformis had normal fat absorption and urinary oxalate excretion despite histological abnormalities in their jejunum identical with that in the sprue patients (Brow *et al.*, 1971). Abnormal jejunal mucosa does not lead to increased intestinal oxalate absorption in itself. In the one patient (no. 4) with refractory sprue, both jejunal and ileal mucosa remained histologically abnormal despite a strict gluten-free diet; nevertheless, the same reciprocal relationship was present between faecal fat and urinary oxalate.

It is paradoxical that increased absorption of food oxalate occurs in a setting where other constituents of the diet, especially fat, are severely malabsorbed. This may relate to a change in oxalate solubility (Binder, 1974; Earnest *et al.*, 1975b). In the normal situation, oxalate is released from food during digestion and precipitates from solution as an insoluble calcium salt. However, when there is severe fat malabsorption, large amounts of fatty acids remain in the intestinal lumen and precipitate with ionised calcium to form calcium soaps of the fatty acids. This decreases intraluminal calcium ion activity and, secondarily, decreases formation of insoluble calcium oxalate. The net result is formation of more soluble oxalate salts which remain in solution available for absorption. Recent studies (Binder 1974) have demonstrated that soluble oxalate salts are absorbed across intestinal mucosa by a passive,

energy-independent process. Therefore, severe fat malabsorption could enhance oxalate absorption simply by increasing the quantity of dietary oxalate remaining in solution. By this same mechanism, calcium absorption would also be impaired because of precipitation of calcium from solution by the malabsorbed fatty acids (Agnew and Holdsworth, 1971; Bliss *et al.*, 1972). Indeed, urinary calcium excretion, which roughly reflects intestinal calcium absorption, was lowest in our patients when fat malabsorption and urinary oxalate excretion was most raised.

The colon has been suggested as the major site of absorption of excess oxalate in other patients with enteric hyperoxaluria (Chadwick *et al.*, 1973; Earnest *et al.*, 1974). The strongest evidence for this is the absence of hyperoxaluria in patients with ileostomy, ileal resection, and fat malabsorption (Earnest *et al.*, 1974). Studies of regional differences in oxalate absorption in rat intestine also support the concept that increased oxalate absorption with fat malabsorption occurs primarily in the colon (Saunders *et al.*, 1975; Dobbins and Binder, 1976). In the rat jejunum and ileum, oxalate absorption parallels water absorption. In contrast, oxalate absorption in the colon appears to be enhanced by fatty acids despite depressed net water transport (Saunders *et al.*, 1975). A similar mechanism may operate in the human colon.

In our patients, excessive jejunal absorption of oxalate is unlikely for these reasons: (1) absorption of soluble oxalate is directly related to water absorption (Binder, 1974; Saunders *et al.*, 1975); (2) net secretion of water and electrolytes has been demonstrated in the jejunum of patients with coeliac sprue (Fordtran *et al.*, 1967; Kumar *et al.*, 1974); (3), large amounts of luminal fatty acid depress net water transport in the human small bowel (Ammon and Phillips, 1972; Ammon and Phillips, 1973).

It is possible that absorption of water and oxalate is enhanced in the ileum of sprue patients because intestinal perfusion studies have shown increased ileal water and electrolyte absorption in sprue (Silk *et al.*, 1975). But whether this occurs after a meal is unclear, as malabsorbed fatty acids depress ileal as well as jejunal water transport (Ammon and Phillips, 1974). Enhanced ileal water absorption is an unlikely explanation for the hyperoxaluria of our patient no. 4, with flat ileal mucosa.

In summary, the effect of steatorrhoea on oxalate absorption may be two-fold: (1) excessive intraluminal fatty acid may lead to formation of increased quantities of soluble oxalate salts; (2) malabsorbed fatty acids may themselves enhance colonic absorption of soluble oxalate. It appears that the necessary ingredients for development of enteric hyperoxaluria

are adequate dietary oxalate, an intact colon, and excessive malabsorbed fatty acid.

The authors wish to express their appreciation to Dr. H. E. Williams and Dr. C. E. Rubin for their advice and help with this study, and to Mrs. Elaine Hartsook, R. D., for her culinary efforts.

References

- Agnew, J. E., and Holdsworth, C. D. (1971). The effect of fat on calcium absorption from a mixed meal in normal subjects, patients with malabsorptive disease, and patients with a partial gastrectomy. *Gut*, **12**, 973-977.
- Ammon, H. V., and Phillips, S. F. (1972). Fatty acid diarrhea. *Clinical Research*, **20**, 447. (Abstract).
- Ammon, H. V., and Phillips, S. F. (1973). Inhibition of colonic water and electrolyte absorption by fatty acids in man. *Gastroenterology*, **65**, 744-749.
- Ammon, H. V., and Phillips, S. F. (1974). Inhibition of ileal water absorption by intraluminal fatty acids. Influence of chain length, hydroxylation, and conjunction of fatty acids. *Journal of Clinical Investigation*, **53**, 205-210.
- Archer, H. E., Dormer, A. E., Scowen, E. F., and Watts, R. W. (1957). Studies on the urinary excretion of oxalate by normal subjects. *Clinical Science*, **16**, 405-411.
- Binder, H. J. (1974). Intestinal oxalate absorption. *Gastroenterology*, **67**, 441-446.
- Bliss, C. M., Small, D. M., and Donaldson, R. M., Jr. (1972). The excretion of calcium and magnesium fatty acid soaps in steatorrhea. *Gastroenterology*, **62**, 724. (Abstract).
- Brow, J. R., Parker, F., Weinstein, W. M., and Rubin, C. E. (1971). The small intestinal mucosa in dermatitis herpetiformis. I. Severity and distribution of the small intestinal lesion and associated malabsorption. *Gastroenterology*, **60**, 355-361.
- Chadwick, V. S., Elias, E., Modha, K., and Dowling, R. H. (1973). Pathogenesis and treatment of secondary hyperoxaluria in patients with ileal resection. *Quarterly Journal of Medicine*, **42**, 826. (Abstract).
- Chadwick, V. S., Modha, K., and Dowling, R. H. (1973). Mechanism for hyperoxaluria in patients with ileal dysfunction. *New England Journal of Medicine*, **289**, 172-176.
- Dickstein, S. S., and Frame, B. (1973). Urinary tract calculi after intestinal shunt operations for the treatment of obesity. *Surgery, Gynecology and Obstetrics*, **136**, 257-260.
- Dobbins, J. W., and Binder, H. J. (1976). Effect of bile salts and fatty acids on the colonic absorption of oxalate. *Gastroenterology*, **70**, 1096-1100.
- Dowling, R. H., Rose, G. A., and Sutor, D. J. (1971). Hyperoxaluria and renal calculi in ileal disease. *Lancet*, **1**, 1103-1106.
- Earnest, D. L., Johnson, G., Williams, H. E., and Admirand, W. H. (1974). Hyperoxaluria in patients with ileal resection: an abnormality in dietary oxalate absorption. *Gastroenterology*, **66**, 1114-1122.
- Earnest, D. L., Williams, H. E., and Admirand, W. H. (1973). Excessive absorption of oxalate contributes to hyperoxaluria in patients with ileal disease. *Gastroenterology*, **64**, 723. (Abstract).
- Earnest, D. L., Williams, H. E., and Admirand, W. H. (1975b). A physico-chemical basis for treatment of enteric hyperoxaluria. *Clinical Research*, **23**, 439A. (Abstract).
- Fikri, E., and Casella, R. R. (1975). Hyperoxaluria and urinary tract calculi after jejunioileal bypass. *American Journal of Surgery*, **129**, 334-336.
- Fordtran, J. S., Rector, F. C., Locklear, T. W., and Ewton,

- M. F. (1967). Water and solute movement in the small intestine of patients with sprue. *Journal of Clinical Investigation*, **46**, 287-298.
- Goldstein, A. (1964). *Biostatistics, an Introductory Text*, pp. 135-146. MacMillan: New York.
- Hockaday, T. D., Frederick, E. W., Clayton, J. E., and Smith, L. H., Jr. (1965). Studies on primary hyperoxaluria. II. Urinary oxalate, glycolate, and glyoxylate measurement by isotope dilution methods. *Journal of Laboratory and Clinical Medicine*, **65**, 677-687.
- Kumar, P. J., Silk, D. B. A., Rousseau, B., Pagaltsos, A. S., Clark, M. L., Dawson, A. M., and Marks, R. (1974). Assessment of jejunal function in patients with dermatitis herpetiformis and adult coeliac disease using a perfusion technique. *Scandinavian Journal of Gastroenterology*, **9**, 793-798.
- O'Leary, J. P., Thomas, W. C., Jr., and Woodward, E. R. (1974). Urinary tract stone after small bowel bypass for morbid obesity. *American Journal of Surgery*, **127**, 142-147.
- Saunders, D. R., Sillery, J., and McDonald, G. B. (1975). Regional differences in oxalate absorption by rat intestine: evidence for excessive absorption by the colon in steatorrhoea. *Gut*, **16**, 543-548.
- Silk, D. B. A., Kumar, P. J., Webb, J. P. W., Lane, A. E., Clark, M. L., and Dawson, A. M. (1975). Ileal function in patients with untreated adult coeliac disease. *Gut*, **16**, 261-267.
- Smith, L. H., Fromm, H., and Hofmann, A. F. (1972). Acquired hyperoxaluria, nephrolithiasis and intestinal disease. Description of a syndrome. *New England Journal of Medicine*, **286**, 1371-1375.
- Stauffer, J. Q., Humphreys, M. H., and Weir, G. J. (1973). Acquired hyperoxaluria with regional enteritis after ileal resection. Role of dietary oxalate. *Annals of Internal Medicine*, **79**, 383-391.
- Stauffer, J. Q., Stewart, R. J., and Bertrand, G. (1974). Acquired hyperoxaluria: relationship to dietary calcium content and severity of steatorrhea. *Gastroenterology*, **66**, 783. (Abstract).
- Zarembski, P. M., and Hodgkinson, A. (1962). The oxalic acid content of English diets. *British Journal of Nutrition*, **16**, 627-634.