

Myopathy in Whipple's disease

M. SWASH, M. S. SCHWARTZ, M. J. VANDENBURG, AND D. J. POLLOCK

From the Departments of Medicine and Pathology, The London Hospital, London

SUMMARY We report a patient with Whipple's disease who developed a myopathy that improved during antibiotic therapy. The muscle biopsy showed mild type 2 fibre atrophy, type 1 fibre preponderance, variability in fibre size, and changes in the myofibrillar pattern of affected fibres. Interfascicular macrophages contained PAS-positive material. With the electron microscope these macrophages contained membranous inclusions and bacillary bodies, similar to those seen in the jejunal biopsies.

Whipple's disease is primarily a disease of the upper gastrointestinal tract, probably caused by a bacillary infection of the duodenal and jejunal mucosa (Yardley and Hendrix, 1961; Ruffin *et al.*, 1976). Clinical involvement of other organs also occurs (Maizel *et al.*, 1970; Ruffin *et al.*, 1976), especially of joints, lymph nodes, lungs, heart, and central nervous system (Silbert *et al.*, 1976) and, in studies of cases that came to necropsy, the characteristic PAS-positive material has been recognised in macrophages in many other organs (Sieracki and Fine, 1959). In order to call attention to the possibility that clinical involvement of skeletal muscle might be a hitherto overlooked complication of the disease, we report the clinical and histological features of a patient with Whipple's disease in whom a proximal myopathy was a prominent presenting feature.

Case report

A 51 year old accountant (LH 730136) was referred for investigation of muscular weakness. For six years he had noted migratory joint pains, with swelling and stiffness, and during this time he had been mildly anaemic. For two years he had complained of intermittent vomiting, diarrhoea, and abdominal discomfort. He had noted difficulty in rising from a low chair for about nine months and during this time a mild intermittent fever had been observed, and he had lost 6 kg body weight. For two months he had been treated empirically with prednisolone (15 mg/d), without improvement.

Address for reprint requests: Dr Swash, The London Hospital, E1 1BB.

Received for publication 15 March 1977

He was 1.75 m tall and weighed 57 kg. There was moderately severe weakness of the shoulder and pelvic musculature and the deltoid muscles were slightly atrophic. There was no muscular tenderness. The ankle jerks were absent but there was no distal weakness or sensory disturbance. The abdomen was moderately distended, without hepatosplenomegaly. The faeces were pale and bulky. The joints were normal and there was no lymphadenopathy.

INVESTIGATIONS

The haemoglobin was 9.3 g/dl, WBC 16400/ μ l (polymorphonuclears 94%), ESR 75 mm/h, serum iron 37 μ g/dl, total iron-binding capacity 177 μ g/dl, albumin 28 g/l, and globulin 40 g/l. The plasma calcium was 2.37 mmol/l, phosphorus 1.2 mmol/l, and alkaline phosphatase 93 IU/l. Liver function tests, blood electrolytes and blood urea, and the serum B₁₂ and folate were normal. During the 24 hours after an oral xylose load (25 g), 5.6 g appeared in the urine. The faecal fat excretion was 42 g in five days. The plasma creatine phosphokinase was 60 IU/l (normal <60 IU/l). Electromyography (EMG) revealed some brief, short-duration, low-amplitude, polyphasic potentials with a normal interference pattern. There was no spontaneous EMG activity. Per-oral biopsies were taken from the stomach, duodenum, and jejunum, and an open biopsy was taken from the superficial part of the right deltoid muscle.

JEJUNAL BIOPSY

The fresh specimen showed flattening, clubbing, and swelling of the villi. With the light microscope the villi were lined by normal epithelial and goblet cells, but the lamina propria was infiltrated with macrophages containing clumps of PAS-positive

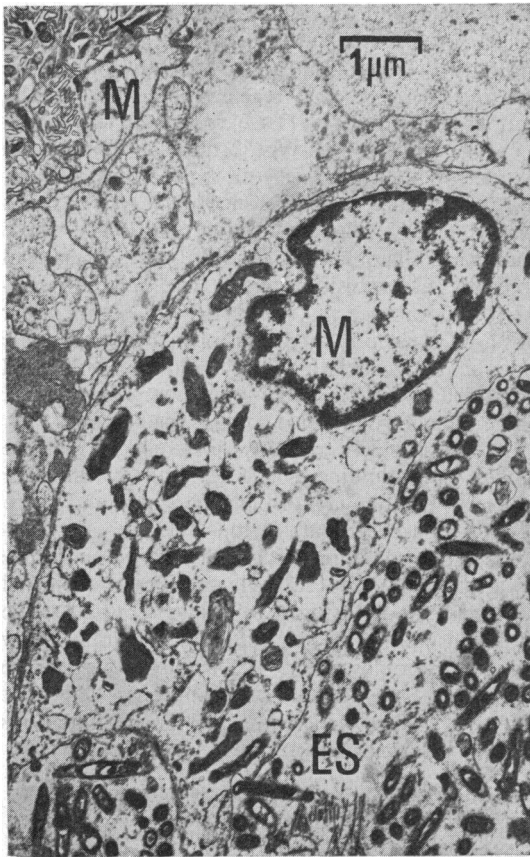

Fig. 1




Fig. 2

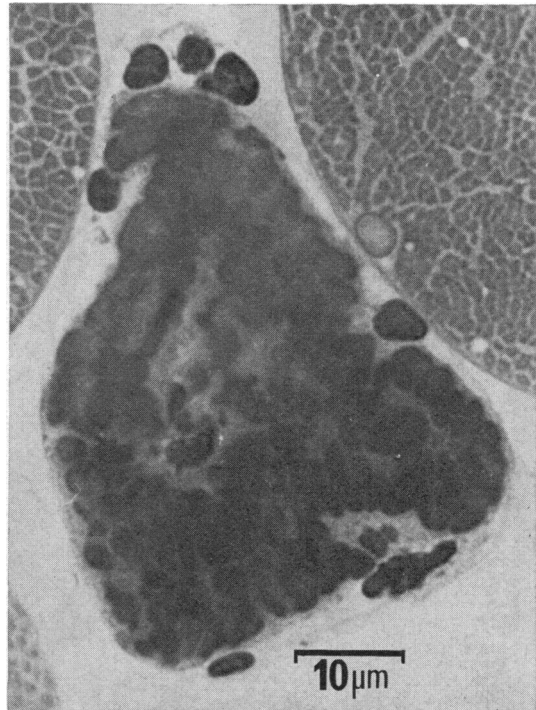


Fig. 3

Fig. 1 *Jejunal biopsy: electron micrograph. Two macrophages (M) contain degraded bacillary material. Bacillary bodies are present in the extra-cellular space (ES).*

Fig. 2 *Muscle biopsy: ATPase. pH 9.5. The dark, type 2 fibres are smaller and more variable in size than the pale, type 1 fibres.*

Fig. 3 *Muscle biopsy: toluidine blue. Semi-thin section. An isolated necrotic fibre.*

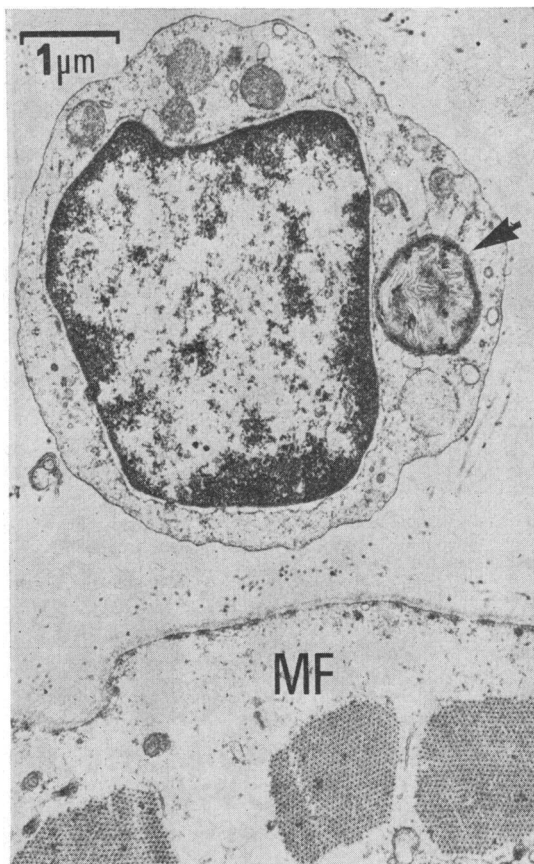


Fig. 4 Muscle biopsy: electron micrograph. A small round cell contains membranous material in a dense-walled cytoplasmic vacuole (arrow). MF: muscle fibre.

material which was resistant to diastase digestion. Similarly abnormal macrophages were also seen in the submucosa. The lymphatic spaces were dilated. With the electron microscope bacillary bodies were found lying free in the extracellular space in the lamina propria, and most macrophages contained arrays of loosely-packed, single-layered membranes (Fig. 1). Culture of the fresh biopsy yielded a moderate growth of *Streptococcus miller*, thought to be unrelated to the organisms seen by electron microscopy.

The duodenal biopsy showed similar abnormalities but the gastric biopsy was normal.

MUSCLE BIOPSY

The muscle biopsy was prepared by standard methods (see Dubowitz and Brooke, 1973) for enzyme histochemical and electron microscopic studies. The frozen sections showed increased variability

in fibre size, and 6% of fibres contained centrally-placed sarcolemmal nuclei (normal < 3%: Dubowitz and Brooke, 1973). Rare necrotic fibres were seen but there were no regenerating fibres. In the sections stained for ATPase pre-incubated at pH 9.5 (Fig. 2) there was type 2 fibre atrophy (mean diameter type 1 fibres 58 μm; type 2 fibres 42 μm), and type 1 fibre preponderance (67% type 1 fibres: normal < 53%, see Johnson *et al.*, 1963). There were no inflammatory changes, but occasional fibres of either histochemical type had a 'moth-eaten' appearance in the NADHtr stain. After diastase digestion small clumps of PAS-positive material remained within the cytoplasm of individual macrophages in the endomysial connective tissue. The muscle fibres did not contain this material.

In semi-thin sections of Araldite-embedded muscle stained with toluidine blue (Fig. 3), the myofibrillar pattern was often abnormally irregular and there were sub-sarcolemmal regions devoid of myofibrils which sometimes extended into the substance of affected fibres. Electron microscopy revealed abnormal variability in myofibrillar size and shape and unusually wide separation of myofibrils by granular sarcoplasm (Fig. 4). The mitochondria were normal and the basement membranes were not thickened. There were no bacillary or membranous inclusions within muscle fibres.

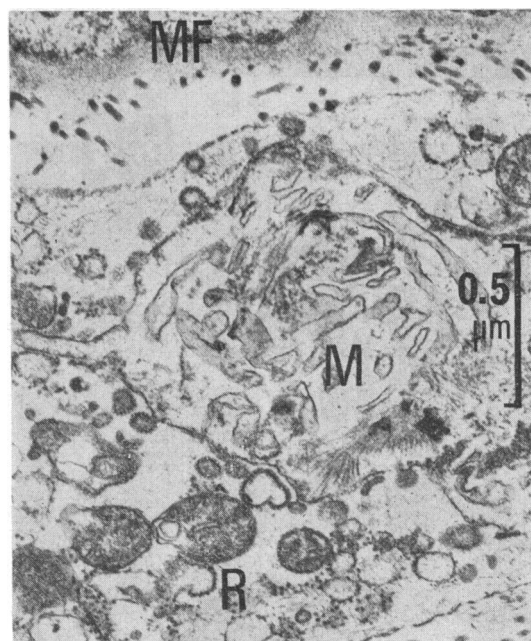


Fig. 5 Muscle biopsy: electron micrograph. Degraded membranous material (M) in a macrophage. MF: muscle fibre. R: ribosomes.

Macrophages and small round cells in the interstitial spaces contained electron-dense, membrane-bound vesicles 0.4 to 1.8 μm in diameter, in which amorphous granular material and degenerate folded membranes were found (Figs. 4 and 5). Rarely, structures similar to the intracellular bacilliform bodies observed in the jejunal biopsies were seen in these cells.

COURSE

A diagnosis of Whipple's disease was made and treatment was begun with oral antibiotics. There was gradual improvement, and a year later proximal weakness was no longer demonstrable. In a second jejunal biopsy, taken after eight weeks' antibiotic therapy, there was less oedema of the villi, and very few bacillary bodies or intracellular membranous inclusions were found.

Discussion

The myopathy in this patient was characterised by changes in the myofibrillar pattern of affected fibres, by variability in fibre size with some excess central nucleation, and by type 1 fibre preponderance with mild type 2 fibre atrophy. These changes are non-specific, but small round cells and macrophages in the interstitial space between the muscle fibres contained PAS-positive material which was resistant to diastase digestion. These abnormal macrophages were similar, both by light and by electron microscopy, to those found in the jejunal and duodenal biopsies, in which the typical appearances of Whipple's disease were observed. The myopathy improved when the underlying Whipple's disease was treated with antibiotics but, before deducing a causal relation between the myopathy and Whipple's disease, three other possible causes of the myopathy must be considered.

Firstly, although muscular weakness was first observed several months before steroid therapy was begun, some of the histological changes in the muscle biopsy could be due to steroid myopathy. Type 2 fibre atrophy is usually a prominent feature of steroid myopathy, and necrosis and vacuolation of muscle fibres may occur (Dubowitz and Brooke, 1973). Enlarged degenerate mitochondria, dilatation of the tubules of the sarcoplasmic reticulum, marked thickening of the basement membrane, and loss of myofibrils have also been described (Afifi *et al.*, 1968; Engel, 1968). In our patient, however, type 2 fibre atrophy was not very prominent, and it was not associated with any of the latter changes. Further, steroid myopathy has been reported only after treatment with prednisolone at higher dosage, and usually for longer periods, than in our patient

(Afifi *et al.*, 1968).

Secondly, the myopathy might be due to cachexia. However, although our patient had lost 6 kg during the time that his weakness developed, he was not clinically cachectic. The relation of non-specific weight loss to the development of a myopathy is a problem only when weight loss is more severe (Tomlinson *et al.*, 1969).

Thirdly, in patients with osteomalacia muscular weakness may occur with normal plasma calcium levels, although the alkaline phosphatase is almost invariably raised in such cases (Smith and Stern, 1967; Pallis and Lewis, 1974). In Whipple's disease, however, osteomalacia is unusual (Maizel *et al.*, 1970), despite the malabsorption, and in our patient both the plasma calcium and the alkaline phosphatase were normal.

Whipple (1907) described loss of strength in his original description, but this symptom does not seem to have been noted in subsequent reports (see Maizel *et al.*, 1970; Ruffin *et al.*, 1976), perhaps because cachectic muscular atrophy was an inevitable sequel before antibiotic therapy was introduced. Smith *et al.* (1965) recorded non-specific changes in the muscles in one of their two cases that came to necropsy and Sieracki and Fine (1959) found 'a few PAS-positive cells' in two of their five necropsies, but symptoms of muscular disease were not mentioned in these reports.

Systemic involvement in Whipple's disease must result from lymphatic or haematogeneous dissemination (Smith *et al.*, 1965; deGroot-Lasseel and Martin, 1969). Reports of PAS-positive endocardial vegetations in 32 of 94 autopsied cases of Whipple's disease (Enzinger and Helwig, 1963), and of PAS-positive material within small cerebral blood vessels (Smith *et al.*, 1965) support the latter concept. The histological findings in our patient demonstrate the widespread involvement that may occur in the disease, but the precise relation of the myopathy to the inclusions found in small round cells and macrophages in the muscle biopsy is uncertain, and must await studies of additional patients.

References

- Afifi, A. K., Bergman, R. A., and Harvey, J. C. (1968). Steroid myopathy: clinical, histologic and cytologic observations. *Johns Hopkins Medical Journal*, **123**, 158-174.
- Dubowitz, V., and Brooke, M. H. (1973). *Muscle Biopsy: a Modern Approach*. Saunders: London.
- Engel, A. G. (1968). Electron microscopic observations in thyrotoxic and cortico-steroid-induced myopathies. *Mayo Clinic Proceedings*, **41**, 785-796.
- Enzinger, F. M., and Helwig, E. B. (1963). Whipple's disease: a review of the literature and report of fifteen patients. *Virchows Archiv für pathologische Anatomie und Physiologie*, **336**, 238-269.
- deGroot-Lasseel, M., and Martin, J. J. (1969). Etude

- ultrastructurale des lésions du système nerveux central dans la maladie de Whipple. *Pathologie et Biologie (Paris)*, **17**, 121-132.
- Johnson, M. A., Polgar, J., Weightman, D., and Appleton, D. (1963). Data on the distribution of fibre types in thirty-six human muscles: an autopsy study. *Journal of the Neurological Sciences*, **18**, 111-129.
- Maizel, H., Ruffin, J. M., and Dobbins, W. O. (1970). Whipple's disease: a review of 19 patients from one hospital and a review of the literature since 1950. *Medicine (Baltimore)*, **49**, 175-205.
- Pallis, C., and Lewis, P. D. (1974). *The Neurology of Gastrointestinal Disease*. Saunders: London.
- Ruffin, J. M., Dobbins, W. O., and Roufail, W. M. (1976). Whipple's disease. In *Gastroenterology*, vol. 2, 3rd edn., pp. 510-517. Edited by H. L. Bockus. Saunders: Philadelphia.
- Sieracki, J. C., and Fine, G. (1959). Whipple's disease—observations on systemic involvement. II. gross and histologic observations. *Archives of Pathology*, **67**, 81-93.
- Silbert, S. W., Parker, E., and Horenstein, S. (1976). Whipple's disease of the central nervous system. *Acta Neuropathologica (Berlin)*, **36**, 31-38.
- Smith, W. T., French, J. M., Gottsman, M., Smith, A. J., and Wakes-Miller, A. J. (1965). Cerebral complications of Whipple's disease. *Brain*, **88**, 137-148.
- Smith, R., and Stern, G. (1967). Myopathy, osteomalacia and hyperparathyroidism. *Brain*, **90**, 593-602.
- Tomlinson, B. E., Walton, J. N., and Rebeiz, J. J. (1969). The effects of ageing and of cachexia upon skeletal muscle: a histopathological study. *Journal of the Neurological Sciences*, **9**, 321-346.
- Whipple, G. H. (1907). A hitherto undescribed disease characterised anatomically by deposits of fat and fatty acids in the intestinal mesenteric lymphatic tissues. *Bulletin of the Johns Hopkins Hospital*, **18**, 382-391.
- Yardley, J. H., and Hendrix, T. R. (1961). Combined electron and light microscopy in Whipple's disease. Demonstration of 'bacillary bodies' in the intestine. *Bulletin of the Johns Hopkins Hospital*, **109**, 80-98.