

Progress report

Portal circulation and portal hypertension

During the last 25 years, there have been important developments in visualising the portal vein, in examining its contents, and in measuring the pressure of blood flowing within it. Radiologists have set the scene and now is the time of the scanner. These technical advances have been applied to the diagnosis and treatment of patients with portal hypertension, and many ingenious surgical techniques have been proposed. The problem of successful treatment of the patient with bleeding oesophageal varices and cirrhosis of the liver, however, has not yet been solved. This report discusses the portal vein in terms of pressure, flow, and regeneration factors. Portal hypertension is classified and methods of relief are discussed.

Methods of visualising the portal vein

RADIOLOGICAL TECHNIQUES

Peroperative injection of contrast material directly into portal vein or one of its tributaries

This method has the obvious disadvantage of necessitating surgery. Filling of the portal system can be so great that interpretation of anatomy is difficult.

Splenic venography

This is simple to perform. The portal system and collaterals are seen particularly clearly and the portal pressure can be measured at the same time through the splenic needle. The small risk of haemorrhage from the splenic puncture is a disadvantage. Abnormal blood clotting or deep jaundice are contraindications.

Selective visceral angiography

The coeliac axis is catheterised via the femoral artery with a pre-formed opaque catheter and the injection of a bolus of radio-opaque contrast material¹. The portion of contrast material that flows into the splenic artery returns through the splenic and portal veins and produces a splenic and portal venogram of variable quality. Similarly, a bolus of contrast material introduced into the superior mesenteric artery returns through the superior mesenteric and portal vein, which can be seen in radiographs exposed at the appropriate intervals. The portal vascular bed is not seen so clearly as with splenic venography. Because splenic venous blood may be diverted into large gastro-oesophageal collaterals a splenic venogram may occasionally show a non-filled portal vein, even though the vein is patent. In such cases, a mesen-

teric angiogram will determine whether or not the main portal vein is, in fact, occluded.

Visceral angiography has the additional advantage that the hepatic arterial system can be seen, so allowing space-filling lesions in the liver to be identified. A tumour circulation may help to diagnose primary liver cancer or other tumours. Knowledge of splanchnic and hepatic arterial anatomy is useful if surgery is contemplated. Haemangiomas and arteriovenous aneurisms may be identified. A disadvantage is that the portal venous pressure cannot be measured.

Umbilical vein catheterisation

The umbilical vein of the adult can be reopened, and catheterised, so allowing access to the left branch of the portal vein and hence to the portal-venous system^{2,3,4}. Because the technique is not easy and the failure rate high, it demands the services of an experienced team. The procedure fails if there has been previous upper abdominal surgery.

Perhepatic catheterisation

The portal vein may be entered through the liver substance^{5,6,7}. A catheter over a needle is introduced percutaneously into the liver. The needle is then advanced under image intensification in the direction of the portal vein. The needle is removed and the radio-opaque catheter gradually drawn back, with suction applied, until blood is freely aspirated. A test injection of contrast medium will confirm the position of the catheter in the portal vein or one of its branches, and the catheter is then advanced over a guide-wire as far as possible along the splenic vein. The catheter may then be directed into various branches of the splenic and portal vein. Contrast material can be injected and a portal venogram obtained. This technique is not as safe as other methods. It is usually combined with therapeutic sclerosis of the portal venous gastro-oesophageal collaterals⁸.

Ultrasound procedures

These have the advantage of being rapid, non-invasive, and safe. The relatively inexpensive grey scale ultrasound may be used to visualise the portal vein at the hilum of the liver⁹. A normal portal vein is easily seen, while an incomplete or recanalising vein is irregular and reduced in diameter, and a thrombosed vein is not detected. The more costly whole body scanner (EMI scanner) using computerised axial tomography allows better definition of the portal vein. With either technique the visualisation of the whole portal venous tree is not as good as with techniques such as splenic venography or splanchnic arteriography. The collateral circulation is not well shown and pressure measurements are not possible.

Pressure recordings

In any patient with portal hypertension the actual height of the portal venous pressure must be recorded.

METHODS OF RECORDING

Intrasplenic puncture

This is the most convenient technique.

Operative portal pressure measurements

These measurements are unreliable, as they are affected by the anaesthetic, blood-loss, position of the patient, and duration of the operation.

Umbilical vein catheterisation

This procedure allows the pressure in the left branch of the portal vein to be recorded^{3,4}.

Transhepatic portal catheterisation

This procedure allows the pressure in the main portal vein to be measured. A thin needle can be used with safety⁵.

Wedge hepatic venous pressure (WHVP)

This well-established technique of measuring sinusoidal venous pressure is now performed less often. It is time-consuming and is being replaced by the splenic and transhepatic techniques. It continues to be useful in distinguishing presinusoidal from intrahepatic portal hypertension. Hepatic venography is essential for the diagnosis of the Budd-Chiari syndrome¹⁰. The height of the WHVP has been used to distinguish chronic active from chronic persistent hepatitis¹¹.

Portal venous circulation

TECHNIQUES OF MEASUREMENT

Portal blood flow

Newer non-invasive isotopic scanning procedures with scintillation scanning give information on the speed and direction of flow but not on absolute flow. Electromagnetic flowmeters may be used to measure flow in the exposed portal vein or hepatic artery. This, of course, involves surgical exploration.

Dilution methods exist which use the principle of injecting contrast material or a radioactive substance into the portal vein, followed by cine-radiography or isotope counting over the liver. Alternatively, the extraction may be estimated by measuring concentration in hepatic venous blood.

In animals, droplets of Lipiodol may be injected into the portal vein and cinefluography performed. The portal venous flow is calculated from the mean linear velocity and the mean cross-sectional area of the portal vein. In man, the method may be applied by injecting the Lipiodol droplets into the portal vein, access being obtained by umbilical vein catheterisation^{12,13}. Alternatively, a bolus of ¹³³Xe may be introduced and a gamma camera used to monitor rate of clearance¹⁴. A wide difference in blood flow exists between various parts of the human liver.

Scintiphotosplenoportography

This involves injection of a marker bolus of human albumin tc-labelled microspheres into the spleen with subsequent recording of the course by gamma-scintillation cameras and video taping coupled to a data-storage system^{15,16,17}. Direction of flow can be ascertained, also the transit time from spleen to liver, and the fraction of splenic blood flow shunted away from the liver may be assessed. Although images are considerably less precise than those obtained by traditional splenoportography, the procedure may be safer and also more physiological because of the smaller bolus injected.

Reversed blood-flow

Reversal of flow in the portal vein has been postulated in cirrhosis. Because intrahepatic portal and hepatic arterial flow is obstructed, blood entering the liver may find it easier to exit through the portal vein rather than through the normal route via the hepatic vein. This concept is based on various pieces of evidence. The non-filled portal vein in a splenic venogram would support reversed flow. If the portal vein be temporarily clamped at surgery, the pressure in the proximal limb may exceed that in the distal. Sometimes, the wedged hepatic venous (sinusoidal) pressure may exceed that in the main portal vein. Radiological studies show that occasionally opaque medium injected under pressure through a wedged hepatic venous catheter enters the main portal vein and oesophageal collaterals¹. However, the same appearance can be recorded in patients with cirrhosis but without reversed flow¹⁸. Portal venous injection after catheterisation of the umbilical vein may very occasionally result in complete flooding of the portal vein and varices so that the liver fails to be perfused². It is however, very rare, being seen in only two of 232 patients studied.

Reversal of flow, with diversion of hepatic arterial blood away from the parenchyma and into the main portal vein, would deprive the liver cells of oxygen and other nutriment. It would explain poor results after side-to-side portacaval shunting and the frequent development of hepatic encephalopathy after such operations. However, it seems very unlikely that such reversal of flow occurs with any frequency. Indeed, evidence marshalled by Moreno and his colleagues¹⁹ casts doubt on its existence as a spontaneous phenomenon. It may, of course, be a consequence of any side-to-side portal systemic shunting operation.

Streamlines

Work in animals suggested that blood from the spleen drained particularly into the left lobe, whereas blood from the intestines (mesenteric) went predominantly to the right lobe of the liver. This explained the greater susceptibility of the left lobe to both viral and nutritional liver injury, for this was the area deprived of intestinal nutriment. Later workers, using portal venography and radioisotopic methods, have obtained inconsistent results, some clearly demonstrating streamlining²⁰, while others²¹ could not. In the most recent study, a small injection of only 1 ml ^{99m}TcO was made into the spleen and scintiphotosplenoportography performed²². Serial scans over 10 seconds, using a gamma camera, allowed actual visualisation of the channelling of portal blood into the right and left hepatic lobes. The low pressure, small volume injection used for the study would not disturb flow equilibrium in the portal vein. In three of 10 patients the distribution was mainly to the left, whereas in five of 10 it was to the right. In one patient, in whom the test was repeated, the distribution was to the left on the first occasion and to the right on the second. This suggests that crossing over of the blood stream can occur in the human portal vein. These results also support the view that the flow is streamlined rather than turbulent.

Hepatotropic factors in portal venous blood

More than 50 years ago, experimental pathologists postulated that portal blood was particularly beneficial for the encouragement of liver cell regenera-

tion. Rous and Larimore (1920)²³ believed that the poor health of dogs after portacaval anastomosis was due to extrahepatic diversion of portal blood, with its contained hepatotrophic factors. Later the emphasis moved away from the concept of regenerative factors and the importance of portal blood flow *per se* was stressed²⁴. The necessity of portal blood for maintenance of hepatocellular function was re-emphasised when liver transplantation became possible. If an auxiliary liver were transplanted, the original liver remaining *in situ*, then only the liver which had the portal blood flow survived²⁵. The liver lacking portal blood flow shrunk, lost its glycogen, and showed depletion of the rough endoplasmic reticulum²⁶. The portal blood flow returning from the pancreas seemed to play a particular role in hepatocellular regeneration²⁷. This implicated the pancreatic hormones as hepatotrophic substances. The important ones seemed to be insulin and glucagon, but there may be others. The role they play, whether alone or in combination, is extremely controversial^{26,28,29}, and their mode of action is also uncertain. Insulin and glucagon are known to act on the cell membrane and how this effect is related to the hepatocellular hypertrophy and hyperplasia produced by protein, and to RNA or DNA synthesis, is still unclear²⁶.

The concept may have some practical significance. Intraperitoneal glucagon-insulin has prolonged survival in mice with fulminant viral hepatitis³⁰. This animal model does not resemble human viral hepatitis very closely; moreover, the hormones were really effective only when given at the time of infection and clearly this would not be possible in man. Nevertheless, this is a promising approach to the management of a very fatal condition.

Classification of portal hypertension

Portal hypertension is, in general, classified into two main groups, pre-sinusoidal and intrahepatic³¹. This distinction is a practical one. The pre-sinusoidal forms, which include obstruction to the sinusoids by Kupffer and other cellular proliferation, are associated with relatively normal hepatocellular function. Consequently, if patients with this type suffer a haemorrhage from oesophageal varices, liver failure is rarely a consequence. In contrast, the intrahepatic types are associated with hepatocellular disease. Patients with this type suffering haemorrhage frequently go into liver failure.

PORTAL HYPERTENSION

Pre-sinusoidal

The pre-sinusoidal form is divided into two types.

Extrahepatic pre-sinusoidal This type is caused by obstruction to the main portal vein. This may be related to neonatal sepsis, pyelephlebitis, tumour invasion, or to diseases associated with increased blood clotting.

Intrahepatic pre-sinusoidal This form is caused by lesions in the portal zones and within the sinusoids of the liver. Causes include the reticuloendothelial diseases, and sarcoidosis and congenital hepatic fibrosis. In schistosomiasis, the portal hypertension follows portal zone fibrosis after ova have lodged in the portal zones. In primary biliary cirrhosis, portal hypertension may be a presenting feature long before the development and the nodular regeneration of cirrhosis^{32,33}. In this condition the mechanism of the portal hypertension is still uncertain, although portal zone lesions and narrowing of the sinusoids because of cellular infiltration have been incriminated.

The intrahepatic portal venous radicles and sinusoidal cells may be injured by toxic factors. This has been described as a complication of the treatment of psoriasis with inorganic arsenic (sodium arsenite)^{34,35}. The arsenic may be directly injurious to the intrahepatic portal veins by causing fibrosis and sclerosis.

The non-cirrhotic portal fibrosis found in India has also been related to arsenic taken in drinking water, in unorthodox medicines, and in opium obtained illegally^{36,37,38}.

Liver disease in vineyard sprayers in Portugal may be related to prolonged exposure by inhalation to sprays containing copper³⁹. This induces fibrosis, activation of sinusoidal lining cells, and 'idiopathic' portal hypertension. Angiosarcoma may be a complication.

Exposure to the vapour of the polymer of vinyl chloride leads to sclerosis of portal venules in the portal zones, with the development of portal hypertension^{40,41}. The obstruction may be at a sinusoidal level. Vinyl chloride in animals causes piling up of the sinusoidal vascular endothelium and subsequent obstruction⁴². Angiosarcoma is a late development.

In Felty's syndrome⁴³ and in chronic malaria⁴⁴, portal hypertension may be related to lymphocytic infiltration of sinusoids and portal zones as well as nodular hyperplasia⁴⁵.

Increased splenic flow must also be considered. Certainly, in most of the conditions discussed above, including chronic malaria, Felty's syndrome, and schistosomiasis, the splenic flow is very much increased. Patients with portal hypertension may show thickening, sclerosis, and partial thrombosis of the main portal vein radicles. It seems that, in similar fashion to the arterial system, the portal vein may undergo degenerative changes in response to increased flow and pressure. Such increased splenic flow is, however, not thought to be the major factor in maintaining portal hypertension⁴⁶.

Many patients previously diagnosed as suffering from idiopathic portal hypertension may, in fact, have intrahepatic portal venous sclerosis. Post-mortem vinylite injection of the liver followed by corrosion and dissection has shown that some patients so diagnosed during life, and after full investigation including liver biopsy, have such lesions. These include extensive attenuation and occlusion of intrahepatic portal venous branches and organised thrombi⁴⁷. The underlying causes of such portal venous sclerosis are only slowly being identified.

Intrahepatic

Cirrhosis of all types is the most important cause. The obstruction to portal venous flow is at all levels within the liver. The intrahepatic portal vascular bed is distorted and diminished. The hepatic venous radicles and sinusoids are compressed by the regenerating nodules. This nodular obstruction led to the concept of hepatic venous outflow block in cirrhosis. This was supported by the observation that pressure in the main portal vein exceeded that in the wedged hepatic vein and the obstruction was therefore assumed to be sinusoidal. However, later studies show that the wedged hepatic venous pressure and the free portal (umbilical) venous pressure are virtually identical in cirrhosis⁴⁸. This means that the venous stasis extends to the portal in-flow vessels. The concept of simple post-sinusoidal portal hypertension in cirrhosis has been abandoned. The obstruction is now believed to be at all levels from portal zones, through the sinusoids, to the hepatic venous outflow.

Nodular hyperplasia without fibrosis is seen in Felty's syndrome⁴⁵.

Increased hepatic arterial flow remains a controversial factor in portal hypertension. Certainly, hepatic-arterial hypertrophy is well-recognised in cirrhosis. In advanced schistosomiasis this is particularly evident and may account for the continued rise of wedged hepatic venous (sinusoidal) pressure after splenectomy, even when pressure in the main portal vein has fallen⁴⁹.

The Budd-Chiari (hepatic venous obstruction) syndrome results in intra-hepatic portal hypertension at a post-sinusoidal level¹⁰.

Bleeding oesophageal varices

MECHANISM OF RUPTURE

The height of the portal venous pressure seems important⁴⁹. Acid gastro-oesophageal reflux seems an unlikely precipitant, as the gastric contents contain little acid and microscopic examination of the oesophageal mucosa at the time of bleeding shows no signs of oesophagitis⁴⁹. Motility studies of the oesophagus in subjects with cirrhosis showed no difference in lower oesophageal sphincter pressure compared with controls⁵⁰. No differences were found among patients with ascites, variceal haemorrhage, or different degrees of hepatic decompensation. This suggests that the lower oesophageal sphincter function is intact in patients with cirrhosis with or without ascites or oesophageal haemorrhage.

DIAGNOSIS OF BLEEDING

Gastro-oesophageal bleeding in patients with cirrhosis may not be from oesophageal varices. Non-variceal bleeding is particularly frequent in alcoholic patients in whom duodenal ulcers, gastric erosion, and the Mallory-Weiss syndrome are frequent.

Fibrotic oesophagogastrroduodenoscopy will usually visualise the bleeding area if performed within eight hours of the haemorrhage⁵¹. In another series, emergency fibroscopies revealed bleeding lesions in 84 cirrhotic patients⁵². In patients with moderate or no hepatic failure, the commonest actively bleeding sources were oesophagogastric varices and acute mucosal ulcers, associated with the ingestion of anti-inflammatory drugs. In patients with severe hepatic failure, acute mucosal ulcers unrelated to drugs predominated and there was evidence that these were stress-induced erosions.

If bleeding is not seen, diagnostic procedures include measurements of the wedged hepatic venous pressure. In cirrhosis, the wedged hepatic venous pressure is 25 mm above that of the inferior vena cava. Gradients less than this suggest that varices are not the site of haemorrhage or that an unusual non-cirrhotic type of portal hypertension exists⁵³. Similar results are obtained when the portal hepatic gradient was measured by the difference between the free portal pressure measured by the umbilical vein and the free hepatic venous pressure.⁵⁴

Management of bleeding oesophageal varices (Fig. 1)

General principles include the supply of adequate amounts of compatible blood, avoidance of salt-containing infusions, routine intramuscular Vitamin K₁, avoidance of sedation, and the administration of a short course of oral neomycin⁵⁵. Cimetidine should be given routinely to reduce gastric acidity.

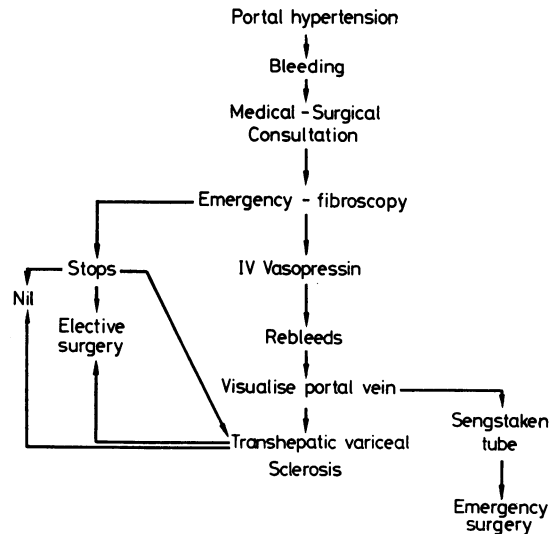


Fig. 1 Steps in the management of bleeding oesophageal varices.

VASOPRESSIN

If bleeding does not stop spontaneously, intravenous vasopressin is given as 20 units in 100 ml glucose over 10 minutes. Alternatively, a continuous infusion of 40 units over 60 minutes may be used. This is said to cause a more prolonged drop in portal blood pressure but less substernal discomfort and abdominal pain⁵⁶. This systemic infusion technique may have a more favourable splanchnic to systemic therapeutic ratio than the high dose intravenous bolus method⁵⁷. Vasopressin may also be infused directly into the mesenteric artery for long periods⁵⁸. A controlled prospective trial of this treatment showed that it effectively stopped haemorrhage from varices and that transfusion requirements were reduced⁵⁹. Survival, however, was not improved. Unfortunately, the Sengstaken tube did not form part of the treatment used in the control of conventionally treated patients. In a further study, 0.2 units vasopressin per minute were infused for 40 to 60 minutes into the superior mesenteric artery and portal blood was sampled through the umbilical vein⁶⁰. Free portal pressure fell but also the portal oxygen content. Systemic effects were noted, including an increase in blood pressure, a fall in cardiac output, and a fall in arterial PO_2 . Vascular thrombosis remains a complication of vasopressin treatment. Finally, in dogs, the haemodynamic effects of intravenous vasopressin do not differ appreciably from those induced by infusion of the same dose into the superior mesenteric artery⁵⁷. The triglyceryl homologue of vasopressin (glypressin) is an active, non-peptide hormone that has a more prolonged action, although of low potency⁶¹. It needs further evaluation. It can be concluded that continuous intravenous vasopressin seems the most suitable method of administration. Controlled trials of this technique versus the intravenous bolus method would be interesting. There is little indication for the intra-arterial technique. It must be recognised, however, that vasopressin has only limited usefulness. It may stop bleeding temporarily but does not improve survival. It must be used in the context of

the whole management of the patient and, in particular, the steps that are to be taken when the patient rebleeds.

SENGSTAKEN OESOPHAGEAL COMPRESSION TUBE

Good results from gastro-oesophageal tamponade are the outcome only of meticulous attention to detail in inserting and positioning the tube. The fourth tube, allowing continuous aspiration of the pharynx above the oesophageal balloon, is particularly important. Although a barium meal does seem to pass the balloons easily⁶², complications are numerous and the tube should be introduced only in specific circumstances. It is particularly useful in transporting a patient to a specialist centre. It may be used as an immediate preliminary to surgery so that resuscitation can take place without continuing haemorrhage. If it is used when vasopressin has failed, it should be inflated continuously for not more than 24 hours. Obstruction to the innominate vein has been described recently⁶³.

PERCUTANEOUS TRANSHEPATIC OBLITERATION OF GASTRO-OESOPHAGEAL VARICES

The main collateral venous supply of the gastro-oesophageal varices can be visualised by percutaneous transhepatic injection of contrast material into them. The veins can then be catheterised and obliterated by injection of human thrombin followed by gelatin foam to stabilise the clot^{6,7,8}. The major indication is in patients with severe decompensated cirrhosis, who have not responded to conservative treatment and in whom, because of liver failure, surgery is contraindicated. After successful obliteration of varices, surgery may be performed electively or deferred indefinitely. Long-term effectiveness of variceal obliteration has not been established. The procedure is well tolerated and easily repeated. Hepatic encephalopathy is not a complication. A controlled prospective trial on its use compared with more conservative methods is needed.

Surgical procedures

The aim is to reduce portal venous pressure, maintain total hepatic and, particularly, portal venous blood flow and, above all, not have a high incidence of complicating hepatic encephalopathy. There is no currently available procedure that fulfils all these criteria satisfactorily.

The traditional end-to-side portacaval shunt certainly prevents bleeding from gastro-oesophageal varices and probably increases survival. In controlled trials, however, the difference in survival is not remarkable and does not reach statistical significance^{64,65,66}. This may be related to selection of patients on the grounds of liver disease and haemorrhage without identifying the source of the bleeding by endoscopy. In randomised prospective trials, severe encephalopathy was more frequent in shunted individuals but not markedly so⁶⁷. It is more frequent with the side-to-side than the end-to-side procedure⁶⁸.

Hepatocellular function deteriorates after shunting⁶⁴ and this has been confirmed in animals. Rats which were given an end-to-side shunt, showed 14 days later a reduction in galactose elimination capacity, plasma indocyanine green clearance, and bromsulphalein transport maximum compared with sham-operated animals. The reduction in these parameters corresponded to a loss of at least 50% of liver mass⁶⁹.

The importance of maintaining portal venous flow, with the hepatotrophic factors that it contains, has already been stressed. The value of hepatic arterial flow is also emphasised⁷⁰. The capacity of the hepatic arterial flow to increase postoperatively may determine morbidity, hospital mortality, and long-term survival in cirrhotic patients given end-to-side or side-to-side portacaval shunts.

In the face of these conflicting results, what shunt should be chosen and when? Despite the aggressive approach adopted by Orloff and his group⁷¹ who operated within 8.5 hours of admission on 158 unselected patients with alcohol-related cirrhosis, usually in liver failure and with 49% operative mortality, emergency shunting is not favoured. Prophylactic shunting is likewise not done, because the time of the first haemorrhage cannot be predicted. The accepted candidate has usually had at least one haemorrhage from proven varices which required blood transfusion, is under 50 years old, and without jaundice, encephalopathy, or ascites. The portal vein has been visualised and is patent. Preoperative diversion of portal blood away from the liver is said to improve the results of portacaval anastomosis. This can be measured by an indicator-dilution technique, injecting into the splenic or superior mesenteric artery. This was done in cirrhotic patients within one week of gastrointestinal bleeding⁷². Those who had bled from varices showed significantly greater portal systemic shunting of both splenic and superior mesenteric blood. Measures of wedged hepatic venous pressure and total blood flow provided no insight into the pattern of shunting.

Surgical aspects of the operations in current use have been reviewed⁷³. All the newer procedures attempt to maintain hepatic blood flow. One operation which maintains flow in the portal vein involves constructing a portacaval shunt and then arterialisising the hepatic portion of the portal vein^{74,75}. This does not of course supply portal-venous blood. It has not been assessed long-term and, in particular, controlled trials of its use have not been undertaken.

The side-to-side portacaval anastomosis preserves continuity of the portal vein with the liver but there is little evidence that much blood flows through it after the operation⁷⁶.

Mesocaval shunt performed with the use of a Dacron 'H' graft⁷⁷ (Fig. 2) is increasing in popularity. It is particularly used in the poor-risk patient and is technically easy. The mortality rate is 9% and the incidence of encephalopathy

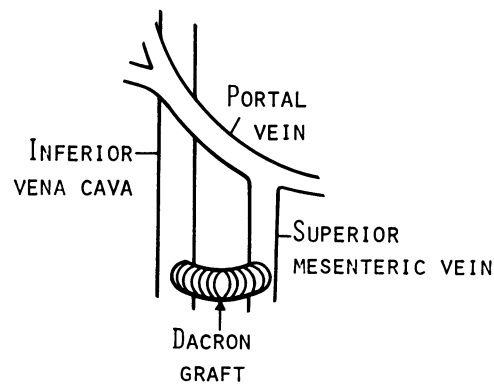


Fig. 2 The Drapanas mesocaval shunt performed with a Dacron graft.

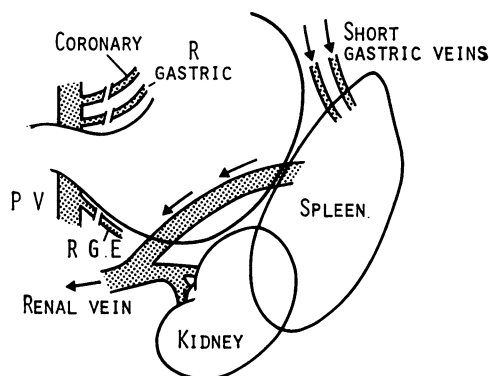


Fig. 3 The Warren distal splenorenal shunt. The aim is to divide veins feeding gastro-oesophageal collaterals (coronary, right gastroepiploic (RGE)) while allowing drainage of portal blood through short gastric veins, spleen, and splenic vein to the renal vein. Portal venous (PV) flow to the liver is preserved.

in 80 patients was 11%⁷⁸. The portal vein remains patent, although the flow through it is uncertain. As the portal blood pressure is maintained, portal flow may well be conserved. Shunt occlusion may follow the use of the graft.

Selective shunt procedures aim at decompression of the varices while maintaining portal venous flow. The most favoured is the distal 'selective' splenorenal shunt, reported by Warren *et al.*⁷⁹ (Fig. 3). This operation has been compared with the Drapanas mesocaval graft procedure in a randomised control trial. Encephalopathy and deterioration of hepatic function were less in the selective group⁸⁰. These are, however, early days. Encephalopathy may not develop for many years after a shunt operation. Moreover, the selected shunt is a technically difficult operation and has a high operative mortality; this is likely to remain the case with all teams who start to use the procedure.

How can one conclude? Perhaps with the words of Conn⁶⁵: 'If I were bleeding from oesophageal varices, I should like to be treated at an academic institution, preferably one where a controlled trial was in progress. I would try to meet the criteria for inclusion since the prognosis of those who do is much better than for those who do not. I would fervently hope to be selected—randomly, of course—for the operative group. Then in the light of previous findings, and with faint heart, I would refuse surgery'.

SHEILA SHERLOCK
The Royal Free Hospital
Pond Street
Hampstead
London NW3

Received for publication 25 July 1977

References

- ¹Viamonte, M. Jr, Warren, W. D., Fomon, J. J., and Martinez, L. O. (1970). Angiographic investigations in portal hypertension. *Surgery, Gynecology, and Obstetrics*, **130**, 37-53.
- ²Kessler, R. E., Tice, D. A., and Zimmon, D. S. (1973). Value, complications and limitations of umbilical vein catheterisation. *Surgery, Gynecology, and Obstetrics*, **136**, 529-535.
- ³Viallet, A., Joly, J-G., Marleau, D., and Lavoie, P. (1970). Comparison of free portal venous pressure and wedged hepatic venous pressure in patients with cirrhosis of the liver. *Gastroenterology*, **59**, 372-375.

- ⁴Reynolds, T. B., Ito, S., and Iwatsuki, S. (1970). Measurement of portal pressure and its clinical application. *American Journal of Medicine*, **49**, 649-657.
- ⁵Boyer, T. D., Triger, D. R., Horisawa, M., Redeker, A. G., and Reynolds, T. B. (1977). Direct transhepatic measurement of portal vein pressure using a thin needle. Comparison with wedged hepatic vein pressure. *Gastroenterology*, **72**, 584-589.
- ⁶Lunderquist, A., and Vang, J. (1974). Transhepatic catheterisation and obliteration of the coronary vein in patients with portal hypertension and esophageal varices. *New England Journal of Medicine*, **291**, 646-649.
- ⁷Viamonte, M. Jr, LePage, J., Lunderquist, A., Pereiras, R., Russell, E., Viamonte, M., and Camacho, M. (1975). Selective catheterisation of the portal vein and its tributaries. *Radiology*, **114**, 457-460.
- ⁸Scott, J., Long, R. G., Dick, R., and Sherlock, S. (1976). Percutaneous transhepatic obliteration of gastro-oesophageal varices. *Lancet*, **2**, 53-55.
- ⁹Webb, L. J., Berger, L. A., and Sherlock, S. (1977). Diagnosis of extrahepatic portal obstruction by grey scale ultrasound. *Gut*. (In press.)
- ¹⁰Tavill, A. S., Wood, E. J., Kreel, L., Jones, E. A., Gregory, M., and Sherlock, S. (1975). The Budd-Chiari syndrome: correlation between hepatic scintigraphy and the clinical, radiological, and pathological findings in nineteen cases of hepatic venous outflow obstruction. *Gastroenterology*, **68**, 509-518.
- ¹¹Redeker, A. G., Horisawa, M., Boyer, T. D., and Reynolds, T. B. (1977). (Unpublished observations.)
- ¹²Sovak, M., Soulen, R. L., and Reichle, F. A. (1971). Blood flow in the human portal vein. A cineradiographic method using particulate contrast medium. *Radiology*, **99**, 531-536.
- ¹³Reichle, F. A., Sovak, M., Soulen, R. L., and Rosemond, G. P. (1972). Portal vein blood flow determination in the unanesthetized human by umbilicportal cannulation. *Journal of Surgical Research*, **12**, 146-150.
- ¹⁴Sherriff, S. B., Smart, R. C., and Taylor, I., (1977). Clinical study of liver blood flow in man measured by ¹³³Xe clearance after portal vein injection. *Gut*, **18**, 1027-1031.
- ¹⁵Kuba, J., and Seidlová, V. (1972). Evaluation of portal circulation by the scintillation camera. *Journal of Nuclear Medicine*, **13**, 689-692.
- ¹⁶Kashiwagi, T., Kamada, T., and Abe, H. (1975). Dynamic studies on the portal hemodynamics by scintiphotosplenoportography: streamline flow in the human portal vein. *Gastroenterology*, **69**, 1292-1296.
- ¹⁷Syrota, A., Vinot, J. M., Paraf, A., and Roucayrol, J. C. (1976). Scintillation splenoportography: hemodynamic and morphological study of the portal circulation. *Gastroenterology*, **71**, 652-659.
- ¹⁸Smith, G. W., Westgaard, T., and Björn-Hansen, R. (1971). Hepatic venous angiography in the evaluation of cirrhosis of the liver. *Annals of Surgery*, **173**, 469-480.
- ¹⁹Moreno, A. H., Burchell, A. R., Reddy, R. V., Steen, J. A., Panke, W. F., and Nealon, T. F. Jr (1975). Spontaneous reversal of portal blood flow: the case for and against its occurrence in patients with cirrhosis of the liver. *Annals of Surgery*, **181**, 346-358.
- ²⁰Gates, G. F., and Dore, E. K. (1973). Streamline flow in the human portal vein. *Journal of Nuclear Medicine*, **14**, 79-83.
- ²¹Groszmann, R. J., Kotelanski, B., and Cohn, J. N. (1971). Hepatic lobar distribution of splenic and mesenteric blood flow in man. *Gastroenterology*, **60**, 1047-1052.
- ²²Kashiwagi, T., Kamada, T., and Abe, H. (1974). Dynamic studies on the portal hemodynamics by scintiphotosplenoportography: the visualisation of portal venous system using ^{99m}Tc. *Gastroenterology*, **67**, 668-673.
- ²³Rous, P., and Larimore, L. D. (1920). Relation of the portal blood to liver maintenance: a demonstration of liver atrophy conditional on compensation. *Journal of Experimental Medicine*, **31**, 609-632.
- ²⁴Child, C. G. III, Barr, D. P., Holswade, G. R., and Harrison, C. S. (1953). Liver regeneration following portacaval transposition in dogs. *Annals of Surgery*, **138**, 600-608.
- ²⁵Starzl, T. E., Marchioro, T. L., Rowlands, D. T. Jr, Kirkpatrick, C. H., Wilson, W. E. C., Rifkind, D., and Waddell, W. R. (1964). Immuno-suppression after experimental and clinical hemotransplantation of the liver. *Annals of Surgery*, **160**, 411-439.
- ²⁶Popper, H. (1974). Implications of portal hepatotrophic factors in hepatology. *Gastroenterology*, **66**, 1227-1233.
- ²⁷Starzl, T. E., Francavilla, A., Halgrimson, C. G., Francavilla, F. R., Porter, K. A., Brown, T. H., and Putnam, C. W. (1973). The origin, hormonal nature, and action of hepatotrophic substances in portal venous blood. *Surgery, Gynecology, and Obstetrics*, **137**, 179-199.
- ²⁸Bucher, N. L. R., and Swaffield, M. N. (1975). Regulation of hepatic regeneration in rats by synergistic action of insulin and glucagon. *Proceeding of the National Academy of Sciences USA*, **72**, 1157-1160.
- ²⁹Starzl, T. E., Watanabe, K., Porter, K. A., and Putnam, C. W. (1976). Effects of insulin, glucagon, and insulin/glucagon infusions on liver morphology and cell division after complete portacaval shunt in dogs. *Lancet*, **1**, 821-825.
- ³⁰Farivar, M., Wands, J. R., Isselbacher, K. J., and Bucher, N. L. R. (1976). Effect of insulin and glucagon on fulminant murine hepatitis. *New England Journal of Medicine*, **295**, 1517-1519.
- ³¹Sherlock, S. (1974). Classification and functional aspects of portal hypertension. *American*

- Journal of Surgery*, **127**, 121-128.
- ³²Zeegeen, R., Stansfeld, A. G., Dawson, A. M., and Hunt, A. H. (1969). Bleeding oesophageal varices as the presenting feature in primary biliary cirrhosis. *Lancet*, **2**, 9-13.
- ³³Kew, M. C., Varma, R. R., Dos Santos, H. A., Scheuer, P. J., and Sherlock, S. (1971). Portal hypertension in primary biliary cirrhosis. *Gut*, **12**, 830-834.
- ³⁴Morris, J. S., Schmid, M., Newman, S., Scheuer, P. J., and Sherlock, S. (1974). Arsenic and non-cirrhotic portal hypertension. *Gastroenterology*, **66**, 86-94.
- ³⁵Huet, P. M., Guillaume, E., Côté, J., Légaré, A., Lavoie, P., and Viallet, A. (1975). Non-cirrhotic presinusoidal portal hypertension associated with chronic arsenical intoxication. *Gastroenterology*, **68**, 1270-1277.
- ³⁶Datta, D. V. (1976). Arsenic and non-cirrhotic portal hypertension (Letter). *Lancet*, **1**, 433.
- ³⁷Datta, D. V. (1977). Arsenic in opium (Letter). *Lancet*, **1**, 484.
- ³⁸Datta, D. V., and Kaul, M. K. (1976). Arsenic content of drinking water in villages in Northern India. A concept of arsenicosis. *Journal of the Association of Physicians of India*, **24**, 599-604.
- ³⁹Pimentel, J. C., and Menezes, A. P. (1977). Liver disease in vineyard sprayers. *Gastroenterology*, **72**, 275-283.
- ⁴⁰Thomas, L. B., Popper, H., Berk, P. D., Selikoff, I., and Falk, H. (1975). Vinyl-chloride-induced liver disease. From idiopathic portal hypertension (Banti's syndrome) to angiosarcomas. *New England Journal of Medicine*, **292**, 17-22.
- ⁴¹Smith, P. M., Crossley, I. R., and Williams, D. M. J. (1976). Portal hypertension in vinyl-chloride production workers. *Lancet*, **2**, 602-604.
- ⁴²Schaffner, F., Popper, H., and Selikoff, J. (1976). Initial features of vinyl chloride (VC) hepatic injury (Abstract). *Gastroenterology*, **71**, 928.
- ⁴³Blendis, L. M., Ansell, I. D., Lloyd-Jones, K., Hamilton, E., and Williams, R. (1970). Liver in Felty's syndrome. *British Medical Journal*, **1**, 131-135.
- ⁴⁴Butler, T., Boyer, J. L., Farrell, R. L., Goldstein, H. M., Schaeffer, B. T., and Loan, N. T. (1973). Chronic splenomegaly in Vietnam, II. The role of liver disease and portal vein obstruction in pathogenesis. *American Journal of Tropical Medicine and Hygiene*, **22**, 6-13.
- ⁴⁵Reisman, T., Levi, J. U., Zeppa, R., Clark, R., Morton, R., and Schiff, E. R. (1977). Non-cirrhotic portal hypertension in Felty's syndrome. *American Journal of Digestive Diseases*, **22**, 145-148.
- ⁴⁶Gitlin, N., Grahame, G. R., Kreef, L., Williams, H. S., and Sherlock, S. (1970). Splenic blood flow and resistance in patients with cirrhosis before and after portacaval anastomoses. *Gastroenterology*, **59**, 208-213.
- ⁴⁷Boyer, J. L., Hales, M. R., and Klatskin, G. (1974). 'Idiopathic' portal hypertension due to occlusion of intrahepatic portal veins by organised thrombi. *Medicine (Balt.)*, **53**, 77-91.
- ⁴⁸Alves, C. A. P., Alves, A. R., Abreu, W. N., and Andrade, Z. A. (1977). Hepatic artery hypertrophy and sinusoidal hypertension in advanced schistosomiasis. *Gastroenterology*, **72**, 126-128.
- ⁴⁹Orloff, M. J., and Thomas, H. S. (1963). Pathogenesis of esophageal varix rupture. A study based on gross and microscopic examination of the esophagus at the time of bleeding. *Archives of Surgery*, **87**, 301-307.
- ⁵⁰Eckardt, V. F., Grace, N. D., and Kantrowitz, P. A. (1976). Does lower oesophageal sphincter incompetency contribute to esophageal variceal bleeding? *Gastroenterology*, **71**, 185-189.
- ⁵¹Mitchell, C. J., and Jewell, D. P. (1977). The diagnosis of the site of upper gastrointestinal haemorrhage in patients with established portal hypertension (Abstract). *Gut*, **17**, 833-834.
- ⁵²Franco, D., Durandy, Y., Deporte, A., and Bismuth, H. (1977). Upper gastrointestinal haemorrhage in hepatic cirrhosis: causes and relation to hepatic failure and stress. *Lancet*, **1**, 218-220.
- ⁵³Reynolds, T. B. Jr, and Redeker, A. G. (Unpublished observations.)
- ⁵⁴Viallet, A., Marleau, D., Huet, M., Martin, F., Farley, A., Villeneuve, J. P., and Lavoie, P. (1975). Hemodynamic evaluation of patients with intrahepatic portal hypertension. Relationship between bleeding varices and the portohepatic gradient. *Gastroenterology*, **69**, 1297-1300.
- ⁵⁵Sherlock, S. (1975). Portal venous system and portal hypertension. Emergency treatment, in *Diseases of the Liver and Biliary System*, p. 192. 5th ed. Blackwell: Oxford.
- ⁵⁶Thomford, N. R., Sirinek, K. R., and Martin, E. W. Jr (1975). A series of 20 successful Warren shunts. *Archives of Surgery*, **110**, 584-587.
- ⁵⁷Barr, J. W., Lakin, R. C., and Rösch, J. (1975). Similarity of arterial and intravenous vasopressin on portal and systemic hemodynamics. *Gastroenterology*, **69**, 13-19.
- ⁵⁸Baum, S., and Nusbaum, M. (1971). The control of gastrointestinal hemorrhage by selective mesenteric arterial infusion of vasopressin. *Radiology*, **98**, 497-505.
- ⁵⁹Conn, H. O., Ramsby, G. R., Storer, E. H., Mutchnick, M. G., Joshi, P. H., Phillips, M. M., Cohen, G. A., Fields, G. N., and Petroski, D. (1975). Intra-arterial vasopressin in the treatment of upper gastro-intestinal hemorrhage: a prospective, controlled clinical trial. *Gastroenterology*, **68**, 211-221.
- ⁶⁰Millette, B., Huet, P. M., Lavoie, P., and Viallet, A. (1975). Portal and systemic effects of selective infusion of vasopressin into the superior mesenteric artery in cirrhotic patients. *Gastroenterology*, **69**, 6-12.
- ⁶¹Vosmik, J., Jedlička, K., Mulder, J. L., and Cort, J. H. (1977). Action of the triglycyl hormo-

- nogen of vasopressin (glypressin) in patients with liver cirrhosis and bleeding esophageal varices. *Gastroenterology*, **72**, 605-609.
- ⁶²Andersen, J. R., and Agger, P. (1976). Passage of barium meal through esophagus in patients with balloon-tamponade of esophageal varices. *Scandinavian Journal of Gastroenterology*, **11**, 561-563.
- ⁶³Juffé, A., Tellez, G., Eguaras, M. G., Villagra, F., and Figuera, D. (1977). Unusual complication of the Sengstaken-Blakemore tube. *Gastroenterology*, **72**, 724-725.
- ⁶⁴Resnick, R. H., *et al.*, and the Boston Inter-Hospital Liver Group (1969). A controlled study of the prophylactic portacaval shunt—a final report. *Annals of Internal Medicine*, **70**, 675-688.
- ⁶⁵Conn, H. O. (1974). Therapeutic portacaval anastomosis: to shunt or not to shunt. *Gastroenterology*, **67**, 1065-1071.
- ⁶⁶Rueff, B., Prandi, D., Degos, F., Sicot, J., Degos, J.-D., Sicot, C., Maillard, J.-N., Fauvert, R., and Benhamou, J.-P. (1976). A controlled study of therapeutic portacaval shunt in alcoholic cirrhosis. *Lancet*, **1**, 655-659.
- ⁶⁷Mutchnick, M. G., Lerner, E., and Conn, H. O. (1974). Portal-systemic encephalopathy and portacaval anastomosis: a prospective, controlled investigation. *Gastroenterology*, **66**, 1005-1019.
- ⁶⁸Iwatsuki, S., Mikkelsen, W. P., Redeker, A. G., Reynolds, T. B., and Turrill, F. L. (1971). Clinical comparison of the end-to-side and side-to-side portacaval shunt. *Annals of Surgery*, **178**, 65-69.
- ⁶⁹Lauterburg, B. H., Sautter, V., Preisig, R., and Bircher, J. (1976). Hepatic functional deterioration after portacaval shunt in the rat. *Gastroenterology*, **71**, 221-227.
- ⁷⁰Burchell, A. R., Moreno, A. H., Panke, W. F., and Nealon, T. F. Jr (1976). Hepatic artery flow improvement after portacaval shunt. *Annals of Surgery*, **184**, 289-302.
- ⁷¹Orloff, M. J., Charters, A. C., III., Chandler, J. G., Condon, J. K., Grambort, D. E., Modafferi, T. R., Levin, S. E., Brown, N. B., Sviokla, S. C., and Knox, D. G. (1975). Portacaval shunt as emergency procedure in unselected patients with alcoholic cirrhosis. *Surgery, Gynecology, and Obstetrics*, **141**, 59-68.
- ⁷²Lebrec, D., Kotelanski, B., and Cohn, J. N. (1976). Splanchnic hemodynamics in cirrhotic patients with esophageal varices and gastrointestinal bleeding. *Gastroenterology*, **70**, 1108-1111.
- ⁷³Marks, C. (1976). The anatomical basis for portal decompressive surgery. *Annals of the Royal College of Surgeons of England*, **58**, 293-299.
- ⁷⁴Maillard, J.-N., Benhamou, J.-P., and Rueff, B. (1970). Arterialisation of the liver with portacaval shunt in the treatment of portal hypertension due to intrahepatic block. *Surgery (St. Louis)*, **67**, 883-890.
- ⁷⁵Adamsons, R. J., Kinkhabwala, M., Moskowitz, H., Himmelfarb, E., Minkowitz, S., and Lerner, B. (1972). Portacaval shunt with arterilization of the hepatic portion of the portal vein. *Surgery, Gynecology, and Obstetrics*, **135**, 529-535.
- ⁷⁶Redeker, A. G., Kunelis, C. T., Yamamoto, S., and Reynolds, T. B. (1964). Assessment of portal and hepatic haemodynamics after side-to-side portacaval shunt in patients with cirrhosis. *Journal of Clinical Investigation*, **43**, 1464-1471.
- ⁷⁷Drapanas, T. (1972). Interposition mesocaval shunt for treatment of portal hypertension. *Annals of Surgery*, **176**, 435-448.
- ⁷⁸Drapanas, T., LoCicero, J. III., and Dowling, J. B. (1975). Hemodynamics of the interposition mesocaval shunt. *Annals of Surgery*, **181**, 523-533.
- ⁷⁹Warren, W. D., Zeppa, R., and Fomon, J. J. (1976). Selective trans-splenic decompression of gastroesophageal varices by distal splenorenal shunt. *Annals of Surgery*, **166**, 437-455.
- ⁸⁰Galambos, J. T., Warren, W. D., Rudman, D., Smith, R. B., III., and Salam, A. A. (1976). Selective and total shunts in the treatment of bleeding varices. *New England Journal of Medicine*, **295**, 1089-1095.