

⁷⁵Se-selenomethionine scanning in the diagnosis of tumours of the pancreas and adjacent viscera: The use of the test and its impact on survival

DENIS M. McCARTHY,¹ PAMELA BROWN,² R. N. MELMED,³ J. E. AGNEW,
AND I. A. D. BOUCHIER⁴

From the Departments of Medicine and Physics of the Royal Free Hospital, London, and the Department of Gastroenterology of the Central Middlesex Hospital, London

SUMMARY The results of pancreatic scanning with ⁷⁵Se-selenomethionine in 393 carefully documented patients over a two-year period are presented. On follow up 50 patients had operatively proven malignant tumours in the gland and a further 22 had similar tumours in adjacent organs, clinically mimicking carcinoma of the pancreas and in many cases causing scan abnormalities. Five patients had pancreatic adenomata. Remote tumours rarely affected the scan. Examination of the role of scanning in patients with neoplastic disease revealed that the test was effective in screening and in detection; false negative diagnoses were rare. By contrast, survival following diagnosis was extremely poor with only 8% of pancreatic tumours resectable and 50% metastasized at the time of surgery. Causes of pancreatic dysfunction, other than pancreatitis or carcinoma, which were associated with abnormalities on the scan are described and general aspects of reporting on the scan are discussed. The patterns seen in abnormal scans, while non-specific with regard to aetiology, were anatomically meaningful and useful adjuncts to the diagnosis of pancreatic disease. A normal scan excluded pancreatic cancer with a probability greater than 95%.

Following the development of successful pancreatic scanning in human subjects injected with ⁷⁵Se-selenomethionine (Blau and Bender, 1962) a large number of papers were published on its clinical value. Up to the inception of the present studies in 1967 over 40 reports had been published from various centres. Some commented favourably on the technique (Sodee, 1966; Swyngedaauw, Tacquet, Foissac-Gegoux, and Huart, 1967; Centi Colella and Pigorini, 1967; Kakehi, Tateno, Uchiyama, and Tsuchiya, 1967; Riccobono, 1968; Steinoff and Pabst, 1968); others commented unfavourably (Zuidema, Kirsh, Turcotte, Gaisford, Powers, and Kowalczyk, 1963; Burke and Goldstein, 1964; Aronsen, Gynning, and Walderskog, 1965; King,

Sharpe, Grubb, Brock, and Greenberg, 1966). The majority of these papers were characterized by descriptive rather than quantitative evaluation of the procedure. There was no standardized scanning technique or generally accepted method of patient preparation. Lack of adequate clinical investigation of the scanned patients, especially where the test was in error or equivocal, combined with premature pronouncements on specific patterns of abnormality in various conditions led to generally conflicting views about the value of the test.

In only seven centres had more than 50 patients been scanned (Blau, 1964; Lähdevirta, Räsänen, and Haikonen, 1966; Rodríguez-Antúnez, Filson, Sullivan, and Brown, 1966; Sodee, 1966; Centi Colella and Pigorini, 1967; Kaplan, Ben-Porath, Fink, Clayton, and Jacobson, 1967; Swyngedaauw *et al*, 1967); these included scans performed before overcoming the technical problems posed by the procedure, and included incompletely investigated normal and abnormal subjects. Many of these reports on larger series nevertheless commented that the usefulness of the test increased markedly with

¹Present address: GI Research Lab 151-M2, V.A. Hospital, 4150 Clement St, San Francisco, Cal 94121, USA

²Present address: Department of Medicine, University of Auckland, New Zealand

³ Present address: Courtauld Institute of Biochemistry, London, W1

⁴Requests for reprints should be sent to I.A.D.B., Department of Medicine, Royal Free Hospital, London, WC1X 8LF

Received for publication 8 December 1971.

experience in the technique and in reporting on the results (Burdine and Haynie, 1965; Rodríguez-Antúnez *et al.*, 1966; Sodee, 1966; Centi Colella and Pigorini, 1967; Swyngedauw *et al.*, 1967). Most of the published papers, while concentrating on scanning in carcinoma, gave little indication of the incidence of the various patterns of scan abnormality associated with malignant disease or their relationship to the size or site of the tumour. The specificity of such abnormalities needed clarification, as did their associations with non-neoplastic diseases, a frequent source of 'false-positive' diagnoses.

Many of the early papers tended to equate the finding of localized 'cold' areas or 'filling defects' on the scan with the presence of carcinoma and 'generalized reduction of uptake' throughout the pancreas scan with pancreatitis, but gradually it has become apparent that there are many pitfalls in this type of thinking. The present paper describes the common patterns of scan abnormality associated with tumours, their incidence, and their relationship to the operative findings, symptoms, and subsequent survival of the patient. Patients with neoplastic disease are reviewed in the context of a large sample where non-neoplastic pancreatic disease was common. Other aspects of this study have already been published (Melmed, Agnew, and Bouchier, 1968; Agnew, McCarthy, Melmed, and Bouchier, 1969; McCarthy and Brown, 1969; McCarthy, Kreel, Agnew, and Bouchier, 1969; McCarthy, 1970, 1972): in the present paper attention is concentrated on the value of scanning patients with neoplastic disease.

Methods

PATIENT SELECTION

Four hundred and twenty-one patients suspected of having pancreatic disease were referred from 29 hospitals in the London area over a two-year period. Subsequently 28 (6.6%) were lost to follow up. The remaining 393 patients have all been observed for at least six months and many for up to two and a half years, at six-monthly intervals. Of 60 patients with primary malignant tumours in or impinging on the gland, survival data have been obtained in 57.

INVESTIGATION

A detailed history and physical examination was performed by one of the authors in every case and recorded. Scans were performed only when simpler routine methods had first been carried out and the problem defined. The following tests were performed routinely: stool test for occult blood, serum amylase, serum calcium, glucose tolerance test (50 g oral), plain radiograph of the abdomen, and a barium meal examination. Liver function studies were

performed in patients with icterus, pruritus, hepatomegaly, ascites, or other specific indication. Similarly faecal fat excretion was studied only when the history suggested stool abnormality or when weight loss had been marked. More specialized tests were performed when specifically indicated and are listed in Table I. These more specialized tests were generally carried out at either the Central Middlesex or Royal Free Hospitals, irrespective of the referring hospital. All relevant data from each patient were coded and transferred to 105-hole punch cards (Paramount 30673.R) in order to allow analysis of multiple variables in the group as a whole.

Investigation	No. of Patients
Cholangiography	169
Liver biopsy	130
Hypotonic duodenography	124
Pancreatic enzyme/HCO ₃ ⁻ output	86
Pancreatic angiography	36
Transhepatic cholangiography	33
Duodenal cytology	10
Lymphangiography	8

Table I *Supplementary specialized investigations*

DEFINITIVE DIAGNOSIS

In the group as a whole (393 patients) an examination of the pancreas was made at laparotomy in 216 and at necropsy in nine: biopsies of metastatic lesions were obtained in two cases. Thus a definitive diagnosis was made in 57% of the patient sample and in all of those diagnosed as suffering from neoplastic disease.

PATIENT SAMPLE

On the basis of all available data the patients were finally allocated to the diagnostic categories indicated in Table II. It can be seen that in addition to 55

Normal patients	79
Pancreatitis	133
Neoplastic disease (1) Pancreas	55
(2) Adjacent organs	22
Miscellaneous diagnoses	104
Total	393

Table II *Diagnostic groups included in study*

patients with tumours originating within the gland substance (48 primary, two secondary, five adenomata), there were 22 others thought clinically to have pancreatic tumours but subsequently shown to have tumours in adjacent organs. The sites of these tumours are given in Table III.

SCAN REPORTING

The scanning methods employed have been described

Pancreas (55)		
Primary	Head	32
	Body	15
	Tail	1
Secondary	Body	1
	Tail	1
Adenomata	Head	1
	Tail	4
Periampullary-duodenal (7)		7
Common bile duct (7)	Low	5
	High	2
Hepatic ducts (4)		4
Gall bladder (2)		2
Liver (2)		
Hepatoma		1
Haemangiosarcoma		1
Total		77

Table III Distribution of neoplasms

in previous communications (McCarthy and Brown, 1969; McCarthy *et al*, 1969). In these papers it has been pointed out that no pattern of scan abnormality is unique to pancreatic carcinoma, though in the context of the particular case certain patterns may be suggestive of it. Reporting on the scans was always carried out as a two-stage procedure: first, the scan was assessed blindly and classed as 'normal' or 'abnormal'; secondly, the appearance was interpreted in the light of the total clinical, biochemical, radiological, and physical data available, the patient's case being reviewed in detail at the time of reporting. Finally this information, with a comment on its probable significance, was communicated to the referring clinician. Reporting was routinely performed by a physician and a physicist working in a joint session. Some variants of the normal pancreas scan are presented in Figure 1.

Results

CARCINOMA OF THE HEAD OF THE PANCREAS (32 CASES)

There are only two features of the scan which were commonly noted in association with carcinoma. The first and commonest was a generalized reduction in uptake throughout the gland and variable in severity. This abnormality is illustrated in Figure 2. This appearance is non-specific. Its cause must be determined by the referring clinician. In carcinoma of the pancreas the majority of such generalized abnormalities were graded 'moderate' or 'severe'. A typical scan is shown in Figure 3. A generalized abnormality of this kind was found in 19 of 32 patients with tumours in the head of the gland: the majority of these appeared to have had blocked pancreatic ducts and distal abnormality of the gland at surgery. Alternatively there may be a localized 'cold area' in the head of the gland, of the type shown in Figure 4. This type of localized reduction in uptake

in the head, irrespective of the appearance in the remainder of the gland, was found in 12 (37%) of the 32 cases. In the whole series (393 cases) a localized abnormality was found on the scan in 23 out of 77 cases of malignant disease, in 17 out of 133 cases of pancreatitis, and in a small number of rare conditions. Thus while a localized abnormality may be suggestive of the presence of a tumour it was by no means specific. Furthermore, a generalized abnormality was almost twice as commonly seen as was a local one in patients with neoplastic disease.

The pattern of abnormality was not related to tumour size. The smallest lesion detected was 2.5 cm in diameter, 13 tumours were between 2.5 and 8.0 cm, and the rest were very large tumours. Only one tumour was resectable and 13 had metastasized at the time of surgery. One patient with a carcinoma of the head of the gland had a scan rendered uninterpretable because of hepatomegaly.

CARCINOMA OF THE BODY OF THE PANCREAS (15 CASES)

The high incidence in normals of a localized reduction in isotopic uptake occurring in the body of the gland greatly reduced the possibility of interpreting the significance of small filling defects in this area. This type of abnormality appeared to increase with age and in some cases may have been related to ectasia of the aorta (Fig. 5). Hence, such defects were regarded with uncertainty unless they were 'punched out', had well marked irregular edges, or were totally circumscribed, points which favoured their being due to genuine disease. Such a defect is shown in Figure 6. This scan was reported as showing 'thinning in the body, which was probably within normal limits: the referring clinician thought otherwise and at laparotomy a carcinoma 2.5 cm in diameter was resected successfully. Purely on the scan appearance, this report should probably remain unchanged: in the context of the particular patient, who was a thin, 45-year-old male with classical pain, the clinician rightly decided to pursue the matter further. In retrospect this turned out to be an infrequent problem to the reporter as most tumours of the body were large at the time of presentation and large filling defects could be diagnosed with confidence as due to space-occupying lesions—not always carcinomata but generally so. Such a scan is shown in Figure 7. This type of 'filling defect' was found in seven of the 15 cases. A generalized reduction in uptake involving the whole gland was found in the remaining seven.

The tumour which was missed (Fig. 6) was 2.5 cm in diameter. The other 14 tumours were all greater than 8.0 cm in diameter: 11 had metastasized at the time of surgery and only two were resectable.

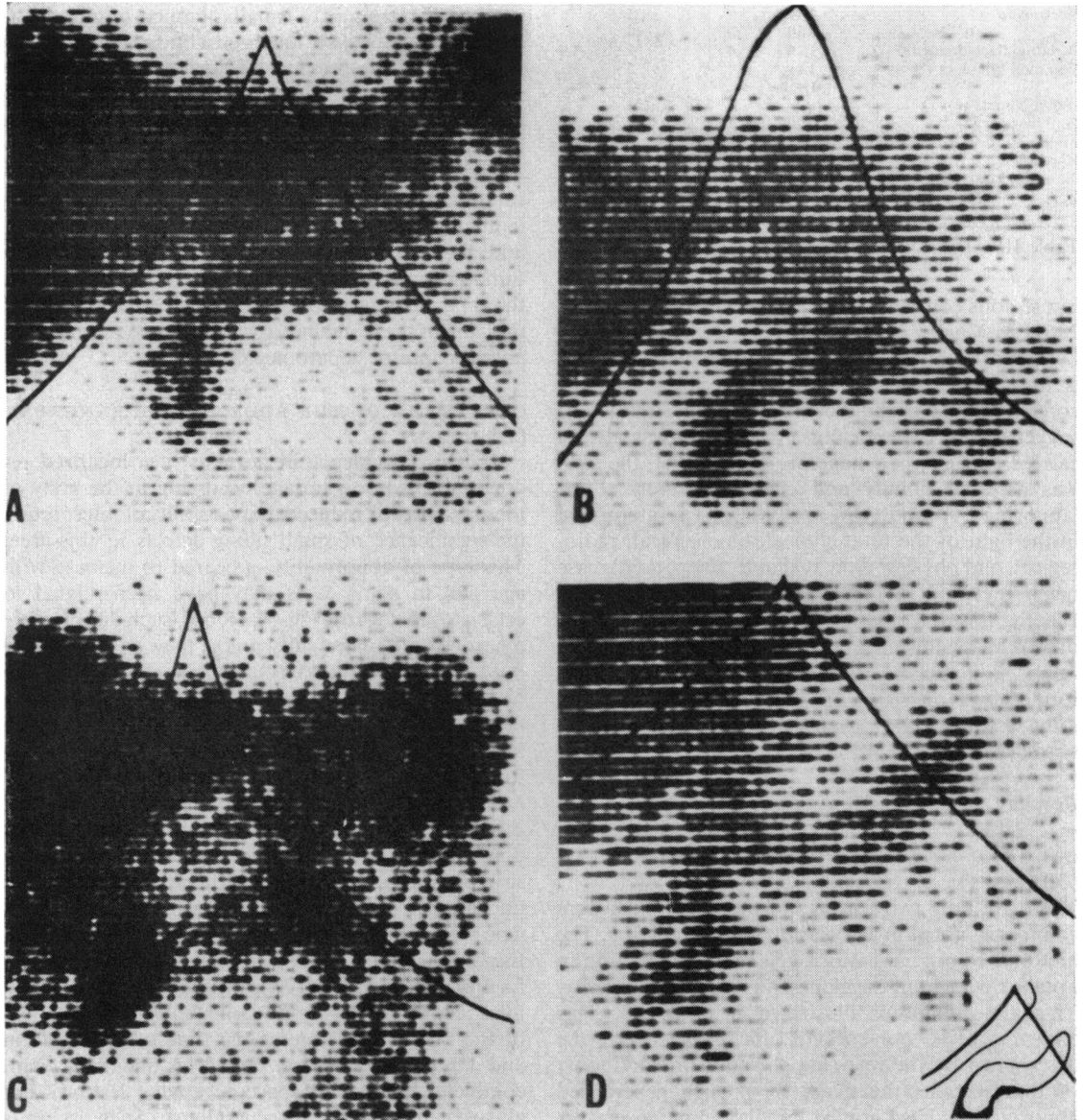


Fig. 1 Normal variants of pancreas scan. A = 'Pistol shaped', variable angulation. B = 'Horseshoe' variant. C = 'Bilobed' pancreas: bowel emission. D = 'Sigmoid' variant.

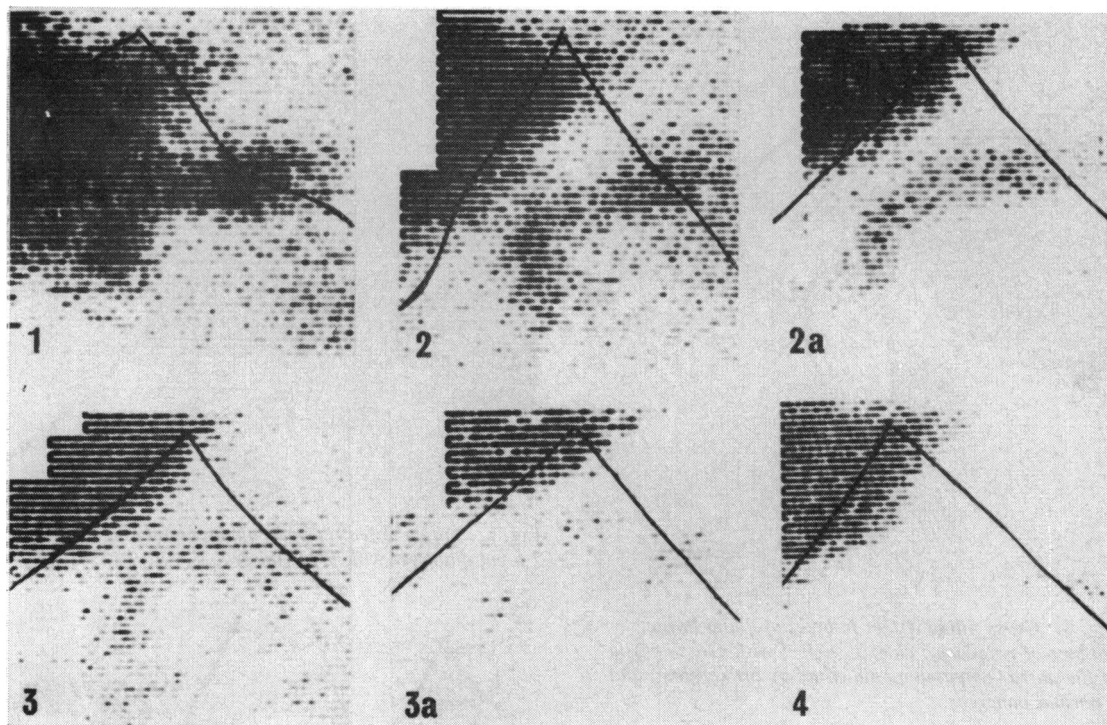


Fig. 2 A normal scan (1) shown for comparison with abnormal scans demonstrating 'mild' (2 to 2a), 'moderate' (3 to 3a), and 'severe' (4) generalized reductions in isotopic uptake by the pancreas: non-specific changes.

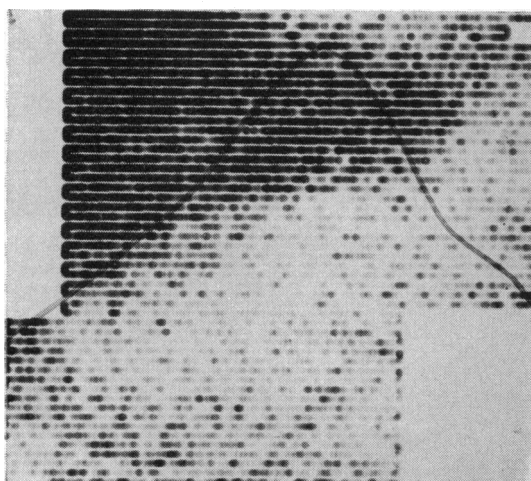


Fig. 3 Generalized reduction of uptake of ⁷⁵Se in a case of carcinoma of the head of the pancreas. Liver clearly seen in top left.

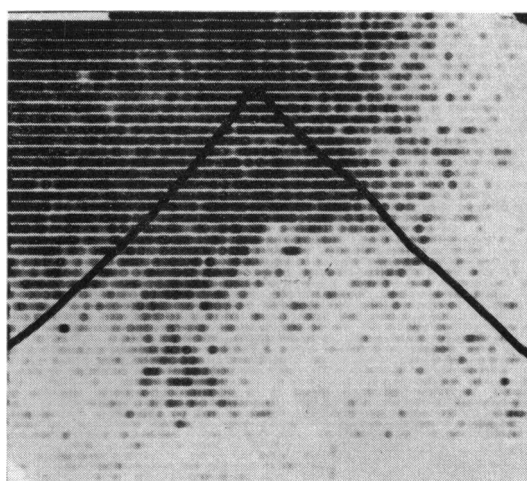


Fig. 4 Localized abnormality or 'filling defect' in the head due to carcinoma: pancreas adjacent to liver but easily seen.

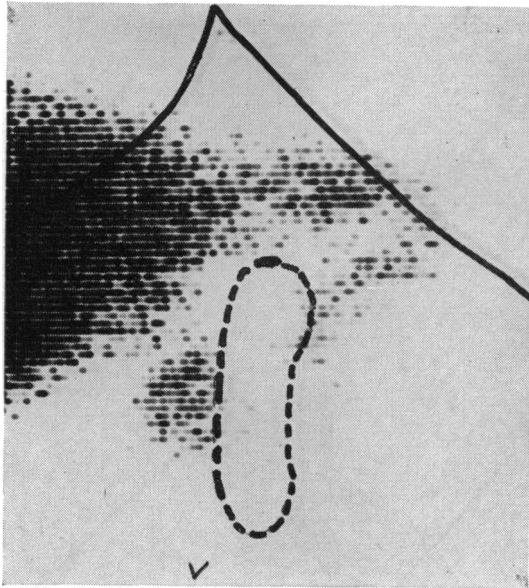


Fig. 5 Gross filling defect in body of gland in the absence of neoplasia: elderly subject with gross ectasia of the aorta (palpated as indicated by broken line) and a normal pancreas.

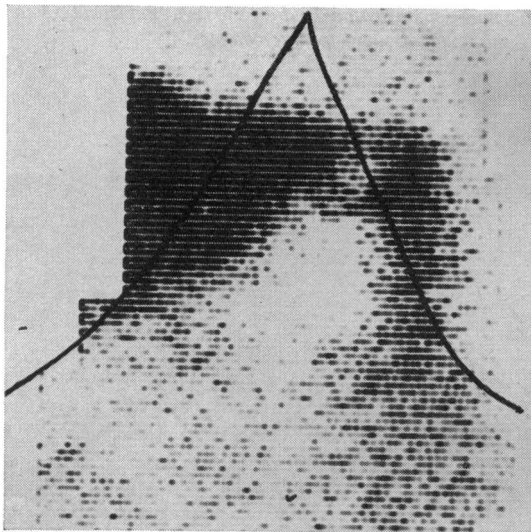


Fig. 7 Large filling defect in body of the gland due to a tumour.

Fig. 8 Two ^{76}Se scans from patient with carcinoma of the tail of the pancreas. A = Scan at narrow energy window. B = Scan at broad energy window. Bifid appearance of tail enclosing an area of low uptake, unusual at this site.

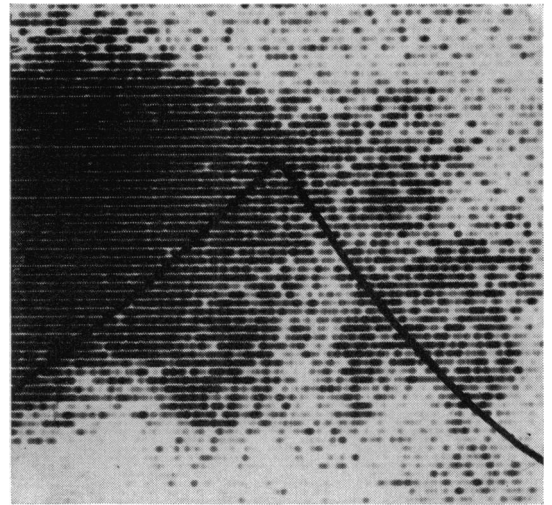


Fig. 6 Filling defect in body of the gland due to tumour 2.5 cm diameter which was missed.

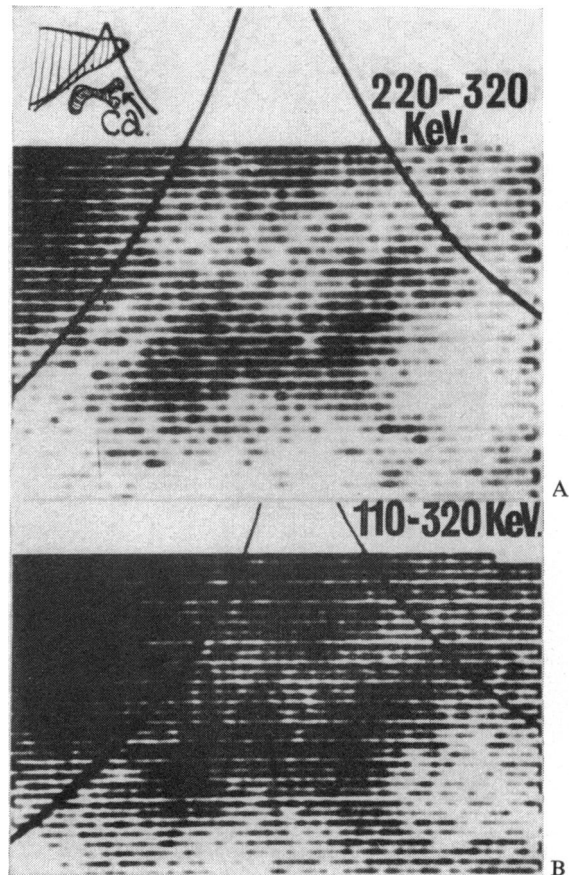


Fig. 8.

CARCINOMA OF THE TAIL (ONE CASE)

There was only one such case in the series and it was correctly diagnosed as a tumour. The scan is shown in Figure 8. The initial impression was that of a normal 'sigmoid' pancreas with some bowel uptake just below the tail. However, to the left of the tail and above the bowel, an area of low uptake was seen—very surprising at this site. Because of the greater depth of the tail of the gland, with consequent deterioration in counting statistics, the patient was rescanned at a wide energy-window (110-320 KeV). The area of low activity of the tail was again noted, with a higher degree of contrast. For this reason it was thought to be significant and reported 'probable carcinoma'. However, a large number of phantom studies provided no rational basis for including this technical modification as a routine.

The tumour was 4.0 cm in diameter, had metastasized, and was not resected because of invasion of the posterior abdominal wall.

METASTASES (TWO CASES)

One small superficial metastasis from a carcinoma of the rectum located on the surface of the tail of the gland was associated with a normal scan. One larger metastasis in the body from a gastric neoplasm was associated with a large filling defect and diagnosed from the scan as a pancreatic tumour. From the scanning point of view this may be regarded as a correct diagnosis.

PERIAMPULLARY DUODENAL TUMOURS

(SEVEN CASES): EXTRAHEPATIC OBSTRUCTION
Seven tumours appeared to originate in the duodenal

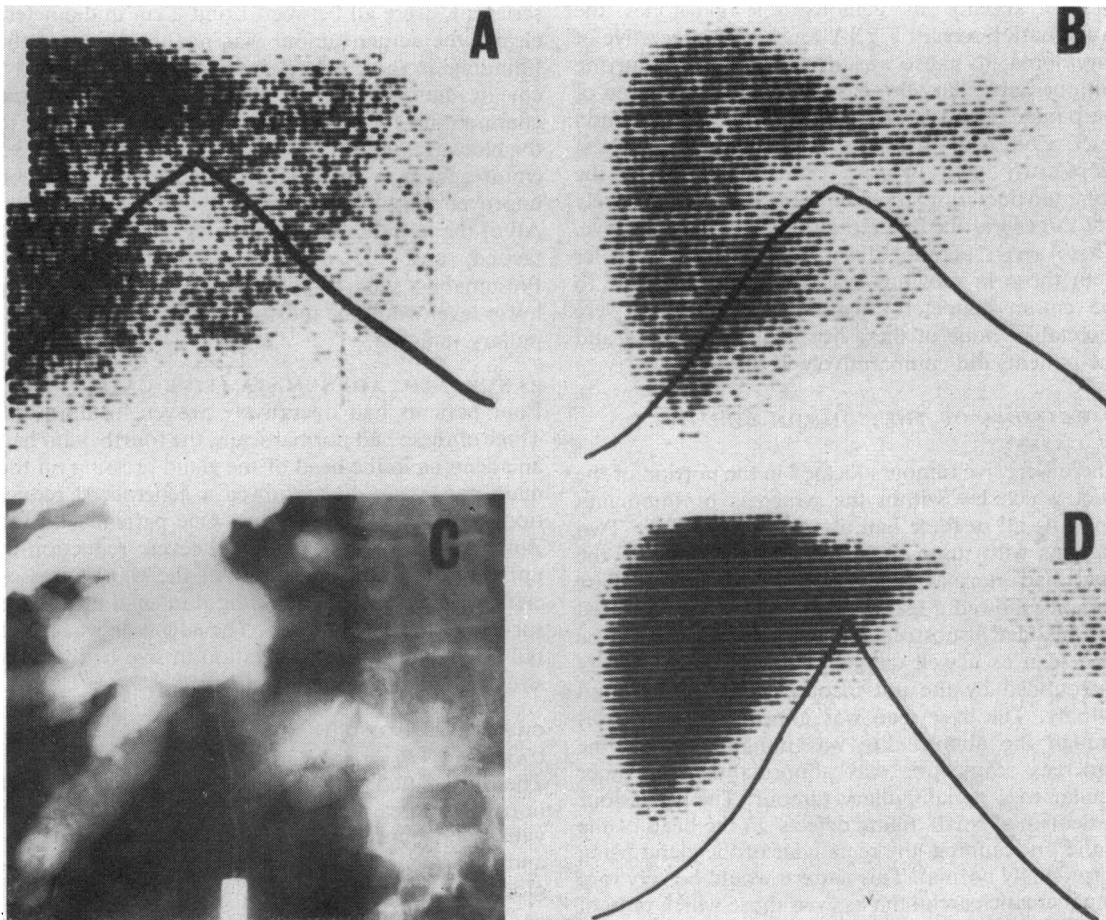


Fig. 9 Findings in extrahepatic obstructive jaundice. A: ⁷⁵Se scan, poor pancreatic uptake with hepatic hilar filling defect. B: ¹⁹⁸Au liver scan, same patient. C: Percutaneous cholangiogram with dilated duct radicals. D: Repeat of B. three months after operative resection of periampullary tumour with choledocho-jejunostomy.

mucosa at the ampulla. Tumours in this site all gave rise to a combination of abnormalities: first, there was a generalized reduction of uptake throughout the gland of variable severity (Fig. 2); secondly, hepatomegaly was noted on the liver scan: all of the patients were jaundiced. This combination suggested periampullary obstruction irrespective of cause, be it tumour, stone, parasite, etc. In half of such cases the liver scan showed a well marked 'hilar' filling defect, illustrated in Figure 9 (A, B). This was due to dilatation of the intrahepatic bile ducts (Fig. 9C) and was common, occurring in 48 out of 393 scanned patients of whom 20 had benign causes such as gallstones, and 28 had malignant obstructions. The filling defect was generally more marked in patients with malignant disease. It was reversible when the obstruction was relieved surgically, irrespective of aetiology (Fig. 9D). Its main importance lies in not confusing the appearance with intrahepatic secondary deposits. In the absence of demonstrable gallstones the combination seen in Fig 9A was highly suggestive of carcinoma: its cause was always surgical, occurring with periampullary tumours, tumours of the head of the pancreas, and rarely with tumours of the common duct. Combination of the scan with a Lundh test (McCarthy and Brown, 1969) may enable the common duct tumours to be predicted preoperatively but in general the differential diagnosis is operative. These seven periampullary tumours were smaller than those in previous sections ranging from 1 to 6.5 cm in diameter (mean = 3.0 cm). Five were resectable: none of these five had metastasized and the patients did comparatively well.

CARCINOMA OF THE COMMON BILE DUCT (7 CASES)

There were five tumours located in the portion of the duct which lay within the pancreas or impinging upon it: all of these had abnormal ^{75}Se scans. Two patients with tumours in the upper portion of the duct had normal pancreas scans. One of these patients showed a 'gall bladder effect': the enlarged gall bladder of obstructive jaundice was seen on the ^{75}Se scan as a well defined area of absent activity surrounded by the not inconsiderable background activity. The liver scan was abnormal in all cases though the abnormality was non-specific. Of the pancreas scans, one was abnormal in a manner similar to a periampullary tumour. The other four patients had small 'filling defects' in the head of the gland on scanning, the remainder of the gland being surprisingly normal. This pattern would be very rare in pancreatic carcinoma as even those which present as 'filling defects' on the scan are usually associated with some generalized abnormality in the gland. This pattern is illustrated in Figure 10.

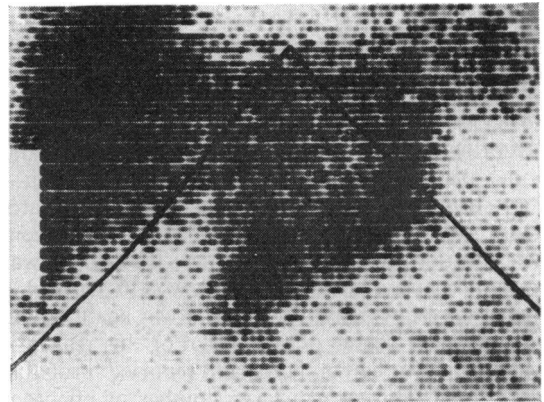


Fig. 10 Filling defect in the head of the pancreas, carcinoma of the lower end of common bile duct.

These tumours were the smallest in the whole series and were all between 1 and 2 cm in diameter: clearly the actual tumour was not the cause of the 'thinning' in the head which was generally 2.5 to 3.5 cm in diameter. However, in all the cases the common bile duct was markedly dilated proximal to the blockage, the duct diameters measuring 2.0 to 3.5 cm at operation and it seemed likely but remained unproven that this was the cause of the abnormality. All of the tumours were resectable, none had metastasized, and the patients did reasonably well. Presumably, such tumours occurring at a slightly lower level would be indistinguishable from periampullary tumours.

PANCREATIC ADENOMATA (FIVE CASES)

Four patients had operatively proven insulinomas. Three of these had normal scans, the fourth, who had an adenoma in the head of the gland pressing on the main pancreatic duct, showed a generalized reduction in uptake of the isotope. One patient with the Zollinger-Ellison syndrome had severe reduction in uptake in the head and body of the gland in association with a large penetrating duodenal ulcer with surviving activity in the tail. The adenoma was in the tail but there was no correlation in size between its size and the area of radioactivity.

CARCINOMA OF THE HEPATIC DUCTS (FOUR CASES)

These presented with obstructive jaundice. All had normal pancreas scans but liver scans, carried out with the pancreas scans, suggested the abnormality and led to the performance of percutaneous cholangiograms.

CARCINOMA OF THE GALL BLADDER (TWO CASES)

One of these had a filling defect in the head of the

pancreas: a large tumour mass was infiltrating the area at laparotomy: the other had a prominent 'gall bladder' effect and the head of the gland appeared displaced medially.

HEPATOMA (ONE CASE)

The hepatoma showed as a 'hot' area on the ⁷⁵Se scan and a 'cold' area on the ¹⁹⁸Au scan. There was a generalized reduction in pancreatic uptake.

HAEMANGIOSARCOMA (ONE CASE)

A large invasive haemangiosarcoma, probably hepatic in origin and extending down from the region of the porta hepatis, was invading the pancreas, duodenum, gall bladder, and vascular structures. This was associated with a grossly abnormal scan.

INDEPENDENT USE OF THE LIVER SCAN

¹⁹⁸Au-colloidal gold liver scans were performed after the pancreas scan in all cases. Eighty of the 393 patients (20%) derived independent benefit from the liver scan, summarized as follows:

Condition	No. of Cases
Appearance of extrahepatic obstruction	48
Probable carcinoma of hepatic ducts	4
Cirrhotic pattern	11
Presence of hepatic metastases	9
Simple hepatomegaly	7
Shrunken liver	1

In some cases this did no more than divert attention away from the pancreas. In many others it focused attention on the liver, a hitherto unsuspected site of disease. In nine patients it prevented useless laparotomies. The prominent splenic uptake, seen almost exclusively in cirrhotics—except those who had splenectomies, porto-systemic shunting operations, or splenic vein thrombosis—helped to alert the pancreas scan reporter to the presence of a condition which was associated with a high incidence of non-specific scan abnormalities.

EXCLUSION OF THE DIAGNOSIS OF CARCINOMA

One of the most important aspects of the scan was the exclusion of the diagnosis of carcinoma. This was particularly true when an obscure mass was palpable in a patient subsequently shown to have a normal pancreatic scan. In 127 suspects reported as having 'normal' scans, only two were subsequently found to have a pancreatic tumour, a 'false-negative' rate of less than 2% of those reported 'normal' and less than 3% of those who had malignant disease. This aspect

of the test proved of great value to clinicians anxious to exclude the condition from the differential diagnosis in obscure cases.

SURVIVAL FOLLOWING DIAGNOSIS

Of 12 periampullary and lower common duct tumours and 48 primary malignant tumours of the pancreas, 97% were reported as having abnormal scans. Three of these 60 patients were lost to complete follow up due to change of domicile. The relationship of the scan in time to the duration of symptoms and the subsequent survival of the remaining 57 patients is shown in Figure 11. Only 14 of these tumours (one of which was missed on scanning) were resectable at surgery (five periampullary, five lower common bile duct, and four pancreatic).

The conclusions in relation to pancreatic disease were very depressing. With the exception of the patient shown in Fig. 6 whose scan report was wrong, no patient with a tumour of primarily pancreatic origin was alive at 12 months. This was in spite of the fact that most patients had their presenting symptom

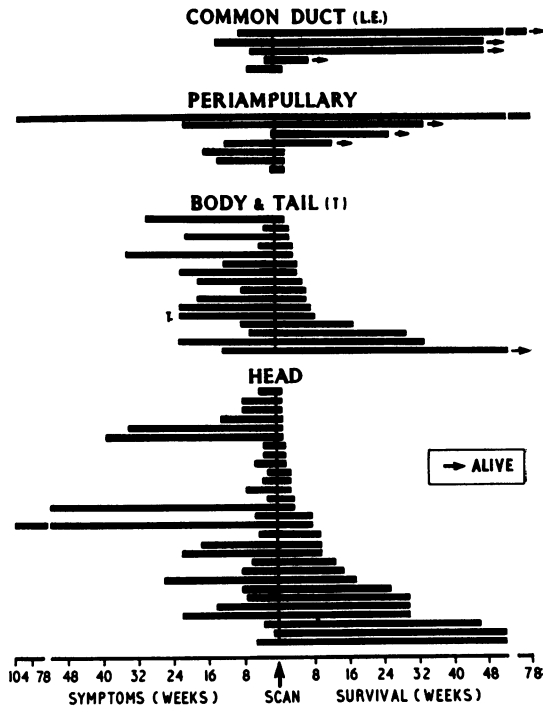


Fig. 11 Time of scan (centre) in relation to duration of presenting symptom (left) and subsequent survival (right) in 57 patients. Each horizontal bar represents one patient. The site of the tumour is indicated for each group of patients. (The abbreviation L.E. denotes tumours of the lower end of the common bile duct.)

for a comparatively short time, especially for tumours of the head of the gland. Of these latter only 10 of the 32 patients had complained for more than eight weeks: of the remainder over half had symptoms for four weeks or less. All had abnormal scans which were acted upon after consideration of all the facts about the cases. From the point of view of survival the outstanding problem was clearly not one of medical delay or diagnostic difficulty but of the late stage of the disease at which symptoms first presented. Clearly the immediate outlook for patients with periampullary or common duct tumours was much better, as indeed it was before the advent of scanning, but this was due to the early development of jaundice and to laparotomy being performed before spread of the tumour.

ACCURACY OF SCANNING IN OVERALL SERIES

Seventy-nine patients were classified from follow-up data as normal (Table II). Most of these had presented with obscure abdominal pain, weight loss, depression, or, less commonly, recurrent deep venous thrombosis or thrombophlebitis. In 35 cases the pancreas was inspected at laparotomy. In addition six patients with tumours adjacent to the pancreas (four hepatic duct tumours and two high common bile duct tumours) who were shown at laparotomy to have a normal pancreas were regarded as 'normal' in assessing the accuracy of scanning (Table IV).

Patients	Normal	Abnormal	Unreportable
Normal ¹ (85)	77	6	2
Carcinoma			
Gland (50)	2	47	1
Adjacent (16)	—	16	—
Pancreatic adenoma (5)	3	2	—
Pancreatitis (133)	21	112	—
Miscellaneous (104)	24	77	3

Table IV Scan reports in various diagnostic groups

¹Includes four patients with hepatic duct tumours and two with high common duct tumours since the pancreas was shown to be normal in each case.

In six 'normal' patients the scan report was abnormal but in each case the report was equivocal as to the cause of the abnormality and in no case was a diagnosis of carcinoma made in the scan report.

The largest single diagnostic group comprised patients in whom a final diagnosis of pancreatitis was established (McCarthy, 1972). The scan appearances were no different from those seen in patients with carcinoma but, in the context of the supplementary data on each case, were often quite helpful. Factors favouring the diagnosis of neoplastic rather than inflammatory disease were a short duration of symp-

toms, persistent pain, lack of a history of biliary disease or alcohol ingestion, marked weight loss, the presence of metastases on the liver scan, or the presence of a localized abnormality on the pancreas scan of a patient who did not have peptic ulcer disease or a previous history of pancreatitis. Twenty-one patients who were recovering from or had recovered from single or multiple attacks of acute pancreatitis had normal scans.

Of considerable importance was the realization that there were many conditions other than pancreatitis or carcinoma, but associated with varying degrees of pancreatic dysfunction, which could cause abnormalities on scanning. These are summarized in Table V, which has been compiled mainly from the present study (McCarthy, 1970) although the effect on the scan of many of these conditions has also been documented by other workers. Such conditions were a large source of error ('false positive' scan diagnoses of carcinoma) early in the study but this source of error rapidly reduced as the study progressed. Associated with this fall was an increase in the number of scan reports which stated clearly that the scan was abnormal but were equivocal as to the cause of the abnormality.

General

Peptic ulceration	Cirrhosis (esp. alcoholic)
Abdominal trauma	Haemochromatosis
Postgastrectomy/vagotomy	Fibrocystic disease
Mumps	Amyloidosis
Hyperparathyroidism	Polyarteritis
Infective hepatitis	Mesenteric ischaemia
Crohn's disease	Portal vein thrombosis
Weber-Christian disease	Lymphoma
Coeliac disease	Diabetes mellitus
Whipple's disease	Hypopituitarism
Gross malnutrition	Diazoxide therapy
Metastatic disease	Anticholinergic therapy

Technically difficult

Gross obesity	Large anterior masses
Ascites or intraperitoneal haemorrhage	

Reported in the literature

Mesenteric fibrosis	Gross hydronephrosis
Post-pancreatic resection	Hepatoma

Table V Conditions with a high incidence of abnormal scans

A high proportion of equivocal reports were inevitably issued for abnormal scans obtained in patients with the conditions listed in Table V who comprise the miscellaneous group in Table IV. In such patients an abnormal scan is likely to be due to the condition *per se* and should not be used to justify a diagnosis of carcinoma.

In spite of these various problems, it is noteworthy that in the case of 50 tumours directly involving the gland (48 primary, two metastatic) the scan report

suggested carcinoma as the most likely diagnosis in 38 (76% of tumour cases) in the context of all available data on the case. Only three 'false negative' reports were issued (one in a scan uninterpretable because of hepatomegaly, one small carcinoma of the body (Fig. 6) and one superficial metastasis on the surface of the pancreas). In the remaining nine cases the scan report, while stating that the gland was definitely abnormal, was equivocal as to the cause.

Discussion

Scanning is clearly helpful in the diagnosis of pancreatic cancer and is a very effective screening test in suspect patients who do not suffer from the condition. The problem is that by the time of scanning the majority of malignant neoplasms so diagnosed are large, unresectable, have usually metastasized and are associated with a very poor survival rate. These conclusions are based on patients with short symptomatic intervals preceding the test. It must therefore be concluded that scanning has contributed little to the patient's welfare and indeed a similar analysis of other tests performed in symptomatic patients is likely to lead to similar conclusions. Tumours originating in the common bile duct or periampullary duodenal mucosa, by contrast, are usually small, resectable, localized, and at least in the short term associated with a fair prognosis. But this can be attributed to the early development of symptoms and signs in association with these lesions rather than to any test employed in their diagnosis. There is also a rationale for the performance of laparotomy and radical surgery early in their course. Failure of the scan to detect insulinomas has been reported (Centi Colella and Pigorini, 1968; Steinhoff and Pabst, 1968) and this is almost certainly related to the small size of the lesions. The finding of a 'cold area' on the scan of a patient with a non- β -cell tumour, 4 cm in diameter, has been reported and there has been some speculation as to whether or not 'hot' areas have been seen in two cases (Melmed *et al.*, 1968), but on general principles scanning has little to offer in the diagnosis of small adenomata at the present time. The specific activity of tumour tissue removed at operation has never compared with that of the surrounding tissue but would be of considerable interest and would help to end speculation on the matter.

One of the limitations of pancreatic scanning has been the high incidence of false positive diagnoses in some centres (Burdine and Haynie, 1965; King *et al.*, 1966; Rodríguez-Antúnez *et al.*, 1966). In the present series six 'normal' patients—none of whom had had a laparotomy—had abnormal scans. Two of these six patients had borderline abnormal scans reported

equivocally and four had areas of localized reduction in uptake interpreted as filling defects; one of the patients was 80 years old and two had persistent abdominal pain for which a pancreatic cause could not totally be excluded. In no case was a grossly abnormal scan seen in an unequivocally normal patient. On the other hand, it is of great importance to note that abnormal scans were obtained in 77 of the miscellaneous group (Table IV). Of these 77 patients some interference with the pancreas was found biochemically, functionally, operatively, radiologically, or at necropsy in over half the sample. With the exception of a minority of cases of rare diseases, all the other unexplained or difficult cases belong to diagnostic groups within which there was a high association with abnormal scans: almost all of these diagnostic groups have been associated with evidence of secondary pancreatic dysfunction in the published literature and it seems probable that the abnormal scan always indicates some dysfunction in the gland even when clinically florid pancreatic disease is not present. In the absence of a simple test of pancreatic function the incidence of minor degrees of pancreatic dysfunction may have been underestimated in earlier clinical studies of many disease states. From a practical point of view, in a suspect case, with clinical features of these conditions (Table V) an abnormal scan may be used to indicate pancreatic dysfunction but not to diagnose pancreatic neoplasia or pancreatitis. Far less should the isolated finding of a scan abnormality be used to justify laparotomy, unless the history strongly suggests carcinoma. When this type of diagnostic vigilance is required it seems essential to involve a physician, with a special interest in pancreatic diseases, in reporting on the scan.

On the basis of the survival data it has been suggested that the ominous present outcome of malignant pancreatic disease implies that those afflicted will not benefit appreciably from having the diagnosis established. However, these numbered less than 20% of the suspect population: in the majority the outcome of scanning was to divert clinical attention to less discouraging aspects of the case. Furthermore, early diagnosis greatly reduced the wastage of hospital beds, laboratory services, and medical manpower which so often characterizes the undiagnosed clinical problem.

The scan has been found helpful in the diagnosis and assessment of pancreatitis, both in the present study and by other workers (Sodee, 1966; Van Vaerenbergh, Van Vaerenbergh, Demeulenaere, Yvergnaux, and Barbier, 1966; Marabini, Donati, Cabassa, and Gagni, 1967; Swyngedauw *et al.*, 1967; Centi-Colella and Pigorini, 1968; Eaton, Fleischli, Pollard, Nebesar, and Potsaid, 1968;

Melmed *et al.*, 1968; Blanquet, Doutre, Beck, and Ducassou, 1970): this was often its most useful application. However, one of the commoner clinical problems is to differentiate between inflammatory and neoplastic pancreatic disease as the cause of a patient's signs, symptoms, or dysfunction. On its own the scan cannot be used for this differentiation. In the series of Liewendahl and Kvist (1970), localized abnormalities were least liable to interpretive error and usually associated with the presence of tumour tissue, but in the present series such abnormalities were associated with pancreatitis in an almost equivalent number of cases, though their incidence in such cases was much lower, the number of cases of pancreatitis being approximately double the number of cases of malignant disease. These figures may be somewhat biased in the present series, which included a considerable number of patients with known severe pancreatic inflammatory disease and complicated peptic ulcers.

Applications of the test in assessing pancreatitis, together with its use in the detection of various pancreatic dysfunctions, emphasizes that to regard the test solely in terms of the detection of carcinoma is to ignore the more common benefit of the test to the patient. On the other hand its wider use as a clinical test is somewhat limited by cost and shortage of equipment outside special centres and by the associated radiation hazard in the young, the pregnant, and those previously scanned. These difficulties have recently led to the development of a new test for pancreatic malfunction, based on measurement of the radioactivity of a single sample of duodenal aspirate obtained two hours after injection of a small dose of ^{75}Se -selenomethionine, 10% of that employed in scanning (Youngs, Agnew, Levin, and Bouchier, 1971). However, it is unlikely that this test will prove of value in the differentiation of tumours from other causes of glandular abnormality. Newer technical innovations in scanning equipment seem equally unlikely to resolve this difficulty. An isotope with high rather than low affinity for tumour tissue seems most likely to increase the specificity of the test, as applied to symptomatic cases.

The real need is for the development of a relatively simple serological test which can be used to screen large numbers of presymptomatic subjects in the tumour-prone age group, when hopefully the tumours will be less advanced. In this regard the findings of carcinoembryonic antigens in foetal pancreas and in pancreatic tumour tissue (Gold, 1967), together with the recent demonstration of antibodies to this or to a similar antigen in 13 out of 13 cases of carcinoma of the pancreas (Moore, Zupchik, Marcon, and Zamcheck 1971), are of great

interest. Hopefully purification of the antigen employed in these studies may lead to the development of specific antisera, which can be used to screen large populations for the presence of various digestive tract cancers at an early stage of their development. In the interim pancreatic scanning seems likely to remain a useful adjunct to the diagnosis of the more advanced case for some time to come.

We should like to express our sincere thanks to the many clinicians who referred cases for study. Particular thanks are due to Professor Sheila Sherlock, Sir Francis Avery Jones, Drs T. D. Kellock, A. M. Dawson, C. N. Mallinson, N. Compston, and A. G. Beckett who referred many of the patients and cooperated closely in obtaining detailed information following the scan. We are also very grateful to Drs L. Kreel and F. Piggott, who carried the main brunt of the supporting radiological studies, and to Mr J. Ogle of the Radiochemical Centre, Amersham, Bucks, who was of great assistance in obtaining translations of foreign language publications.

References

- Agnew, J. E., McCarthy, D. M., Melmed, R. N., and Bouchier, I. A. D. (1969). Count rate analysis as an adjunct to the ^{75}Se -selenomethionine pancreas scan. *Brit. J. Radiol.*, **42**, 762-769.
- Aronsen, K. F., Gynning, I., and Walderskog, B. (1965). Evaluation of ^{75}Se -selenomethionine for visualisation of the pancreas by scanning technique. *Acta chir. scand.*, **129**, 624-630.
- Blanquet, P., Doutre, L. P., Beck, C., and Ducassou, D. (1970). Intérêt et limites de la scintigraphie du pancréas. *Acta gastroent. belg.*, **33**, 409-421.
- Blau, M. (1964). Pancreas scanning with Se^{75} -selenomethionine. In *Medical Radioisotope Scanning*, Vol. II, pp. 275-287. International Atomic Energy Agency, Vienna.
- Blau, M., and Bender, M. A. (1962). Se^{75} -selenomethionine for visualization of the pancreas by isotope scanning. *Radiology*, **78**, 974.
- Burdine, J. A., and Haynie, T. P. (1965). Diagnosis of pancreatic carcinoma by photoscanning. *J. Amer. med. Ass.*, **194**, 979-983.
- Burke, G., and Goldstein, M. S. (1964). Radioisotope photoscanning in the diagnosis of pancreatic disease. *Amer. J. Roentgenol.*, **92**, 1156-1161.
- Centi Colella, A., and Pigorini, F. (1967). Experiences in pancreas scanning using ^{75}Se -selenomethionine. *Brit. J. Radiol.*, **40**, 662-669.
- Centi-Colella, A., and Pigorini, F. (1968). Problems of interpretation of isotope scans of the normal and abnormal pancreas. *Atti del XXIII Congresso Nazionale di Radiologia e Medicina Nucleare, Padua, 1968*. Trans LBIG. 2848, U.K. Atomic Energy Authority.
- Eaton, S. B., Fleischli, D. J., Pollard, J. J., Nebesar, R. A., and Potsaid, M. S. (1968). Comparison of current radiologic approaches to the diagnosis of pancreatic disease. *New Engl. J. Med.*, **279**, 389-396.
- Gold, P. (1967). Circulating antibodies against carcinoembryonic antigens of the human digestive system. *Cancer (Philad.)*, **20**, 1663-1667.
- Kakehi, H., Tateno, Y., Uchiyama, G., and Tsuchiya, S. (1967). Radioisotope scanning of pancreas carcinoma. (Abstr.) *J. nucl. Med.*, **8**, 387-388.
- Kaplan, E., Ben-Porath, M., Fink, S., Clayton, G. D., and Jacobson, B. (1967). Evaluation of pancreatic disease by dual channel scanning. (Abstr.) *J. nucl. Med.*, **8**, 349.
- King, E. R., Sharpe, A., Grubb, W., Brock, J. S., and Greenberg, L. (1966). A study of the morphology of the normal pancreas using Se^{75} -methionine photoscanning. *Amer. J. Roentgenol.*, **96**, 657-663.

- Lähdevirta, J., Räsänen, T., and Haikonen, M. (1966). Isotope scanning of the pancreas as a diagnostic aid in some cases of pancreatic disease. *Ann. Med. intern. Fenn.*, **55**, 115-119.
- Liewendahl, K., and Kvist, G. (1970). Evaluation of pancreatic scanning. *Acta. med. scand.*, **188**, 75-80.
- McCarthy, D. M. (1970). Pancreatic scanning. MD Thesis, University College Dublin (NUI).
- McCarthy, D. M. (1972). Scanning in pancreatitis. In *Pancreatitis*, edited by O. Fitzgerald and J. McMullin. London (in press).
- McCarthy, D. M., and Brown, P. (1969). Measurement of duodenal tryptic activity and ⁷⁵Se-selenomethionine pancreatic scanning compared as tests of pancreatic function. *Gut*, **10**, 913-920.
- McCarthy, D. M., Kreel, L., Agnew, J. E., and Bouchier, I. A. D. (1969). Value of hypotonic duodenography as an adjunct to pancreatic scanning. *Gut*, **10**, 665-673.
- Marabini, A., Donati, E., Cabassa, N., and Gagni, G. (1967). Rilievi scintigrafici ottenuti con seleniomethionina radioattiva nelle pancreatiti acute e croniche. (Abstr.) *Radiol. med. (Torino)*, **53**, 504.
- Melmed, R. N., Agnew, J. E., and Bouchier, I. A. D. (1968). The normal and abnormal pancreatic scan. *Quart. J. Med.*, n.s., **37**, 607-624.
- Moore, T. L., Zupchik, H. Z., Marcon, N., and Zamcheck, N. (1971). Carcinoembryonic antigen assay in cancer of the colon and pancreas and other digestive tract disorders. *Amer. J. dig. Dis.*, **16**, 1-7.
- Riccobono, X. J. (1968). Pancreatic scanning. *Semin. Roentgenol.*, **3**, 310-317.
- Rodriguez-Antúnez, A., Filson, E. J., Sullivan, B. H., Jr., and Brown, C. H. (1966). Photoscanning in diagnosis of carcinoma of the pancreas. *Ann. intern. Med.*, **65**, 730-737.
- Sodee, D. B. (1966). The clinical correlation of isotope pancreatography. *Amer. J. Gastroent.*, **45**, 454-459.
- Steinhoff, H., and Pabst, H. W. (1968). Bisherige Ergebnisse der Pancreasszyntigraphie mit ⁷⁵Se-Methionin. *Schweiz. med. Wschr.*, **98**, 285-287.
- Swyngedauw, J., Tacquet, A., Foissac-Gegoux, P., and Huart, M. (1967). L'exploration isotopique du pancréas par la sélénométhionine: à propos de 60 observations. *Lille med.*, **12**, 773-782.
- Van Vaerenbergh, M., Jr., Van Vaerenbergh, P. M., Demeulenaere, L., Yvergneux, J. P., and Barbier, F. (1966). La pancreatographie par les isotopes radioactifs. *Acta gastro-ent. belg.*, **29**, 197-210.
- Youngs, G. R., Agnew, J. E., Levin, G. E., and Bouchier, I. A. D. (1971). Radioselenium in duodenal aspirate as an assessment of pancreatic exocrine function. *Brit. med. J.*, **2**, 252-255.
- Zuidema, G. D., Kirsh, M., Turcotte, J. G., Gaisford, W. D., Powers, W., and Kowalczyk, R. S. (1963). Pancreatic uptake of Se⁷⁵-selenomethionine. *Ann. Surg.*, **158**, 894-897.