

Peliosis hepatis in recipients of renal transplants¹

C. DEGOTT, B. RUEFF, H. KREIS, A. DUBOUST, F. POTET, AND
J. P. BENHAMOU²

From the Unité de Recherches de Physiopathologie Hépatique (INSERM), Hôpital Beaujon, Clichy; Service d'Anatomie et de Cytologie Pathologiques, Hôpital Beaujon, Clichy; Département de Thérapeutique Néphrologique, Hôpital Necker, Paris; and Service de Médecine II, Hôpital Broussais, Paris, France

SUMMARY Peliosis hepatis, an uncommon liver lesion characterised by blood-filled cavities bordered by hepatocytic plates, was found in 12 patients three to 17 months after renal transplantation. Hepatomegaly and portal hypertension were present in five of the six patients with major peliosis hepatis, and were absent in the other six with minor hepatic lesions. Alterations of centrilobular vein walls in some of these patients suggest that peliosis hepatis could be the result of a blockade of liver blood outflow at the junctions of sinusoids and centrilobular veins. The cause of these alterations might be azathioprine.

Peliosis hepatis, from the Greek *πελιόσ* (which means livid), is an uncommon liver lesion consisting of blood-filled cavities distributed at random in the hepatic parenchyma. This liver lesion has been reported in patients suffering from various diseases (Zak, 1950; Hamilton and Lubitz, 1952; Trites, 1957; Kent and Thompson, 1961; Caroli *et al.*, 1964; Orandi and Pirozynski, 1967) or receiving various drugs (Yanoff and Rawson, 1964; Bernstein *et al.*, 1971; Delage and Lagacé, 1973; Naeim *et al.*, 1973; Bagheri and Boyer, 1974; Kühböck *et al.*, 1975); the mechanism whereby these diseases and drugs induce peliosis hepatis is unknown. The purpose of this paper is (1) to demonstrate that the frequency of the disorder is relatively high in renal transplant recipients, and (2) to offer a hypothesis for the mechanism of this liver lesion.

Methods

PATIENTS

The present investigation was based on a series of 500 patients, 328 men and 172 women, aged from 16 to 56 years, suffering from chronic renal failure, who were treated by renal transplantation between 1965 and 1975. In 138 of them, a liver specimen was taken

intraoperatively during renal transplantation. All the renal transplant recipients received azathioprine and corticosteroids. Among these 500 patients, 55 were referred to the Liver Unit because they had one or several disorders suggesting liver alteration: liver enlargement, ascites, oesophageal varices, increased level of serum transaminases, hepatitis B surface antigen (HBsAg) present in serum. A liver specimen was taken three to 17 months after renal transplantation by surgical biopsy in five of the patients, by percutaneous needle biopsy in 45, and by transjugular needle biopsy in five; the last method can be used in those patients with bleeding tendency in whom percutaneous needle biopsy is contraindicated (Lebrec *et al.*, 1978). In six of the patients with peliosis hepatis peritoneoscopy was performed. In eight of the patients with this lesion, a second liver specimen was obtained three to 32 months after the first histological examination either by one of the methods of biopsy mentioned above or at necropsy.

Results

No liver lesions suggesting peliosis hepatis were found in any of the 138 patients submitted to biopsy during renal transplantation. Lesions of peliosis hepatis were demonstrated in 12 of the 55 patients submitted to biopsy after renal transplantation. The ages of these 12 patients ranged from 24 to 56 years. There were 11 men and one woman. None of them took anabolic, androgenic, or oestrogenic steroids. According to the size and extent of the liver lesions, we distinguished a minor and a major form of

¹This work was presented in part at the 11th Meeting of the European Association for the Study of the Liver, Copenhagen, 1976 (Degott *et al.*, 1976).

²Address for reprint requests: Dr J. P. Benhamou, Hôpital Beaujon, 92118 Clichy, France.

peliosis hepatis: in the former, the size of the blood-filled cavities was small, and the lesions affected only a part of the hepatic lobules (Fig. 1); in the latter, the blood-filled cavities were large and often confluent, and the lesions affected a large portion of the hepatic lobules (Fig. 2); the hepatocytic plates lining the small cavities were normal, but those lining the large cavities were thin and often interrupted. The minor form of peliosis hepatis was found in six of the 12 patients, and the major form in the other six.

In four of the six cases of the major form of the disorder, the walls of some centrilobular veins were oedematous and fibrous; these alterations affected either the whole or only a part of the circumference of the vessels and were not associated with thrombosis (Fig. 3); the lesions of the centrilobular veins were not spatially related to the areas of peliosis hepatis. In the other two cases of the major form of the lesion and in all six cases of the minor form, these venous alterations were not seen.

Peritoneoscopy showed multiple purplish areas, more or less circular, with a diameter ranging from 0.5 to 2 mm, disseminated at the surface of the liver, in two of the three patients with the minor form of the lesion and in all the three patients with the major form in whom this examination was performed.

Peliosis hepatis was associated with chronic persistent hepatitis or chronic active hepatitis (as defined according to the histological criteria of De Groote *et al* (1968)) in three and four, respectively, of the 12 patients. HBsAg, tested for by radio-immunoassay, was present in the sera of six out of

those seven patients with peliosis hepatis and chronic hepatitis; HBsAg was absent in the sera of the other five patients with the disorder and without chronic hepatitis.

In four patients with the major form of peliosis hepatis, a second liver specimen was obtained; in two of them, lesions of peliosis hepatis almost similar to those observed previously were demonstrated one and 15 months, respectively, after the first histological examination; in the other two patients in whom the lesion was not associated with chronic hepatitis, cirrhosis with marked fibrosis and small-sized regenerative nodules was demonstrated three and 12 months, respectively, after the first histological examination. In four patients with the minor form of peliosis hepatis, a second liver specimen was obtained; in one of them, lesions almost similar to those demonstrated previously were observed 15 months after the first histological examination; in the other three patients in whom peliosis hepatis was associated with chronic active hepatitis, cirrhosis was demonstrated three, 17, and 32 months, respectively, after the first histological examination.

There was a relationship between some clinical manifestations and the degree of peliosis hepatis. Liver enlargement was present in all, and manifestations suggesting portal hypertension—that is, oesophageal varices and/or ascites—were present in five of the six patients with the major form of peliosis hepatis. The liver size was normal, and manifestations suggesting portal hypertension were

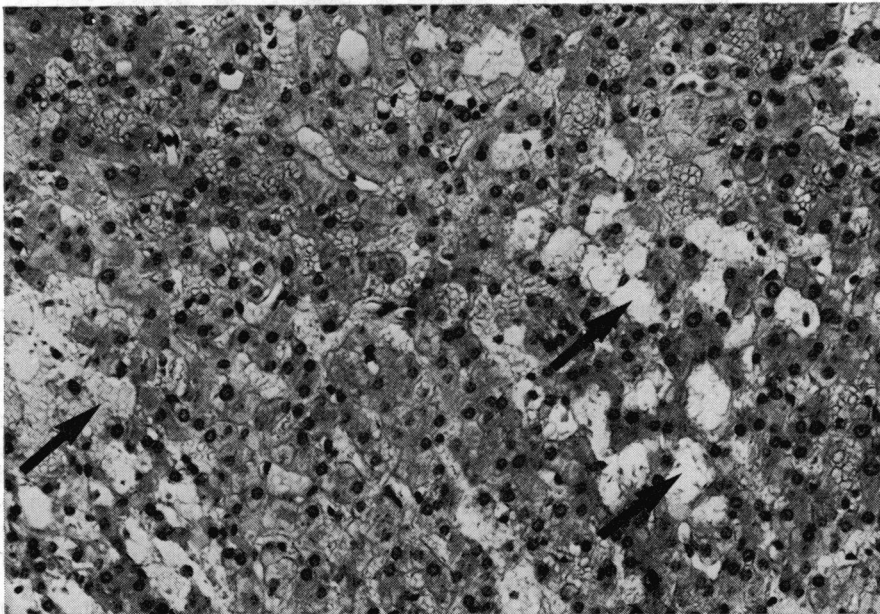


Fig. 1 Minor form of peliosis hepatis. The blood-filled cavities (some are indicated by arrows) are small; they are bordered by normal hepatocyte plates. Haematoxylin and eosin stain $\times 225$.

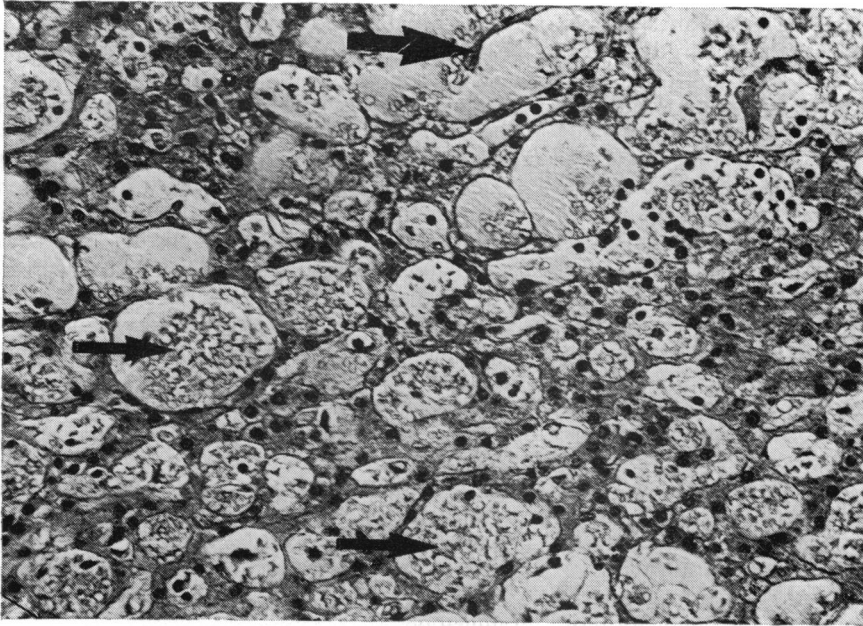


Fig. 2 Major form of peliosis hepatis. The blood-filled cavities (some are indicated by thin arrows) are large: they are bordered by thin or interrupted (thick arrow) hepatocyte plates. Haematoxylin and eosin stain $\times 225$.

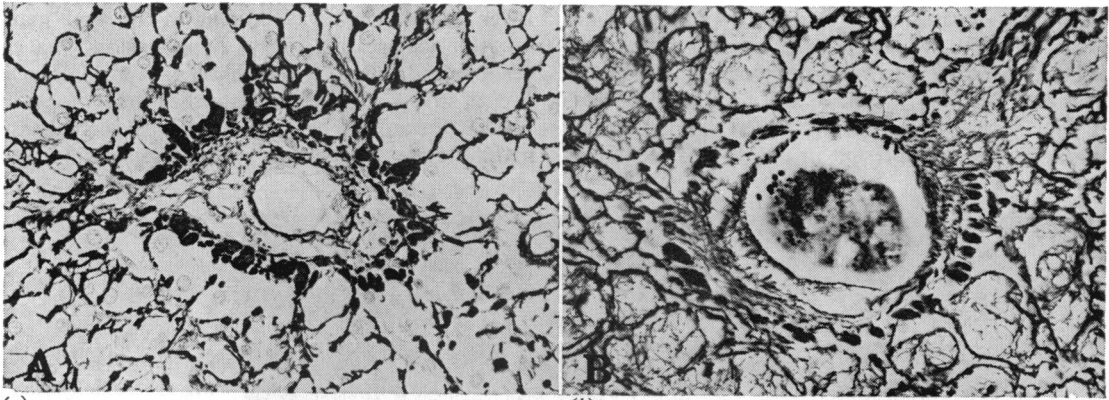


Fig. 3 Centrilobular vein. The centrilobular vein walls are thickened by subendothelial connective tissue. This lesion affects either the whole (a) or only a part (b) of the circumference of the vessel. Reticulin stain $\times 275$.

absent in all the six patients with the minor form of peliosis hepatis. Rejection episodes occurred at the time of, or before recognition of the disorder in all the 12 patients.

Discussion

The histological pattern of the liver lesions observed in our 12 patients is that attributed to peliosis hepatis. The random distribution of the lesions throughout the hepatic lobules distinguishes peliosis hepatis from congestive liver, Budd-Chiari

syndrome, and veno-occlusive disease of the liver (Bras *et al.*, 1954; Stein and Isaacson, 1962; Putzke *et al.*, 1972) in which sinusoidal dilatation predominates in the centrilobular areas. According to Yanoff and Rawson (1964), there are two varieties of peliosis hepatis: (1) phlebotatic, in which the blood-filled spaces are lined with endothelium, and (2) parenchymal, in which the blood-filled spaces possess no endothelial lining; the liver lesions observed in our patients belong to the latter variety.

The peritoneoscopic lesions observed in almost all

our patients—that is, small purplish areas at the surface of the liver—are similar to the macroscopic lesions described at necropsy of patients with peliosis hepatis (Zak, 1950). This finding reinforces the view that the liver lesions observed in our patients correspond to peliosis hepatis and confirm the value of peritoneoscopy for the diagnosis of the disorder (Caroli *et al.*, 1964).

The clinical manifestations of peliosis hepatis have been poorly defined, probably because, in most of the cases reported, the liver lesions have been recognised only at necropsy, and have been associated with a severe disease, the signs and symptoms of which have been intermingled with those of peliosis hepatis. However, it has been established that the disorder can induce hepatomegaly (Naeim *et al.*, 1973), liver failure (Bernstein *et al.*, 1971), and intraperitoneal bleeding (Bagheri and Boyer, 1974). In our experience, the minor form of peliosis hepatis was clinically latent and the major form was associated with hepatomegaly and portal hypertension. In two of our patients in whom peliosis hepatis was not accompanied by chronic active hepatitis, cirrhosis was found at a subsequent histological examination: this finding is compatible with the view that peliosis hepatis *per se* can induce the development of cirrhosis.

Peliosis hepatis or similar lesions have been reported in patients suffering from malignancy (Zak, 1950; Caroli *et al.*, 1964; Yanoff and Rawson, 1964; Delage and Lagacé, 1973), tuberculosis (Hamilton and Lubitz, 1952), or diabetes (Hamilton and Lubitz, 1952) and in patients receiving anabolic, androgenic, or oestrogenic steroids (Yanoff and Rawson, 1964; Bernstein *et al.*, 1971; Naeim *et al.*, 1973; Bagheri and Boyer, 1974; Kühböck *et al.*, 1975; Winkler and Poulsen, 1975; Westaby *et al.*, 1977); none of these recognised aetiological factors is implicated in the aetiology of peliosis hepatis in our patients. Peliosis hepatis has also been reported in a patient suffering from chronic renal disease (Trites, 1957); however, in our patients, peliosis hepatis is likely to be related, not to chronic renal disease, but to renal transplantation, since this liver lesion has been detected in none of our patients submitted to biopsy during renal transplantation, and only in patients after renal transplantation. The association of the disorder with renal transplantation has not been hitherto described, although the liver lesions have been extensively investigated in large series of renal transplant recipients (Hill *et al.*, 1966; Evans *et al.*, 1968; Gault *et al.*, 1971; Torisu *et al.*, 1971; Berne *et al.*, 1975; Nielsen *et al.*, 1975; Ware *et al.*, 1975); we have no explanation for this discrepancy between our findings and the apparent absence of peliosis hepatis in the other series; the

selection of the patients, the technique of renal transplantation, and the nature and dosage of immunosuppressing drugs seem to be no different in our series and in the other series.

The prevalence of peliosis hepatis in our series of renal transplant recipients is 2.4%: this is a minimal figure as only those patients with manifestations suggesting liver alteration have been subjected to biopsy, and most of our patients have been observed for only a part of their lifetime. The male-to-female ratio is much higher in our patients with peliosis hepatis than in the entire group of renal transplant recipients, being 1.0:1 and 1.0:5, respectively; we have no explanation for this male predominance. Hepatitis B virus is not the causal factor of peliosis hepatis, as only six of our 12 patients with the disorder are chronic HBsAg carriers. Rejection episodes have occurred in all our patients; however, rejection being a common complication of renal transplantation, a fortuitous association with peliosis hepatis cannot be excluded. All our patients have received corticosteroids and azathioprine; peliosis hepatis has not been reported in patients receiving these drugs; however, veno-occlusive disease of the liver or sinusoidal dilatation, both hepatic lesions probably closely related to peliosis hepatis (as discussed below), have been reported in patients treated with azathioprine (Marubio and Danielson, 1975), or 6-mercaptopurine (Clark *et al.*, 1960), a metabolite of azathioprine, or 6-thioguanine (Griner *et al.*, 1976), a compound chemically close to 6-mercaptopurine; sinusoidal dilatation has also been described in dogs receiving azathioprine (Stuart *et al.*, 1967).

The hypothesis we offer for the mechanism of peliosis hepatis is based on an assumption and an observation: (1) sinusoidal dilatation, the basic lesion of peliosis hepatis, would result from congestion due to a blockade of liver blood outflow; (2) alterations of the walls of some centrilobular veins are present in some of our patients and, interestingly, have likewise been observed in patients with peliosis hepatis after long-term administration of methyltestosterone (Paradinas *et al.*, 1977). From this assumption and this observation, we hypothesise that sinusoidal dilatation in peliosis hepatis might be the consequence of a blockade of liver blood outflow located at the junctions of sinusoids and centrilobular veins; the absence of vascular lesions in some of our patients and in most cases reported previously might be only apparent and be due to their patchy distribution. In other words, peliosis hepatis would be a variant of the syndromes resulting from a blockade of liver blood outflow, the other variants being veno-occlusive disease of the liver and Budd-Chiari syndrome in which the blockade is located on

the centrilobular veins and on the main hepatic veins, respectively.

Our hypothesis fits in with, and is reinforced by, the following observations and considerations: (1) the lesions of centrilobular veins are more frequent in our patients with the major form of peliosis hepatis than in those with the minor form; a similar parallelism between the degree of peliosis hepatis and the severity of the vascular lesions has been noted in patients with the disorder after long-term administration of methyltestosterone (Paradinas *et al.*, 1977); (2) sinusoidal dilatation is the basic lesion in peliosis hepatis as well as in veno-occlusive disease of the liver and Budd-Chiari syndrome; the random distribution of sinusoidal dilatation in the former and the centrilobular predominance in the latter conditions might be related to the different locations of the blockade of liver blood outflow; (3) some aetiological factors are common to peliosis hepatis and thrombosis of the hepatic veins or veno-occlusive disease of the liver; this is the case for oestrogenic steroids and azathioprine; the former have been recognised as a cause of both peliosis hepatis and similar lesions (Winkler and Poulsen, 1975) and thrombosis of the hepatic veins (Hoyumpa *et al.*, 1971); the latter has been mentioned as a cause of veno-occlusive disease of the liver (Marubio and Danielson, 1975), and could be the aetiological factor of peliosis hepatis in our patients; (4) portal hypertension, a common complication of the major form of peliosis hepatis in our patients, might be another consequence of the presumed blockade of liver blood outflow.

References

- Bagheri, S. A., and Boyer, J. L. (1974). Peliosis hepatis associated with androgenic-anabolic steroid therapy. A severe form of hepatic injury. *Annals of Internal Medicine*, **81**, 610-618.
- Berne, T. V., Chatterjee, S. N., Craig, J. R., Redeker, A. G., and Payne, J. E. (1975). Hepatic dysfunction in recipients of renal allografts. *Surgery, Gynecology and Obstetrics*, **141**, 171-175.
- Bernstein, M. S., Hunter, R. L., and Yachnin, S. (1971). Hepatoma and peliosis hepatis developing in a patient with Fanconi's anemia. *New England Journal of Medicine*, **284**, 1135-1136.
- Bras, G., Jelliffe, D. B., and Stuart, K. L. (1954). Venocclusive disease of liver with nonportal type of cirrhosis, occurring in Jamaica. *Archives of Pathology*, **57**, 285-300.
- Caroli, J., Julien, C., and Albano, O. (1964). Péliose hépatique et plasmosarcomatose splénique. Première observation reconnue in vivo. *Semaine des Hôpitaux de Paris*, **40**, 1709-1720.
- Clark, P. A., Hsia, Y. E., and Huntsman, R. G. (1960). Toxic complications of treatment with 6-mercaptopurine. Two cases with hepatic necrosis and intestinal ulceration. *British Medical Journal*, **1**, 393-395.
- Degott, C., Potet, F., Feldmann, G., Rueff, B., and Benhamou, J.-P. (1976). Peliosis hepatis in renal transplant recipients. *Digestion*, **14**, 467-468 (Abstract).
- De Groote, J., Desmet, V. J., Gedigk, P., Korb, G., Popper, H., Poulsen, H., Scheuer, P. J., Schmid, M., Thaler, H., Uehlinger, U., and Wepler, W. (1968). A classification of chronic hepatitis. *Lancet*, **2**, 626-628.
- Delage, C., and Lagacé, R. (1973). La péliose hépatique: rôle étiologique possible des médicaments (1973). *Union Médicale du Canada*, **102**, 1888-1893.
- Evans, D. B., Millard, P. R., and Herbertson, B. M. (1968). Hepatic dysfunction associated with renal transplantation. *Lancet*, **2**, 929-934.
- Gault, M. H., Aronoff, A., Huang, S., Lal, S., Wu, T., Moinuddin, and MacLean, L. D. (1971). Liver disorders in kidney transplant recipients. *Gastroenterology*, **60**, 168 (Abstract).
- Griner, P. F., Elbadawi, A., and Packman, C. H. (1976). Veno-occlusive disease of the liver after chemotherapy of acute leukemia. Report of two cases. *Annals of Internal Medicine*, **85**, 578-582.
- Hamilton, F. T., and Lubitz, J. M. (1952). Peliosis hepatis: report of three cases with discussion of pathogenesis. *Archives of Pathology*, **54**, 564-572.
- Hill, R. B., Jr., Porter, K. A., and Massion, C. G. (1966). Hepatic reaction to renal transplants modified by immunosuppressive therapy. *Archives of Pathology*, **81**, 71-77.
- Hoyumpa, A. M., Jr., Schiff, L., and Helfman, E. L. (1971). Budd-Chiari syndrome in women taking oral contraceptives. *American Journal of Medicine*, **50**, 137-140.
- Kent, G., and Thompson, J. R. (1961). Peliosis hepatis: Involvement of reticuloendothelial system. *Archives of Pathology*, **72**, 658-664.
- Kühböck, J., Radaszkiewicz, T., and Walek, H. (1975). Peliosis hepatis, eine Komplikation der Anabolikatherapie. *Medizinische Klinik*, **70**, 1602-1607.
- Lebre, D., Degott, C., Rueff, B., and Benhamou, J.-P. (1978). Transvenous (transjugular) liver biopsy: an experience based on 100 biopsies. *American Journal of Digestive Diseases*, **23**, 302-304.
- Marubio, A. T., and Danielson, B. (1975). Hepatic veno-occlusive disease in a renal transplant patient receiving azathioprine. *Gastroenterology*, **69**, 739-743.
- Naeim, F., Copper, P. H., and Semion, A. A. (1973). Peliosis hepatis. Possible etiologic role of anabolic steroids. *Archives of Pathology*, **95**, 284-285.
- Nielsen, V., Clausen, E., and Ranek, L. (1975). Liver impairment during chronic hemodialysis and after renal transplantation. *Acta Medica Scandinavica*, **197**, 229-234.
- Orandi, M., and Pirozynski, W. J. (1967). Peliosis hepatis. *Canadian Medical Association Journal*, **96**, 1219-1220.
- Paradinas, F. J., Bull, T. B., Westaby, D., and Murray-Lyon, I. M. (1977). Hyperplasia and prolapse of hepatocytes into hepatic veins during longterm methyltestosterone therapy: possible relationships of these changes to the development of peliosis hepatis and liver tumours. *Histopathology*, **1**, 225-246.
- Putzke, H. P., Persaud, T. V., and Bienengraber, A. (1972). Fine structure of the liver in experimental veno-occlusive disease. *Experimentelle Pathologie*, **6**, 325-332.
- Stein, H., and Isaacson, C. (1963). Venocclusive disease of the liver. *British Medical Journal*, **1**, 372-374.
- Stuart, F. P., Torres, E., Hester, W. J., Dammin, G. J. and Moore, F. D. (1967). Orthotopic autotransplantation and allotransplantation of the liver: functional and structural patterns in the dog. *Annals of Surgery*, **165**, 325-340.
- Toritsu, M., Yokoyama, T., Amemiya, H., Kohler, P. F., Schroter, G., Martineau, G., Penn, J., Palmer, W., Halgrimson, C. G., Putnam, C. W., and Starzl, T. E. (1971). Immunosuppression, liver injury, and hepatitis in renal, hepatic, and cardiac homograft recipients: with particular reference to the Australia antigen. *Annals of Surgery*, **174**, 620-637.

- Trites, A. E. W. (1957). Peliosis hepatis: report of a case. *Archives of Pathology*, **63**, 183-186.
- Ware, A. J., Luby, J. P., Eigenbrodt, E. H., Long, D. L., and Hull, A. R. (1975). Spectrum of liver disease in renal transplant recipients. *Gastroenterology*, **68**, 755-764.
- Westaby, D., Ogle, S. J., Paradinis, F. J., Randell, J. B., and Murray-Lyon, I. M. (1977). Liver damage from long-term methyltestosterone. *Lancet*, **2**, 261-263.
- Winkler, K., and Poulsen, H. (1975). Liver disease with periportal sinusoidal dilatation. A possible complication to contraceptive steroids. *Scandinavian Journal of Gastroenterology*, **10**, 699-704.
- Yanoff, M., and Rawson, A. J. (1964). Peliosis hepatis: an anatomic study with demonstration of two varieties. *Archives of Pathology*, **77**, 159-165.
- Zak, F. G. (1950). Peliosis hepatis. *American Journal of Pathology*, **26**, 1-15.