

Non-restorative surgery in the treatment of Crohn's disease of the large bowel

JEAN K. RITCHIE AND H. E. LOCKHART-MUMMERY

From St Mark's Hospital, London

SUMMARY This study gives detailed information on the two principal groups of patients undergoing excisional surgery with a permanent artificial stoma for Crohn's disease of the large bowel. During the years 1952-71, 64 patients were treated by total proctocolectomy and ileostomy and 26 patients by excision of the distal large bowel and colostomy.

In the group of patients undergoing proctocolectomy, there were two postoperative and six late deaths. Of the 56 patients alive at the end of the follow-up period (average length of follow-up 8.1 years), four had shown evidence of recurrent disease. In each case this occurred following a staged proctocolectomy and at, or immediately proximal to, the ileostomy: the shortest interval between surgery and recurrence was just under 10 years.

Among the patients treated by excision of the distal large bowel, there were two unrelated late deaths: with an average duration of follow up of 7.3 years, recurrent disease occurred in only one of the 24 patients alive at the concluding date for this study.

The essential diagnostic features of large bowel Crohn's disease have been delineated in a number of studies from this hospital (Lockhart-Mummery and Morson, 1960, 1964; Morson, and Dawson, 1972) and, using these criteria, the surgery undertaken in 84 cases was described (Jones, Lennard-Jones, and Lockhart-Mummery, 1966). The intention in the present paper is to present the results of surgery in the two main groups of patients undergoing excisional operations with the establishment of a permanent artificial stoma. These operations are total proctocolectomy and ileostomy (carried out for diffuse or extensive disease) and excision of the distal large bowel with a terminal colostomy (undertaken for disease apparently confined to the sigmoid colon and rectum). The study includes patients treated by these operations mentioned in the earlier paper and is an elaboration of the results already published in brief by Lockhart-Mummery (1972).

The criteria which have been applied for the selection of patients for this enquiry are as follows. (1) Patients have been included if (a) laparotomy only, (b) appendicectomy, (c) ileostomy or colostomy, or (d) an anal operation had previously been carried out elsewhere. (2) Patients have been excluded if (a)

excisional surgery, a resective operation or a by-pass procedure had been undertaken before referral, or if (b) the proctocolectomy was completed at another hospital. (3) Cases in which the histopathological diagnosis remains in doubt ('unclassified colitis') have been excluded and this series is composed entirely of patients with proven Crohn's disease.

Total Proctocolectomy

The series consisted of 38 male and 26 female cases with an average age at the completion of the proctocolectomy of 38.6 years (range 19 to 71 years) and 39.9 years (range 16 to 82 years) respectively.

The length of history (regarding, where relevant, an anal lesion as the first symptom) to the first excisional surgery varied from three months to 15 years with a mean of 4.5 years.

INDICATIONS FOR SURGERY

Indications for surgery were, in general, extensive disease with marked symptoms failing to respond to medical management. The symptoms were usually of a chronic continuous nature, but in eight cases a more rapidly progressive course and, in 11 patients, recurrent acute attacks formed the basis for a surgical approach. In three cases surgery was undertaken as

an urgent measure (for pericolic abscess in two patients and commencing colonic dilatation in one) but no case of free colonic perforation or severe dilatation of the colon was encountered. Severe and intractable anal lesions played an important part in the decision for surgery in 37 patients; in eight cases these lesions were the major deciding factor.

TYPE AND YEAR OF OPERATION

Total proctocolectomy and ileostomy was undertaken as a one-stage procedure in 27 patients and in more than one stage in 37 patients. The earliest case in the former group was operated on in 1957 and, in the latter group, in 1952. The distribution of the cases according to the year of the completion of the surgery is shown in fig 1 which demonstrates the relative increase in one-stage operations in more recent years.

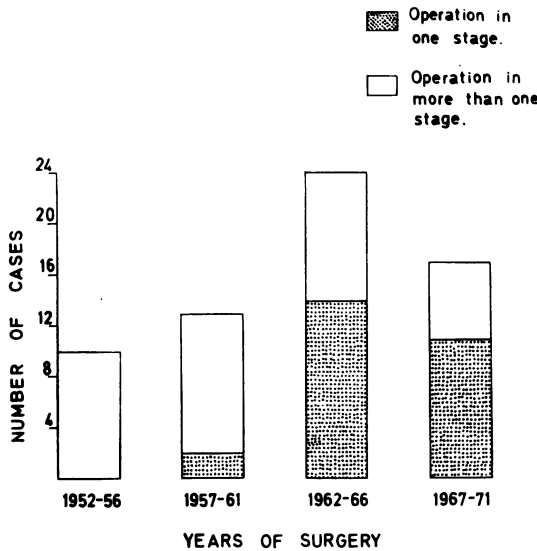


Fig 1 Year of completion of proctocolectomy in 64 cases.

PATHOLOGY

Pathological examination of the specimen showed total colonic and rectal involvement in 43 cases, complete involvement of the colon together with anal lesions in five patients, and less extensive disease mainly of the distal half of the large bowel in 16 cases. The terminal ileum showed histological evidence of disease in 20 cases; the distribution of the disease is shown diagrammatically in figure 2.

IMMUNOSUPPRESSIVE OR CORTICOSTEROID THERAPY

Apart from the patient being treated with azathioprine for recurrent disease (vide infra), three patients have received this drug postoperatively for periods of between eight and 18 months up to the end of the follow-up period. In one case this was given to assist healing of a very large perineal wound with a urethral fistula, and in the other two patients as a prophylactic measure because of extensive terminal

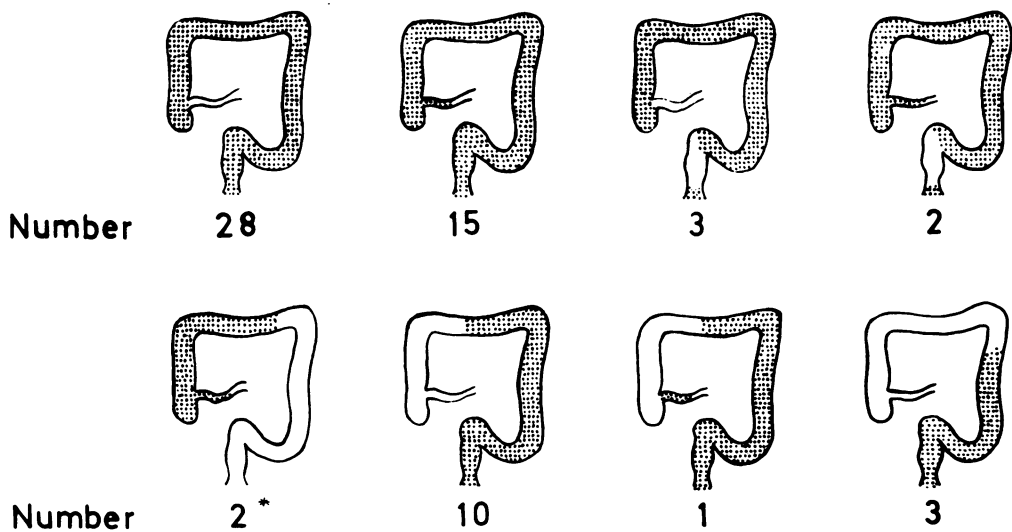


Fig 2 Distribution of disease in 64 patients undergoing proctocolectomy¹.

¹Staged proctocolectomy: residual colon reported as 'burnt-out' phase of the disease.

ileal disease in the operation specimen. Maintenance corticosteroid therapy was not used in these patients.

POSTOPERATIVE MORTALITY AND COMPLICATIONS

Nine patients developed major postoperative complications: intraabdominal sepsis was the most frequent, such complication occurring in seven patients, two¹ of whom died in the postoperative period. Minor complications in 22 patients were related to the perineal wound in 12 cases.

LATE MORTALITY AND MORBIDITY

There were six late deaths: two deaths in the early years were due in one case to intestinal obstruction from torsion of the terminal ileum² and in the other to spreading perineal sepsis². The causes in the other four cases were myocardial infarction in two patients, suicide in one², and multiple metastases from a primary carcinoma of the rectum in a patient who died 18 months after proctocolectomy (case reported by Jones, 1969).

The date of healing of the perineal wound was known accurately in 47 of the 57 patients who left hospital and survived more than one year to the end of the follow-up period of the study. Healing was complete in six months or less in 16 patients, within one year in a further 11 patients, and within two years in 13 further cases. Seven patients had an unhealed perineal wound more than two years after surgery. Ten of the 57 patients (17.5%) required further inpatient treatment for an unhealed wound.

Other late complications related to surgery included complete intestinal obstruction in two patients due to terminal ileal torsion in one case and to adhesions in the other.

Patients were followed until 1 January 1972: the average length of follow up of the 56 patients alive at that time was 8.1 years. Diseases of a general nature were very uncommon; two patients, however, required surgical intervention for renal calculi.

RECURRENT DISEASE

Twenty-seven patients underwent a one-stage total proctocolectomy and ileostomy: there has been no evidence of recurrent disease in any patient in this group although in eight of these cases the terminal ileum was involved histologically.

Recurrence has been found in four of the 37 patients in whom a staged proctocolectomy was carried out. Twelve of these 37 patients had terminal ileal disease in the excised specimen but of the four

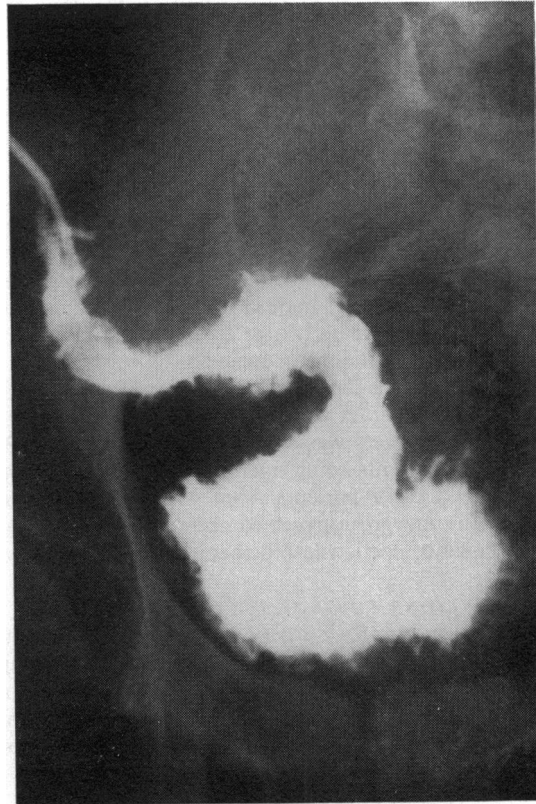


Fig 3 Ileostomy barium enema showing recurrent disease in distal ileum.

with recurrence, in only two was there definite evidence of involvement of the terminal ileum initially.

The shortest interval between surgery and recurrence was almost 10 years and the longest period was 17 years. In three of the four cases, the recurrent disease was at the ileostomy and removal of the affected segment with the construction of a new stoma has been followed by seven- and eight-year periods of freedom from disease in two patients; the third patient has only recently undergone this further excision. Pathological examination of the specimen in each of these three cases showed involvement of the stoma and some 10 cm of terminal ileum. The fourth patient has disease just proximal to the ileostomy radiologically involving about 20 cm of bowel (fig 3): treatment at present is by azathioprine.

Figure 1 shows that the patients who underwent a one-stage operation were treated mainly in the later years of this study: the average length of follow up in the group was 5.6 years. For those treated by a staged proctocolectomy, the mean follow-up period

¹One of these deaths has been previously reported (Jones *et al.*, 1966).

Deaths already reported (*ibid*)

was 10.1 years. It is therefore possible that the absence of recurrence in the former group may be related to the shorter period of follow up: a considerably longer period of observation will be required to elucidate this point.

Excision of the Distal Large Bowel

Twenty-six patients underwent a standard combined excision with a terminal left iliac colostomy for disease apparently confined to the rectum and sigmoid colon. There were 15 male cases with a mean age at surgery of 49.7 years (range 17 to 73 years) and 11 female cases with a mean age of 51.6 years (range 18 to 79 years). The length of history varied from seven months to 12 years with an average duration of 3.4 years. The surgery was carried out in the years 1953-71, seven patients being operated on in the years up to 1961 and 19 patients from 1962 onwards. No patient in this group received immunosuppressive or maintenance corticosteroid therapy postoperatively.

INDICATIONS FOR SURGERY

The indications for surgery were severe, persistent anal lesions (nine patients), rectal disease failing to respond to medical treatment (six patients), or a combination of these two presentations (eight patients). In seven cases a severe anal stenosis or

rectal stricture developed, the latter being the main indication for operation in three patients.

PATHOLOGY

Examination of the specimen showed histological involvement of the sigmoid colon, rectum, and anal canal in 19 patients (figs 4 and 5), disease of the sigmoid and rectum in two cases, of the rectum only in one case, and of the rectum and anal canal in three patients. In one patient with very extensive perianal ulceration, the disease was limited to this area and the anal canal.

POSTOPERATIVE COMPLICATIONS

The postoperative period was free of complications in 16 patients, minor setbacks occurred in six cases, and major complications in four patients (intestinal obstruction two, localized intraabdominal sepsis two).

LATE MORTALITY AND MORBIDITY

Patients were followed up until 1 January 1972. Two patients died during the follow-up years: one at the age of 75 years from a coronary occlusion 11 years after surgery, the other at the age of 76 years from bronchopneumonia three years after surgery. Neither had had evidence of recurrent disease.

The perineal wound healed in less than six months

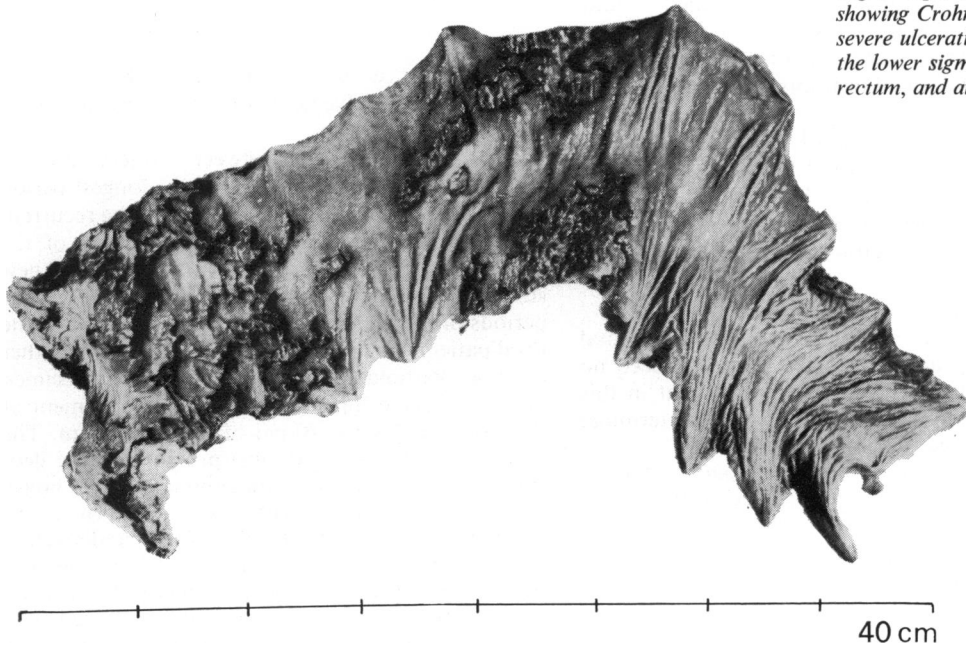


Fig 4 Operation specimen showing Crohn's disease with severe ulceration localized to the lower sigmoid colon, rectum, and anal canal.




Fig 5 Close-up view of lower end of specimen in figure 4.

in six cases, within one year in eight further patients, and within two years in one case. The wound remained unhealed for more than two years in three patients while in eight cases the exact date of healing was uncertain. Five of the 26 patients (19.2%) required readmission for treatment to the wound.

RECURRENT DISEASE

Twenty-three patients were alive at the end of the follow-up period having had no evidence of recurrent disease and the average length of follow up in these cases was 7.3 years.

The disease recurred in one patient. Investigation six years after rectal excision showed terminal ileal disease and this area, together with the caecum and part of the ascending colon, was resected. The colon in this specimen was normal but two years later there was a further recurrence in the terminal ileum as well as in the residual colon and proctocolectomy was completed eight and a half years after the original rectal excision.

Problems Common to Both Groups of Patients

ANAL LESIONS

These were present during the course of the disease in all but six of the patients treated by total proctocolectomy and in 23 of the 26 patients who underwent rectal excision and the effect of their presence on treatment policy has already been described. The lesions were often multiple and the incidence of the various types is shown in the table. Figures 6 and 7 illustrate some of these lesions.

THE PERINEAL WOUND

The exact date of healing was known in 65 patients: this occurred in less than six months in 22 cases (33.8%) and within one year in 41 patients (63.1%). A previous study of patients at this hospital in whom the rectum was excised for ulcerative colitis has shown that in 51% of cases the perineal wound had healed in less than six months and in 77.1% of patients healing was complete within one year (Ritchie, 1972).

Operation	Type of Anal Lesion						
	Fistula	Abscess	Ulceration	Fissure	Tags	Stenosis	Recto-vaginal Fistula
Total proctocolectomy (64 patients)	30	22	22	20	18	14	7
Excision of distal large bowel (26 patients)	14	7	7	4	10	2	2

Table Incidence of various types of anal lesion

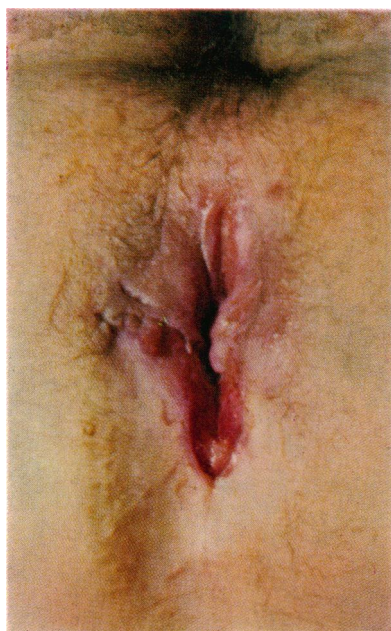


Fig. 6.

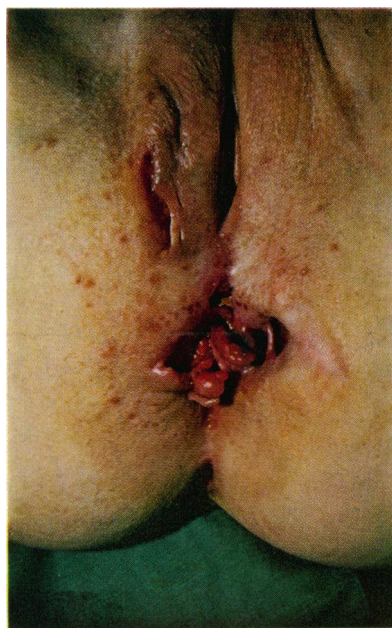

Fig. 7.

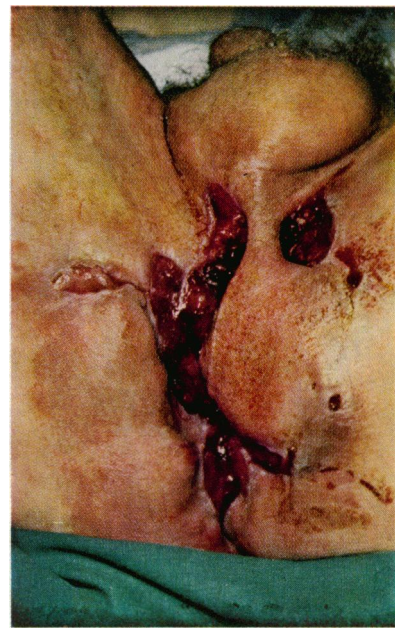


Fig. 8.

Fig 6 *Indolent, undermining, perianal ulceration in a patient with extensive large bowel disease.*

Fig 7 *Oedematous anal tags, undermining ulcers, and anal fistula in a girl with disease of the distal sigmoid and rectum.*

Fig 8 *Unhealed perineal wound 16 months after rectal excision (second stage of total proctocolectomy).*

Thus, although the present figures for patients with Crohn's disease do not differ very markedly from those for patients with ulcerative colitis, it is found in practice that considerable difficulties in healing may be encountered in a minority of patients with Crohn's disease. An example of an unhealed and indolent perineal wound in a patient referred from elsewhere is shown in figure 8.

Discussion

At this hospital, large bowel Crohn's disease is seen considerably more frequently than disease involving the small bowel. Of the various surgical approaches used during the last 20 years, the two operations described in this paper have proved the most successful when assessed on the criterion of recurrence rate.

An initial ileostomy for extensive colonic disease has proved disappointing in the past at this hospital (Jones *et al*, 1966) although rather more success has been reported by other authors (Truelove, Ellis, and Webster, 1965; Oberhelman, Kohatsu, Taylor, and

Kivel, 1968; Burman, Thompson, Cooke, and Williams, 1971). Ten patients in the present study had an ileostomy alone in the first instance. Similarly, seven of the 26 patients treated by rectal excision had undergone colostomy previously and this had proved ineffective in controlling the disease. Limited resection for segmental colonic disease at this hospital has been only moderately successful while total colectomy and ileorectal anastomosis has shown over the period of follow up a recurrence rate of approximately 50% (Baker, 1971; Lockhart-Mummery, 1972).

The operative mortality in the group treated by proctocolectomy was 3.1% (two patients out of 64), the late mortality related to the disease or surgery 6.4% (four patients out of 62), and the late unrelated mortality 3.2% (two patients out of 62). The recurrence rate can be considered as 7.1% (four patients out of 56) over a follow-up period averaging 8.1 years.

There are few large series in the literature of patients with Crohn's disease treated by total

proctocolectomy but one series shows results similar to those reported here. This is the group of 39 cases reported by de Dombal, Burton, and Goligher (1971a): 37 of these patients were followed and only four (10.8%) developed recurrence. Other authors, however, report a considerably higher recurrence rate: Cooke, Burman, and Williams (1970) found 16 patients with recurrent disease out of 37 treated by proctocolectomy.

It is interesting that all the four patients in this series who developed recurrent disease did so at, or immediately proximal to, the ileostomy and that no higher skip lesion or widespread small intestinal recurrence has been seen so far among the 56 patients in the group still being followed. The sites of recurrence in five patients following proctocolectomy have recently been described in detail by Goligher (1972) and were very similar to those reported in this study, ie, involving the terminal segment of ileum only. However, the recurrences differ from those in the present series in that two occurred within five years of surgery and four were seen after a one-stage total proctocolectomy and ileostomy.

There is no comparable series in the literature of patients with distal large bowel involvement treated by rectal excision alone. In the comprehensive analysis of the surgical treatment undertaken in 244 patients at Leeds (de Dombal, Burton, and Goligher, 1971b), there is no mention of this operation, suggesting perhaps that this distribution of the disease is seen more frequently at this hospital than elsewhere. This type of disease occurs predominantly in the older age groups, and the symptoms of diarrhoea, rectal pain, and bleeding with, in most cases, extensive anal lesions, can be most distressing: a well controlled colostomy would appear a preferable alternative if medical management is unsuccessful. With a mean follow up of 7.3 years, only one case of recurrent disease (4.2%) has been seen in the group and this, together with no operative mortality or related late death, indicates that rectal excision is a most success-

ful operation when medical treatment and anal surgery have failed to relieve symptoms in this localized form of distal disease.

We are grateful to our colleagues for permission to study the records of patients admitted under their care and to Dr Basil Morson for reviewing the pathology in a number of these cases. Mr Norman Mackie was responsible for the photographic work and we thank him for his help.

References

- Baker, W. N. W. (1971). Ileo-rectal anastomosis for Crohn's disease of the colon. *Gut*, **12**, 427-431.
- Burman, J. H., Thompson, H., Cooke, W. T., and Williams, J. A. (1971). The effects of diversion of intestinal contents on the progress of Crohn's disease of the large bowel. *Gut*, **12**, 11-15.
- Cooke, W. T., Burman, J. H., and Williams, J. A. (1970). Post colectomy ileitis. (Unpublished data quoted by Burman, J. H., Cooke W. T., and Williams, J. A. (1971). The fate of ileorectal anastomosis in Crohn's disease. *Gut*, **12**, 432-436).
- de Dombal, F. T., Burton, I., and Goligher, J. C. (1971a). Recurrence of Crohn's disease after primary excisional surgery. *Gut*, **12**, 519-527.
- de Dombal, F. T., Burton, I., and Goligher, J. C. (1971b). The early and late results of surgical treatment for Crohn's disease. *Brit. J. Surg.*, **58**, 805-816.
- Goligher, J. C. (1972). Ileal recurrence after ileostomy and excision of the large bowel for Crohn's disease. *Brit. J. Surg.*, **59**, 253-259.
- Jones, J. H., Lennard-Jones, J. E., and Lockhart-Mummery, H. E. (1966). Experience in the treatment of Crohn's disease of the large intestine. *Gut*, **7**, 448-452.
- Jones, J. H. (1969). Colonic cancer and Crohn's disease. *Gut*, **10**, 651-654.
- Lockhart-Mummery, H. E., and Morson, B. C. (1960). Crohn's disease (regional enteritis) of the large intestine and its distinction from ulcerative colitis. *Gut*, **1**, 87-105.
- Lockhart-Mummery, H. E., and Morson, B. C. (1964). Crohn's disease of the large intestine. *Gut*, **5**, 493-509.
- Lockhart-Mummery, H. E. (1972). Crohn's disease of the large bowel. *Brit. J. Surg.*, **59**, 823-826.
- Morson, B. C., and Dawson, I. M. P. (1972). *Gastrointestinal Pathology*. Blackwell, Oxford.
- Oberhelman, H. A., Jr., Kohatsu, S., Taylor, K. B., and Kivel, R. M. (1968). Diverting ileostomy in the surgical management of Crohn's disease of the colon. *Amer. J. Surg.*, **115**, 231-240.
- Ritchie, J. K. (1972). Ulcerative colitis treated by ileostomy and excisional surgery: fifteen years' experience at St. Mark's Hospital. *Brit. J. Surg.*, **59**, 345-351.
- Truelove, S. C., Ellis, H., and Webster, C. U. (1965). Place of a double-barrelled ileostomy in ulcerative colitis and Crohn's disease of the colon: a preliminary report. *Brit. med. J.*, **1**, 150-153.