

The pseudomembranous colitis associated with clindamycin therapy—a viral colitis

H. W. STEER¹

From Southampton General Hospital

SUMMARY Four patients are described who developed pseudomembranous colitis in association with clindamycin therapy.

Rectal biopsies from two patients were studied with the electron microscope and compared with the ultrastructural appearance of the rectal mucosa from seven normal people. Ultrastructural evidence for a viral colitis was obtained. The significance of the clindamycin therapy to the viral colitis and the contribution of the viral colitis to the clinical state are discussed.

Pseudomembranous colitis is a well defined histopathological condition (Goulston and McGovern, 1965), whose aetiology is ill defined and probably multiple. It has been described in association with antibiotics (Cummins, 1961; Hale and Cosgriff, 1957; Pearce and Dineen, 1960; Cohen, McNeill, and Wells, 1973), postoperatively (Pettet, Baggenstoss, Dearing, and Judd, 1954), with primary colonic diseases, especially those producing obstruction (Kleckner, Bagen, and Baggenstoss, 1952), and with various systemic conditions (Goulston and McGovern, 1965).

Although the pseudomembrane can occur at any site along the gastrointestinal tract (Pettet, Baggenstoss, Dearing, and Judd, 1954) that associated with clindamycin therapy is limited to the colon and has yet to be described in other parts of the gastrointestinal tract. A characteristic feature of the clindamycin-associated pseudomembranous colitis

has been the pathologist's inability to isolate any infective organism as the stools show no evidence of any pathogenic bacteria (Cohen *et al*, 1973; Tedesco, Stanley, and Alpers, 1974; Dyck, Viteri, and Howard, 1974; Temperley, 1974).

The present study was undertaken in order to determine whether any aetiological information could be gained by an ultrastructural study of the colonic mucosa in pseudomembranous colitis associated with clindamycin therapy.

Material and Methods

Rectal biopsies were obtained from four patients who developed pseudomembranous colitis while being treated with clindamycin. The patients received 150-300 mg of clindamycin every six hours. Specimens obtained from all patients were fixed in phosphate-buffered 10% neutral formalin for 24 hours at 4°C. They were dehydrated in a graded series of ethyl alcohols and cleared in benzene, after which they were embedded in paraffin wax. The

¹Present address: Nuffield Department of Surgery, Radcliffe Infirmary, Oxford.

Received for publication 17 June 1975.

Patient	Sex	Age (yr)	Interval from Initiation of Clindamycin C to Diarrhoea (Days)	Other Relevant Diagnoses	Other Antibiotics	Outcome
1.	F	71	11	Rheumatoid arthritis	None	Recovery after 28 days
2.	M	74	7	Septic arthritis right hip	Lincomycin for 1 day	Recovery after 6 days
3.	M	73	16	Peripheral vascular disease, pyelonephritis	None	Died after 22 days
4.	M	61	25	Polycythaemia, rubra vera, chronic bronchitis, peripheral vascular disease	None	Died after 4 days

Table Details of the four patients suffering from pseudomembranous colitis.

tissues were subsequently sectioned at 6 μm and mounted on glass slides. Several staining procedures were performed—haematoxylin and eosin, the periodic acid-Schiff reaction (McManus, 1948), and Mallory's phosphotungstic acid-haematin method (see Pearse, 1960). Colonic biopsies from four patients not suffering from pseudomembranous colitis and not receiving clindamycin were processed in a similar manner as controls.

Tissues from patients 3 and 4 (table) were used for an electron microscopic study. In addition, specimens were obtained from seven patients aged 25 years to 70 years who were being investigated for functional gut disorders, in whom no abnormality was found and who were receiving no medication. The specimens used for the electron microscopic study were fixed in 5% cacodylate-buffered glutaraldehyde (pH 7.3) for four hours at 4°C and subsequently washed in four changes of cacodylate-buffered 10% sucrose solution for 24 hours and were then postfixed in veronal acetate-buffered 2% osmium tetroxide (pH 7.3) for one hour at 4°C, rinsed in chilled tap water at 4°C and dehydrated in a graded series of ethyl alcohol solutions; propylene oxide was used as the clearing agent. The cleared tissues were embedded in Araldite.

Sections 1 μm thick were cut with a glass knife on an ultramicrotome and stained by the method of Richardson, Jarret, and Fincke (1960). These sections were examined with a light microscope and, as a result, certain limited areas were selected from which sections approximately 25 nm thick were cut with a glass knife. These sections were stained with 1% uranyl acetate and Reynold's lead citrate, and examined with a Philips 300 electron microscope.

Results

Between January 1973 and July 1974 four patients developed pseudomembranous colitis whilst receiving clindamycin therapy at a single district general hospital. The relevant clinical details are given in the table. The patients developed diarrhoea at a variable time after starting the clindamycin therapy. The stools consisted of a brown fluid containing a particulate material which was light tan in colour. The diarrhoea was associated with pyrexia, tachycardia, episodes of relative hypotension, non-specific abdominal pains, variable abdominal distension and a polymorphonuclear leucocytosis. The relationship between the clindamycin therapy, the pyrexia, the diarrhoea and the polymorphonuclear leucocytosis for patient number 3 is shown in figure 1. Stool cultures did not reveal any pathogenic bacteria.

On sigmoidoscopy, the rectal mucosa was erythematous and its surface was covered with plaques of a

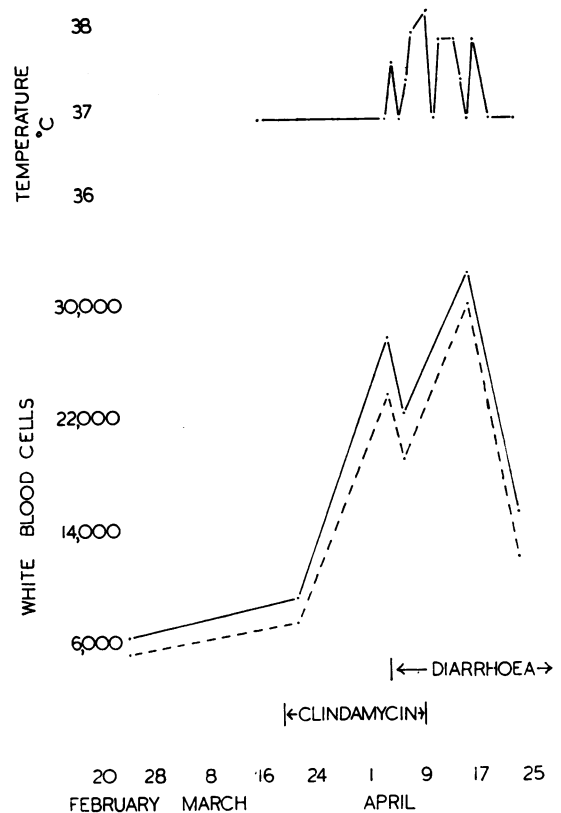


Fig 1 The relationship between temperature, leucocytosis, diarrhoea and clindamycin therapy in patient number 3. The polymorphonuclear leucocyte count is indicated by the broken line.

creamy exudate. There was no macroscopic mucosal ulceration and the exudate, as well as the intraluminal contents, did not contain any visible blood. Fragments of the exudate had become detached from the mucosa and, when mixed with the liquid faeces, formed the particulate portion of the diarrhoea.

The diagnosis was confirmed by independent histopathologists examining the biopsy material. The limitation of the pseudomembrane to the colon was substantiated in patients 3 and 4 at postmortem examination.

HISTOLOGY

Various stages in the development of the pseudomembrane are observed. An irregularity of the colonic epithelium develops: the brush border disappears and bizarre cytoplasmic processes appear on the luminal aspect of the epithelial cells (fig. 2). Associated with these changes polymorphonuclear

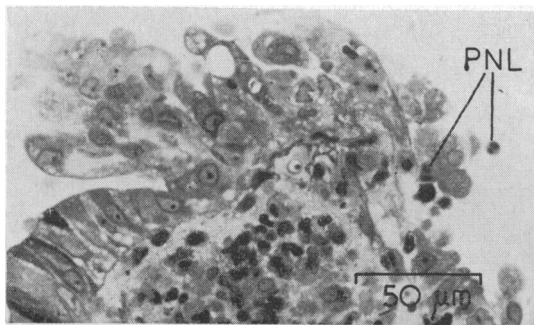


Fig 2 Surface epithelium of a patient with pseudomembranous colitis. The localized atypicality of the colonic epithelium is apparent when compared with the more normal arrangement of the epithelium at the left hand side of the photomicrograph. Polymorphonuclear leucocytes (PNL) are migrating through the abnormal epithelium. Methylene blue-Azur 11.

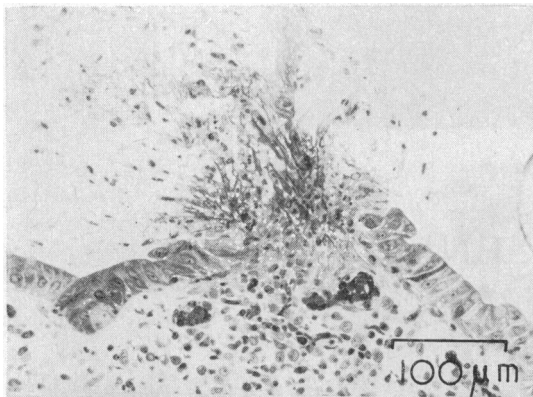


Fig 3 Localized ulceration of the colonic epithelium in pseudomembranous colitis. The mucosal contents, together with a fibrin meshwork and polymorphonuclear leucocytes, appear to be erupting into the colonic lumen. Methylene blue-Azur 11.

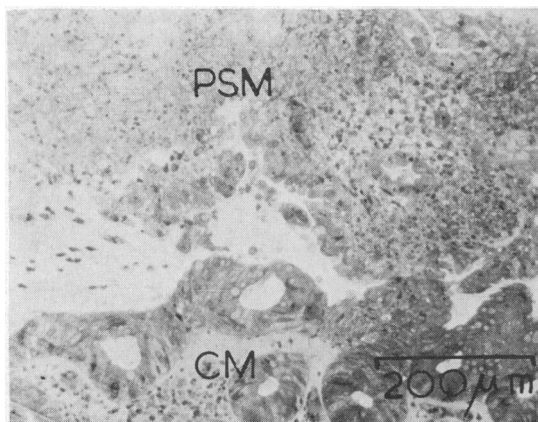


Fig 4 The pseudomembrane (PSM) covers the colonic mucosa (CM) and has a localized attachment to this mucosa. Methylene blue-Azur 11.

leucocytes migrate from the capillaries into the mucosal connective tissue and the colonic epithelium. These changes are not generalized but occur at localized areas of the colonic mucosa. Discrete epithelial ulcers appear and at such sites there is a considerable increase in the polymorphonuclear leucocyte concentration. Fibrin is present in the connective tissue at such sites. From the areas of epithelial ulceration, the mucosal tissue is shed into the colonic lumen: the polymorphonuclear leucocytes and fibrin appear to erupt into the lumen (fig 3). The epithelium adjacent to such ulcerated regions appears normal. The tissue being exuded into the lumen consists of polymorphonuclear leucocytes, mucous and epithelial cells enmeshed in a fibrin network and forms the pseudomembrane of pseudomembranous colitis. This process continues until the colonic mucosa is covered by a pseudomembrane which is attached to the colonic mucosa at those sites of localized ulceration (fig 4).

ULTRASTRUCTURE

The colonic mucosa has a complete epithelial covering except at the areas of focal ulceration where the pseudomembrane is attached to the mucosa. In pseudomembranous colitis there is a decrease in the number of microvilli. Some epithelial cells possess an irregular surface membrane (figs 5 and 6), and associated with it and the remaining microvilli there are numerous round particles, about 50 nm diameter (figs 5 and 7), which have a limiting membrane about 7 nm thick consisting of two electron-dense layers separated by an electron-lucent layer. Such particles are not found in the normal colon.

The epithelial cells of patients suffering from pseudomembranous colitis contain supranuclear membrane-bound vesicles, 0.2 μm to 1.0 μm diameter (figs 5 and 8). These vesicles are absent from the epithelial cells of the normal colon and they contain particles, about 50 nm diameter, which are bounded by a limiting membrane about 7 nm thick. These particles are identical to those related to the surface membrane of these cells. Occasional vesicles are connected to the surface membrane and liberate their contents into the colonic lumen (fig 6). The number of cytoplasmic vesicles containing these particles varies amongst different epithelial cells and are absent from the goblet cells. The increase in the number containing these distinctive particles is associated with a dilatation of the granular endoplasmic reticulum and the perinuclear space (fig 6). The nucleus enlarges and the chromatin has a flocculent appearance (fig 6). This process continues with a further increase in the number of the cytoplasmic vesicles at the expense of the other cytoplasmic organelles (fig 9). The cytoplasm of such

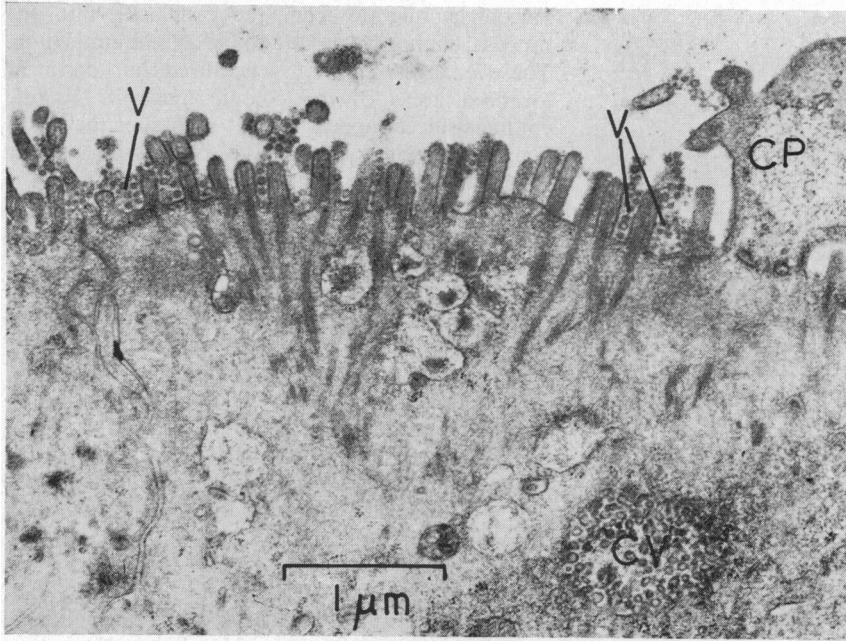


Fig 5 Surface of two colonic epithelial cells with numerous virus particles (V) situated between the microvilli of these cells. At one place the surface membrane is deformed by a bizarre cytoplasmic process (CP). In one of the cells a cytoplasmic vesicle (CV) contains virus particles.

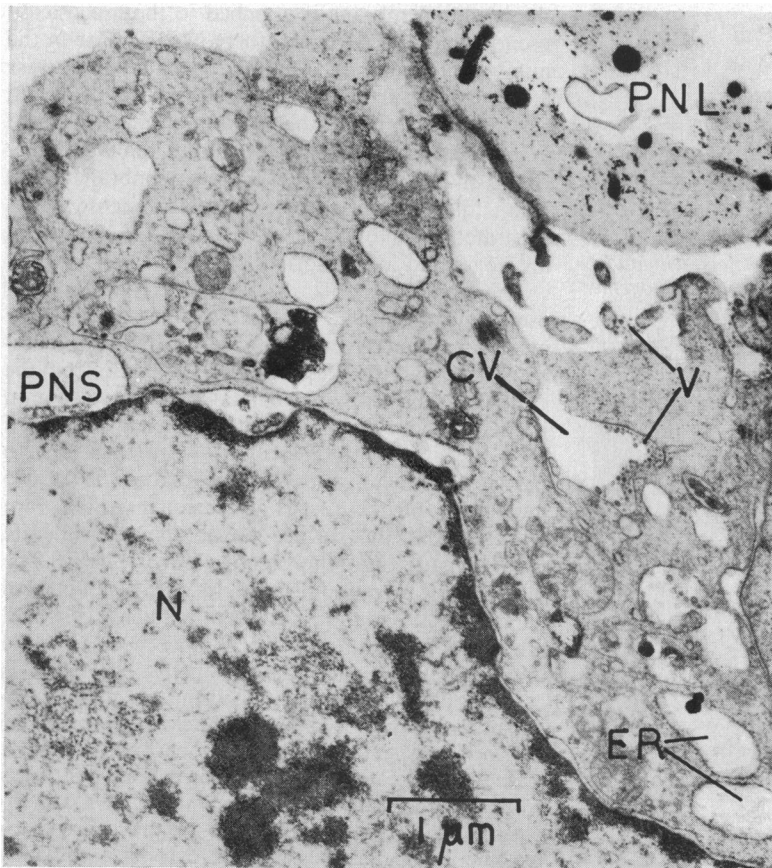


Fig 6 Colonic epithelial cell. The dense chromatin of the nucleus (N) has become aggregated into specific areas, the perinuclear space (PNS) is dilated and the cytoplasmic vesicles (CV) containing virus particles communicate with the surface membrane. The granular endoplasmic reticulum (ER) is dilated and an intraluminal polymorphonuclear leucocyte (PNL) is present.

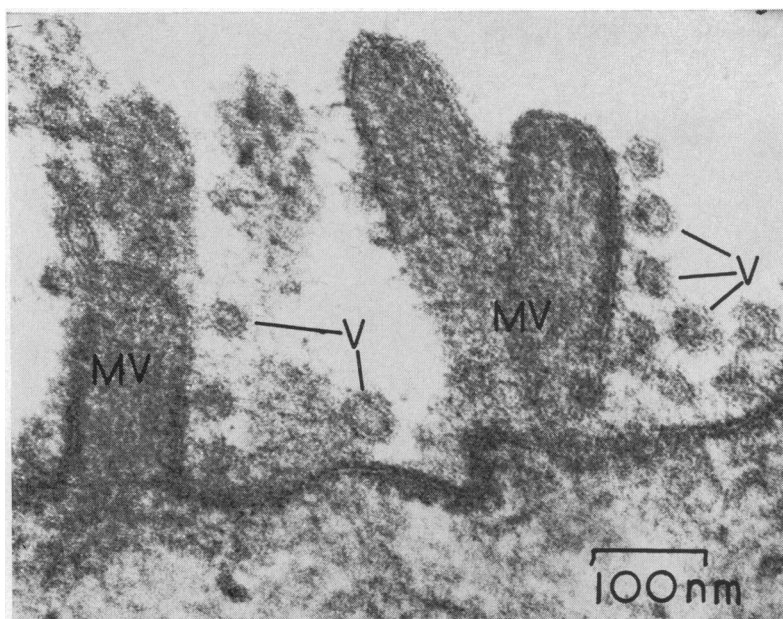


Fig 7

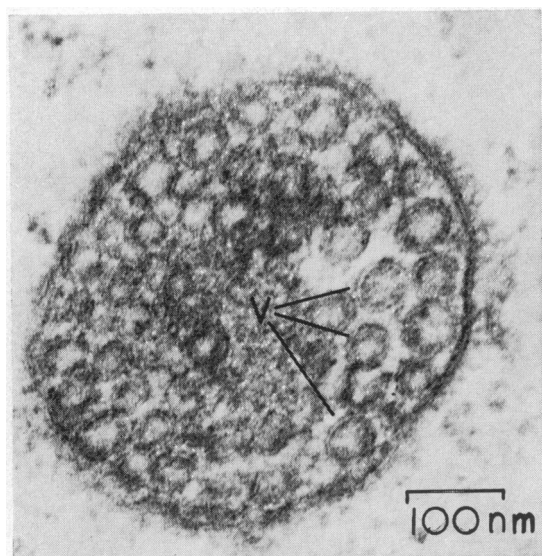


Fig 8

Fig 7 Microvillous surface (MV) of a colonic epithelial cell. Virus particles (V) are situated between the microvilli.

Fig 8 Cytoplasmic vesicle from a colonic epithelial cell. The vesicle has a limiting membrane consisting of two electron-dense layers separated by an electron-lucent layer. The vesicle contains numerous virus particles (V).

cells is darkly staining and these cells are frequently shed into the colonic lumen.

The mucosal connective tissue of patients with pseudomembranous colitis possesses several characteristic features. These are maximal at the sites of epithelial ulceration. The blood vessels at the sites of epithelial ulceration contain fibrin which is also found

in the surrounding connective tissue where a fibrin meshwork is formed extending up to the epithelial basement membrane adjacent to the sites of epithelial ulceration.

The endothelium of capillaries near the regions of epithelial ulceration possess membrane-bound vesicles about 0.4 μm in diameter (figs 10 and 11),

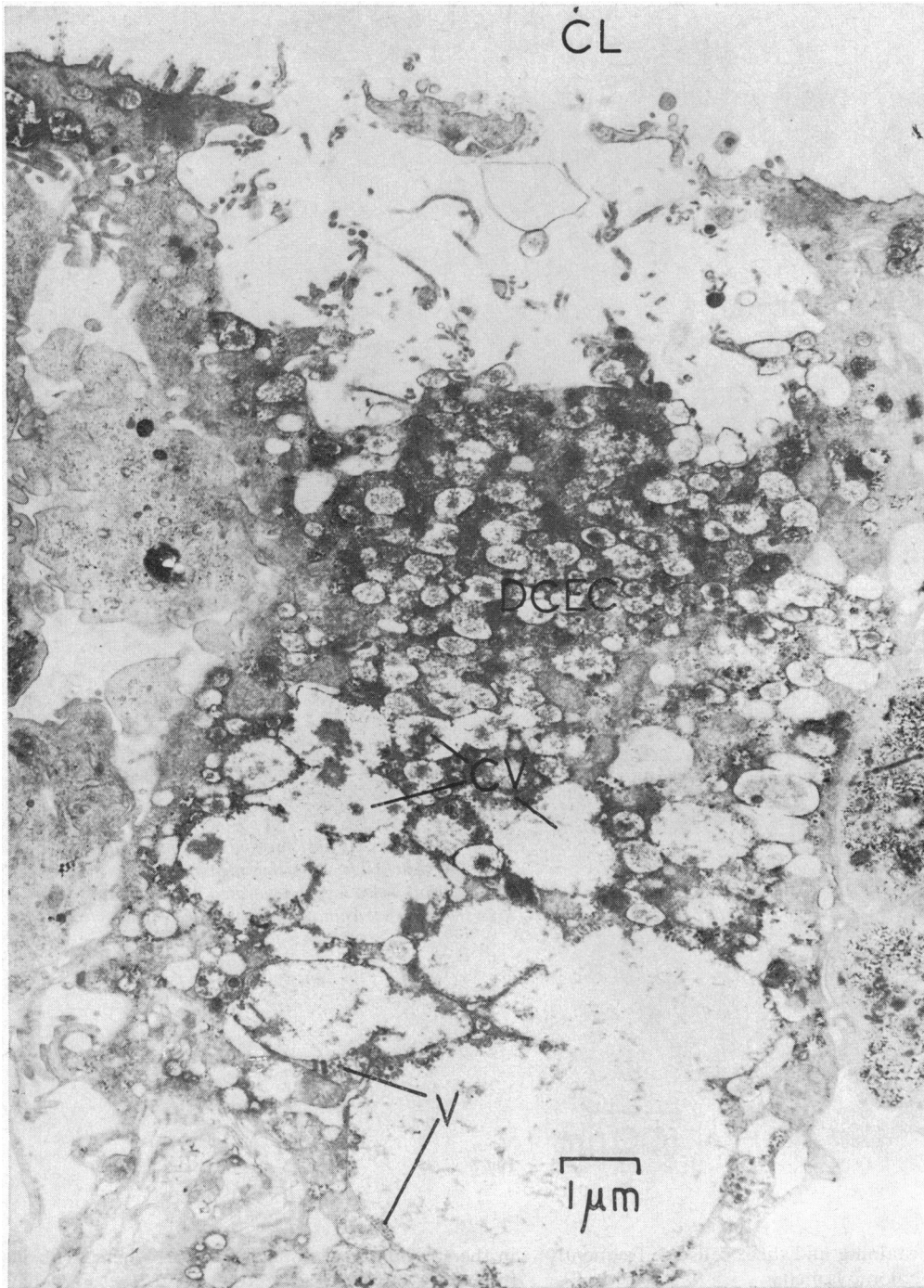


Fig 9 A degenerating colonic epithelial cell (DCEC) containing numerous cytoplasmic vesicles (CV) of variable size. These vesicles possess virus particles (V). These degenerating cells are shed into the colonic lumen

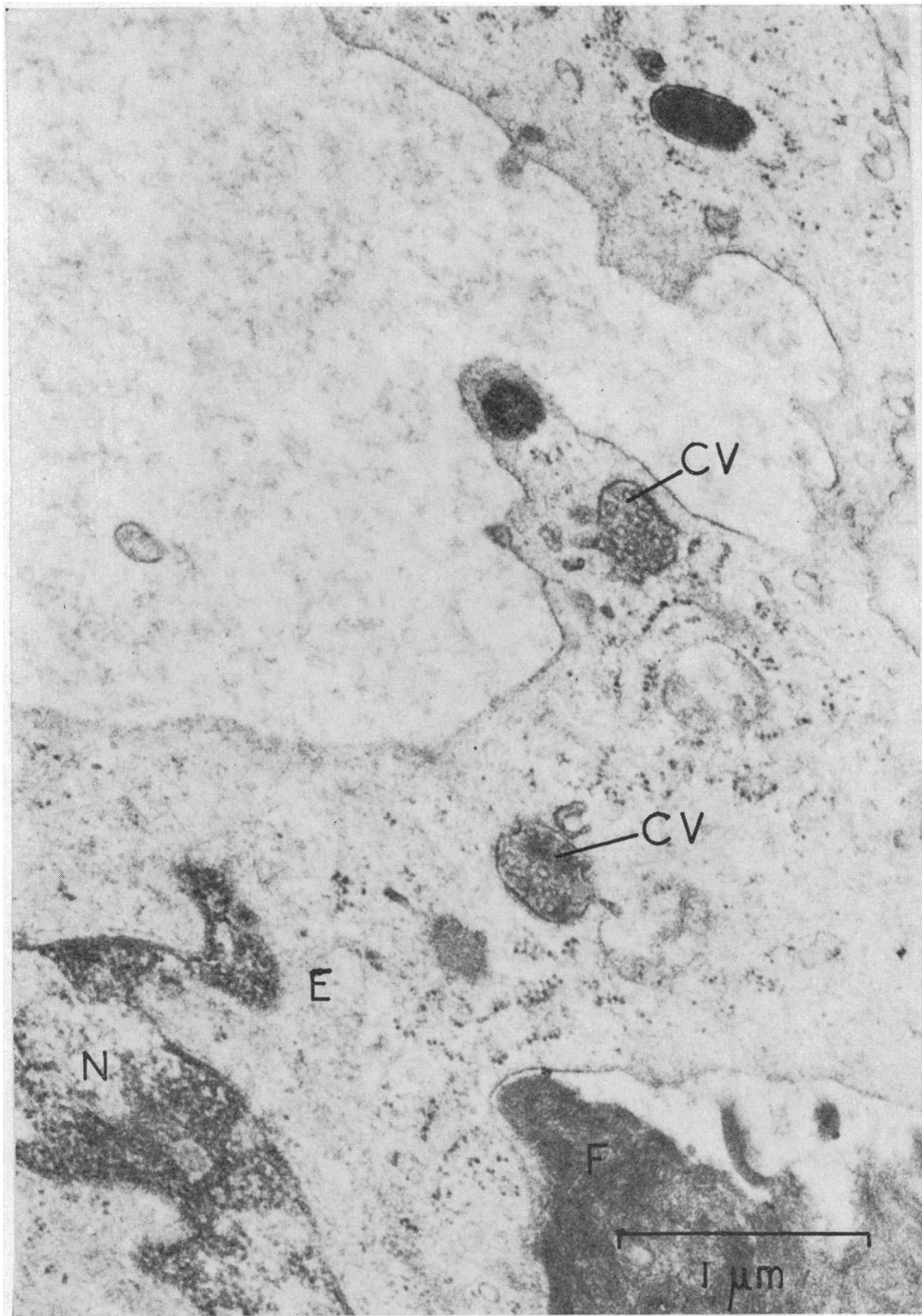


Fig 10 *The endothelial cell (E) of a colonic mucosal capillary. Two cytoplasmic vesicles (CV) contain virus particles. Fibrin (F) is seen outside the endothelial cell. The nucleus (N) of the endothelial cell is also apparent.*

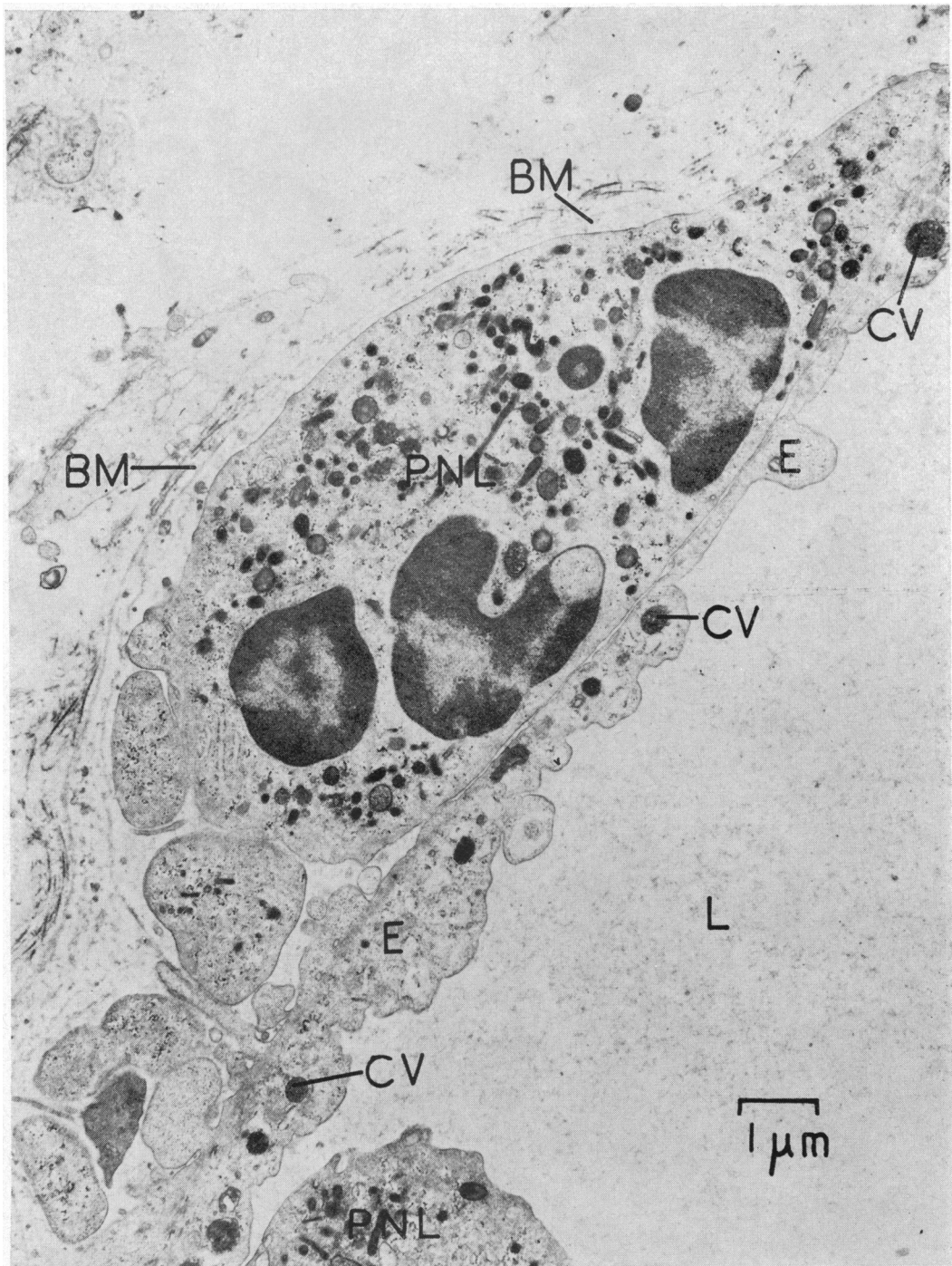


Fig 11 A colonic mucosal capillary with its endothelial cell (E) lining the lumen (L). The endothelial cell contains cytoplasmic vesicles (CV) which possess virus particles. Part of a polymorphonuclear leucocyte (PNL) has migrated through the endothelium (E) to lie between the latter and its basement membrane (BM).

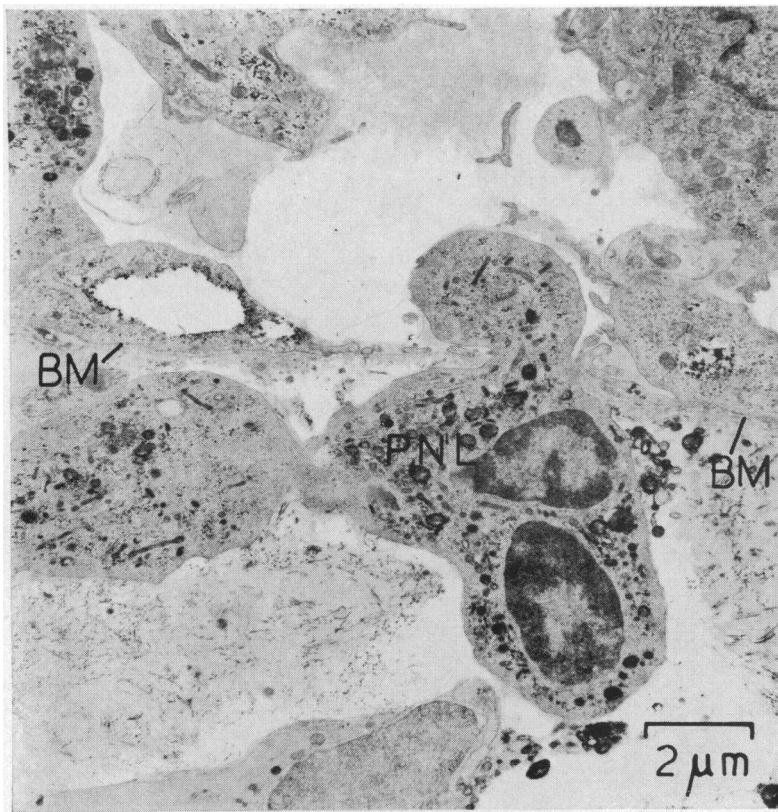


Fig 12 The basal region of the colonic epithelium with its underlying basement membrane (BM) which is breached by a polymorphonuclear leucocyte (PNL) migrating from the mucosal connective tissue into the colonic epithelium.

which contain particles, about 50 nm in diameter, which have a limiting membrane, about 7 nm thick, and are similar to those particles seen in the colonic epithelial cells. Such particles are not seen in the endothelium of the normal colon. There is an increase in the number of polymorphonuclear leucocytes in the colonic mucosa of patients suffering from pseudomembranous colitis, most marked at the sites of epithelial ulceration. Polymorphonuclear leucocytes migrate through the capillary endothelium (fig 11), traverse the surrounding basement membrane and enter the mucosal connective tissues. The polymorphonuclear leucocytes pass through the basement membrane of colonic epithelial cells (fig 12) so as to lie between adjacent epithelial cells. Ultimately, these polymorphonuclear leucocytes are shed into the colonic lumen. At the sites of epithelial ulceration, the polymorphonuclear leucocytes are shed directly into the colonic lumen.

The pseudomembrane of pseudomembranous colitis consists of a fibrin meshwork (fig 13) containing exuded polymorphonuclear leucocytes (fig 13), mucous and degenerating cells which represent the shed epithelial and connective tissue cells. In addition, the pseudomembrane contains numerous

particles, about 50 nm in diameter (figs 13 and 14), which have a limiting membrane, about 7 nm thick, consisting of two electron-dense layers separated by an electron-lucent layer. Occasional particles contain an electron-dense central core which represents the nucleocapsid of virus particles. Such particles have already been described in the colonic epithelium and certain capillary endothelial cells in patients with pseudomembranous colitis.

Discussion

Clindamycin is known to cause diarrhoea but the incidence varies between 2% and 30% (Geddes, Bridgwater, Williams, Oon, and Grimshaw, 1970; McGehee, Smith, Wilcox, and Finland, 1968), and during the past two years there have been numerous cases of pseudomembranous colitis occurring in patients who are simultaneously receiving clindamycin therapy. Pseudomembranous colitis is a well defined pathological entity but from an examination of the literature related to this condition it is apparent that pseudomembranous enterocolitis can be related to several different conditions. The association of a *Staphylococcus aureus* infection with pseudomem-

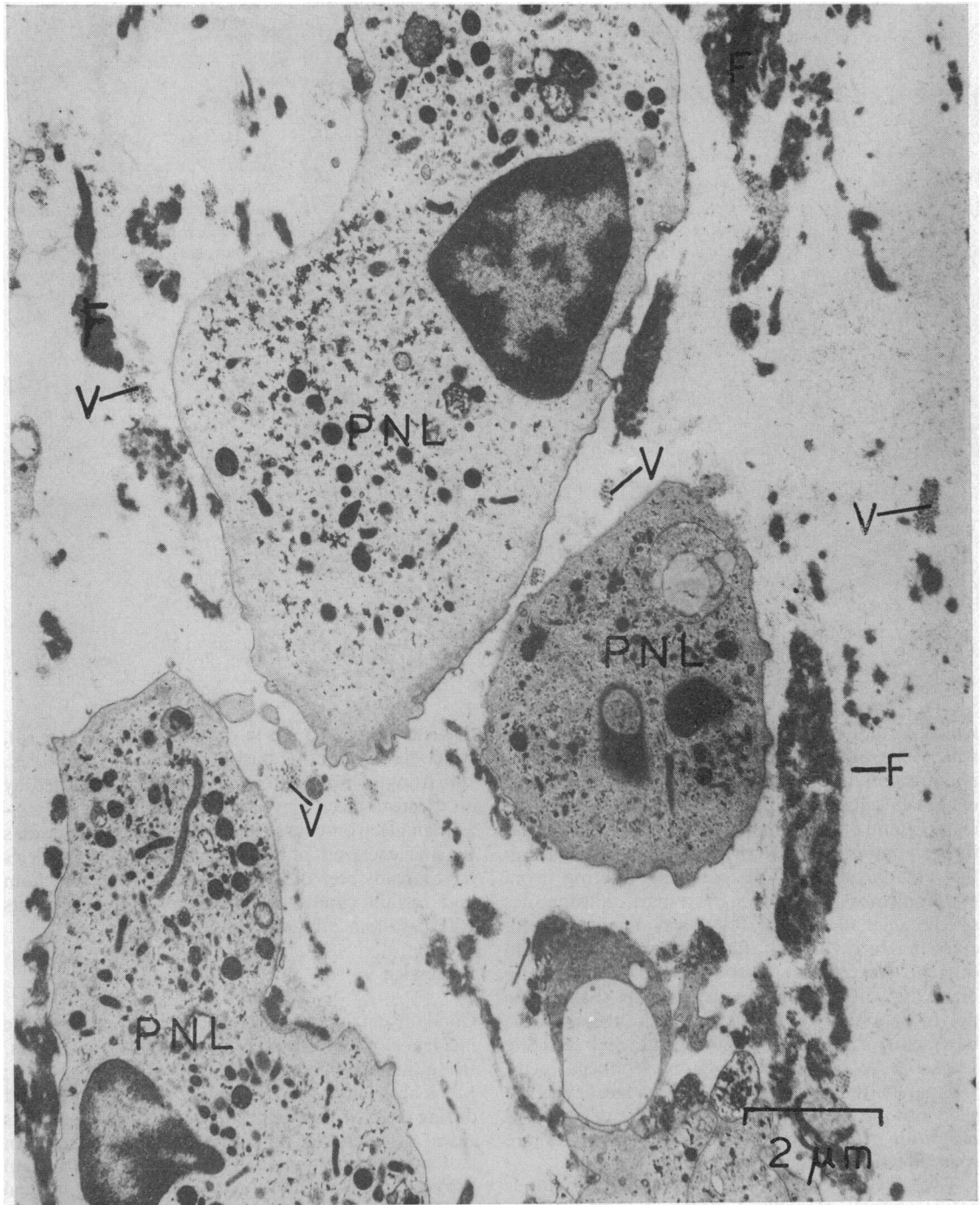

Fig 13 *Polymorphonuclear leucocytes (PNL) in the pseudomembrane of pseudomembranous colitis. The fibrin (F) meshwork between these cells can be seen and clusters of virus particles (V) are also apparent.*

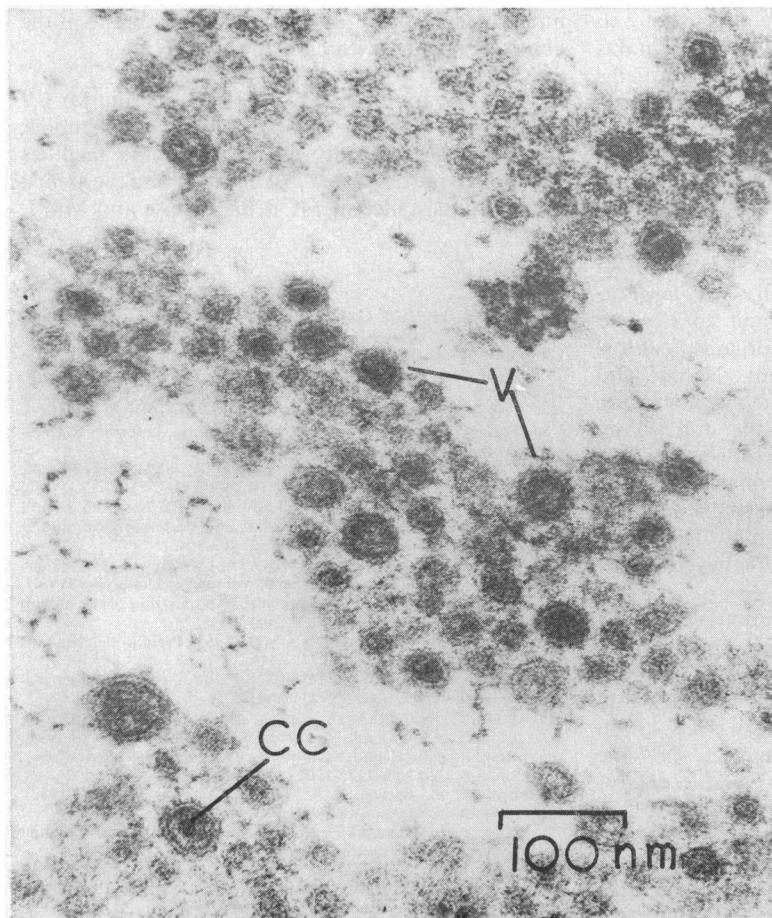


Fig 14 Intraluminal virus particles (V) which possess a limiting membrane consisting of two electron-dense layers separated by an electron-lucent layer. Occasional virus particles contain an electron-dense central core (CC) which is separated from the limiting membrane by a less densely staining region and represents the nucleocapsid of the virus particle.

branous enterocolitis has been frequently reported (Dearing, Baggenstoss, and Weed, 1960; Jackson, Haigh, Kass, Womack, Gocke, and Finland, 1951; Hale and Cosgriff, 1957; Speare, 1954) but is not absolute. There were many patients suffering from pseudomembranous enterocolitis who did not have an intestinal infection that could be attributed to any recognizable bacterial infection but may have been due to inadequate means of identifying certain pathogenic bacteria, and up to 1952 antemortem stool cultures were infrequently performed (Pettet, Baggenstoss, Dearing, and Judd, 1954).

Pseudomembranous enterocolitis can affect any part of the gastrointestinal tract (Pettet *et al*, 1954) but that associated with clindamycin or lincomycin therapy has been limited to the colon—pseudomembranous colitis (Cohen *et al*, 1973; Scott, Nicholson, and Kerr, 1973; present postmortem observations). Another feature of the pseudomembranous colitis associated with clindamycin therapy is the pathologist's inability to isolate any

pathogenic bacteria from the stools (Cohen *et al*, 1973; Tedesco *et al*, 1974; Dyck *et al*, 1974; Temperley, 1974). Histological examination has failed to reveal colonies of infecting bacteria but ultrastructural examination has given some insight into the aetiology of the pseudomembranous colitis associated with clindamycin. Particles have been found with the ultrastructural characteristics of viruses. They are about 50 nm in diameter and have a limiting membrane about 7 nm thick. They are first observed in the supranuclear region of the colonic epithelial cells but are not confined to these cells, and are shed into the colonic lumen so that they become related to the surface membrane of the colonic epithelial cells. They are found in large numbers in the pseudomembrane. The colonic epithelial cells are overwhelmed by the degree of viral infection and are shed into the lumen. The viral infection is not confined to the colonic epithelial cells and such particles are seen in the endothelial cells of capillaries near the sites of colonic epithelial

ulceration. The presence of a viral colitis leading to the histological appearance of pseudomembranous colitis associated with clindamycin therefore explains why pathogenic bacteria have not been isolated from the stools of such patients.

An alteration in the normal bowel flora has been postulated as a mechanism for the development of pseudomembranous enterocolitis (Pettet *et al*, 1954). Lincomycin, a compound chemically related to clindamycin, has been shown to suppress *Bacteroides* spp, anaerobic lactobacilli, *Streptococcus faecalis* and *Escherichia coli* of the gut flora but to cause an increase in certain other organisms (Gorbach, Spanknebel, Weinstein, Plaut, Nahas, and Levitan, 1969). These changes in the gut flora were present in the distal small intestine and colon. Clindamycin may therefore alter the normal colonic bacterial flora so that the colonic mucosa is more susceptible to viral infection. Viral particles have not been observed in the normal human colon. The source of the virus producing the viral colitis has yet to be elucidated.

The patient suffering from pseudomembranous colitis is frequently in a state of shock and attempts have been made to relate shock to the aetiology of pseudomembranous enterocolitis (Penner and Bernheim, 1939), and this theory has been incriminated with that of ischaemia as possible aetiological factors in pseudomembranous enterocolitis (McKay, Hardaway, Wahle, and Hall, 1955). However, the histological appearance of pseudomembranous colitis (Goulston and McGovern, 1965) differs from that of ischaemic enterocolitis (McGovern and Goulston, 1965). The findings of viral particles in the capillary endothelium of the colon as well as in the colonic epithelium supports the hypothesis that the viral infection is not confined to the colonic epithelium and may be part of a more generalized systemic illness. Such a situation would contribute to the shocked state, particularly when associated with fluid and electrolyte depletion from the watery diarrhoea.

The epithelial ulceration of the colonic mucosa in pseudomembranous colitis has been attributed to a process of fibrinoid necrosis of the surface of the mucosa (Goulston and McGovern, 1965). With deposition of fibrin in the mucosal connective tissue and its observation beneath the epithelial basement membrane, the nutrition of the overlying epithelium would be impaired but the present findings of a viral colitis introduces another aetiological factor in the development of mucosal ulceration. The viral infection gradually overwhelms the colonic epithelial cells which degenerate and are shed into the colonic lumen. Such a viral infection would appear to be primarily responsible for the epithelial ulceration

and the development of the pseudomembrane in the colitis associated with clindamycin therapy.

I should like to thank Mr J H H Webster and Mr B J Wilken for allowing me to study patients under their care. I gratefully acknowledge the facilities afforded to me by Professor D Bulmer and the skilled technical assistance of Mr B Backhouse and Mrs L Baker.

References

- Cohen, L. E., McNeill, C. J., and Wells, R. F. (1973). Clindamycin-associated colitis. *J. Amer. med. Ass.*, **223**, 1379-1380.
- Cummins, A. J. (1961). Pseudomembranous enterocolitis and the pathology of nosology. *Amer. J. dig. dis.*, **6**, 429-431.
- Dearing, W. H., Baggenstoss, A. H., and Weed, L. A. (1960). Studies on the relationship of *Staphylococcus aureus* to pseudomembranous enteritis and to postantibiotic enteritis. *Gastroenterology*, **38**, 441-451.
- Dyck, W. P., Viteri, A. L., and Howard, P. H. (1974). Lincomycin, clindamycin and colitis. *Lancet*, **1**, 272-273.
- Geddes, A. M., Bridgwater, F. A. J., Williams, D. N., Oon, J., and Grimshaw, G. J. (1970). Clinical and bacteriological studies with clindamycin. *Brit. med. J.*, **2**, 703-704.
- Gorbach, S. L., Spanknebel, G., Weinstein, L., Plaut, A. G., Nahas, L., and Levitan, R. (1969). Studies of intestinal microflora. VIII. Effect of lincomycin on the microbial population of the human intestine. *J. infect. Dis.*, **120**, 298-304.
- Goulston, S. J. M., and McGovern, V. J. (1965). Pseudo-membranous colitis. *Gut*, **6**, 207-212.
- Hale, H. W., and Cosgriff, J. H. (1957). Pseudomembranous enterocolitis. *Amer. J. Surg.*, **94**, 710-717.
- Jackson, G. G., Haight, T. H., Kass, E. H., Womack, C. R., Gocke, T. M., and Finland, M. (1951). Terramycin therapy of pneumonia; clinical and bacteriological studies in 91 cases. *Ann. intern. Med.*, **35**, 1175-1202.
- Kleckner, M. S., Bargaen, J. A., and Baggenstoss, A. H. (1952). Pseudomembranous enterocolitis: clinicopathologic study of fourteen cases in which the disease was not preceded by an operation. *Gastroenterology*, **21**, 212-222.
- McGehee, R. F., Smith, C. B., Wilcox, C., and Finland, M. (1968). Comparative studies of antibacterial activity in vitro and absorption and excretion of lincomycin and clindamycin. *Amer. J. med. Sci.*, **256**, 279-292.
- McGovern, V. J., and Goulston, S. J. M. (1965). Ischaemic enterocolitis. *Gut*, **6**, 213-220.
- McKay, D. G., Hardaway, R. M., Wahle, G. H., and Hall, R. M., (1955). Experimental pseudomembranous enterocolitis; production by means of thrombosis of intestinal mucosal capillaries. *Arch. intern. Med.*, **95**, 779-787.
- McManus, J. F. A. (1948). Histological and histochemical uses of periodic acid. *Stain Technol.*, **23**, 99-108.
- Pearce, C., and Dineen, P. (1960). A study of pseudomembranous enterocolitis. *Amer. J. Surg.*, **99**, 292-300.
- Pearse, A. G. O. (1960). *Histochemistry: Theoretical and Applied*, 2nd ed. Churchill, London.
- Penner, A., and Bernheim, A. I. (1939). Acute postoperative enterocolitis: a study on the pathologic nature of shock. *Arch. Path.*, **27**, 966-983.
- Pettet, J. D., Baggenstoss, A. H., Dearing, W. H., and Judd, E. S. (1954). Postoperative pseudomembranous enterocolitis. *Surg. Gynec. Obstet.*, **98**, 546-552.
- Richardson, K. C., Jarret, L., and Fincke, E. H. (1960). Embedding in epoxy resins for ultrathin sectioning in electron microscopy. *Stain Technol.*, **35**, 313-323.
- Scott, A. J., Nicolson, G. I., and Kerr, A. R. (1973). Lincomycin as a cause of pseudomembranous colitis. *Lancet*, **2**, 1232-1234.
- Speare, G. S. (1954). *Staphylococcus pseudomembranous enterocolitis* a complication of antibiotic therapy. *Amer. J. Surg.*, **88**, 523-534.
- Tedesco, F. J., Stanley, R. J., and Alpers, D. H. (1974). Diagnostic features of clindamycin-associated pseudomembranous colitis. *New Engl. J. Med.*, **290**, 841-843.
- Temperley, J. M. (1974). Lincomycin, clindamycin and colitis. *Lancet*, **1**, 221.