

CYSTS OF THE URACHUS.

BY WALTER RUPERT WEISER, M.D.

OF SPRINGFIELD, MASS.,

Surgeon to Mercy Hospital.

THE literature on the subject of cysts of the urachus is not voluminous and is much scattered. Statistical papers are very rare. Wutz,¹ writing in 1883, denies that any large, clinically-important cyst of the urachus had been reported up to that time. He analyzes all the alleged cases, whether found at autopsy or seen clinically, and rejects them all; because they represent either notable diagnostic errors or data too scanty to justify a diagnosis. He gives no formal conclusions, but simply analyzes each reported case. He evidently expects that a typical case should show in its cyst-wall the presence of each anatomical layer of the urachus from which the cyst is believed to form by partial dilatation. Thus, in an ideal case we should find, first, stratified epithelium, and second, smooth muscle fibres, as well as the non-dilated portion of the urachus. The cyst should also lie outside and in front of the peritoneal cavity.

The minute cysts claimed in his day as urachal are summed up as follows:

1. All have their seat in the lower fourth or third of the distance or space between the navel and vertex of the bladder, and proceed from the normal, persistent portion of the urachal canal.

2. The majority have stratified pavement epithelium; a few, only a single layer.

3. All cases have a more or less pronounced envelope of smooth muscle fibres.

4. Size from microscopic to bean.

The essentials are not demonstrable in the alleged large cysts of the urachus reported at autopsy or clinically.

Small cysts, microscopic to bean size, he claimed were relatively frequent, as he had seen seventy-four cases; but as these are of no clinical importance I shall not consider them in my statistics.

Doran,² like Wutz, whose critical acumen he praises, does not indulge in any concluding generalizations, but, using Wutz as a guide, is content to show that all reported cases of urachal cysts of large size are more or less defective.

His own case is apparently well documented, and he seeks to show that it could not have been any other pathological condition, such as might form in that locality (organized peritoneal effusion, encysted dropsy, abscess cavity, etc.). Yet despite positive evidence and results of exclusion, he does not seem to commit himself to an absolute diagnosis. He is evidently deterred by the fact that Wutz, with much better opportunities for exact work, was led to a non-committal point of view.

Cases other than his own are discussed pro and con with the outcome that they are not beyond criticism, although in many cases satisfactory for ordinary requirements.

Thus, the conclusions reached by both Wutz and Doran are seen to be destructive rather than constructive to the statistical side of my subject.

The reports by Hoffman³ in 1870, Wolff⁴ in 1873, and Atlee,⁵ 1873, furnished about the only information upon the subject until Tait's⁶ article appeared in 1883, followed in 1886 by his report of twelve cases as reported to the British Gynæcological Association.⁷

To Mr. Tait belongs the credit of being the first to make a diagnosis in these cases prior to operation. His teachings were of great value in explaining this bewildering pathological condition to the abdominal surgeon of twenty years ago.

Since that period a few writers have studied and reported upon the subject.

Dr. F. Byron Robinson⁸ has reported four additional cases operated upon by Tait and two personal cases seen elsewhere. He reports his observations in studying the urachus of the foetal calf, foetal pig, cow, dog, sow and sheep. The bulk of the paper is made up of his observations while with Mr. Tait, followed by his conclusions. The paper is of much value to the student of this pathological phenomenon.

Freer⁹ and Douglas¹⁰ also furnish comprehensive articles upon the subject, with report of cases.

My own cases, three in number, are rather typical of the more serious type of these cases by reason of their considerable size and their dipping down into, and being adherent to, the pelvic viscera; and their being in each case extra-peritoneal, with bladder attachment, makes the diagnosis conclusive.

CASE I.—Female, age 75. Family history negative. Patient had, aside from diseases of childhood, always enjoyed perfect health. Had three children, with normal pregnancies and labors. For fifteen years had suffered the inconvenience of a discharge of pus from the umbilicus. The discharge was constant, and at times, following an enlargement of the abdomen and pain, it became profuse, relieving the pain and causing the swelling to diminish to such an extent that care was required in its detection.

At various times she had consulted physicians in reference to the condition, but aside from prescribing various washes and ointments, no treatment or diagnosis was offered.

She was finally referred to me, and an examination revealed the following conditions: Patient well preserved and active for her age. The abdomen was very fat, and a tumor, cocoanut size, presented in the median line between the umbilicus and symphysis pubis. The mass could be raised with the abdominal wall, and was apparently attached thereto.

There was a copious discharge of foul-smelling pus from the umbilicus, and an eight-inch probe passed into the sinus failed to reach the lower wall of the sack. The temperature

was 101°; pulse 100. She volunteered the information that it was no worse than usual, but she was not feeling so well generally, and there had been, during the past month, very frequent micturition.

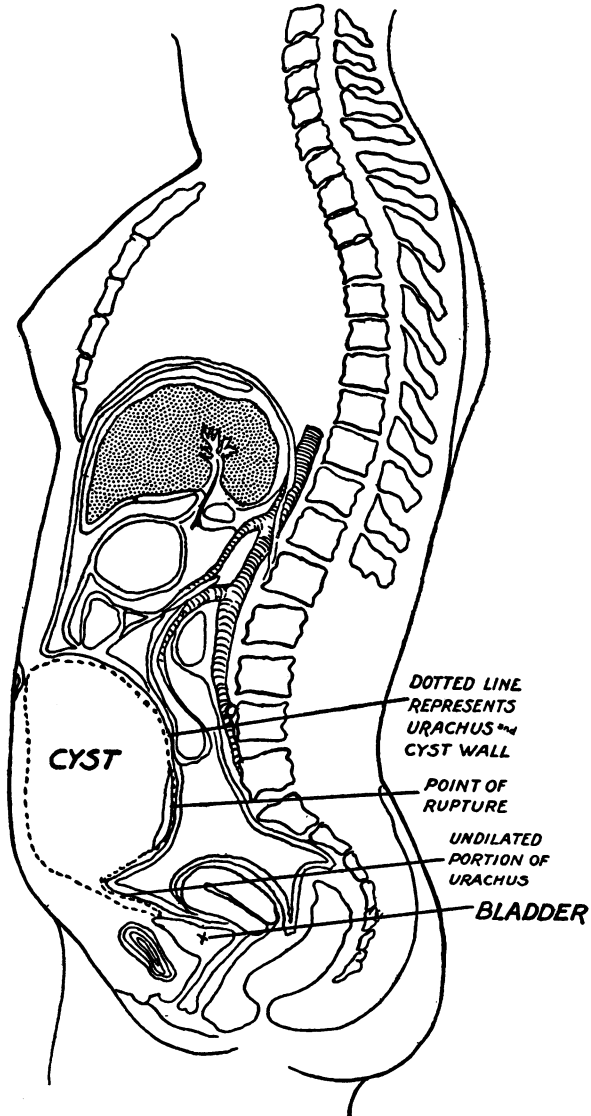


FIG. 1.—Cyst of Urachus.

Under ether anæsthesia I excised the umbilicus and unhealthy skin surrounding it, and, incising down through two inches of fat, came upon a bulging mass extending from the umbilicus as far down as I could feel toward the symphysis pubis. (Fig. I.) This I tapped, and evacuated about five ounces of horribly fetid pus, followed by a calculus weighing 70 grains. Exploration with the finger demonstrated the fact that the cyst had a thick and indurated wall and dipped well down to the pelvis.

Up to this point in the operation I had not opened the peritoneal cavity. I now washed out the sac and packed it with gauze and entered the peritoneal cavity above the location of the tumor. To my surprise I found the mass densely adherent to the intestines posteriorly, and, passing my hand down into the pelvis on the outside of the cyst, discovered it to be closely associated with the bladder. I now concluded that I was dealing with a urachal cyst, and as the posterior wall was almost entirely made up of intestines, I concluded to cut away such portion of the sac as seemed safe. I left the posterior wall intact, as well as that portion which dipped down into the pelvis. The wound was closed so far as I had peritoneum and the balance walled off with a coffer-dam drain of iodoform gauze. Her recovery was uneventful, but required three months to close the sinus.

CASE II.—Female, aged 11. Was admitted to the Mercy Hospital April 11, 1905, with the following history furnished by Dr. M. W. Pearson, who referred the case.

The child had complained for some days of headache and vomiting, gradually developing slight tenderness and some pain in the abdomen, but not severe at any time. There was at first no localized tenderness and very little distention. One week prior to admission a general flatness was noted, with fluctuation. The abdomen became more and more distended.

On admission her temperature was 101.2°, pulse 172, respiration 30. The child was pale and emaciated, with a dry tongue and anxious expression. She complained bitterly of abdominal pain, and the entire abdomen was tender, but especially so about the umbilicus. The abdomen was greatly distended and board-like. Flatness extended from the umbilicus to symphysis pubis and from a point two inches to the right of the median line, almost completely into the loin on the left side. Entirely

surrounding but especially above the umbilicus was a zone of redness one and three-eighths inches in diameter, which represented an area through which the abscess was ulcerating toward the surface. A positive diagnosis was not made prior to operation, but tubercular peritonitis and suppurative urachal cyst were both considered.

Under ether anæsthesia the abdomen was opened in the median line between the umbilicus and symphysis. Absence of the peritoneum made a diagnosis quickly possible and a peculiar state of affairs presented. The abdominal cavity was divided into two compartments by the sac wall, which displaced the intestines almost entirely to the right side of the cavity and walled them off. Almost the entire left side below the umbilicus was filled with the cyst, which had ruptured, as shown by Diagram No. 2. Except at the point of rupture the cyst contents were entirely extra-peritoneal, although occupying so large a part of the abdominal cavity. Several pints of free pus was confined to the left side and was not in contact with the intestines.

The position occupied by the mass is fairly well shown in diagram, Fig. II. The urachus was patulous down to within three-eighths of an inch of the bladder and was ligated at that point; so much of the sac as could be dissected out without tearing up the limiting wall was taken away, and the abscess cavity washed out and drained with a coffer-dam drain of iodoform gauze.

An area two by four and one-half inches was bare of peritoneum at the site of wound, but there has been no trouble from this source.

CASE III.—Male, aged 73. Referred by Dr. Stowell. Family history negative. Had always been well, except an attack of orchitis four months previous. For six months he suffered with pain and soreness in the abdomen, but noticed no tumor. Two weeks before my visit the abdominal wall opened spontaneously two inches below the umbilicus and discharged urine. There had never been any pus. If lying down quietly the urine did not escape, but so soon as he assumed an upright position there was a constant discharge.

The old gentleman appeared perfectly well aside from this urinary sinus, which was about the circumference of a pencil

and entered immediately into a large sac, the lower limit of which I could not reach with an eight-inch probe.

Under ether anæsthesia I entered the peritoneal cavity

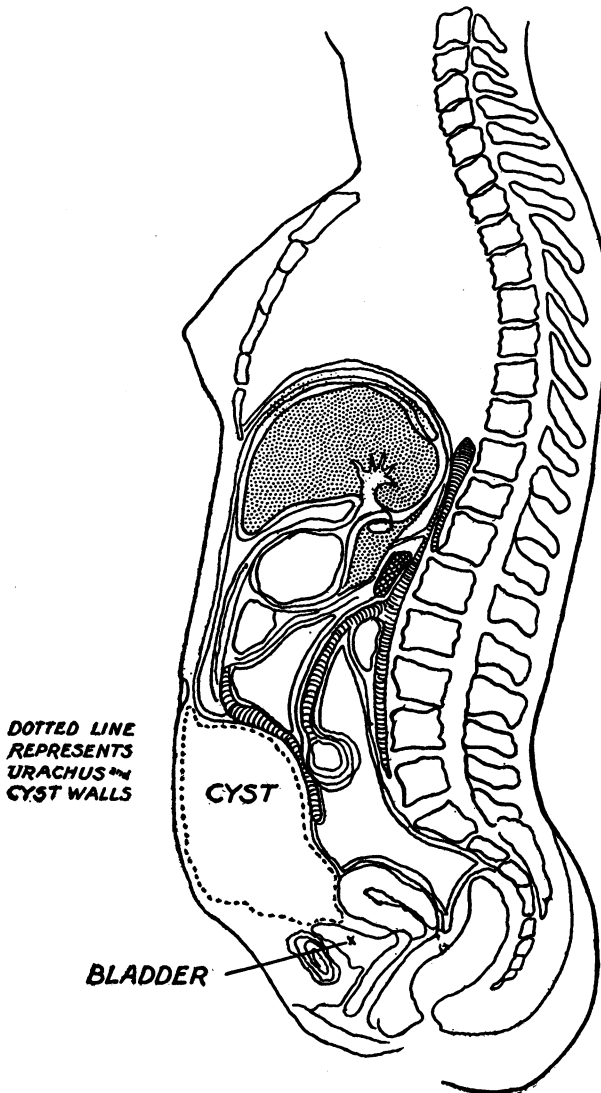


FIG. 2.—Cyst of Urachus.

above the sinus and found the sac anterior to the parietal peritoneum. The sac extended to within one inch of the umbilicus, above which the urachus was not patulous (Fig. III.), and down-

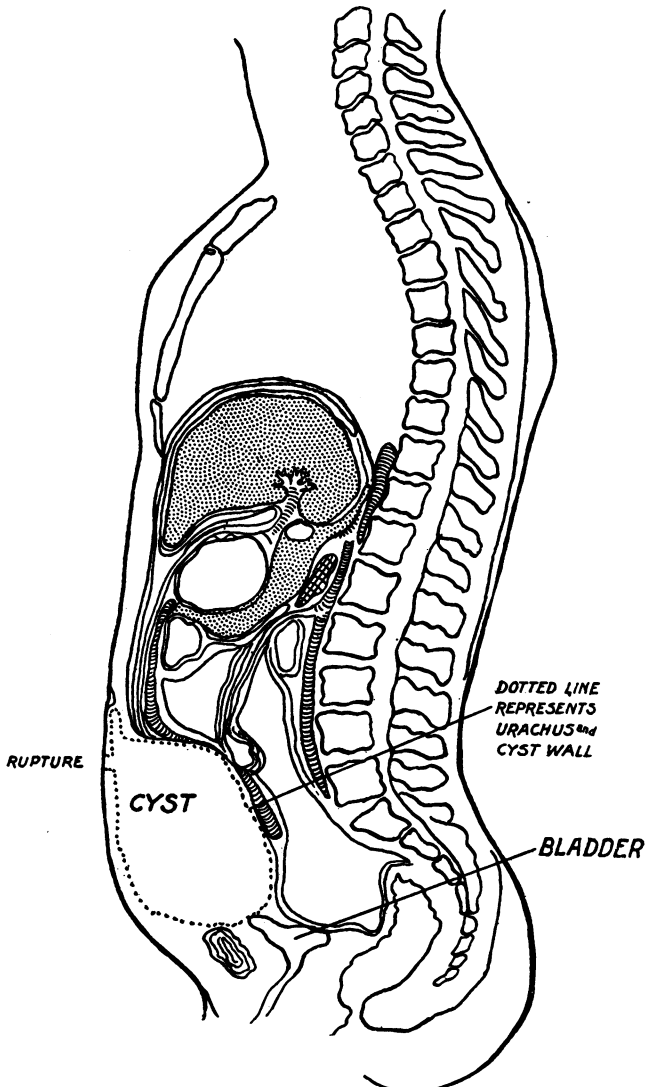


FIG. 3.—Cyst of Urachus.

ward into the pelvis. It was intimately connected with the bladder at the point of urachal contact and was densely adherent to the posterior bladder-wall, as well as to the intestines, the greater part of the posterior sac-wall being made up of abdominal viscera. After freeing the anterior wall of the cyst sufficiently, I made a plastic closure of the original point of rupture through the abdominal wall. A catheter was passed into the bladder through the urethra and allowed to remain for several days. The abdominal wound was closed without drainage. Patient made an uninterrupted recovery and was about the house on the fourteenth day.

Two months later I was told by Dr. Stowell that the abdominal wall had given way again a trifle lower down toward the symphysis, and urine is again discharging through a small sinus. I have advised its closure, but shall not attempt anything more radical than plastic closure, not entering the peritoneal cavity, since I think total extirpation impossible.

Since writing the above, I am informed by Dr. Stowell that the opening has closed spontaneously, and urine is voided entirely through the urethra.

TABLE OF CASES OF CYST OF THE URACHUS REPORTED IN MEDICAL LITERATURE.

Operator and Reference.	Age	Sex	History and Symptoms.	Treatment.	Character of Cyst Contents.	Result.	Remarks.
1 Wolf Inaug. Dissertation Marburg, 1873.	31	F.	Two years before had noted small tumor in left lower abdominal region. Fever present. Was in fourth month of pregnancy. Next few days rapid increase in size. Moisture about navel from time of birth. Blood and pus discharged from time to time but never urine. Small aperture in lower part of ring. Upon pressure serum escapes. A sound introduced reveals a canal running in a downward direction along linea alba.	Incision and evacuation of fluid. Mass extirpated.	Five litres yellowish serous fluid.	Not stated.	
2 "	2½	M.	When about to remove an ovarian tumor, the incision in linea alba, between umbilicus and pubis, opened a small cyst from which an ounce of yellowish fluid escaped. He finished the ovarian operation and closed the wound. Six days later dressings began to be saturated with a thin fluid which was devoid of smell. Urine passed normally. Nevertheless the oozing fluid was later found to be the same as that escaping by the urethra.	Opening dilated by a laminaria tent whereupon a teaspoonful of yellowish-green pus escaped.	Teaspoonful of yellowish-green pus.	Discharged without cure.	
3 Ailee, Ovarian tumors, 1873, p. 50.	18	F.	Vesical tenesmus, tumor and tenderness in abdominal region. Belly prominent, ovoid, largest just below navel, where a hard fluctuating mass was present. Navel gradually became thin and opened, an albuminous-like fluid oozing forth.	Patient ordered to void urine frequently whereupon the escape of fluid from the wound ceased and the wound closed completely.	Yellowish thin fluid devoid of smell.	Cured.	
4 Scholz, Bericht i. K. K. Allgemeln. Krankenhäuser, Wien, 1871.	16	F.	Three months pregnant when acute abdominal swelling appeared. Tapped and pregnancy went to term with normal delivery. Four years later, pregnant again. Fluid reappeared, patient aborted. Temporary communication between cystic mass and bladder.	Opening dilated and fluid evacuated. No further operation.	300 C. C. colorless transparent fluid. Tenacious. Eventually much thick yellow pus.	Healed in two months.	No diagnosis.
5 Rosert, Arch. f. klin. Chirurgie, 1876, XX, p. 472.		F.		First tapped and wash-basin full of fluid removed. Second operation, laparotomy, incision of cyst and evacuation of three litres of foul ammoniacal purulent fluid. After a long period during which catheter was passed every two hours, it healed.	Foul purulent ammoniacal fluid.	Cured.	

9	Hoffmann, Arch. f. Heilkunde XI, p. 373.	28	M.	Thick abdomen even in youth. Increased in size at 24, with dyspnoea, fluctuation to right side, for which he was tapped. Patient well for two years when he again became worse.	Tapped and two years later a second tapping.	Reddish-yellow thin fluid. Seventy-five litres at second tapping.	Death.	After death fifty litres residual fluid in sac. Diagnosis at autopsy.
7	"	28	M.	One year before had fluctuation beneath costal arch to left. Pains in right lower abdominal cavity for ten years.	Tapped twice.	Six litres greenish-yellow clear and albuminous fluid. Second tapping 103 litres bloody fluid becoming purulent and urinous.	Death.	Diagnosis at autopsy.
8	McLean, Md. Record, Feb. 8th, 1879.	24	F.	In 1867 pains and bloating in abdomen with indications of growth in left iliac fossa. In 1876 the mass attained large dimensions. Abdomen uniformly enlarged.	Laparotomy after tapping abdomen. At lower angle of incision a cyst of the abdominal wall was wounded, two drachms of pale fluid escaping. Large mass was ovarian tumor, multilocular. This was removed and pedicle ligated. Bladder had been wounded and was repaired.	Pale fluid.	Death, 30 hrs. after operation.	Autopsy showed bladder to be intact and densely adherent to abdominal wall.
9	Heinecke, Billroth, Allg. Pithas, Allg. gem. und Speciale Chirurgie, 1879, III, 2, p. 64.	33	F.	Primipara. Two years before, abdominal distention noted. Most marked below navel. Dull to percussion on left side, as far back as lumbar region. Puncture with evacuation of albuminous fluid and numerous squamous epithelial cells in fatty degeneration.	Laparotomy cyst exposed by the incision. This was incised and emptied and an attempt made to dissect it out. After much trouble the anterior wall was detached from the abdominal wall and an attempt made to roll the mass out but this was impossible as intestines seemed to be part of the posterior wall.	Albuminous fluid and squamous epithelia in fatty degeneration.	Death "soon after."	At autopsy the author seemed to think this diagnosis wrong and that the real condition was encapsulated peritoneal exudate.
10	Helmut, Contributions to Gynecological Surgery, p. 16.	54	F.	Multipara. When 14 years old a mass the size of an apple formed at the navel and burst with projectile escape of water. After menopause at 44, the abdomen became enlarged and tender.	Tapping and then laparotomy. A peculiar mass exposed which was adherent to abdominal wall. Incised with escape of fluid. This cyst was pushed aside and a large ovarian cyst extirpated. The smaller cyst communicated with the bladder. Its walls were repaired in a suprapubic lithotomy.	Quart of dark viscid fluid.	Death from peritonitis on fifth day.	No autopsy.
11	Helmut Case reported by Freer, Annals of Surgery, 1886, V, p. 110.	2 or 3 mos.	M.	Said to pass urine through the navel. A hollow growth one and one-half inches long at navel communicating with a pervious urachus. Discharge continuous.	Operation of ligation proposed but refused.	Urine.		

TABLE OF CASES OF CYST OF THE URACHUS—Continued.

Case	Operator and Reference.	Age	Sex	History and Symptoms.	Treatment.	Character of Cyst Contents.	Result.	Remarks.
12	Freef, ANALS OF SURGERY, V, 1887, p. 107.	Middle aged	F.	Inability to urinate at will, by reason of cyst of urachus which filled up to extent of several litres. By compressing the cyst, she could empty the bladder in part only. She became pregnant and it was necessary to tap her. After gestation, she did well for four years, when she again became pregnant. She was tapped again and aborted. The communication between cyst and bladder closed spontaneously and patient had no further annoyance.	Tapped twice.		Recovery.	
13	Freef, ANALS OF SURGERY, V, p. 112.	10	M.	Urine contained blood and pus and treated successfully, but shortly afterward urine began to escape from navel. Just before this happened a growth which had appeared at the navel ruptured.	Fistula dilated with a laminaria tent and fistula closed by cauterization and use of subcutaneous ligatures. Ten days later re-opened, suppurated and was again closed. Plastic operation for umbilicus followed by peritonitis.		Death.	Autopsy old peritonitis. Trabecular bladder which also contained a setum between several openings. Cystic cavity communicated with bladder and contained two openings, marking site of ruptures which had caused peritonitis.
14	Freef, ANALS OF SURGERY, V, p. 110.	40	F.	Purulent discharge. Sound introduced at navel, located a cavity three inches broad at widest diameter. Several ounces of pus could be squeezed out. Communication between cyst and bladder.	Cyst treated antiseptically and healed without operation. Patient stated that this had been done several times before.	Pus.	Cured.	
15	Freef, ANALS OF SURGERY, V, p. 111.	26	M.	Had a large abdomen since infancy. Marked increase in size recently. Fluctuation, in and around umbilicus. Dyspnoea increased necessitating tapping. Remained in good health for two years when abdomen re-filled and patient became cachectic. Second tapping brought away six litres bloody fluid. In next nine months three more tapplings, 18%, 17 and 6 litres respectively.	Repeated tapplings.	Considerable reddish-yellow fluid at first tapping.	Death.	Autopsy. Patient weighed 192 lbs. but cyst contained 50 litres of fluid equal to 100 lbs. weight. Cyst did not communicate with bladder. A smaller cyst lay between it and the bladder

91	B r a m a n n, Arch. f. klin. Chirurgie, 1887, XX XVI, p. 1004.	36	F.	Eighteen years before, an abdominal tumor had appeared, with high fever, pain, vomiting, etc. Attending physician found tumor size of fist in umbilical region, a little to the right of and above the navel. This persisted with fluctuation in size, and a tendency to approach the symphysis. Two years later rupture at navel and escape of foul pus. Fistula persisted until present consultation. Oval tumor exactly in median line reaching from navel to symphysis and five c.m. wide. Urine had always been voided normally.	Laparotomy. Incision to fistula with escape of pus. Extraction of four concretions size of pigeon's egg. Fistulous tract curetted and cavity of cyst tamponed and afterward drained with tube.	Foul pus.	Recovery after three months.	Concretions appeared to be gall stones. Author unable to account for their presence.
17	Flemming, Trans. Glasgow Pathol. and Clinical Society, 1888, III, p. 99.		M.	Admitted to hospital for swelling inguinal region, which appeared after he had jumped from a cart. Thought he had sustained a rupture and put on a truss. No improvement. Swelling persisted and grew larger. Large fluctuating mass above Poupart's ligament on right side. Crural ring intact. Yellow fluid aspirated by needle. Later nine ounces dull yellow fluid removed by trocar and iodine injected. Fluid behaved like hydrocele fluid. Said to contain spermatozoa, also cholesterin.	Laparotomy. Cyst incised, scraped and drained.	Yellow fluid.	Recovery.	
18	Teichelmann and Tait, Lancet, 1888, II, p. 675.	28	F.	Fever and vomiting were followed by appearance of hard painful tumor between umbilicus and pubes somewhat to the left side. No mention of suppuration at any time or of a diagnosis before operation. Cyst a large one dipping into pelvic cavity attached by short pedicle to abdominal wall.	Laparotomy. Enucleation. Cavity drained and margins stitched to abdominal wall. Peritoneal cavity was separately drained.		Recovery in three weeks complete.	
19	Schulkenbach, Inaug. Dissertation, 1888.	66	M.	Fistula at umbilicus which discharged a turbid fluid constantly. Urine could be withdrawn through fistula by catheter.	Laparotomy. Incision of cysts with escape of a litre of pus and urine. Cyst extirpated.	Pus and urine.	Recovery.	

TABLE OF CASES OF CYST OF THE URACHUS—Continued.

Case No.	Operator and Reference.	Age	Sex	History and Symptoms.	Treatment.	Character of Cyst Contents.	Result.	Remarks.
20	Lawson Tait, British Gynecological Journal, 1886-7, II, p. 328.	56	F.	Abdominal pain and tenderness, vomiting, swelling of abdomen. These increased for four months when tapped for a supposed ascites. Ten pints of fluid drawn off. Not ascites but cystic. Diagnosis of parovarian cyst. Fluid re-collected at once.	Laparotomy. Cyst incised. Thirty pints evacuated. Much fibrin present. Cyst now extirpated. Union of front and peritoneum behind. Cyst removed bodily. Inner aspect of broken-down epithelium infiltrated with pus. Muscular coat beneath epithelium.		Death in three days.	
21	"	39	F.	Great pelvic pain and abdominal swelling. Hard mass to be felt on left side, which in two months had become central. Amenorrhœa purulent urine. Supposition of ovarian cyst.	Laparotomy. Cyst tapped and seven pints putrid urine drawn off. Cyst everywhere adherent. Separated as far as possible behind. Wound closed and drained with tube. Urinary fistula remained about a month after operation. Patient aborted, dying suddenly.	Putrid urine.	Death in one month.	No autopsy.
22	"	39	F.	Condition dated back three years and when seen by Tait appeared too far gone for intervention.	Laparotomy. Cyst gangrenous and full of pus. Peritoneal cavity not opened. When stitches were removed the wound re-opened and discharged dark unhealthy pus.	Pus.	Death in seven-teen days.	No autopsy.
23	"	21	F.	Symptoms of parovarian cyst.	Laparotomy. Cyst found to be extra peritoneal. Contents clear. Cyst emptied, sponged out, and drainage tube inserted. Suppuration began immediately and continued profusely until patient died of exhaustion.	Clear fluid.	Death in six weeks.	No autopsy.
24	"	33	F.	Profuse menstruation for which she was cured with benefit. Shortly afterward had chills followed by evidence of peritoneal effusion. Physical signs of encysted fluid, evidently purulent.	Laparotomy. Condition found exactly like that in last case save that contents of cyst were purulent. Drainage as above.	Pus.	Death.	No autopsy.
25	"	37	F.	Symptoms of pelvic tumor. From its relations expected a condition like all the preceding, <i>i.e.</i> , an extraperitoneal cyst.	Laparotomy. Cyst emptied and drained. Case did well for twelve days when all the urine began to appear through the tube. Sinus finally closed without operation.		Cured.	

26	Lawson Tait, British Gynecological Journal, 1886, 7, II, p. 328.	17	F.	Large tumor of abdomen and pelvis.	Laparotomy. Cyst evacuated by incision, six quarts clear fluid coming away. Drainage tube inserted.	Clear fluid.	Cured.
27		17	F.	Two months before consultation abdomen began to enlarge. Hectic appearance indicated suppuration. Diagnosis of purulent peritonitis.	Laparotomy. Condition found exactly like the preceding case. Circular drainage.	Clear fluid.	Cured.
28	"	29	F.	Confined three weeks before. Began to increase in size enormously, immediately after.	Laparotomy. An intraperitoneal cyst found containing nine pints of fluid. Peritoneum not opened. Circular drainage, a tube being passed through the retrouterine cul-de-sac into the vagina.		Cured.
29	"	41	F.	History of ovarian tumor which had been tapped and operated. Thought to have been a sarcoma with subsequent infection of peritoneum (Thornton).	Laparotomy by Tait. Old scar found in cyst wall. Case inoperable but not sarcomatous. No solid portion found. Drained.		Cured.
30	"	17	F.	Referred to Tait as acute inflammatory disease of abdomen. Exact diagnosis impossible. Pulse and temperature high and much free fluid in abdomen.	Laparotomy. Piece of cyst excised for diagnosis. Circular drainage.		Cured.
31	"	23	F.	Ailing for nine months and in bed two weeks. Hectic and emaciated.	Cyst tapped and six pints of purulent serum evacuated. Incision extended and diagnosis then made of allantoic cyst.	Purulent serum.	Cured.
32	Bantock.	30	F.	Abdominal tumor. No history.	Laparotomy. Incision of cyst and evacuation of twenty-five pints of thick grumous fluid. Attempted extirpation but had to be abandoned. Cyst washed out with iodine and wound closed with drainage tube. Peritoneal cavity not opened. For many weeks a thick mustard-colored discharge.	Thick grumous fluid.	Recovery.
33	Bantock.	37	F.	Taken violently ill with pain in stomach, fever, swelling of abdomen. Seven weeks later tapping necessitated. Over a gallon thick yellow fluid evacuated. Second tapping necessary.	After two tapings a laparotomy was done. Attempt to cut out a fistulous tract in site of trocar opening led to accidental opening of cyst containing several pints of purulent fluid. Cyst washed out and treated exactly as in previous case.	Thick yellow fluid.	Recovery.

Microscopical diagnosis Allantoic cyst.

TABLE OF CASES OF CYST OF THE URACHUS—Continued.

Case No.	Operator and Reference.	Age	Sex	History and Symptoms.	Treatment.	Character of Cyst Contents.	Result.	Remarks.
34	Tait, Reported by Byron Robinson. ANNALS OF SURGERY, 1891, XIV, P. 356.	17	F.	Fluctuating mass in lower abdomen and pelvis. Showed peculiar difference from ovarian and parovarian cyst. Only history given was that of irregular menstruation for eighteen months with poor health.	Laparotomy. Cyst wall which was very thick and brittle, incised. Could not be separated from its bed. Contents thick and pulsatious. Walls could not be collapsed. Cavity irrigated with iodine water. Wound closed at first without drainage, but five days later suppurating began and circular drainage was then instituted.	Thick and pulsatious.	Recovery in six weeks.	
35	"	9	F.	History so much like preceding that description is omitted by author. History of supposed gastritis four weeks before, when swelling was first noticed. Then became very anæmic.	Laparotomy as last resort. (No mention of diagnosis at time.) Condition recognized during operation as cyst of urachus. Incision and evacuation of thick pus, irrigation, abdomen closed with drainage.	Pus.	Recovery.	
36	"	40	F.	Had been ill some time. Hard mass in abdomen.	Laparotomy. As usual no peritoneum found. Diagnosis of cyst of urachus. Wall cheesy and friable as were also contents. To the naked eye, condition was tuberculous. Cavity irrigated with iodine, wound closed with a single glass drainage tube. First post-operative week was febrile.	Semi-solid and cheesy.	Recovery to surprise of Tait.	
37	"	17	F.	Never menstruated. Was thin and anæmic. For past six months ill and for most part of that period in bed. As is so often the case her general condition suggested tuberculosis. Diagnosis of urachal cyst made before operation and confirmed.	Laparotomy. Cyst filled with cheesy matter. Tait pronounced this case hopeless as he did the preceding one. As before he closed the wound, after irrigation, with a single drainage tube.	Cheesy.	Recovery from operation but when seen afterward was evidently succumbing to tuberculosis.	
38	Not one of Tait's but occurred in practice of a colleague of Dr. Robinson.	12	M.	Abdomen enlarged for months with diagnosis of peritonitis. Later evidences of a pelvic cyst, but no further diagnosis.	Laparotomy. Surgeon puzzled to find no peritoneum. Cyst incised with escape of pus and cheesy matter. Abdomen closed with silk and a glass drain left in.	Pus and cheesy matter.	Recovery.	

39	Robinson, as above.	10	M.	It is only stated that this case was a post-mortem specimen. No clinical particulars, nor is it stated whether the cyst or an operation for it had anything to do with the patient's death.		Death.
40	Dosseker Baino Rel- fråg, 1889, Klini, Chir- urgie, 1893, X, p. 102.	43	F.	Four years before, after severe pu- erperium became run down, with lancinating pains in right lower ab- domen. Some months afterward, tumor palpable through vagina, to right of uterus regarded as ovarian cyst, improved under vaginal douches, mud baths, etc., but in course of a year became worse. Tumor grew larger, and attacks of pain occurred. Afterward, fever, vomiting, etc.	Bloody fluid.	Recovery.
41	Vanderveer, Medical and Surgical Re- porter, 1889, XXI, p. 661.	20	F.	Umbilical fistula from birth. Irregu- lar discharge, profuse at times. Get- ting worse for past two years. Dis- charge very offensive.	Pus.	Recovery in two or three months.
42	Vanderveer, Journal of Obstetrics, 1897, XXXVI, p. 367.	Young	F.	Cyst not large, evidently fistulous.	Offensive dis- charge.	Cured.
43	"	Young	F.	Cyst not large, evidently fistulous.	Offensive dis- charge.	Recovery. Cured.
44	"	"	"	"	"	Recovery.
45	Ill. Transac- tions Am. Association Obstet and Gynec., 1892, p. 298.		F.	Had noticed swelling of small size for about ten years. During preg- nancy it enlarged rapidly and at end of third month contained five litres of fluid.		Recovery. Cured.
46	Ill. American Journal of Obstet, 1897, XXXVI, p. 568.		F.	Urine entered cyst but no inflamma- tion ensued.	Urine.	Recovery.
47	C. A. L. Reed Am. Journal of Obstet, 1897, XXXVI, p. 368.			Scanty notes. Says he has several cases but no allusion to others.		Recovery.

TABLE OF CASES OF CYST OF THE URACHUS—Continued.

Case No.	Operator and Reference.	Age.	Sex.	History and Symptoms.	Treatment.	Character of Cyst Contents.	Result.	Remarks.
48	Newman, Glasgow Medical Journal, 1896, XLVI, p. 20.	39	M.	Admitted for pain in hypogastric region of four days duration. Inability to urinate. Blood evacuated with catheter. Abdomen swollen, dull on percussion over hypogastrum. Swelling resembling a distended bladder. Improvement under expectant measures, but tenderness on pressure and fluctuation lead to intervention. Had a swelling in this locality so far back as he could remember.	Laparotomy. Accidental opening of cyst. Gelatinous contents having ammoniacal odor. Wall thin and smooth, extending from bladder to umbilicus. Cyst evacuated, flushed out and drained with tube, urine escaped into dressings through operation wounds, discontinuing after a month when wound closed.	Gelatinous contents of ammoniacal odor urine.	Recovery.	
49	Morgan, Lancet, 1896, II, p. 1154.	5	M.	No data except that it was a case of supposed peritonitis with no characteristic symptoms.	Cyst opened and it together with bladder were washed out. No attempt to dissect out cyst wall. Wound in cyst closed with double row of silk sutures, superficially placed. No mention of suppuration during operation, but abdominal wound discharged pus and urine for several days.		Recovery in one month.	
50	Carroll, Jane W., Buffalo Medical Journal, 1896, XXXV, p. 869.	34	F.	Recurrent bowel attacks for eleven years. Fever, pain, emaciation. Diagnosis of peritonitis made. When first seen had pain and soreness in right iliac region, tumor palpable. Recurring attacks of fever and pain while under observation.	Laparotomy. Cyst of urachus recognized with numerous adhesions. Dissected out and wound closed.		Recovery.	
51	Douglas, Am. Journal of Obstet. 1897, XXXVI, p. 477.	36	F.	18 months ago noticed swelling in lower abdomen, more marked to right soft and painless. Grew slowly up to four months ago, then more rapidly. Digestive disturbances, cough and loss of flesh, later vomiting. Urine normal. Examination gave evidence pointing to ovarian cyst.	Laparotomy. Cyst exposed and aspirated, 25 pints clear fluid drawn off. Diagnosis of urachal cyst now made. Cyst very adherent, but author enucleated it without much hemorrhage. Peritoneal cavity not entered but peritoneum detached from abdominal wall for a considerable area. No attempt to suture it, trusting intra-abdominal pressure would fix it in place. Wound closed without drainage.	Clear fluid.	Death in 48 hours.	Gangrene of detached peritoneum and death due to sapremia, shown at autopsy.

	M.	20	18 months before, after troubles of micturition, the urine being very cloudy, felt pain in umbilical region, which was also swollen. Soon after this, pus escaped at the navel and continued to do so at intervals. Bladder trouble became worse progressively. Patient found to have a gonorrhoeal cystitis, duration of infection could not be determined.	M.	43	About a year ago hemorrhage from bladder which continued to recur. Tumor size of orange felt above symphysis. Trial puncture, evacuation of turbid, yellow thickish fluid. Cystoscopy revealed tumor of the bladder.	Cystitis treated first. In washing out bladder pus appeared at the navel. Attempted radical cure of fistula. The urachus dissected out. Shape of bladder abnormal (tubular). Fistulous tissue extirpated, bladder wound closed.	Pus.	Recovery.
52	L e x e r, Archives f. klin. Chirurgie, LVII, p. 81, 1898.								
53	R o t t e r, Deutsch. Med. W o c h e n s c h r i f t, 1898, Vereisbeilage, p. 10.						Laparotomy. Tumor intimately adherent behind to peritoneum. Lower pole dipped into bladder. Cyst and tumor both extirpated. Healing throughout by first intention. Diagnosis cancer of bladder complicating urachal cyst.	Thick turbid yellow fluid.	Recovery.
54	D o r a u, Medico-Chirurg. Transactions, 1867, LXXXII, p. 301.						Laparotomy. Cyst incised and emptied and washed out. Its wall adherent to intestines and omentum. Second cyst beneath first, not the bladder. Was tapped and then opened. Two cavities made into one, packed and drained. No urine escaped. Not entirely healed for six months.	Inflammatory products.	Recovery.
55	M i c h e l i, Bollettino, I. Società Toscana di Ostetricia e Ginecologia, 1903, II, p. 211.						The cyst was the size of a pigeon's egg, or less. Wall mostly thin, transparent, and contained thick yellowish fluid. Was evidently extirpated whole as shown in plate.		
56	"						Not so large as preceding (small nut). Walls thicker, filled with thick clear liquid. Extirpated as shown in accompanying plate.	Thick clear fluid.	

TABLE OF CASES OF CYST OF THE URACHUS—Continued.

Case No.	Operator and Reference.	Age	Sex	History and Symptoms.	Treatment.	Character of Cyst Contents.	Result.	Remarks.
57	Matthais, Beiträge z. klin. Chirurg., 1904, XLII, p. 339.	48	M.	Came to Mikuliciz's clinic in 1901. Six months before tension in lower abdominal region. Urine turbid, tenesmus of bladder. General health suffered for next three months. Patient then improved, but symptoms suddenly returned to vanish again for two months. Returned a second time. Suspicion of cancer of bladder. Sent to Mikuliciz. Superficially placed, firm tumor, not sharply outlined, below navel, slightly more to right of middle line. Adherent to abdominal wall. Diagnosis of persistent urachus. When urine contained abundance of pus, patient felt better. Tumor varied in size.	Laparotomy. Abdominal wall dissected from tumor. Latter adherent to vertex of bladder. Cyst laid open and found to contain old blood clots and pus. Cyst size of a billiard ball. Water injected into bladder did not escape through cyst. Tumor detached with resulting perforation of the bladder. Bladder sutured and external wound closed.	Old blood clots and pus.	Recovery but fistula in abdomen had not closed at time of discharge.	
58	Patel, Revue des maladies France, 1904, XXII, p. 77.	3	M.	Fluctuating abdominal subumbilical tumor in middle line adherent to umbilicus. Persistent incontinence of urine, for which advice was sought. No connection established between tumor and bladder. Cyst of urachus thought of, also diverticulum of intestines, former hypothesis favored.	Medium laparotomy. Tumor exposed. Anterior aspect covered by peritoneum, readily separated. Cyst incised. Wall seemed to be muscular. Clear albuminous fluid evacuated. Impossible to extirpate cyst. Wall sutured together as in case of Hydatid cyst of liver. External wound closed. As cavity communicated with bladder, a retention catheter was inserted and left five days.		Recovery.	
59	Joseph Price,	Young	F.	Pain but complicating other abdominal troubles in all but two cases. All were suppurated; four were diagnosed during, and two before, operation.	Excision and closure in four cases, opened and drained two.			
60	"	"	F.					
61	"	"	F.					
62	"	"	F.					
63	"	"	F.					
64	"	"	F.					
	Pers'l letter.							

65	William J. Mayo,	F.	Slowly growing tumor discovered during sections.	Excision.	Cure.
66	"	F.	"	"	Death.
67	"	M.	"	"	Malignant. Recurred and died 11 mos. later.
68	Pers'l letter. Nicholas Senn. Pers'l letter.	F.	45 Swelling between umbilicus and pubes. Discovered during sections.	Excision.	Cure.
69	Edwin Martin.	M.	Fusiform, inflam. tumor. Diagnosed before operation.	"	Cure.
70	"	M.	"	"	Cure.
71	Pers'l letter. W. A. Smith. Pers'l letter.	F.	36 Discovered during operation.	Excision.	Cure.
72	Roswell Park,	..	Annoying discharge from umbilicus.	Excision.	Cure.
73	"	..	7	"	Cure.
74	"	..	2	No operation.	Cure.
75	J. F. Erdman,	F.	Young Fixed tumor in abdominal wall.	Excision.	Cure.
76	"	F.	Adult	"	Cure.
77	"	M.	Middle Age	Excision.	Cure.
78	Pers'l letter. Howard A. Kelly,	F.	27 Burning sensation on urination with increased frequency in micturition, in first case. Slight pressure about rectum for two years previous to operation, in second case. Swelling in lower abdomen, without pain, in third.	Cyst grasped on its peritoneal surface, pulled out to develop a pedicle. This was snipped through with scissors. No sutures or ligatures needed.	Two were diagnosed before and one during an operation.
79	"	F.	46	"	Cure.
80	"	F.	25	Cyst of urachus removed along with a piece of its pedicle.	Cure.

TABLE OF CASES OF CYST OF THE URACHUS—Continued.

No. of Case	Operator and Reference.	Age	Sex	History and Symptoms.	Treatment.	Character of Cyst Contents.	Result.	Remarks.
81	DeForest Willard,	Child	F.	Intermittent oozing of urine.	Plastic closure.		Cure.	
82	"	"	F.	Intermittent oozing of urine.	No operation.		Don't know.	
83	" Pers'l letter.	14	F.	Treated by family physician for two months for typhoid fever. Probably sepsis. When first seen had enormously large abdomen which had been distended for several weeks. The day previous to his first visit the umbilicus opened and several pints of pus discharged. No odor of urine and history gave no report of urinary discharge from umbilicus.	Wound in umbilicus enlarged and drained. The cavity healed after 3 months, and has since remained closed.	Pus.	Cure.	
84	E. Wyllys Andrews,	Young adult	}	All were small narrow sacks which gave no trouble and were accidentally discovered.	Treatment not stated.		Cure.	
85	"	Adult					Cure.	
86	" Pers'l letter.	"					Cure.	

The cases above tabulated represent the known clinical material as published up to this time, or at least all that a careful search revealed. The table contains in addition 28 cases which were secured by correspondence and which have not been previously reported (Cases 59 to 86).

The history of many of these cases as given is very meagre and some of them are of no clinical importance. I have, however, tabulated all of those secured by correspondence, although in most instances the data received is not sufficient to warrant a positive classification.

SEX AND AGE.

Of the 89 cases here tabulated, including the three of my own, there were twenty-one males, fifty-eight females, and seven in which sex was not stated.

That urachal cysts are more common in middle life (from 20 to 40 years), and that in adult life women are more frequently affected than men, is shown from the fact that in seventy-two cases where the age is given, thirty-four cases were between twenty and forty years of age. Twenty-nine of these were females and five males. Of fourteen cases under fifteen years of age an equal number were males and females, and of the remaining fifteen who were past forty, ten were females and five males. It was stated in five cases that the woman was pregnant at the time she presented herself for treatment.

HISTORY.

Perhaps the most constant factor in the history of this condition is a mass felt between the umbilicus and symphysis pubis, varying in size from a barely palpable mass to a very large tumor. The symptoms usually present are a feeling of illness, loss of flesh, pain, often fever, gastric disturbance, and indeed the appearance of a tubercular subject. In addition to these we have in 15 per cent. of cases a discharging sinus through the umbilicus.

Tait speaks of peculiarities in the percussion note.

Other phenomena resulting from attempts at diagnosis, bimanual palpation, tapping, etc., appear to be equivocal in character, excepting in the presence of polygonal epithelium in the sediment of the tapped fluid. This, if present, is said to be pathognomonic.

DIFFERENTIAL DIAGNOSIS.

This condition has been diagnosed as tubercular peritonitis, and to one who has not come in contact with urachal cyst it is a most pardonable error.

A large cyst of the urachus may be mistaken for a parovarian cyst or an ectopic gestation.

TREATMENT.

Tait's Technique is naturally depended upon largely in the treatment. Incision and drainage are the first essential. A large proportion of these cysts cannot be extirpated, and Tait used irrigation and mopping with iodine. In two of my cases I simply irrigated and drained, with good recovery.

The detached peritoneum is troublesome, but, as suggested by Douglas, may be sutured back to the parietes, the to omentum, or excised and spread over the gap.

REFERENCES.

- ¹Virchow's Archiv. xcii, p. 387.
- ²Medico-Chirurgical Transactions, 1898, lxxvi, p. 301.
- ³Archiv für Heilk., Bd. xi, 1870.
- ⁴Inaug. Dissertation, Marburg, 1873.
- ⁵Ovarian Tumors, p. 50.
- ⁶Diseases of the Ovaries.
- ⁷British Gynæcological Journal, 1886-7, ii, p. 328.
- ⁸ANNALS OF SURGERY, xiv., p. 350.
- ⁹ANNALS OF SURGERY, 1887, v., p. 107.
- ¹⁰American Journal of Obstetrics, 1897, xxxvi, p. 472.