

- 1 Delitala G, Masala A, Alagna S, Devilla L, Lodico G, Lottie G. Metergoline in the inhibition of puerperal lactation. *Br Med J* 1977;i:744-6.
- 2 Ferrari C, Caldara R, Romussi M, *et al.* Prolactin suppression by serotonin antagonists in man: further evidence for serotonergic control of prolactin secretion. *Neuroendocrinology* 1978;25:319-28.
- 3 Chiodini PG, Liuzzi A, Muller EE, *et al.* Inhibitory effect of an ergoline derivative, methergoline on growth hormone and prolactin levels in acromegalic patients. *J Clin Endocrinol Metab* 1976;43:356-63.
- 4 Besser GM, Delitala G, Grossman A, Yeo T. Metergoline and cyproheptadine suppress prolactin by a non-5-hydroxytryptaminergic, non-dopaminergic mechanism. *Br J Pharmacol* 1980;70:5-7.
- 5 Cavagnini F, Raggi U, Micossi P, DiLandro A, Invitti C. Effect of an anti-serotonergic drug, metergoline, on the ACTH and cortisol response to insulin hypoglycaemia and lysine-vasopressin in man. *J Clin Endocrinol Metab* 1976;43:306-12.

(Accepted 28 February 1985)

#### Royal Liverpool Hospital, Liverpool L7 8XP

I F CASSON, MD, MRCP, senior medical registrar  
B A WALKER, MD, FRCP, consultant physician

#### University of Liverpool, Liverpool L69 3BX

L J HIPKIN, MD, FRCPATH, senior lecturer in endocrine pathology  
P E BELCHETZ, MD, FRCP, senior lecturer in medicine

Correspondence to: Dr I F Casson.

## Men who steal children

The stealing of children is a rare offence. d'Orbán described three characteristic patterns in women who steal children—namely, comforting offences, manipulative offences (with the intention of influencing a male partner), and offences by psychotic women.<sup>1</sup> The associated psychiatric problems include hysterical personality disorder, mental handicap, and schizophrenia<sup>1,2</sup> and also pseudocycosis.<sup>3</sup> Child stealing is generally considered to be a crime committed by women. Until recently, however, most of the offences were committed by men,<sup>2</sup> and during 1977-82 the sexes were equally represented (34 men and 34 women).<sup>4</sup> There are no previous reports on men who steal children, but d'Orbán hypothesised that men are likely to steal older children for sexual motives.<sup>2</sup> We gathered available evidence on child stealing offences committed by men.

### Subjects and method

We inquired from colleagues in special hospitals, secure units, and a London remand prison about men charged with stealing children. We also collected press reports over six months in 1983. We examined four patients: three were charged with stealing children and one with theft of a car, but his admitted intention had been to use the vehicle to abduct a child. We also found two cases reported by the press. The table shows the salient features.

### Comment

This small series of cases is not representative of all men charged with child stealing. Nevertheless, the findings confirm our hypothesis and suggest that men who steal children differ from women in that they abduct older children rather than babies and their motivation is sexual. The four men examined had personality disorders, but, unlike a high proportion of women who steal children, none was mentally ill. All the men were paedophiles and had a preference for children of a specific age and sex. Five had a history of sexual offences against children, and in case 6 the judge's reported

remarks also indicated a sexual motive. Two men (cases 1 and 3) had sadistic fantasies about children.

Interestingly, two men (cases 4 and 6) were acquitted because the children had apparently accompanied the men voluntarily and the prosecuting counsel could not prove that the abduction had entailed force or fraud, which was a necessary element of the offence of child stealing under section 56 of the Offences Against the Person Act 1861. Another shortcoming of this law was that it did not apply to a natural parent, although nowadays most cases of abduction of children concern separated or divorced parents who abduct their own children. Until recently, the only legal protection in such cases was for a child to be made a ward of court, but in 1984 the House of Lords ruled that a parent can also be convicted of the common law offence of kidnapping his own child.<sup>5</sup>

The confusing legal position was simplified by the Child Abduction Act implemented in October 1984, which repealed the offence of child stealing under the 1861 Act and created two new offences—namely, abduction of a child under the age of 16 by a parent if the child is taken out of the United Kingdom without appropriate consent, and abduction of a child by other persons. Whereas the offence of child stealing required proof of force or fraud, the new offence of abduction of a child focuses on lack of consent by the parent or lawful guardian to the removal of the child and therefore provides stronger legal safeguards. The men in cases 4 and 6 who were acquitted of child stealing would probably have been convicted of abduction under the new legislation.

- 1 d'Orbán PT. Child stealing: a typology of female offenders. *British Journal of Criminology* 1976;16:275-81.
- 2 d'Orbán PT. Baby stealing. *Br Med J* 1972;ii:635-9.
- 3 d'Orbán PT. Child stealing and pseudocycosis. *Br J Psychiatry* 1982;141:196-8.
- 4 Home Office. *Criminal statistics England and Wales*. London: HMSO, 1977-82.
- 5 R v D. Law report. *The Times* 1984 Jun 22:14.

(Accepted 21 February 1985)

#### Academic Department of Psychiatry, Royal Free Hospital, London NW3 2QG

P T D'ORBÁN, MB, FRCPSYCH, consultant forensic psychiatrist

#### Maudsley Hospital, London SE5 8AZ

P HAYDN-SMITH, MB, MRCPSYCH, senior registrar in forensic psychiatry

Correspondence to: Dr P T d'Orbán.

## Torsade de pointes induced by sotalol despite therapeutic plasma sotalol concentrations

Sotalol, a  $\beta$  blocking agent with additional group III antiarrhythmic properties, prolongs the QT interval in a manner that depends on concentration.<sup>1</sup> Prolongation of the QT interval by sotalol has been associated with ventricular tachyarrhythmias, but controversy exists over whether it occurs in the absence of high doses (480 mg and more a day), intoxication with sotalol, or renal failure.<sup>2</sup> Ventricular tachycardia due to prolongation of the QT interval has been reported in a patient taking normal doses of sotalol (320 mg daily), but the concentration of sotalol was not measured.<sup>3</sup> We report a case of sustained torsade de pointes induced by sotalol that necessitated cardioversion. The patient was taking a normal oral dose of sotalol and had therapeutic plasma sotalol concentrations.

### History of offenders

Case No	Age (years)	Charge	Age (years) and sex of victim	Previous sex offences	Outcome	Source
1	24	Child stealing	8 F	Four indecent exposures	Hospital order with restriction (psychopathic disorder)	Special hospital
2	29	Child stealing	4 F	Attempted rape (girl aged 5); indecent assault (girl aged 8)	Hospital order with restriction (psychopathic disorder)	Secure unit
3	26	Car theft (with intent to abduct girl)		Indecent assaults (girls aged 7 and 8)	Hospital order (psychopathic disorder)	Secure unit
4	27	Child stealing (three counts), indecent assault, administering drugs (diethylpropion)	11, 12, 13 M	Indecent assault (boy aged 10)	Acquitted of child stealing. Convicted of administering drug	Remand prison
5	48	Child stealing, attempted gross indecency	9 M	Numerous offences against boys	Six years' imprisonment	<i>The Times</i> (22 Dec 1983)
6	61	Child stealing	4, 5 F	Not known	Acquitted	<i>The Times</i> (19 Nov 1983)

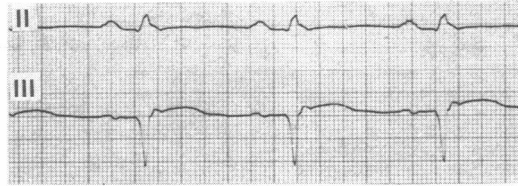
**Case report**

A 65 year old woman with a history of inferior myocardial infarction who was taking oral digoxin 0.25 mg daily and maprotiline 75 mg daily underwent total hip replacement. Postoperatively, supraventricular tachycardia developed, which was converted into sinus rhythm by the administration of verapamil twice (2.5 mg intravenously). To prevent the arrhythmia and correct coexisting hypertension treatment with sotalol 160 mg twice daily was started.

lead to ventricular tachycardia similar to torsade de pointes, which is probably due to prolongation of the QT interval. The plasma concentrations and half life of sotalol in this patient were comparable with those in healthy subjects given similar doses.<sup>4,5</sup> Before and after treatment with sotalol the QT interval was normal and no ventricular arrhythmia was observed. The temporal association indicates that digoxin and maprotiline did not have a role, although theoretically an interaction of sotalol with digoxin or maprotiline, or both cannot be

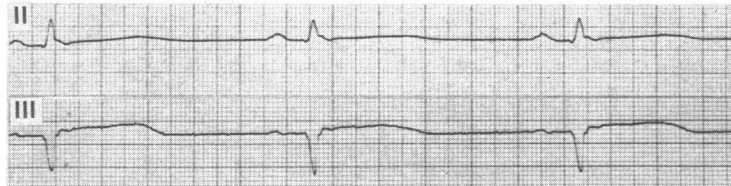
Before sotalol:

Rate 93 beats/min  
QT interval 320ms



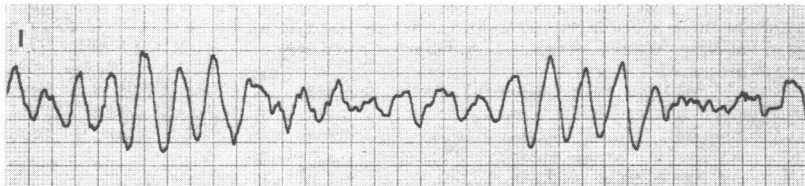Six hours after:

Sotalol 2.45 µg/ml  
Rate 52 beats/min  
QT interval 540 ms



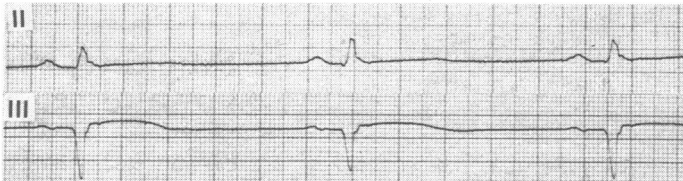
Seven hours after:

Torsade de pointes  
Ventricular  
tachycardia  
Rate about  
220 beats/min



24 hours after:

Sotalol 1.36 µg/ml  
Rate 52 beats/min  
QT interval 440 ms



Electrocardiographic recordings and concentrations of sotalol before and after treatment. (Paper speed was 50 mm/s except in lead with torsade de pointes (25 mm/s).)

Before the start of treatment the sinus rate was 93 beats/min and the QT interval 320 ms. Twenty four hours later (total oral dose of sotalol 480 mg) she had sinus bradycardia (54 beats/min) with prolongation of the QT interval to 530 ms (normal 420 ms (SD 10%)). Sotalol was stopped and digoxin and maprotiline continued. The plasma digoxin concentration was 2.2 µg/l (normal 0.6-3.2 µg/l). Serum creatinine, potassium, calcium, and magnesium concentrations were repeatedly within normal limits. In particular, the serum potassium concentration at the time of ventricular tachycardia was 4.0 mmol/l. Postoperatively, the creatine kinase activity was 304 U/l (normal 0-109 U/l) with an MB fraction of 13 U (control value 12 U).

Electrocardiograms were obtained and plasma sotalol concentrations measured six, 12, and 24 hours after withdrawal of sotalol; the concentrations were 2.45, 2.10, and 1.36 µg/ml, respectively (figure). The half life of sotalol ( $t_{1/2}$ ) in this patient was calculated to be 19.14 hours:

$$t_{1/2} = \frac{\ln 2}{k} \quad \text{with } k = \frac{\ln C_{12} - \ln C_{24}}{12}$$

( $\ln$  = logarithmus naturalis; C = concentrations at 12 and 24 hours.)

Seven hours after the last dose of sotalol persistent ventricular tachycardia with torsade de pointes developed, causing unconsciousness, which was unresponsive to lignocaine 100 mg intravenously. After cardioversion with 100 W sinus bradycardia recurred. After this no antiarrhythmic drugs were given. Two days later the sinus rate and QT interval had normalised (66 beats/min, 380 ms) with the continued administration of digoxin and maprotiline. No further ventricular arrhythmia was observed during constant cardiac monitoring for 72 hours after the withdrawal of sotalol.

**Comment**

This case shows that sotalol given in average oral doses (320 mg daily), and plasma concentrations within the therapeutic range, can

excluded entirely. The arrhythmogenic effect of sotalol is due to one of its intrinsic antiarrhythmic properties, the prolongation of the QT interval.

Clinicians should be aware of this potentially fatal complication even in a patient taking average doses of sotalol whose plasma concentrations are within the therapeutic range. Strict and early control of the QT interval should be carried out when treatment is started.

Plasma sotalol concentrations were measured by Bristol-Myers (Belgium/USA).

- 1 Neuvonen PJ, Elonen E, Tanskanen A, Tuomilehto J. Sotalol and prolonged Q-Tc interval. *Lancet* 1981;ii:426.
- 2 Laakso M, Pentikäinen PJ, Pyörälä K, Neuvonen PJ. Prolongation of the Q-T interval caused by sotalol—possible association with ventricular tachyarrhythmias. *Eur Heart J* 1981;2:353-8.
- 3 Kuck KH, Kunze KP, Roewer N, Bleifeld W. Sotalol-induced torsade de pointes. *Am Heart J* 1984;107:179-80.
- 4 Brown HC, Carruthers SG, Kelly JG, McDevitt DG, Shanks RG. Observations on the efficacy and pharmacokinetics of sotalol after oral administration. *Eur J Clin Pharmacol* 1976;9:367-72.
- 5 Anttila M, Arstila M, Pfeffer M, Tikkanen R, Vallinkoski V, Sundquist H. Human pharmacokinetics of sotalol. *Acta Pharmacol Toxicol* 1976;39:118-28.

(Accepted 18 February 1985)

Insel University Hospital, CH-3010 Berne, Switzerland

R KRAPP, MD, assistant in medicine

M GERTSCH, MD, assistant professor in cardiology

Correspondence to: Dr R Krapf.