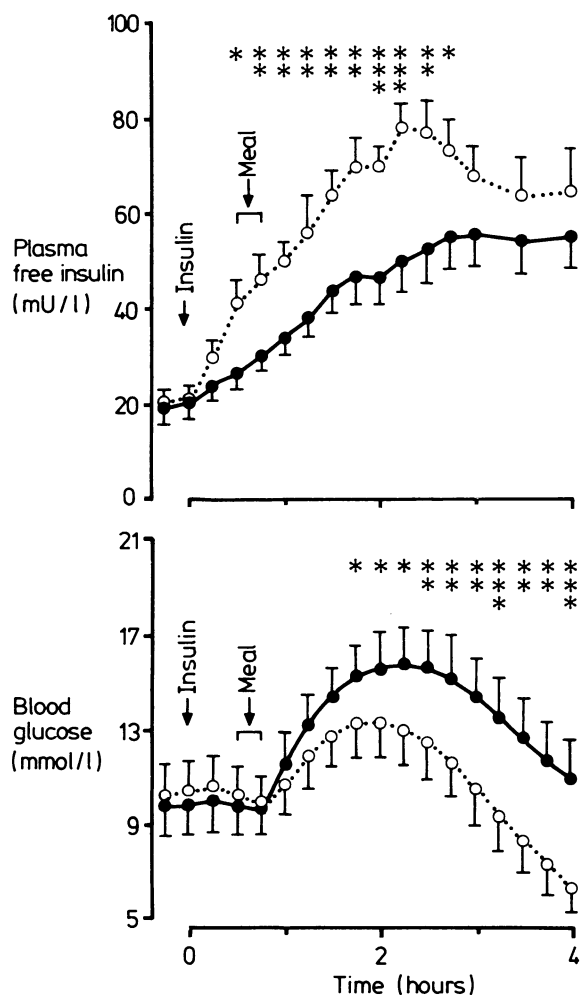


mediate acting insulins and were studied twice with an interval of one week in between. Patients were randomised to receive either human Actrapid plus human Monotard or human Velosulin plus human Insulatard initially and then received the other combination during the second period of study. All insulins were of U40 strength. The tests began at least 30 minutes after cannulation. After an overnight fast the morning dose of short acting (mean 12.6 IU, range 4-36 IU) and intermediate acting insulin (mean 32.2 IU, range 16-52 IU) was administered by one of us. The insulins were injected perpendicularly into the thigh immediately after mixing in the syringe (Plastipak). The mean (range) ratio between short and intermediate acting insulin was 0.39 (0.11-0.90). After 30 minutes a standard liquid meal (2.1 MJ (500 kcal), 56% carbohydrate) was taken. Blood glucose concentrations and plasma free insulin concentrations (measured by radioimmunoassay after plasma extraction with macrogol (polyethylene glycol)) were measured at regular intervals for four hours. Statistical analysis was by Student's paired *t* test and Kendall's rank correlation test. Results are given as means (1 SEM).

Postprandial blood glucose concentrations rose to higher peaks after short acting plus lente insulin than after short acting plus isophane insulin: from 9.9 (1.3) to 16.5 (1.5) mmol/l (178 (23.4) to 297 (27) mg/100 ml) at 130 (9) minutes, compared with from 10.5 (1.2) to 13.6 (1.5) mmol/l (189 (21.6) to 245 (27) mg/100 ml) ( $p < 0.01$ ) at 118 (6) minutes (figure). Blood glucose concentrations were significantly different from 105 to 240 minutes.



Postprandial plasma free insulin and blood glucose concentrations after administration of short acting with lente (●—●) and short acting with isophane (○- - ○) insulin mixtures in 13 patients with type I diabetes.

\* $p < 0.05$ , \*\* $p < 0.005$ , \*\*\* $p < 0.001$ .

Conversion: SI to traditional units—Glucose: 1 mmol/l  $\approx$  18 mg/100 ml.

Plasma free insulin concentrations rose faster after short acting plus isophane insulin than after short acting plus lente insulin: from 20 (3) and 20 (3) mU/l to peaks of 91 (8) and 64 (7) mU/l ( $p < 0.01$ ) at 137 (9) and 172 (13) minutes ( $p < 0.05$ ), respectively. Plasma free insulin concentrations were significantly different from 30 to 165 minutes (figure). The initial rate of absorption of insulin (incremental peak concentration divided by the time in which it was reached) was significantly greater after short acting plus isophane insulin than after short acting plus lente insulin (0.54 (0.06) v 0.26 (0.04) mU/l/min ( $p < 0.001$ )). These values were positively correlated

with the ratios of short to intermediate acting insulins (for short acting plus lente insulin  $r = 0.62$ ,  $p < 0.01$ ; for short acting plus isophane insulin  $r = 0.54$ ,  $p < 0.02$ ).

## Comment

This study shows that mixing short acting with lente insulin in the syringe immediately before injection delays absorption of the insulin and causes higher postprandial blood glucose concentrations than a mixture of short acting plus isophane insulins. The results agree with our findings in healthy volunteers.<sup>2</sup> Retarded absorption is probably caused by the excess of zinc in lente insulin, which binds the added short acting insulin.<sup>3-5</sup> The relation between the rate of absorption of insulin and the ratio between short and intermediate acting insulins in the mixture suggests that the dosage of short acting insulin may be reduced by changing from a combination of a short acting plus lente insulin to a short acting plus isophane insulin.

- 1 Kahn CB. Insulin therapy. In: Kozak GP, ed. *Clinical diabetes mellitus*. Philadelphia: W B Saunders, 1982:72-85.
- 2 Heine RJ, Bilo HJG, Fonk T, van der Veen EA, van der Meer J. Absorption kinetics and action profiles of mixtures of short and intermediate acting insulins. *Diabetologia* (in press).
- 3 Hallas-Møller K, Peterson K, Schlichtkrull J. Crystalline and amorphous insulin zinc compounds with prolonged action. *Ugeskr Laeger* 1951;113:1761-7.
- 4 Grootendorst BC, Jonkers JR, Kruit L. The miscibility of short acting insulins with depot insulins: an in vitro study. *Pharm Weekbl [Sci]* 1983;118:746-51.
- 5 Berger M, Cüppers HJ, Hegner H, Jörgens V, Berchtold P. Absorption kinetics and biologic effects of subcutaneously injected insulin preparations. *Diabetes Care* 1982;5:77-91.

(Accepted 2 October 1984)

Department of Internal Medicine, Free University Hospital, 1081 HV Amsterdam, The Netherlands

R J HEINE, MD, physician  
H J G BILO, MD, physician  
A C SIKKENK, MD, research associate

Department of Endocrinology, Free University Hospital

E A VAN DER VEEN, PHD, physician

Correspondence to: Dr R J Heine.

## Necrotising glomerulonephritis associated with cholesterol microemboli

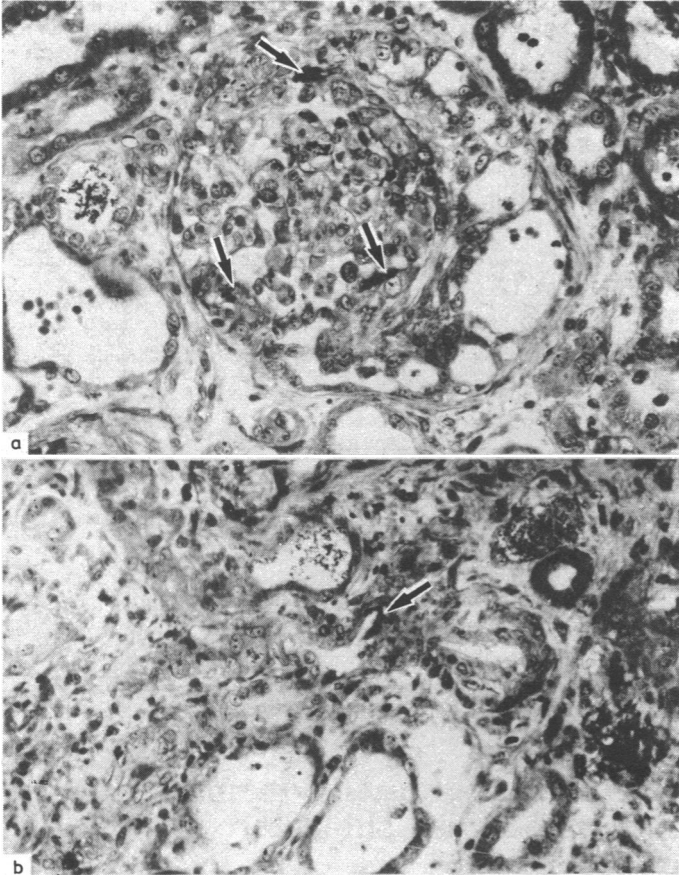
Embolisation of cholesterol in the kidneys may result in severe, irreversible renal failure.<sup>1</sup> Antemortem diagnosis can sometimes be established by renal biopsy when characteristic crystalline clefts are seen in arterial lumens and ischaemic changes in the renal parenchyma.<sup>2</sup> Although fibrinoid necrosis of small vessels has been associated with microemboli of cholesterol,<sup>3,4</sup> necrotising angiitis in the kidney has not been reported as a manifestation of cholesterol embolisation. We describe a case of necrotising glomerulonephritis associated with cholesterol microemboli in an elderly man with extensive aortic atheromatosis.

## Case report

A 75 year old man with chronic obstructive pulmonary disease was admitted to this hospital in October 1982 with acute bronchitis. He had a long history of coronary insufficiency and had recently experienced transient right hemianopsia. Results of biochemical tests were unremarkable apart from an increased erythrocyte sedimentation rate (72 mm in the first hour). Serum urea concentration was 3.7 mmol/l (22 mg/100 ml) and creatinine concentration 97  $\mu$ mol/l (1.1 mg/100 ml); no proteinuria was found, and the urine sediment was normal. Treatment with antibiotics resulted in a rapid improvement of the pulmonary state. Funduscopic examination showed three cholesterol emboli in the right retina, and computed tomography of the brain indicated scattered bilateral ischaemic lesions. On 15 November carotid angiography was performed via the femoral artery. It showed an ulcerated atheromatous plaque in the right internal carotid artery and several stenotic lesions of the intracerebral vessels. Severe atheromatous lesions were present in the aorta.

On 21 December he developed oliguria and rapidly progressive renal failure. Blood urea nitrogen concentration was 32.5 mmol/l (91 mg/100 ml) and serum creatinine concentration was 407  $\mu$ mol/l (4.6 mg/100 ml). The urine sediment contained +++ red cells, and transient macroscopic haematuria was noted. Proteinuria was 1.5 g/day. On 23 December he was anuric and

haemodialysis was started. Percutaneous renal biopsy two days later showed focal necrotising glomerulonephritis with the formation of crescents (figure (A)). Two small arterioles exhibited fibrinoid necrosis with the presence of needle shaped crystalline clefts (figure (B)). Immunofluorescence failed to detect deposits of immune reactants. Renal failure appeared to be irreversible, and he received maintenance treatment with haemodialysis. Six months later he died from a stroke. At necropsy the presence of characteristic crystalline clefts in several arteries and arterioles confirmed the diagnosis of renal cholesterol embolisation.



A: Glomerules showing focal necrosis (arrows) and extracapillary reaction. B: Arteriole with necrosis (arrow) around needle shaped crystalline cleft. Masson's trichrome  $\times 300$  (original magnification).

### Comment

Our patient had evidence of atheroembolic disease in the retina, brain, and kidney. The necrotising glomerulonephritis was probably directly related to renal cholesterol embolisation because fibrinoid necrosis around a cholesterol crystal was observed in the renal biopsy specimen. Necrotising angiitis of distal vessels associated with cholesterol microemboli has been described in other organs,<sup>3,4</sup> and cholesterol embolisation may result in a multisystemic disease simulating polyarteritis nodosa.<sup>3</sup> Our case indicates that necrotising angiitis resulting from cholesterol embolisation may also occur in the kidney and lead to severe glomerulonephritis with formation of crescents similar to those observed in the microscopic form of polyarteritis nodosa.

Cholesterol embolisation may occur spontaneously but is usually a complication of angiographic procedures or aortic surgery.<sup>1</sup> In our case aortic catheterisation for carotid angiography may have had a role in the development of renal embolisation; the time between the angiography and the onset of renal failure was consistent with this hypothesis.<sup>1</sup> The nephropathy of our patient was rapidly progressive and irreversible, as usually occurs after renal cholesterol embolisation.<sup>5</sup>

Cholesterol embolisation may result in protean clinical manifestations and is recognised as a possible cause of renal failure in patients with aortic atheromatosis.<sup>1</sup> We suggest that necrotising glomerulonephritis should be included in the clinical manifestations of cholesterol embolisation.

1 Smith MC, Chose MK, Henry AR. The clinical spectrum of renal cholesterol embolization. *Am J Med* 1981;71:174-80.

2 Jones DB, Iannaccone PM. Atheromatous emboli in renal biopsies. *Am J Pathol* 1975;78:261-70.

- 3 Richards AM, Eliot RS, Kanjuh VI, Bloemendaal RD, Edwards JE. Cholesterol embolism, a multiple-system disease masquerading as polyarteritis nodosa. *Am J Cardiol* 1965;15:696-707.
- 4 Anderson WR. Necrotizing angiitis associated with embolization of cholesterol. *Am J Clin Pathol* 1965;43:65-71.
- 5 Kassirer JP. Thrombosis and embolism of the renal vessels. In: Earley LE, Gottschalk CW, eds. *Strauss and Welt's diseases of the kidney*. Boston: Little, Brown, 1979:1393.

(Accepted 26 October 1984)

### Departments of Nephrology and Pathology, Cliniques Universitaires de Bruxelles, Hôpital Erasme, Université Libre de Bruxelles, Belgium

M GOLDMAN, MD, resident, department of nephrology  
Y THOUA, MD, resident, department of pathology  
M DHAENE, MD, resident, department of nephrology  
C TOUSSAINT, MD, head of department of nephrology

Correspondence to: Dr M Goldman, Hôpital Erasme, Service de Néphrologie, 1070 Brussels, Belgium.

## Micro-organisms isolated from skin under wedding rings worn by hospital staff

Little evidence exists to support theories on the risk of infection from rings worn by hospital staff. The bacterial flora of skin under rings is not predictable because changes encouraged by occlusion could be offset by the release of toxic metal ions, such as silver and copper, from gold alloys. We surveyed the microflora isolated from skin under rings worn by hospital staff.

### Methods and results

Fifty nurses working on medical and surgical wards who permanently wore rings took part in the survey. Rings were removed and the skin underneath sampled with a swab that neutralised the residual action of any skin disinfectants. A similar area on a non-adjacent finger of the same hand served as a control site. Bacteria were grown on caesin, yeast extract, lactose, and glucose agar and MacConkey agar number 3 (Oxoid) and Gram negative bacilli identified by API 20E (API Laboratory Products) and conventional tests. The lower limit of detection was 10 colony forming units/swab. Nurses whose ring site yielded Gram negative bacilli were sampled at intervals for five months. At the end of the survey samples were obtained from all of the nurses who were still working at the hospital.

### Occurrence and distribution of Gram negative species colonising skin under rings

Organism	No of staff colonised	No of colony forming units/swab
<i>Enterobacter cloacae</i>	10	10-24 000
<i>Klebsiella pneumoniae ssp aerogenes</i>	5	10-2 200 000
<i>Acinetobacter calcoaceticus</i>	3	110-560 000
<i>Pseudomonas aeruginosa</i>	2	7 200-40 000
<i>Serratia marcescens</i>	1	48 000
<i>Proteus mirabilis</i>	1	50
<i>Providencia stuartii</i>	1	14 000

The numbers of organisms comprising the normal Gram positive flora were significantly increased at ring sites, with a geometric mean of 1600/swab from the skin under rings and 180/swab from control sites ( $p < 0.001$ , paired  $t$  test). Of the 50 nurses originally sampled, 20 had Gram negative bacilli on the skin under their rings and one also had Gram negative bacilli on the control site. The geometric mean number of Gram negative bacilli on these ring sites was 730/swab (range 10 to 2 760 000). The table shows the distributions of some species found. Other species isolated (and the number of nurses colonised) were: *Enterobacter agglomerans* (three), *Ent aerogenes* (one), *Klebsiella oxytoca* (three), *Pseudomonas paucimobilis* (one), *Ps putida* (one), *Serratia liquefaciens* (one), *Aeromonas hydrophila* (one), *Kluyvera sp* (one), *Citrobacter freundii* (one), and *Escherichia coli* (one). The single control site that showed Gram negative bacilli yielded 50 *Kleb pneumoniae ssp aerogenes*, which were indistinguishable from those on the ring site. The ring site was colonised by one species in eight cases, by two species in eight, by three species in three, and four species in one.

Over the five months of the study 16 of the original 20 colonised nurses had Gram negative bacilli on the ring site on at least one other occasion. In most cases the strains were present each time the nurses were sampled (up to six samples). The final sample from two nurses yielded Gram negative bacilli although these had not been present in the initial sample.