
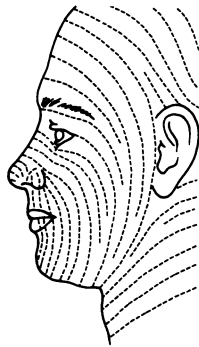


SCARS, HYPERTROPHIC SCARS, AND KELOIDS

Relaxed skin tension lines



Plastic surgeons have the enviable reputation with the lay public of being able to produce invisible scars, but unfortunately this goal cannot be attained. All surgeons try to produce a slender, pale scar that is flat, but despite great attention to surgical technique some patients develop an itchy, raised, and broad scar that is unattractive. Several factors influence the final cosmetic appearance of a scar:

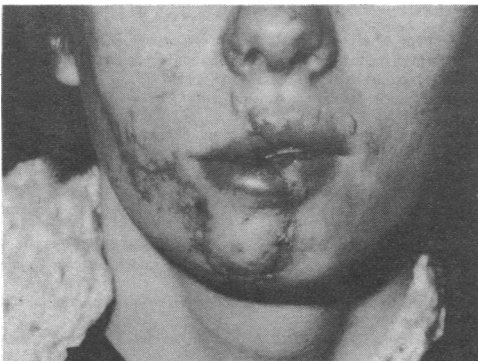The site on the patient—Scars tend to be excellent on the eyelids but poor on the shoulders and presternal regions. Elective incisions should be placed so that the underlying muscles apply the least tension across the wound. These are not consistent with Langer's lines or, always, with the skin creases of old age, though the second are a good guide. The relaxed skin tension lines may be derived by pinching the skin and observing the ease and size of the furrows and ridges formed. Pinching at right angles to the relaxed skin tension lines is performed with greater ease and produces a longer furrow, and it is along this line that the scar should be placed. Collagen in the dermis is predominantly orientated in a plane perpendicular to the underlying muscle pull. The collagen formed in scars is parallel to the long axis of the scar. Thus a scar placed perpendicular to the muscle pull will heal with collagen fibres orientated in the same direction as normally present. The scar will then merely be an accentuation of the normal pattern.

The age of the patient—Old people tend to develop almost invisible scars on the face, whereas younger patients tend to develop livid scars. Interestingly, pregnant women develop scars that behave like those in children.

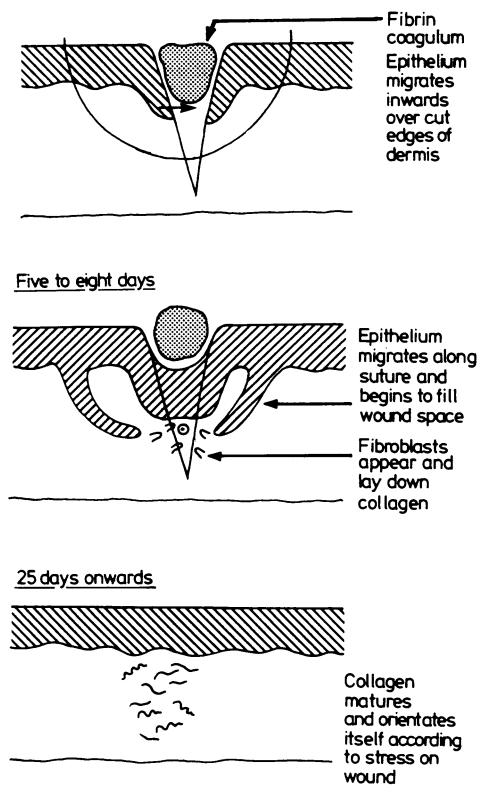
The amount of pigmentation—Dark skinned people are far more likely than lighter skinned people to develop a keloid.

A family history of keloid formation may be important, but this has not been statistically proved.

The shape of the scar—A U or V shaped scar tends to form a raised trap door because of poor lymphatic drainage and unequal scar contraction, especially if the injury is shelving.

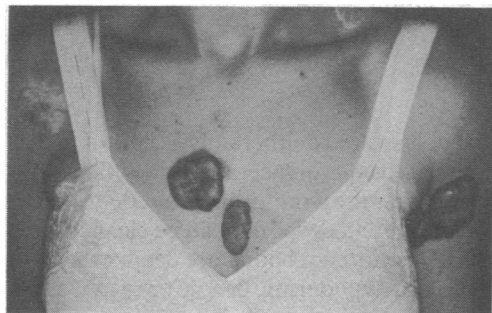

Pathophysiology of wound healing



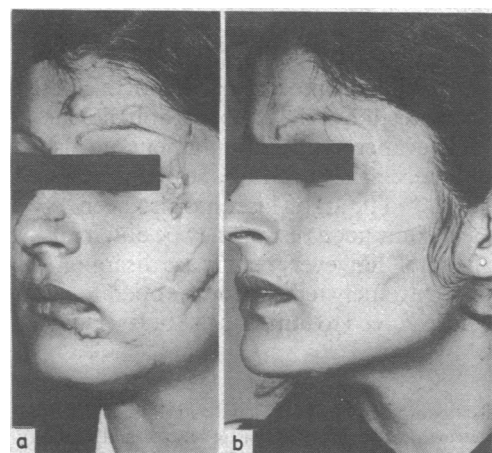The edges of a surgically incised wound are neatly opposed with a suture and the wound edges carefully everted. Histological examination of the healing wound shows many complex cellular reactions. The surface of the wound becomes covered with a fibrin coagulum that seals off the edges of the wound. The epithelial wound edge almost always becomes inverted, grows down into the wound over the dermis to the level of the dermal fat junction, and within five days has migrated across and underneath the fibrin plug. At one week there is a solid core of epithelium in the wound that communicates with a spur of epithelium that has grown down every skin suture track. At about two weeks there is regression of the invasive spur down in the wound and also of the epithelium lining the suture track. At a deeper level in the dermis healing occurs by the invasion of blood capillaries and fibroblasts, the fibroblasts laying down initially immature collagen. This is followed by a much longer phase of scar maturation. This lasts for many months, in which the collagen content increases slowly but mainly undergoes maturation and remodelling so that the collagen bundles reorientate themselves in the scar depending on local forces. At the same time some fibroblasts mature into myofibroblasts, which have the ability to contract and produce scar contracture.

Stress is important as it not only influences the arrangement of the collagen fibres but also determines the activity of the myofibroblasts. Scar contractures tend to occur over the flexor surfaces of joints but not so readily on the extensor aspect. This is partly in response to compression and buckling forces, which stimulate the formation of more collagen, and the contraction of the myofibroblasts, resulting in thick, hypertrophic scars on the flexor aspects of joints.



Clinically, a healed scar initially goes through a red, raised period. Over six months to one year this matures to produce a hypopigmented, flat scar. In some patients, for no particular reason other than the factors mentioned above, the scar goes on to become increasingly red, raised, and itchy. The scar at this point is described as being hypertrophic. If after a year it continues with these symptoms and also tends to invade the surrounding, unaffected, normal tissue as well as increasing in height it is called a keloid scar (derived from the Greek word kelis meaning claw like). The exact clinical differentiation between a hypertrophic scar and a keloid scar is not distinct, and there is no histological difference between the two, but if such scars are compared with a normal scar considerable increases are seen in the amount of immature collagen present. Interestingly, only man forms keloids.

Management of scars



Scar maturation without surgery

TRAUMATIC SCARS

The most important time to influence the cosmetic result of a scar is at the time of its initial repair. Elective scars should be placed in the most favourable anatomical position and sutured using an atraumatic technique. In general, interrupted cutaneous sutures should be left in situ for only a few days to avoid cross hatching marks. I advocate the use of a subcuticular suture in most positions on the body except the face. In traumatically induced lacerations thorough debridement of anaesthetised wounds is required together with a conversion of ragged injuries into straight edged wounds. In general, once initial repair of the wound has been undertaken the scar should be left alone to mature for up to one year. This is because many scars that start out red and appear cosmetically unattractive will with maturity fade and become less obvious. A scar should be excised early only if it will obviously require revision at a later date, either because it contains foreign material producing tattooing or because it is distorting anatomical features.

HYPERTROPHIC AND KELOID SCARS

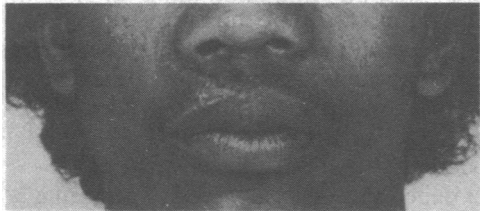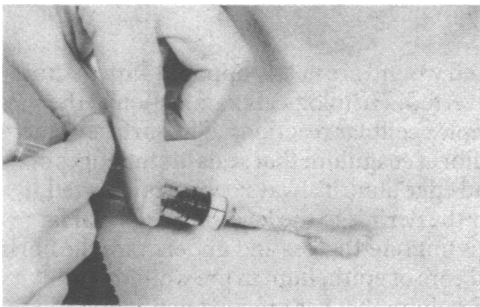
Hypertrophic and keloid scars are extremely difficult to treat satisfactorily. When presented with a scar and an intradermal tumour of unknown aetiology, the diagnosis of a keloid should always be borne in mind as simple excision may result in a larger and more unsightly scar being produced. The following therapeutic measures may, however, help:

Intralesional steroids—Triamcinolone may be injected intralesionally or applied topically as a cream. This will in most cases cure itching and in some cases improve the pigmentation. Its disadvantage is that if overused it will produce a hypotrophic, depigmented, thin scar with telangiectasia, which may be equally unattractive.

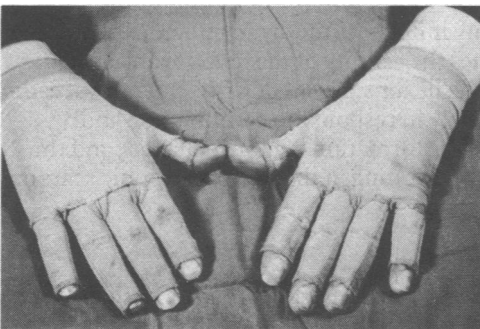
Intralesional excision—Excision within the borders of the keloid tumour produces variable results.

Surgical excision with perioperative or postoperative superficial x ray treatment of 16 Gy (1600 rad) in four fractions, the first preferably being given immediately before operation, can give good results in difficult keloids. I appreciate that some clinicians believe that superficial x ray treatment is never indicated for a benign condition and certainly would not advocate its use in very young patients or on the lower abdomen in women of childbearing age. I would reserve it for cosmetically disfiguring cases of the head and neck.

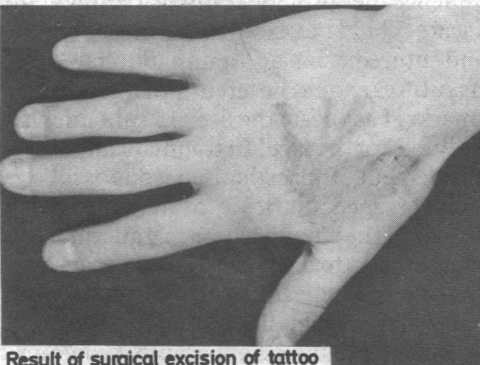
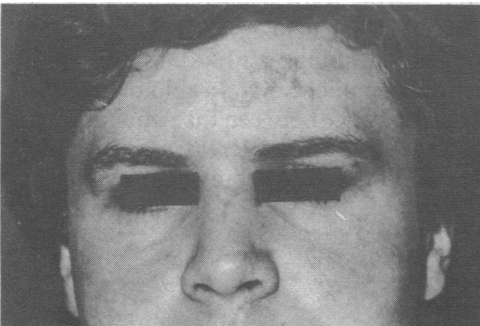
Topical pressure hastens collagen maturation and flattens the scar. Treatment should be started early and requires an individually measured elasticated garment to be made. It should be worn both day and night for at least one year or until the symptoms have improved permanently. In general, the garments are well tolerated except on the head and neck and they are the favoured treatment for extensive scarring after burns. Topical pressure has the particular advantage over the two previously described treatments of not having any particular complications, except in children, in whom pressure garments on the thorax have in a few cases interfered with growth of the spine, causing a scoliosis.



Successful excision one year postoperatively of 3 x 2 cm keloid with perioperative radiotherapy



Tattoos



Result of surgical excision of tattoo

Tattoos may be either traumatic or acquired deliberately as part of body adornment. The former occur after explosions or lacerations in which a pigmented foreign material impregnates the wound and is not debrided at the initial time of injury. Most contaminated wounds can be cleaned by scrubbing with a stiff brush, but if the foreign bodies are deeper they should be picked out individually with a hypodermic needle or each wound should be laboriously excised. Wounds that have healed and are tattooed by a foreign body require excision.

Decorative tattoos may be either self induced, usually with a pin and indian ink, or professionally obtained. The standard treatment is the same for both. The tattoo is shaved down in layers with a skin grafting knife, either under local or general anaesthetic, until all the pigment has been removed. In most cases the pigment lies below the dermis and a skin graft is required for the wound to heal.

In recent years lasers have been introduced into clinical practice. There were several optimistic reports on the results of the use of carbon dioxide lasers, but this energy beam not only evaporates the ink pigment but also destroys the overlying skin. Thus it necessarily produces scarring and is indicated only in small amateur tattoos. The argon laser has also been advocated for removing tattoos, and some good results may be obtained with small indian ink tattoos. In general, however, results are disappointing and not invisible, and the process is extremely tedious for the operator to perform. A law has recently been introduced to limit the use of lasers to establishments that are licensed.

Mr D M Davies, FRCS, is consultant plastic surgeon, West London Plastic Surgery Centre, West Middlesex University Hospital, Isleworth, and consultant plastic surgeon and honorary senior lecturer, Royal Postgraduate Medical School, Hammersmith Hospital, London W12 0HS.