

Case report

Cutaneous vasculitis complicating coeliac disease

S MEYERS,* S DIKMAN, H SPIERA, N SCHULTZ, AND H D JANOWITZ

From the Department of Medicine, Pathology and Dermatology, Mount Sinai School of Medicine, of the City University of New York, New York City, USA

SUMMARY A 38 year old female, with chronic uncontrolled coeliac disease, presented with the rare complication of cutaneous leucocytoclastic vasculitis. Detailed study failed to identify any cause for the vasculitis, other than the underlying coeliac disease. Haematuria and proteinuria with mesangial nephritis were also demonstrated on renal biopsy with electron microscopic study. It is speculated that exogenous or endogenous antigens permeated the abnormal small bowel mucosa leading to formation of circulating immune complexes. Subsequent tissue deposition of these complexes then resulted in vasculitis and nephritis. The skin lesions cleared completely after treatment with a strict gluten free diet.

Coeliac disease may give rise to a variety of dermatological manifestations.¹ Cutaneous vascular inflammation has been noted in some cases associated with cryoglobulinaemia.²⁻⁵ We report in detail the occurrence of leucocytoclastic vasculitis in a patient with established, poorly controlled coeliac disease.

Case report

A 38 year old Caucasian woman was admitted to the Mount Sinai Hospital, with a 20 year history of coeliac disease. Initially, institution of a gluten free diet resulted in complete clinical, biochemical, and histological remission. As her compliance waned, there was recurrence of her malabsorptive state for at least 10 years before the current hospital admission. Two months before admission, she noted the sudden development of purpuric, painful nodules over both lower extremities. These lesions coalesced to form indolent ulcers. Two months before the appearance of the skin lesions, she received a five day course of a sulphonamide for treatment of cystitis. No other medications or immunisations were given. She denied any drug allergy, fever, pruritis, joint pain, or Raynaud's phenomena. There was a 15 year history of insulin dependent diabetes, well controlled with isophane insulin suspension.

Incidentally, she had had documented microscopic haematuria and proteinuria for five years; intravenous pyelogram, cystoscopy, and renal function tests were normal.

Results of the general physical examination were normal. There was no lymphadenopathy or hepatosplenomegaly. Deep ulcerations were present on both lower extremities (Fig. 1). All pulses were normal.

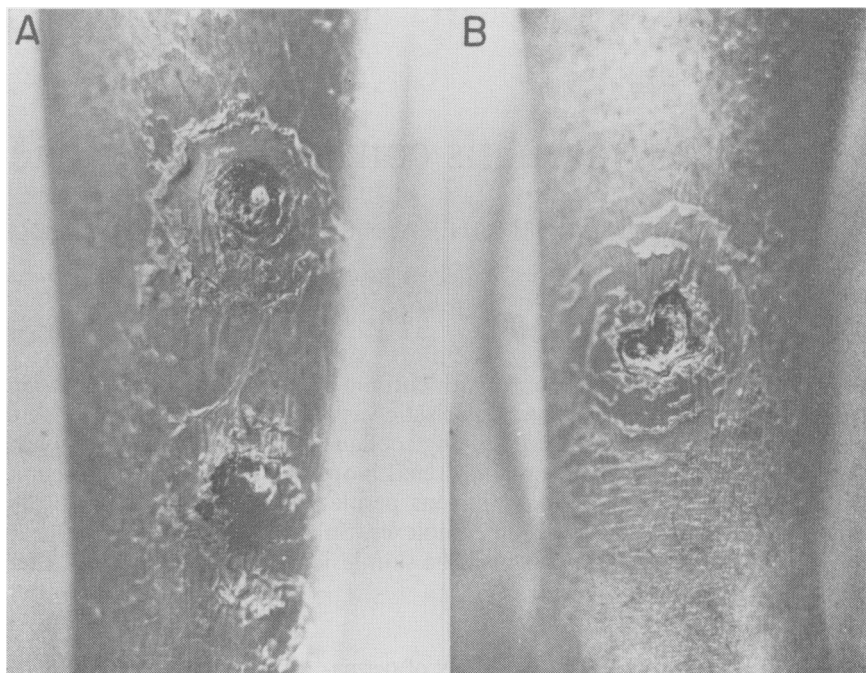
Skin biopsy obtained from the ulcer edge was characteristic of leucocytoclastic vasculitis (Fig. 2). Immunofluorescent study of skin, with fluorescein conjugated monospecific antibody, revealed deposits of IgG, IgA, IgM, fibrin, and third complement component in the dermal blood vessels. In addition, a granular IgA staining at the dermal-epidermal junction, consistent with gluten enteropathy, was present.

Small intestinal mucosal biopsy showed complete loss of villi with plasma-cytic infiltration of the lamina propria. Contrast radiographs of the small bowel were consistent with sprue. There was no evidence of malignant lymphoma in the biopsy, radiographs, or abdominal CT scan and sonogram. Twenty-four hour faecal fat excretion was 12.2 g.

Urinalysis showed proteinuria and numerous red blood cells; no casts were seen. Twenty-four hour urine protein excretion was 300 mg, creatinine clearance 122 ml per minute. Urine and blood cultures were negative. Renal biopsy showed mesangial widening with increase in cells and matrix. Tubular basement membrane thickening consistent with diabetes was present, but glomerular basement

*Address for reprint requests: Dr Samuel Meyers, Division of Gastroenterology, Mount Sinai School of Medicine, Annenberg 23-08, One Gustave Levy Place, New York, New York 10029, USA.

Fig. 1
Deep ulcerations on anterior tibial aspect of both lower extremities (A: right, B: left). The surrounding skin is erythematous and scaling.



membranes were normal. Electron microscopy confirmed the histological changes and demonstrated mesangial electron dense deposits. There was no evidence of renal vasculitis.

The haemoglobin was 7.14 mmol/l (11.5 g/dl). Serum iron 5.9 $\mu\text{mol/l}$ (33 $\mu\text{g/dl}$), total iron binding capacity 38 $\mu\text{mol/l}$ (240 $\mu\text{g/ml}$), direct and indirect Coombs test, reticulocyte count, and serum haptoglobin were normal. White blood cell count was normal, as were platelets. Bone marrow aspirate and biopsy showed evidence of regeneration with no neoplasia. Erythrocyte sedimentation rate was 120 mm/hour. Routine blood chemistries were normal except for mild hyperglycaemia and serum albumen of 435 $\mu\text{mol/l}$ (3 g/dl). The following special tests were negative or normal: venereal disease research laboratory test, antinuclear antibody, latex fixation, anti-streptolysin O titre, serum thyroxine, serum cortisol, anti-thyroid, and anti-parietal cell antibodies. HBsag and anti-HBsag, total serum complement as well as third and fourth complement components, prothrombin time, partial thromboplastin time, fibrinogen, serum viscosity, urine Bence-Jones protein. There were no cryopro-

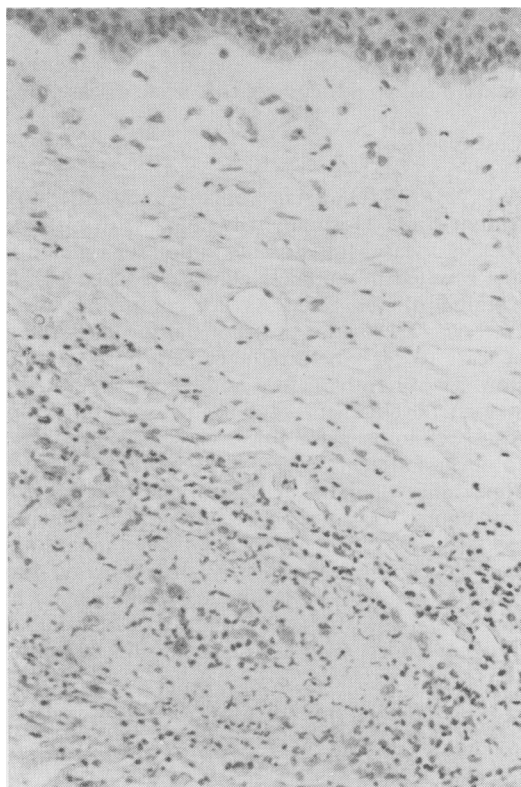


Fig. 2 *Skin biopsy with superficial and mid dermal infiltrate of neutrophils and round cells and in and around vessel walls. Fibrin is present in vessel walls and there are numerous extravasated erythrocytes. H and E, $\times 100$ (original magnification).*

teins and serum SIA test was negative. Serum protein electrophoresis showed a diffuse increase in IgA to 8.1 g/l (810 mg/dl). Urine electrophoresis was normal. Radiograph of the chest was normal.

Institution of a strict gluten free diet over a four month period resulted in complete healing of the skin lesions. Her intestinal function improved at the same time.

Discussion

Clinical, biochemical, radiographic, and biopsy material are consistent with a diagnosis of coeliac disease.^{6,7,8} A variety of dermatological changes may occur during the course of coeliac disease, including desquamation or psoriatic dermatitis, pigmentation, purpura, hair and nail abnormalities, as well as the associated specific lesion of dermatitis herpetiformis.¹ Vasculitic skin lesions have been rarely encountered. Holdstock and Oleesky² describe one case with a generalised dermatosis, biopsy of which showed a chronic inflammatory infiltrate adjacent to the basal layer of epidermis and around dermal capillaries. A more generalised vasculitis was presumed on the basis of a coexistent, unexplained seizure disorder. Booth³ briefly mentions three patients who developed a generalised erythematous rash, with extensive arteritis noted on skin biopsy. In these early reports of vasculitis^{2,3} extensive investigation was not described; the role of cryoglobulins, immune complexes, or other known causes of vasculitis cannot therefore be determined with certainty. Doe *et al.*⁴ describe four patients with mixed cryoglobulinaemia associated with cutaneous vasculitis; systemic vessels were involved in two. The cryoglobulins presumably acted as immune complexes; they had no activity against gluten fractions tested. Katz *et al.*⁵ report a patient and briefly refer to a petechial skin rash, which on biopsy was a vasculitis affecting small vessels of the dermis. There were no immunoglobulins or complement noted in the skin. Immune complexes were identified in the serum, as were antibodies to wheat fractions; no cryoproteins were present. In all cases the vasculitis occurred in the presence of severe, poorly controlled bowel disease. Several patients had pathological evidence of 'collagenous sprue', a condition particularly refractory to therapeutic intervention. Some consider that this is a specific entity,⁹ although the presence of collagen is not inconsistent with the diagnosis of coeliac disease.^{10,11}

Our patient had clinical and pathological abnormalities typical of leucocytoclastic vasculitis, with inflammatory disease confined to the skin. This vasculitis is characterised by involvement of small vessels, usually postcapillary venules. There is

infiltration of polymorphonuclear leucocytes with leucocytoclasia (nuclear debris), fibrinoid necrosis, and extravasation of erythrocytes. Although any organ may be involved, the skin is most common. The usual macroscopic appearance is palpable purpura; however, there may be urticaria, papules, nodules, vesicles, bullae, or the large ulcers seen in our patient. The lesions are at the same stage, suggesting episodic, rather than continuous, exposure to the aetiological factor.¹²

Leucocytoclastic vasculitis is, in most cases, mediated by immune complex deposition, the antigen being either exogenous or endogenous.¹³ The vasculitis may be an expression of a wide variety of distinct disorders.^{14,15} Extensive investigation failed to identify any of these associations in our case. There was exposure to a sulpha antibiotic, but the time interval between exposure to the drug and the onset of vasculitis makes this aetiology unlikely. The vascular inflammation would not be expected after removal of the precipitating antigen.¹⁴ We considered the possibility that her insulin therapy provided the offending antigen. However, change to pure pork insulin zinc suspension did not influence the clinical picture.

We speculate that the aetiology is related to the increased intestinal permeability of coeliac disease.¹⁶ As in other intestinal inflammatory disorders, exogenous antigens may permeate the damaged intestinal mucosa of coeliac disease in larger quantities than normal.¹⁷ This is reflected by significant serum antibody titres to a variety of exogenous proteins, such as milk and gluten fractions.^{18,19} Alternatively, release of endogenous antigens from damaged small bowel mucosa may occur and result in autoimmune sensitisation.²⁰ Humoral and cellular immunological activation and circulating immune complexes are well documented in coeliac disease.¹⁸⁻²² Perhaps immune complexes, originating from exogenous or endogenous antigens, are deposited in the skin, causing the leucocytoclastic vasculitis. The impaired phagocytic function of the reticuloendothelial system which occurs in coeliac disease would favour the circulation of such complexes.²³ Support for this concept is derived from the demonstration of cryoglobulins⁴ or immune complexes⁵ in the sera of a coeliac patient with vasculitis, and immune complex deposition in the skin of a patient with a lichen planus type rash.²⁴ Exogenous dietary antigens may be of prime importance, as reported cases with vasculitis occur among patients with uncontrolled coeliac disease, and, as in our case, may improve on a gluten free diet.⁵ The failure to identify endogenous intestinal brush border antigens in vasculitic lesions in sprue is also consistent with the role of dietary antigens.⁵ Auto-

immunity, however, cannot be eliminated with the meagre evidence available. All cases do not resolve on dietary control alone²⁴ and exogenous antigens have not been localised within immune complexes or vasculitic lesions.

The mesangial nephritis may be another manifestation of the coeliac disease in our case. Proteinuria, haematuria, and mesangial nephritis have been reported in dermatitis herpetiformis,^{25, 26} where bowel morphology may be identical with coeliac disease.²⁷ Moothy *et al.*²⁸ report a patient with dermatitis herpetiformis, gluten sensitive enteropathy, circulating immune complexes, and glomerulonephritis, primarily in the mesangial area. Katz *et al.*⁵ have since reported a patient with a similar immune complex glomerulonephritis and coeliac disease without dermatitis herpetiformis. The electron dense mesangial deposits seen in the renal biopsy of our case are consistent with this immune complex aetiology and may provide a link between our patient's coeliac disease, vasculitis, and renal abnormality.

Treatment of leucocytoclastic vasculitis generally has been frustrating. There is little evidence that any of the known methods of treatment, including corticosteroids, significantly alter the course of the disease.¹² Holdstock and Oleesky² noted improvement of the dermatosis in their case associated with coeliac disease, but they had at the same time instituted a gluten free diet. Dietary therapy alone has been successful⁶ and, in our patient, has allowed remarkable resolution of the vasculitic ulcers. The patient reported should remind us of the possible protean nature of the complications of coeliac disease and stress the importance of strict dietary control.

References

- ¹Jones FA. The skin: a mirror of the gut. *Geriatrics* 1973; **28**: 75–81.
- ²Holdstock DJ, Oleesky S: Vasculitis in coeliac disease. *Br Med J* 1970; **4**: 369.
- ³Booth CC. The enterocyte in coeliac disease. *Br Med J* 1970; **4**: 14–7.
- ⁴Doe WF, Evans D, Hobbs Jr, Booth CC. Coeliac disease, vasculitis and cryoglobulinemia. *Gut* 1972; **13**: 112–23.
- ⁵Katz A, Dyck RF, Bear RA. Coeliac disease associated with immune complex glomerulonephritis. *Clin Nephrol* 1979; **11**: 39–44.
- ⁶Sleisenger MH, Brandberg LL. *Malabsorption*. Philadelphia: WB Saunders, 1977: 160–74.
- ⁷Visakorpi JK. An international inquiry concerning the diagnostic criteria of coeliac disease. *Acta Paediatr Scand* 1970; **59**: 463–4.
- ⁸Meeuwisse G. Diagnostic criteria in coeliac disease. *Acta Paediatr Scand* 1970; **59**: 461–3.
- ⁹Weinstein WM, Saunders DR, Tytgat GN, Rubin CE. Collagenous sprue—an unrecognized type of malabsorption. *N Engl J Med* 1970; **283**: 1297–301.
- ¹⁰Hourihane DOB. The histology of intestinal biopsies. *Proc R Soc Med* 1963; **56**: 1073–7.
- ¹¹Shmerling DH, Shiner M. The response of the intestinal mucosa to the intraduodenal instillations of gluten in patients with coeliac disease during remission. In: Booth CC, Dowling RH, eds. *Celiac disease*. London: Churchill Livingstone, 1970: 64–75.
- ¹²Sams WM, Thorne EG, Small P, Mass MF, McIntosh RM, Stanford RE. Leukocytoclastic vasculitis. *Arch Dermatol* 1976; **112**: 219–26.
- ¹³Alarcon-Segovia D. The necrotizing vasculitides: a new pathologic clarification. *Med Clin North Am* 1977; **61**: 241–60.
- ¹⁴Fauci AS. Hypersensitivity vasculitis, pp. 664–667. In: Fauci AS, moderator. The spectrum of vasculitis. Clinical, pathologic, immunologic and therapeutic considerations. *Ann Intern Med* 1978; **89**: 660–76.
- ¹⁵Gilliam JN, Smiley JD. Cutaneous necrotizing vasculitis and related disorders. *Ann Allergy* 1976; **37**: 328–39.
- ¹⁶Menzies IS, Pounder R, Heyer S, *et al.* Abnormal intestinal permeability to sugars in villous atrophy. *Lancet* 1979; **2**: 1107–9.
- ¹⁷Wands JR, La Mont JT, Mann E, Isselbacher KJ. Arthritis associated with intestinal-bypass procedure for morbid obesity. *N Engl J Med* 1976; **294**: 121–4.
- ¹⁸Taylor KB, Thomson DL, Truelove SC, Wright R. An immunological study of coeliac disease and idiopathic steatorrhea. Serologic reactions to gluten and milk proteins. *Br J Med* 1961; **2**: 1727–31.
- ¹⁹Falchuk ZM, Stroker W. Gluten sensitive enteropathy: Synthesis of antigliadin antibody in vitro. *Gut* 1974; **15**: 947–52.
- ²⁰Scott BB, Losowsky MS. Coeliac disease: a cause of various associated diseases? *Lancet* 1975; **2**: 956–7.
- ²¹Ferguson A, McClure JP, MacDonald TT, Holden RJ. Cell-mediated immunity to gliadin within the small-intestinal mucosa in coeliac disease. *Lancet* 1975; **1**: 895–7.
- ²²Mohamed I, Holborow DJ, Fry L, Thompson BR, Hoffbrand AV, Stewart JS. Multiple immune complexes and hypocomplementemia in dermatitis herpetiformis and coeliac disease. *Lancet* 1976; **2**: 487–90.
- ²³Marsh GW, Stewart JS. Splenic function in adult coeliac disease. *Br J Haematol* 1970; **19**: 445–7.
- ²⁴Green FHY, Carty JE. Coeliac disease and autoimmunity (letter). *Lancet* 1976; **1**: 964.
- ²⁵Cotterill JA, Cunliffe WJ, Bulusu L. Proteinuria associated with skin disease. *Lancet* 1971; **2**: 403–5.
- ²⁶DeCoteau WE, Gerrard JW, Cunningham TA. Glomerulonephritis in dermatitis herpetiformis (letter). *Lancet* 1973; **2**: 679–80.
- ²⁷Scott BB, Young S, Raja SM, Marks J, Losowsky MS. Coeliac disease and dermatitis herpetiformis: further studies of their relationship. *Gut* 1976; **17**: 759–62.
- ²⁸Moothy AV, Zimmerman SW, Maxim PE. Dermatitis Herpetiformis and coeliac disease. Association with glomerulonephritis, hypocomplementemia and circulating immune complexes. *JAMA* 1978; **239**: 2019–20.