

Primary sclerosing cholangitis: a review of its clinical features, cholangiography, and hepatic histology

R W G CHAPMAN*, B Å M ARBORGH, J M RHODES†, J A SUMMERFIELD‡, R DICK, P J SCHEUER, AND SHEILA SHERLOCK

From the Departments of Medicine, Histopathology, and Radiology, Royal Free Hospital, London

SUMMARY Twenty-nine patients with primary sclerosing cholangitis were reviewed. Males predominated (2:1). Seventy-six per cent presented with cholestasis and cholangitis, 17% with cirrhosis and portal hypertension, and 7% were asymptomatic, presenting with a raised serum alkaline phosphatase. The serum immunoglobulin IgM concentration was raised in 45% of the patients, but no patient had serum mitochondrial antibody present. Seventy-two per cent had ulcerative proctocolitis. There was no relationship between either duration or severity of ulcerative proctocolitis and the development of primary sclerosing cholangitis. Four patients were not benefited by colectomy. None of the patients had Crohn's disease. The prognosis was variable. Corticosteroids and azathioprine were ineffective. Eleven patients (38%) had died with a mean survival time of seven years from diagnosis. Three patients with ulcerative proctocolitis developed bile duct carcinoma. The cholangiograms and liver biopsies were reported without reference to clinical information together with 41 patients with other biliary diseases. Cholangiography was diagnostic in 18/22 (82%). Hepatic histology was diagnostic in 8/22 (36%). Ten showed features of large bile duct disease and three were misdiagnosed as primary biliary cirrhosis. Reduced numbers of bile ducts, ductular proliferation, portal inflammation, and substantial copper deposition, in combination with piecemeal necrosis, are commonly seen in primary sclerosing cholangitis and indicate the need for cholangiography.

Primary sclerosing cholangitis (PSC), first described by Delbet¹ in 1924, is a rare disease of unknown aetiology. It is characterised by an intense inflammatory fibrosis usually affecting both the intra- and extrahepatic biliary tree.²

Reported series of patients with PSC have been small^{3,4} and until the advent of percutaneous and endoscopic cholangiography did not include detailed descriptions of the biliary tree. The present paper describes the clinical features, natural history, and treatment of 29 patients with primary sclerosing cholangitis.

Cholangiographic and hepatic histological appear-

ances have been assessed and reviewed by histopathologists and radiologists without knowledge of the diagnosis and in conjunction with 41 patients with other biliary tract diseases, also reviewed blind.

Methods

PATIENTS

Twenty-nine patients with PSC were studied. The diagnosis was established by a clinical presentation without previous biliary surgery, and by the demonstration of generalised beading and stenosis of the biliary system. Bile duct carcinoma was excluded in 18 patients by a laparotomy and bile duct biopsy. The remaining 11 patients have been followed up for at least three years (mean five years).

At presentation, liver function tests, serum immunoglobulin levels, and autoantibodies were estimated.

The control group consisted of secondary sclerosing cholangitis⁵ (five patients); primary biliary cirrhosis (10 patients); benign and malignant bile

*Address for correspondence: Dr R W G Chapman, Academic Department of Medicine, Royal Free Hospital, Hampstead, London NW3 2QG.

R W G C is Watson Smith Research Fellow of the Royal College of Physicians of London.

†JMR is supported by the Stanley T. Johnson Memorial Foundation.

‡JAS is supported by the British Medical Research Council.

Received for publication 27 May 1980

duct strictures (eight patients); cirrhosis (six patients); ulcerative proctocolitis without PSC (eight patients), and miscellaneous cholestatic liver disease (four patients).

The diagnosis of secondary sclerosing cholangitis was based on the demonstration of stricturing and dilatation of the biliary system with a history of gallstones and/or bile duct surgery.

CHOLANGIOGRAPHY

Cholangiograms from 22 patients were examined by two experienced observers who were unaware of the diagnosis. Fourteen of the 22 patients with PSC had endoscopic retrograde cholangiography, seven percutaneous transhepatic cholangiography, and one T-tube cholangiography.

The common bile duct, right and left hepatic ducts, and intrahepatic ducts were assessed for stricturing and dilatation. The intrahepatic bile ducts were also assessed for the regularity of their course and calibre. Filling of the gall bladder and the presence of gall stones were noted.

The diagnosis of PSC was based on the demonstration of multiple stricturing and dilatation of the biliary tree.^{2,4,6} Cirrhosis was suspected whenever pruning (thinning and decreased arborisation) and tortuosity of the intrahepatic bile ducts were seen.⁷ A cholangiographic diagnosis of secondary sclerosing cholangitis was reached when a predisposing cause, such as previous surgery or gallstones, could be identified.

LIVER HISTOLOGY

The 48 liver biopsies were either Menghini needle specimens (30) or operative wedge biopsies (18).

Sections were stained by standard techniques and with p-dimethylaminobenzylidene rhodanine for copper and orcein for copper-associated protein.⁸

The histology of the 22 patients in whom cholangiograms were available was reviewed independently by two experienced histopathologists without reference to the clinical information. If there was disagreement, a final diagnosis was reached after a combined review.

The material was classified as PSC, primary biliary cirrhosis (PBC), cirrhosis, or large bile duct disease. The latter diagnosis was based on the combination of portal oedema and fibrosis, duct and ductular proliferation, portal inflammation and cholestasis. A diagnosis of PSC was made on the basis of periductal fibrosis, together with the above features of biliary tract disease. Primary biliary cirrhosis was diagnosed in accordance with recognised diagnostic criteria,⁹ such as bile duct damage or loss, lymphoid follicles, ductular proliferation, and granulomas.

Table 1 Symptoms at presentation

| Symptoms | No. | % |
|------------------------------|-----|----|
| Jaundice | 21 | 72 |
| Pruritus | 20 | 69 |
| Weight loss | 23 | 79 |
| Right upper quadrant pain | 21 | 72 |
| Acute cholangitis | 13 | 45 |
| Bleeding oesophageal varices | 4 | 14 |
| Malaise | 1 | 3 |
| Asymptomatic | 2 | 7 |
| Total | 29 | |

The liver histology from all 29 patients was then reviewed to assess other diagnostic features of PSC.

Results

CLINICAL FEATURES (Table 1)

The 20 males and nine females (ratio 2:1) were aged at presentation between 10–68 years. Nineteen (66%) patients presented between the ages of 25 and 40 years and the mean age was 36 years.

The majority of patients presented with weight loss, pain in the right upper quadrant, pruritus and acute cholangitis, characterised by intermittent fever, rigors, and jaundice.

Five (17%) presented with cirrhosis and portal

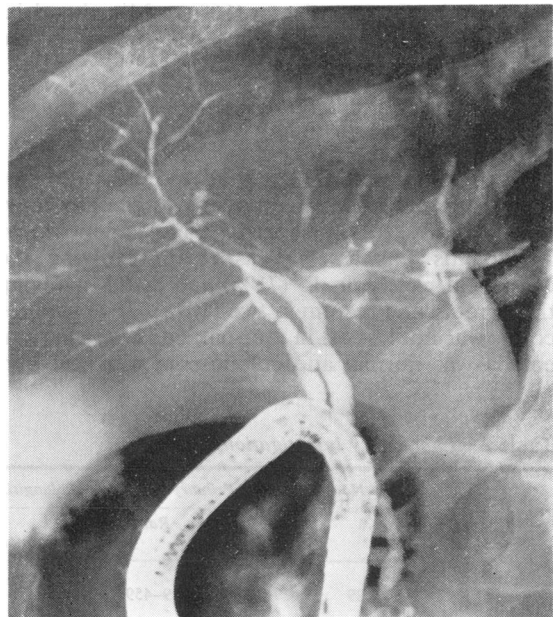


Fig. 1 Endoscopic retrograde cholangiogram of an asymptomatic patient showing beading and strictures of extra- and intrahepatic bile ducts: characteristic appearance of primary sclerosing cholangitis.

hypertension; four of these had bled from oesophageal varices, and one had malaise and hepatosplenomegaly. None of these five patients had had cholestasis or cholangitis, three had been treated as cryptogenic cirrhosis for two, six and seven years before the diagnosis of PSC was established. Two patients were asymptomatic and were diagnosed by persistently raised serum alkaline phosphatase levels (Fig. 1). Seventeen (59%) developed persistent hyperbilirubinaemia, but three (10%) had never been jaundiced.

LABORATORY INVESTIGATIONS (Table 2)

The liver function tests were usually cholestatic. Serum alkaline phosphatase level was more than three times normal in 22/29 (76%) (Fig. 2). A peripheral blood eosinophilia of more than $0.4 \times 10^9/l$ circulating eosinophils was observed in only two patients.

Increased serum IgM concentration was seen in 45% of 20 patients tested (Fig. 2). IgA concentration was raised in two patients (10%) and the serum IgG in five (25%).

Serum autoantibodies were measured in 25 patients. Eight patients (32%) had titres of antinuclear factor of less than 1 in 60. The DNA binding was normal and LE cells were not found. Serum smooth muscle antibody up to a titre of 1 in 40 was detected in four patients (16%). Mitochondrial antibody was not detected. All patients were hepatitis B surface antigen negative.

RELATIONSHIPS BETWEEN ULCERATIVE PROCTOCOLITIS AND PSC

Twenty-one patients (72%) had ulcerative proctocolitis, the diagnosis was made by sigmoidoscopy, rectal biopsy, barium enema, and colonoscopy. The colitis was assessed as total, involving the colon and rectum in 15 (71%) and distal involving the sigmoid and rectum in two (10%). The extent of colitis was not known in four patients as the barium enema was normal and colonoscopy was not per-

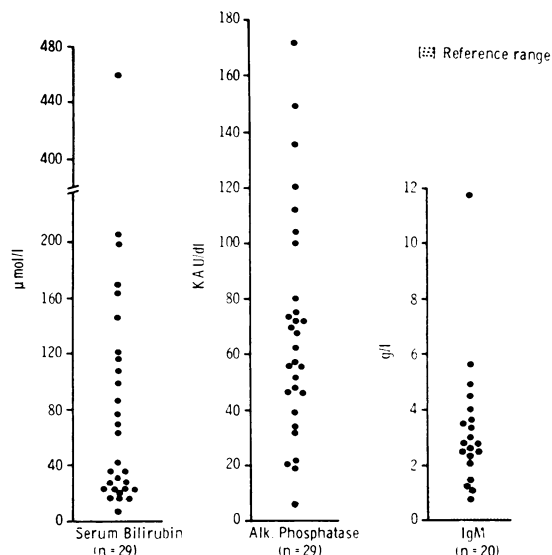


Fig. 2 Serum bilirubin, alkaline phosphatase, and IgM levels at presentation.

formed. Inflammatory bowel disease was excluded as far as possible in the other eight patients by a normal barium enema and rectal biopsy.

The course of the colitis was generally mild with prolonged remissions. Seven had never complained of rectal bleeding and only suffered from episodic diarrhoea. Ulcerative proctocolitis usually developed before PSC (mean of eight years—range three months to 31 years). However, in four patients the PSC appeared to precede the onset of ulcerative proctocolitis by one to three years, and in another seven patients the diagnosis of PSC was made within four years of the first symptom of colitis.

There was no relationship between the exacerbation of acute colitis and acute ascending cholangitis. The outcome of PSC seemed unrelated to the severity and clinical course of the colitis. Despite the high prevalence of total proctocolitis (71%) only four patients had had a colectomy performed. In two of the four the first symptom of PSC appeared two years after colectomy and in the other two patients, colectomy did not result in any clinical or biochemical improvement.

One patient also suffered from ankylosing spondylitis (HLA type B27 positive). Other medical conditions occurring were thyrotoxicosis (two patients), vitiligo, renal tubular acidosis, and rheumatoid arthritis (one patient each). Riedel's thyroiditis without retroperitoneal fibrosis was confirmed at necropsy in one patient without colitis.

No patients in the series had Crohn's disease.

Table 2 Laboratory investigations

| | No. | Normal range | Primary sclerosing cholangitis | | |
|---------------------------------|-----|--------------|--------------------------------|----------|------------|
| | | | Mean | Range | % Abnormal |
| Bilirubin ($\mu\text{mol/l}$) | 29 | 0-17 | 84 | 9-459 | 83 |
| Alkaline phosphatase (KAU/l) | 29 | 3-13 | 69 | 6-172 | 97 |
| Amino transferase (IU/l) | 29 | 4-15 | 62 | 19-226 | 97 |
| Albumin (g/l) | 28 | 35-50 | 39 | 25-47 | 29 |
| IgM (g/l) | 20 | 0.7-2.8 | 3.28 | 0.8-11.7 | 45 |

LENGTH OF ILLNESS AND CAUSE OF DEATH

Eleven patients (38%) have died between six months and 15 years (mean seven years) from the onset of symptoms. Eight patients died in hepatic failure which followed deepening obstructive jaundice in seven. Necropsy in one patient revealed a microscopic adenocarcinoma of the right hepatic duct and widespread changes of sclerosing cholangitis. Two other patients developed well-differentiated bile duct adenocarcinomas after eight and 11 years and died of carcinomatosis. One patient with total ulcerative proctocolitis died from carcinoma of the colon. Ten of the 11 patients who had died had ulcerative proctocolitis.

Eleven of the surviving 18 patients (61%) have had recurrent acute cholangitis; three (17%) have had recurrent bleeding from oesophageal varices; and four (22%) have been symptom-free for a mean of four years (range two to eight years). The 18 surviving patients have lived a mean of five (range two to 13 years).

RESPONSE TO TREATMENT

Twenty-two patients had received courses of corticosteroids lasting between six weeks and 12 years. Six patients had symptomatic improvement of pruritus, three of whom showed slight improvement in liver function tests.

No symptomatic or biochemical improvement was seen in the two patients who received 2 mg/kg azathioprine for four and 10 months respectively.

Nineteen patients had had a laparotomy. T-tube drainage of the common bile duct had been performed in 12; five had had choledochenteric bypass, and two portocaval shunts.

CHOLANGIOGRAPHIC REVIEW

Review of a mixed group of 64 patients resulted in correct identification of 18 of 22 patients (82%) with PSC. In three of the four patients who were not recognised, the intrahepatic ducts were inadequately filled and one was classified as secondary sclerosing cholangitis. One patient with primary biliary cirrhosis was wrongly diagnosed as PSC.

Strictures of the extrahepatic biliary tree were present in 20/22 patients (91%). The calibre of the intrahepatic ducts was irregular in all 20 patients in whom the intrahepatic ducts were opacified. Six patients with PSC also had the radiological appearance of cirrhosis, in five confirmed by liver biopsy.

Three patients had no abnormalities of the intrahepatic bile ducts, but multiple strictures of the extrahepatic biliary tree.

The appearances of secondary sclerosing cholangitis were identical with those of PSC.

Three of the eight patients with ulcerative procto-

Table 3 *Histological findings in primary sclerosing cholangitis (n=29)*

| | - | + | ++ |
|-----------------------------|----|----|----|
| Portal changes | | | |
| Inflammation | 0 | 17 | 12 |
| Bile duct diminution | 12 | 10 | 7 |
| Periductal fibrosis | 18 | 9 | 2 |
| Bile ductular proliferation | 4 | 7 | 18 |
| Lobular changes | | | |
| Piecemeal necrosis | 10 | 8 | 11 |
| Focal necrosis | 11 | 18 | 0 |
| Focal inflammation | 12 | 17 | 0 |
| Kupffer cell hyperplasia | 5 | 11 | 13 |

colitis without PSC had the radiological appearance of cirrhosis, one had a malignant bile duct stricture, and four had normal retrograde cholangiograms despite a liver biopsy suggestive of biliary disease.

LIVER BIOPSY REVIEW

Liver biopsies from the same mixed group of 64 patients were reviewed using the diagnostic criteria described previously. A diagnosis of sclerosing cholangitis was correctly made in 8/22 (36%) patients with PSC; in three the findings were suggestive of PBC (14%), while 10 patients were reported as having large bile duct disease. Inactive cirrhosis of unknown cause was reported in one patient (4%). Cirrhosis additional to biliary disease was seen in 7/22 patients (32%). Four of five patients with secondary sclerosing cholangitis were reported as having large bile duct disease (80%), while the diagnosis of sclerosing cholangitis was made in one (20%).

Of the eight patients with ulcerative proctocolitis in the control group who did not have cholangiographic abnormalities suggestive of PBC, one was diagnosed as sclerosing cholangitis, one as PBC, and six were reported as having non-specific biliary disease. Sclerosing cholangitis was not diagnosed histologically in any of the other patients in the original mixed group of 64 patients. All 10 patients with PBC were correctly identified.

As the diagnostic accuracy was low using conventional criteria, the liver histology from all 29 patients with PSC was then further reviewed (Tables 3 and 4) so that specific diagnostic features could be identified. In every biopsy an inflammatory reaction in the portal tracts was seen (Fig. 3). The inflammatory infiltrate was composed of lymphocytes,

Table 4 *Pigment deposition in primary sclerosing cholangitis*

| | n | - | + | ++ | +++ |
|----------------|----|----|---|----|-----|
| Bile pigment | 29 | 17 | 1 | 10 | 1 |
| Copper pigment | 26 | 5 | 1 | 8 | 12 |

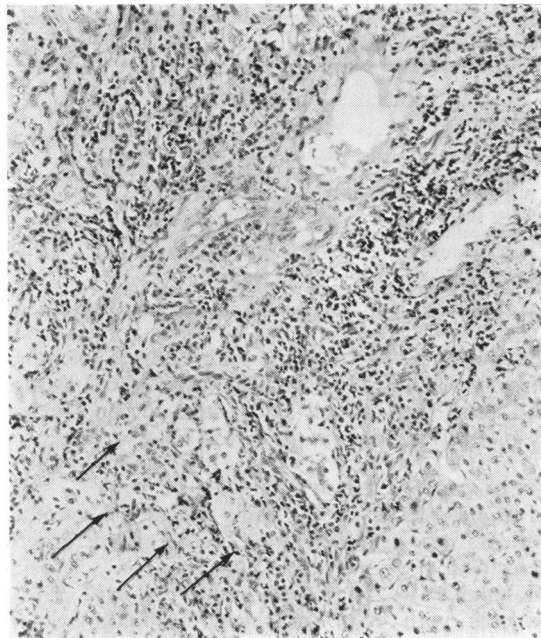


Fig. 3 Expanded portal tract with pronounced mononuclear inflammation and absent bile ducts. There is moderate piecemeal necrosis (arrows). H and E, $\times 150$. (Original magnifications cited in all Figures.)

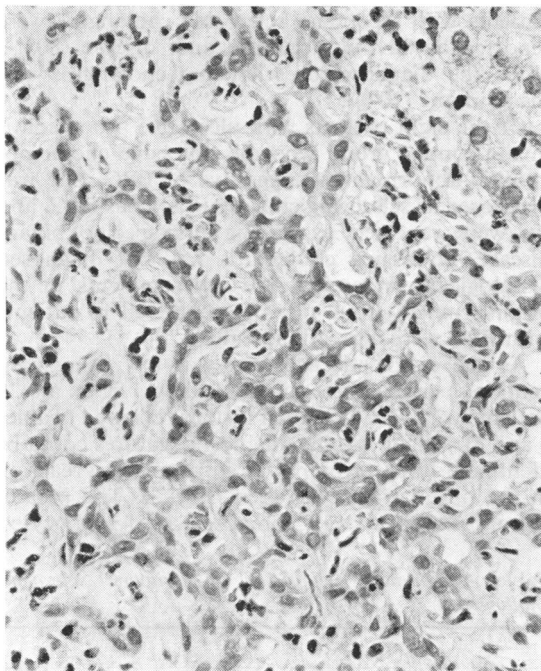


Fig. 4 Area of bile ductular proliferation with mixed inflammatory infiltration. H and E, $\times 360$.

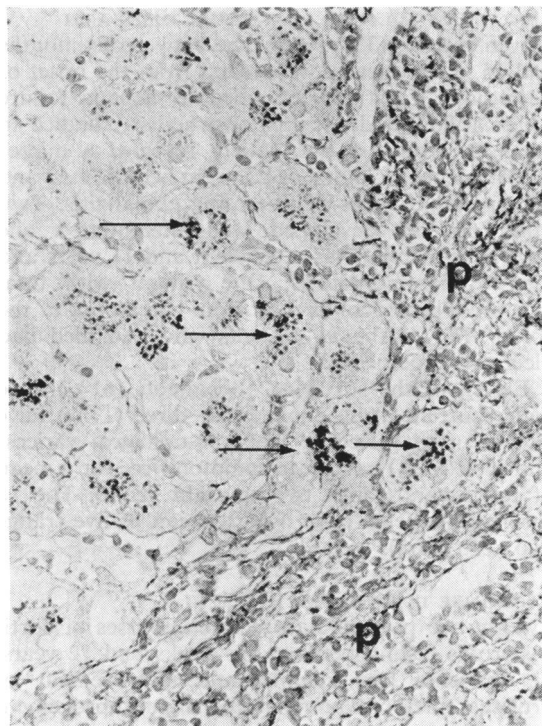


Fig. 5 Copper-associated protein present as dark granules in periportal liver parenchymal cells (arrows). P, portal tract. Orcein, $\times 360$.

plasma cells and histiocytes, and polymorphonuclear leucocytes in association with proliferating bile ductules. Lymphoid aggregates were observed in 11 patients (30%) and granulomas were seen in three patients (10%).

The number of interlobular bile ducts in relation to the number of small arteries was normal (1:12) in 12 patients (41%) and reduced in 10 (34%) (1:5-10). In the remaining seven patients (24%) no bile ducts were seen (Fig. 3). Morphological changes in the bile ducts were observed in eight patients (28%). These consisted of flattened epithelial cells, vacuolation of epithelial cells, and inflammatory infiltration of the bile duct wall. Periductal fibrosis was seen in 11 patients (38%). Bile ductular proliferation was found in the majority of patients (86%) and was frequently (76%) associated with polymorphonuclear leucocytes (Fig. 4).

In the periportal areas piecemeal necrosis was noted in 19 patients (66%) (Fig. 3). This was of moderate severity in 11 (38%); however, bridging hepatic necrosis was not observed. There was no correlation with serum autoantibodies.

Intralobular changes were frequently seen; Kupffer

cell hyperplasia in 24 patients (83%); mild focal inflammation in 18 (62%), and mild focal necrosis in 19 patients (66%). The lobular architecture was normal in 11 patients (38%) and disturbed by fibrous septa in nine patients (31%). Cirrhosis had developed in nine patients (31%).

Cholestasis was seen in 12 patients (41%), accompanied by accumulation of copper and copper-associated protein. Copper pigment and copper-associated protein were present in substantial amounts in 20/26 patients (77%) (Fig. 5); in 11 of these there was no morphological evidence of cholestasis.

Discussion

The male predominance in our patients has been shown previously⁴ but does not reflect the sex incidence of ulcerative proctocolitis which has a slight female predominance.¹⁰

The majority of patients, as in previous series, presented between the ages of 25 and 45 years.^{4,5,11} However, the range was wide, and the youngest patient was a girl aged 10 years.

It is widely believed that PSC always presents with cholangitis and cholestasis.¹² However, while the majority of our patients did present in this way, 17% had never been jaundiced and presented with either cirrhosis and portal hypertension or were asymptomatic, although all had a raised serum alkaline phosphatase. Three patients had been diagnosed as 'cryptogenic' cirrhosis for some years before cholangiography was performed and this study has shown for the first time that a number of patients with 'cryptogenic cirrhosis' may have cirrhosis secondary to PSC. We believe that cholangiography is indicated in patients with 'cryptogenic cirrhosis' in whom the serum alkaline phosphatase is persistently raised.

Asymptomatic PSC has not previously been recognised. The early diagnosis of PSC in these patients may be explained by the advent of endoscopic retrograde and chiba needle cholangiography, as in the past laparotomy was needed to confirm the diagnosis.

Although serum immunoglobulins in PSC have been reported to be normal,⁵ in this study a raised immunoglobulin IgM was found. The levels of IgM observed were greater than those found in long-standing bile duct obstruction,¹³ but correspond more closely to those observed in primary biliary cirrhosis.¹³ The presence in the serum of antinuclear factor and smooth muscle antibody found in this study has not been previously observed. However, the antibody titres were low and have no diagnostic

significance, as low titres of these autoantibodies are known to result from any parenchymal liver damage.¹⁴

PSC is closely associated with ulcerative proctocolitis, and, in this study, ulcerative proctocolitis was found in 72% of our patients, more than previously reported.^{4,5} The higher prevalence of ulcerative proctocolitis in our series may reflect both an increasing awareness of this association and improved cholangiographic techniques.

Although total involvement of the colon and rectum was frequently observed, the colitis was usually symptomatically mild, often with no rectal bleeding. These findings were in contrast with the observation of Warren *et al*⁴ that the ulcerative proctocolitis was moderately severe.

The aetiology of PSC is unknown. It has been suggested that it may be related in ulcerative proctocolitis to a chronic low-grade infection of the biliary tree spreading via the portal circulation from the diseased colon.^{4,5,12} This appears unlikely, as in our patients PSC could be diagnosed before the ulcerative proctocolitis and did not improve either after remission of colitis or after colectomy. The association with other diseases such as Riedel's struma¹⁵ and retroperitoneal fibrosis also needs to be explained.

None of these patients in this large study had Crohn's disease. Only two cases of the association of PSC and Crohn's have been reported^{16,17} and the association remains to be confirmed.

Corticosteroids have not been beneficial but assessment of treatment in this rare disease is difficult because survival is variable and some patients remain asymptomatic for long periods. In view of the hazards of corticosteroids accentuating osteoporosis in patients with cholestasis, these drugs should probably be avoided in PSC.

An increased frequency of bile duct carcinoma is recognised in patients with ulcerative proctocolitis without PSC.¹⁸ This study has shown that adenocarcinoma of the bile ducts may develop in patients with long-standing PSC and ulcerative proctocolitis.

We have confirmed that the majority of patients with PSC show the characteristic cholangiographic pattern of PSC, stricturing and beading of the intra- and extrahepatic bile ducts.^{4,6} Occasionally the cholangitis is confined to the intrahepatic ducts as described by Bhathal and Powell.¹⁹ The intrahepatic cholangiographic appearances of PSC are diagnostic and we have shown that they can usually be distinguished from those of cirrhosis even when both are present.

The study has confirmed the value of endoscopic retrograde cholangiography in the diagnosis and management of PSC,²⁰⁻²² but has also shown that,

contrary to previous reports,^{5,12} percutaneous trans-hepatic cholangiography can be used successfully in this disease, if the 'skinny' needle technique is employed.

We feel that laparotomy should not be performed routinely to confirm the diagnosis of PSC but should be reserved for the minority of patients with complete obstruction of the main bile duct to exclude bile duct carcinoma. Surgery may be also required to relieve bile duct obstruction and to remove biliary sludge and stones above strictures.

Hepatic histology is not usually diagnostic in PSC using standard criteria, although some form of biliary disease can usually be identified, indicating the need for cholangiography.

In view of the low diagnostic accuracy, an additional more detailed histological study was performed. Two-thirds of the patients showed piecemeal necrosis suggesting a possible diagnosis of chronic active hepatitis. This lesion is usually defined in terms of chronic inflammation, fibrosis, and piecemeal necrosis. However, piecemeal necrosis is also found in other conditions, including PBC. In our patients it was not thought to indicate concurrent chronic active hepatitis, as there was no relationship between serum autoantibodies and piecemeal necrosis, the titres of smooth muscle antibody were low or absent, and immunoglobulin IgG was not raised. We believe that in our patients the necrosis represented one of the many different histological features of PSC.

The majority of patients showed marked diminution of small bile ducts in the portal tracts, placing PSC, like PBC, in the group of diseases characterised by bile duct destruction. However, periductal fibrosis, a characteristic lesion of the bile ducts in PSC,⁸ is not a constant feature and was seen in only one-third of our patients.

Accumulation of copper and copper-associated protein are features of any chronic cholestasis. However, the degree and frequency of copper accumulation were striking and similar to those found in late stage PBC.^{23,24} Increased copper and copper-associated protein were seen in the absence of bile pigment deposition and may provide the only histological evidence of underlying biliary disease.

The relationship between PSC and 'pericholangitis' is not clear. Many of the present liver biopsies could, on histological grounds, be classified as 'pericholangitis'.²⁵ Cholangiography was not performed on the patients originally described²⁶ and we feel that it is doubtful whether 'pericholangitis' exists as a separate clinical entity from PSC. A recent report has shown that six out of eight patients with 'pericholangitis' and ulcerative proctocolitis had abnormalities of the bile ducts on ERCP.²⁷ We

believe that cholangiography should be performed in patients with ulcerative proctocolitis and persistently abnormal liver function tests in order to exclude PSC.

It is apparent from this and other studies,²⁸ that PSC may be confused with PBC. The clinical and histological features can be similar and the serum IgM may be high in both diseases. However, in our patients with PSC, the serum mitochondrial antibody was always negative. We feel that cholangiography should be carried out in patients with suspected PBC and a negative mitochondrial antibody.

This study has shown that cholangiography is effective in the diagnosis of PSC and we believe that laparotomy should be reserved for patients with complete obstruction of the main bile duct.

We have also shown that the clinical presentation and prognosis of PSC is more variable than previously recognised. PSC should be considered in patients with ulcerative proctocolitis and abnormal liver function tests, irrespective of symptoms; 'cryptogenic' cirrhosis with a high serum alkaline phosphatase; and mitochondrial antibody negative 'primary biliary cirrhosis'.

References

- ¹Delbet P. Retrecissement du choledoque: cholecysto-duodenostomie. *Bull Mem Soc Nat Chir* 1924; 1144.
- ²Thorpe MEC, Scheuer PJ, Sherlock S. Primary sclerosing cholangitis, the biliary tree and ulcerative colitis. *Gut* 1967; **8**: 435-48.
- ³Smith MP, Loe RH. Sclerosing cholangitis. *Am J Surg* 1965; **110**: 239-46.
- ⁴Warren KW, Athanassiades S, Monge JJ. Primary sclerosing cholangitis. *Am J Surg* 1966; **111**: 23-38.
- ⁵Danzi JT, Makipour H, Farmer RG. Primary sclerosing cholangitis. *Am J Gastroenterol* 1976; **65**: 109-16.
- ⁶Krieger J, Seaman WB, Porter MR. The roentgenologic appearance of sclerosing cholangitis. *Radiology* 1970; **95**: 369-75.
- ⁷Summerfield JA, Elias E, Hungerford GD, *et al.* The biliary system in primary biliary cirrhosis. *Gastroenterology* 1976; **70**: 240-3.
- ⁸Scheuer PJ. *Liver biopsy interpretation*. London: Bailliere Tindall, 1980: 12.
- ⁹Sherlock S, Scheuer PJ. The presentation and diagnosis of 100 patients with primary biliary cirrhosis. *N Engl J Med* 1973; **289**: 674-8.
- ¹⁰Edwards FC, Truelove SC. The course and prognosis of ulcerative colitis. Part 1. *Gut* 1963; **4**: 299-308.
- ¹¹Thompson BW, Read RC. Sclerosing cholangitis and other intra-abdominal fibroses. *Am J Surg* 1974; **128**: 777-81.
- ¹²Anonymous. An unusual cholangitis. *Br Med J* 1976; **2**: 1090-1.
- ¹³Feizi T. Immunoglobulins in chronic liver disease. *Gut* 1968; **9**: 193-8.

- ¹⁴Holborrow EJ. Immunological aspects of viral hepatitis. *Br Med Bull* 1972; **28**: 142-4.
- ¹⁵Bartholomew LG, Cain JC, Woolner LB, Utz DC, Ferris DO. Sclerosing cholangitis. *N Engl J Med* 1963; **269**: 8-12.
- ¹⁶Atkinson AJ, Carroll WW. Sclerosing cholangitis—association with regional enteritis. *JAMA* 1964; **188**: 183-4.
- ¹⁷Dew MJ, Thompson H, Allan RN. The spectrum of hepatic dysfunction in inflammatory bowel disease. *Q J Med* 1979; **48**: 113-35.
- ¹⁸Ritchie JK, Allan RN, Macartney J, Thompson H, Hawley PR, Cooke WT. Biliary tract carcinoma associated with ulcerative colitis. *Q J Med* 1974; **43**: 263-79.
- ¹⁹Bhathal PS, Powell LW. Primary intrahepatic obliterating cholangitis, a possible variant of 'sclerosing cholangitis'. *Gut* 1969; **10**: 886-93.
- ²⁰Elias E, Summerfield JA, Dick R, Sherlock S. Endoscopic retrograde cholangiopancreatography in the diagnosis of jaundice associated with ulcerative colitis. *Gastroenterology* 1974; **67**: 907-11.
- ²¹Lefton HB, Winkelman EI. Endoscopic retrograde cholangiographic evaluation of sclerosing cholangitis. *Cleve Clin Q* 1974; **41**: 143-7.
- ²²Abbruzzese AA. Retrograde cholangiography and sclerosing cholangitis. *Am J Dig Dis* 1974; **19**: 571-4.
- ²³Ritland S, Steinnes E. Copper and liver disease. *Scand J Gastroenterol* 1975; **10**: suppl 34, 41-2.
- ²⁴Ritland S, Steinnes E, Skrede S. Hepatic copper content, urinary copper excretion and serum ceruloplasmin in liver disease. *Scand J Gastroenterol* 1977; **12**: 81-8.
- ²⁵Mistilis SP. Pericholangitis and ulcerative colitis: I Pathology, etiology and pathogenesis. *Ann Intern Med* 1965; **63**: 1-16.
- ²⁶Mistilis SP, Skyring AP, Goulston SJM. Pericholangitis and ulcerative colitis: II Clinical aspects. *Ann Intern Med* 1965; **63**: 17-26.
- ²⁷Blackstone MO, Nemchausky BA. Cholangiographic abnormalities in ulcerative colitis associated pericholangitis which resemble sclerosing cholangitis. *Am J Dig Dis* 1978; **23**: 579-85.
- ²⁸Roseau E. La cholangéite sclérosante primitive. *Nouv Presse Med* 1978; **28**: 2465-7.