

Case reports

Entamoeba histolytica infection in male homosexuals

W R BURNHAM, R S REEVE, AND R G FINCH*

From the Departments of Therapeutics, Pathology and Microbial Diseases, The City Hospital, Nottingham

SUMMARY Amoebic infection in two male homosexuals is described. The possibility that this infection was acquired through homosexual practices and the implications to clinical and diagnostic services is discussed.

Amoebiasis is an uncommon disease in Britain. An estimated 200 new cases of amoebiasis occur annually in England and Wales.¹ The disease may be fatal if misdiagnosed or inappropriately treated.² Most infections are acquired in an endemic area, although occasionally infection has been reported in persons who have never been abroad.³ More recently, several reports from the United States, and from New York in particular, have suggested that protozoal bowel infections including *E. histolytica* are common among the sexually active homosexual population.⁴⁻⁸ We report two cases of amoebic infection occurring in homosexual males which were probably sexually acquired in England.

Case reports

CASE 1

A 22 year old homosexual male was referred from the Clinic for Sexually Transmitted Diseases (STD) with an eight week history of frequent, bloody diarrhoea and colicky lower abdominal pain. He had not lost weight and constitutional upset was absent. He had not been abroad since a trip to Spain eight years before. There was no past medical history of note.

Examination revealed tenderness in the right iliac fossa. Sigmoidoscopy showed the changes of an acute colitis with numerous aphthoid ulcers localised to the anterior wall of the lower 8 cm of the rectum. A rectal biopsy was taken.

*Address for correspondence and reprint requests: Dr Roger Finch, Department of Microbial Diseases, The City Hospital, Nottingham NG5 1PB.

Investigations at the STD Clinic had shown no evidence of venereal infection. The blood count, ESR, urinalysis, liver function tests, and serum albumin were normal. HBsAg was not detected in his serum. At first, stool examination in the laboratory showed no abnormality. However, the rectal biopsy showed active inflammation with haemato-phagic amoebae present (Figure). Subsequent stool examination showed actively motile trophozoites and cysts of *Entamoeba histolytica*. The amoebic fluorescent antibody test was positive at a titre of 128.

A diagnosis of amoebic dysentery was made and treatment started with oral metronidazole 800 mg thrice daily. After seven days' treatment his symptoms had disappeared and sigmoidoscopy and rectal biopsy were both normal. On subsequent enquiry he admitted to oral/anal contact with his partner (case 2).

CASE 2

This was a 27 year old male homosexual who cohabited with case 1. He was on treatment with cimetidine for a radiologically proven duodenal ulcer. When seen, he was asymptomatic and had no recent history of diarrhoea. He had never suffered from rectal bleeding or been abroad.

The results of examination, including sigmoidoscopy, were normal. Microscopy of warm stools showed *E. histolytica* cysts in the third specimen. His serum was negative for HBsAg but the amoebic fluorescent antibody test was positive at a titre of 256. Treatment with metronidazole 800 mg thrice daily for seven days was prescribed.

This patient also admitted to anilingus. Both patients denied sexual contact with other homosexuals.

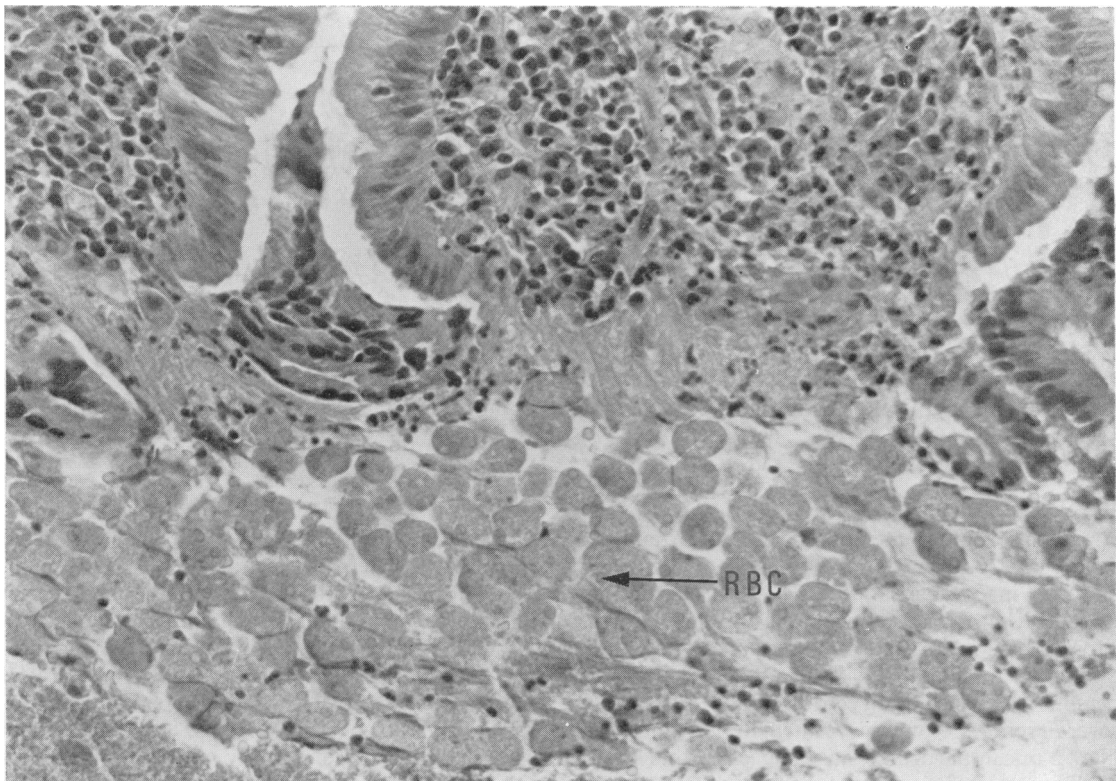


Figure Case 1. Haematoxylin and eosin stained section of the rectal biopsy showing inflammation, mucosal ulceration, and many amoebae containing phagocytosed erythrocytes (RBC). Original magnification $\times 385$.

Discussion

Although it cannot be proven that these patients acquired their infection sexually, it seems likely. Neither had been abroad recently, both admitted anilingus, and the disease is uncommon in Britain. Recent reports from New York and San Francisco indicate that amoebic and *Giardia lamblia* infections are common among sexually active homosexuals.⁴⁻⁸ Of a selected group of 126 homosexual males 31.7% were infected with *E. histolytica*.⁵

If this is found to the same extent in Britain, it will have profound implications. Homosexuals form a substantial proportion of the patients attending STD clinics. Should all these patients be screened, it would be a burden to the microbiological services. Considerable expertise is necessary for the recognition of *E. histolytica* cysts and trophozoites in the stool,³ and serological tests are available only at reference centres. It is apparent that more research is needed to assess the importance of these findings before any definite recommendation can be made with regard to current diagnostic arrangements.

Homosexual patients presenting to gastroenterology clinics with diarrhoea could be misdiagnosed as having inflammatory bowel disease. The use of corticosteroids in such patients can result in fulminant amoebic infection.² Repeated stool examination may be necessary before the diagnosis is confirmed, as in case 1. It is recommended therefore that the diagnosis of amoebiasis be considered in patients with diarrhoea and abdominal pain who are homosexuals. Examination of stool and serum specimens is advisable before starting treatment with corticosteroids for suspected inflammatory bowel disease. If urgent treatment is essential, metronidazole might be given simultaneously.

Finally, the fact that case 2 was taking cimetidine at the time of diagnosis, a drug which is known to reduce gastric acidity and alter the gastrointestinal microbial flora,⁹ is of interest and provokes speculation as to the possible contributory role it may have played in this patient's infection.

The authors wish to thank Dr A L Jeanes, Guy's Hospital Medical School, London, for assistance

with the amoebic serological tests, Professor M J S Langman, and Professor John Hampton for permission to report details of patients under their care, and also Professor Langman for advice and encouragement.

References

- ¹Stamm WP. Amoebiasis in England and Wales. *Br Med J* 1975; **1**: 452-3.
- ²Leading article. Misdiagnosis of amoebiasis. *Br Med J* 1978; **2**: 379-80.
- ³Public Health Laboratory Service. Serologically diagnosed cases of amoebiasis. *B Med J* 1973; **2**: 746-7.
- ⁴Sohn N, Robilotti JG. The gay bowel syndrome. A review of colonic and rectal conditions in 200 male homosexuals. *Am J Gastroenterol* 1977; **67**: 478-84.
- ⁵Kean JH, Williams DC, Luminais SK. Epidemic of amoebiasis and giardiasis in a biased population. *Br J Vener Dis* 1979; **55**: 375-8.
- ⁶Schmerin MJ, Gelston A, Jones TC. Amebiasis. An increasing problem among homosexuals in New York City. *JAMA* 1977; **238**: 1386-7.
- ⁷Mildvan D, Gelb AM, William D. Venereal transmission of enteric pathogens in male homosexuals. Two case reports. *JAMA* 1977; **238**: 1387-9.
- ⁸Hurwitz AL, Owen RL. Venereal transmission of intestinal parasites. *West J Med* 1978; **128**: 89-91.
- ⁹Ruddell WSJ, Axon ATR, Findlay JM, Bartholomew BA, Hill MJ. Effect of cimetidine on the gastric bacterial flora. *Lancet* 1980; **1**: 672-4.