

# Rectal biopsy in patients presenting to an infectious disease unit with diarrhoeal disease

R. J. DICKINSON, H. M. GILMOUR, AND D. B. L. McCLELLAND<sup>1</sup>

*From the Department of Infectious Diseases, City Hospital, Edinburgh, and the Departments of Pathology and Therapeutics, University of Edinburgh, Edinburgh*

**SUMMARY** The role of sigmoidoscopy and rectal biopsy was investigated in patients referred to an infectious diseases unit with diarrhoea. Seventy-four patients were studied. Nine patients (12%) had inflammatory bowel disease, either ulcerative colitis or Crohn's disease. Thirty-six patients (48%) had infective diarrhoea. A wide variety of conditions accounted for the diarrhoea in the remaining patients. Sigmoidoscopy was abnormal in 25 patients and rectal biopsy in 56. The abnormalities in rectal mucosal histology were classified into six grades. Some patients with infective diarrhoea showed rather characteristic histological changes which may be of diagnostic value. Eight showed features which suggested a diagnosis of inflammatory bowel disease. However, repeat rectal biopsy in the convalescent period showed a striking improvement in the patients with infective diarrhoea. In contrast, the histological changes persisted in the patients with inflammatory bowel disease. Repeat rectal biopsy may be essential before making a firm diagnosis of inflammatory bowel disease in some patients who present with diarrhoea and apparently typical histological changes.

Sigmoidoscopy with rectal biopsy is usually performed in patients referred to gastroenterologists because of diarrhoeal disease and there is a wide experience of the range and significance of the histological abnormalities found in this patient population. Patients who are referred to an infectious diseases unit with diarrhoea may represent a rather different clinical group and there are few published reports about the nature and significance of the sigmoidoscopic and rectal biopsy findings in this group. In this report we describe the results of sigmoidoscopy and rectal biopsy performed on adult patients with diarrhoea who were referred to an infectious disease unit. The aims of this study were, firstly, to attempt to classify the histological abnormalities found in these patients, and, secondly, to attempt to correlate the histological and clinical features. The third aim was to determine the extent to which information obtained from sigmoidoscopy and biopsy performed as a routine might influence the diagnosis or management of patients with diarrhoea who are referred to this type of unit.

## Methods

All patients referred to the Infectious Disease Unit of the City Hospital, Edinburgh, with the principal complaint of diarrhoea (defined as three or more loose stools per day for at least 24 hours) during a 15 month period up to December 1976 were included in this study providing that they agreed to participate, were aged under 75 years, and had no contraindication to the investigation. All but 21 patients referred during the study period are included in this report. This study was approved by the Ethical Committee of the South Lothian District Division of Medicine.

Three stool cultures for *Salmonella* and *Shigella* were carried out on all patients. No attempt was made to identify enteropathogenic *E. coli* or gastroenteritis-related viruses.

Sigmoidoscopy was performed within three days of admission and all the examinations were done by one of the authors (R.J.D.). The presence or absence of oedema, visible vascular pattern, and of contact bleeding with or without ulceration were noted (Watts, *et al.*, 1966). The appearances were graded as normal or abnormal but no attempt was made to record the degree of abnormality. Biopsies were taken with Chevalier-Jackson forceps at approxi-

<sup>1</sup>Address for reprints: Dr D. B. L. McClelland, University Department of Therapeutics, Royal Infirmary, Edinburgh EH3 9YW.

mately 8 cm from the anal margin and fixed in formal saline. The sigmoidoscope was washed in water and disinfected and autoclaved before re-use. After routine processing and embedding in paraffin, sections were cut and stained with haematoxylin and eosin. All the biopsies were examined by one of us (H.M.G.) without knowledge of the clinical history or the results of other investigations. The pathologist's description of the biopsy and the provisional histological diagnosis were made available to the clinicians immediately.

Patients were assigned to the diagnostic groups on the basis of their clinical history, physical findings, and the results of all initial investigations including the results of the first sigmoidoscopy and rectal biopsy.

## Results

### DIAGNOSTIC CLASSIFICATION OF PATIENTS

The patients were assigned to the diagnostic categories shown in Table 1. Nine patients were classified as having chronic inflammatory bowel disease (Crohn's disease or ulcerative colitis). Eight of these were previously undiagnosed. Seven had the typical macroscopic and microscopic rectal mucosal changes of active ulcerative colitis and two had the typical histological changes of Crohn's disease including granuloma formation. All nine patients satisfied recognised criteria for inflammatory bowel disease (Lennard-Jones *et al.*, 1976).

Table 1 *Diagnosis, duration of diarrhoea at presentation, nature of stools, and sigmoidoscopy and biopsy*

Diagnosis	Patients (no.)	Mean duration of diarrhoea (days)	Mean stool frequency at presentation (day)	Blood in stool (no.)	Ab-normal sigmoidoscopy (no.)	Ab-normal rectal biopsy (no.)
Infective	36	4.5	14	14	12	32
Travellers	4	64	6	0	0	3
IBD	9	26	10	8	7	9
Unclassified	5	25	5	2	3	5
Antimicrobial drugs	7	10	17	1	3	4
Other drugs	2	10	12	0	0	1
Coeliac	2	38	6	0	0	0
Carcinoma	2	30	15	0	0	0
Irritable bowel	7	22	7	0	0	2

Thirty-six patients were considered to have infective diarrhoea. In 13 a pathogen was isolated (eight *Salmonella*, four *Shigella* and one mixed *Salmonella* and *Shigella* infection). In the remaining 23 stool cultures were negative. The diagnosis of

infective diarrhoea in these patients was based on the clinical features—in particular, a short history of symptoms with a sudden onset, often with a clear history of contact with a source of infection, absence of significant previous episodes of diarrhoea, and lack of evidence of a prolonged illness. All these patients had a short illness and their symptoms resolved rapidly. Although, as described below, some of these patients had marked changes in the initial rectal biopsy, patients with a typical history were not reclassified on the basis of the biopsy findings (Table 2).

Table 2 *Comparison of presenting features of patients with infective diarrhoea (36 patients) and those with IBD (nine)*

	Infective diarrhoea	IBD
Sudden onset of symptoms	32/36	2/9
Associated fever and malaise	22/36	6/9
Blood in stool	14/36	7/9
History of contact with probable source of infection	22/36	2/9
History of previous episode	6/36	6/9
Evidence of chronic ill-health with weight loss	1/36	7/9
Disease satisfying recognised criteria for ulcerative colitis or Crohn's disease	2/36	9/9

Four patients were diagnosed as having traveller's diarrhoea after travel in the Middle East or Asia. All had evidence of chronic ill health with marked weight loss. Seven patients had diarrhoea related to oral antimicrobial therapy and two patients had diarrhoea which was thought to be related to medication with digoxin and mefenamic acid respectively. Two patients had coeliac disease with subtotal villous atrophy and a clinical response to a gluten free diet. There were two patients with rectal carcinoma one of whom had a jejunorectal fistula. Seven patients fulfilled the criteria for the irritable bowel syndrome (Chaudhary and Truelove, 1962). Five patients could not be classified and their salient features are summarised in Table 3.

### HISTOLOGICAL CLASSIFICATION OF RECTAL BIOPSIES

The biopsy appearances were classified into the following categories.

A. Normal appearance or minimal oedema and/or congestion (18 patients) (Fig. 1).

B. Mild to moderate excess of chronic inflammatory cells in the lamina propria but without distortion of crypt architecture, marked epithelial changes, crypt abscesses or granulomas (20 patients) (Fig. 2).

C. A mixed infiltrate of acute and chronic in-

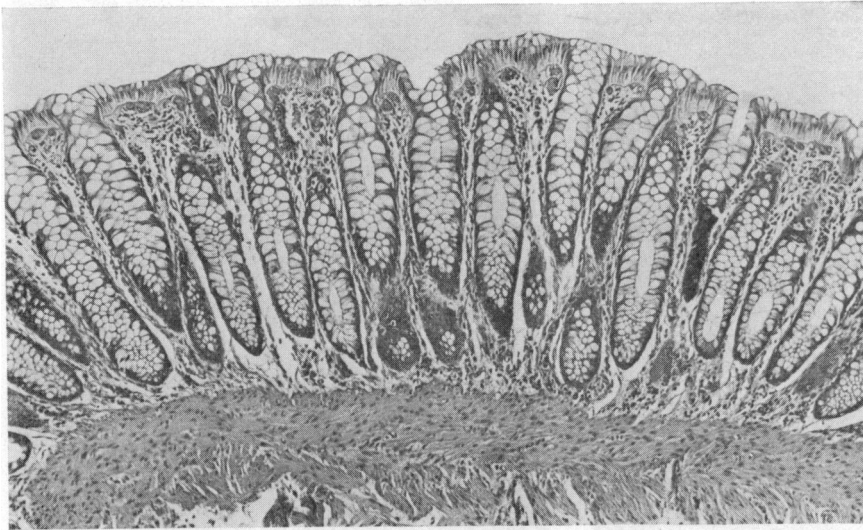


Fig. 1 Normal rectal mucosa. H and E,  $\times 75$  (histological grade A).

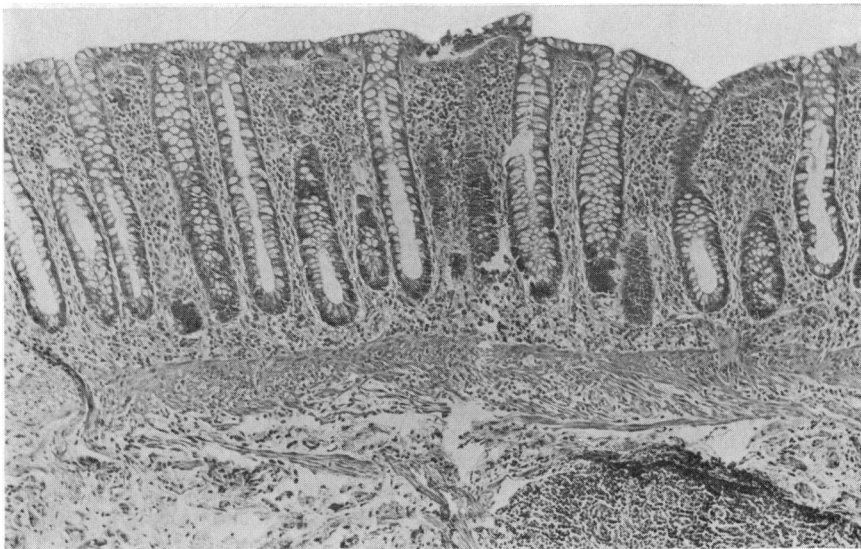


Fig. 2 Mild increase in chronic inflammatory cells in the lamina propria. H and E,  $\times 75$  (histological grade B).

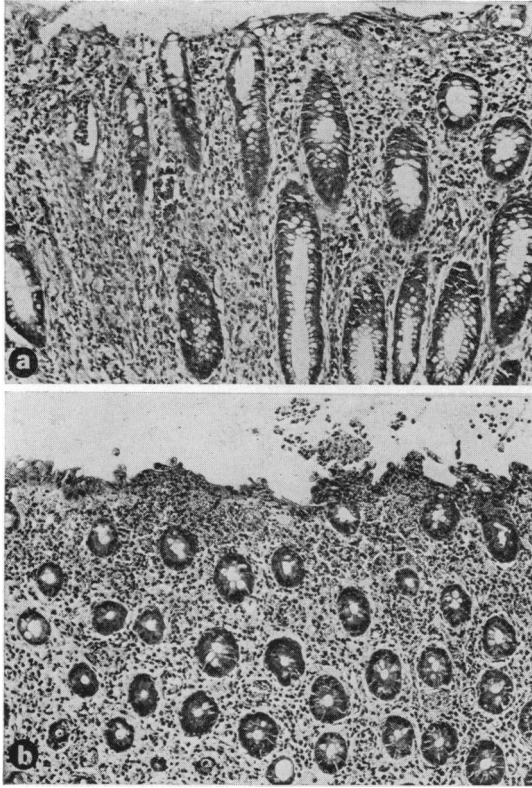
flammatory cells in the superficial lamina propria associated with oedema and congestion, degenerative or reactive changes in the epithelium of the superficial part of the crypts and the mucosal surface, with or without focal erosions. Migration of neutrophil polymorphs through the crypt epithelium or production of small numbers of superficial poorly formed crypt abscesses with a mucoid content rather than the plug of polymorphs seen in ulcerative colitis (15 patients) (Fig. 3a and b).

D. Changes typical or strongly suggestive of ulcerative colitis or Crohn's disease (11 patients) (Fig. 4).

E. Biopsies with some features common to the

preceding two groups but which could not be placed confidently in either category (six patients).

F. Unclassifiable. One patient receiving antimicrobial treatment had a thickened hyperplastic mucosa without typical changes of pseudomembranous colitis. Two patients in the infective group (one with proven *Salmonella* infection) showed focal aggregates of histiocytes in the mucosa (Fig. 5). The fourth patient (no. 46, Table 3) had an acute inflammatory surface exudate with apparently normal underlying mucosa. A random selection of biopsies from different histological categories were examined by an independent pathologist who had been informed of the criteria used to divide each category.

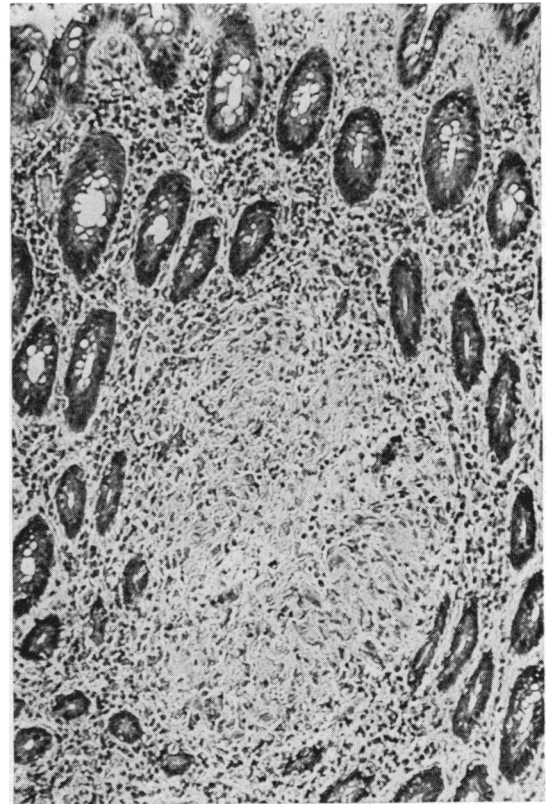


**Fig. 3** Biopsies from two patients with infective diarrhoea. (a) Shows attenuation of surface epithelium, superficial inflammatory infiltrate and superficial small poorly-formed crypt abscess. *H and E,  $\times 130$  (original magnification).* (b) Severe attenuation of surface epithelium with early erosion and prominent acute inflammatory cell infiltrate in lamina propria, within epithelium and on mucosal surface. *H and E,  $\times 140$  (original magnification).* (Both biopsies histological grade C).

His assessment agreed well with the initial examination (Fig. 6).

#### RELATIONSHIP OF CLINICAL DIAGNOSIS AND HISTOLOGICAL FINDINGS

The results of the initial biopsies are summarised in Fig. 7. Within the group clinically classified as 'infective' a wide range of histological changes was found. Eleven patients had changes classified as grade C, which we have provisionally termed 'infective type' histology. Thirteen patients had grade B changes and in four patients the biopsies were normal. In six, however, the biopsies showed histological features which were to some extent suggestive of chronic inflammatory bowel disease (four grade E and two grade F) and in two others the



**Fig. 4** Typical well-formed granuloma in lamina propria—including giant cells. *Crohn's disease. H and E,  $\times 140$  (histological grade D).*

rectal biopsy satisfied accepted histological criteria for inflammatory bowel disease (Lennard-Jones *et al.*, 1976).

A range of histological abnormalities was found in the patients with traveller's diarrhoea and in the small unclassified group. The relationship to clinical findings in the latter group is summarised in Table 3. Of the patients with antibiotic diarrhoea, one had grade F changes, three had grade C biopsies and three had normal biopsies. Patients in the other clinical diagnostic groups had normal histology apart from one patient with drug-induced diarrhoea who had grade B changes and two patients in whom irritable bowel syndrome was diagnosed clinically despite grade B biopsies.

Repeat biopsies were carried out after approximately one month of treatment in all the eight new patients initially thought to have unequivocal inflammatory bowel disease. Typical histological changes persisted in all these patients (Table 4). It was impossible to repeat rectal biopsy on all patients with infective diarrhoea, as patients whose symptoms had completely resolved were naturally

Table 3 Details of five patients in whom no diagnostic classification was made

Patient no.	Age/sex	Duration of diarrhoea (d)	Stool movements (d)	Blood in stool	History of contact	History of previous episode	Chronic ill-health wt loss	Sigmoido- Ba enema scopy	Colono- scopy	Grade of biopsy at presentation	Follow-up biopsy	Probable diagnosis	Follow-up biopsy 1 yr later
8	35F	21	5	-	-	-	-	N	N*	B		Probably infective but early self-discharge	
41	25M	14	6	+	-	-	-	Abn	N	Procto-sigmoiditis	B	Probably IBD no definite tissue diagnosis	B
46	22M	28	5	+	+	+	+	Abn	N*		B	Probably IBD, no definite tissue diagnosis	
54	50F	35	3	-	+	-	-	N	Changes of long-standing sigmoidulcerative colitis	Minimal procto-sigmoiditis	B	Probably infective but Ba enema suggests IBD	
60	29F	28	5	-	-	+	+	Abn	Presigmoidal colonic ulceration		C	Probably IBD, no definite tissue diagnosis	B

\*Normal barium follow-through.

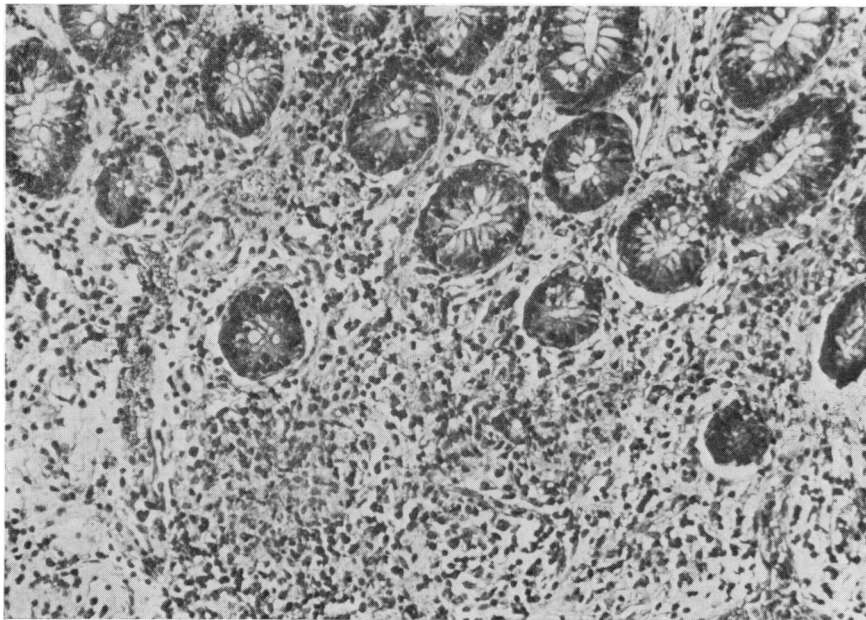


Fig. 5 Two ill-defined granulomas are present deep in the lamina propria, which elsewhere shows a mild increase in chronic inflammatory cells. H and E,  $\times 170$  (histological grade F).

reluctant to undergo repeat sigmoidoscopy. However, repeat biopsies were carried out on 10 patients (including nine with marked histological changes)

approximately one month after initial illness, when symptoms had resolved with no specific treatment. In all these cases the biopsy appearances had im-

Grading by pathologist 2	F					XXX
	E		XX	X	XXXXX	
	D			XXXXXX XXXXX		
	C	X	XXXXXX XXXXXX XXXXXX		X	X
	B	XXXXX X	XXXXXX XXXXXX XXXXXX			
	A	XXXXXX XXXXXX XXXXX	XXX			
		A	B	C	D	E
Grading by pathologist 1						

Fig. 6 Comparison of two pathologists' independent histological grading of the initial biopsies from all 74 patients.

proved strikingly. Seven returned to normality and three showed only mild chronic inflammatory infiltration (grade B) on the repeat biopsy (Table 4).

**Discussion**

This paper reports a preliminary study of the role of sigmoidoscopy and rectal biopsy in the diagnosis of diarrhoeal disease in patients referred to an infectious disease unit. Clinical as well as microbiological criteria were used to define the 'infective' group as, in many patients with clinically typical episodes of infective diarrhoea, it is not possible to isolate conventional bacterial pathogens (Phillips, 1974). In the present series, most patients with infective diarrhoea had biopsy changes graded B or

Table 4 Details of follow-up rectal biopsy in infective and IBD groups and day after presentation on which it was performed

Diagnostic group	Diagnostic information	Initial biopsy grade	Follow-up biopsy grade	Day of follow-up biopsy	
Infective		E	B	30	
		C	A	40	
	Salmonellosis		F	A	28
			D	A	30
			F	A	20
			B	A	24
	Salmonellosis		C	B	30
		Salmonellosis	D	A	33
			C	A	30
		C	B	20	
IBD		D	D	32	
		D	D	50	
		D	D	40	
		D	D	22	
		D	D	21	
		D	D	30	
		D	D	32	
		D	D	31	

C. Grade C changes were sufficiently unusual and characteristic of the infective group to suggest that these features may have diagnostic value. It is our impression that grade B changes are more usually found in patients whose diarrhoea is improving at the time of biopsy. However, it is also clear from this study that clinical and histological features suggestive of inflammatory bowel disease do not necessarily exclude an infective aetiology.

The place of rectal mucosal biopsy is not clear in the distinction between first attacks of inflammatory bowel disease and infective diarrhoea except

F	o o									
E	o o o o	o			o					
D	o o			o o o o o						
C	o o o o o				o		o o o			
B	o o o o o	o o			o o			o		o o
A	o o o o	o				o o o	o	o o	o o	o o o o
	Infective (36)	Travellers (4)	IBD (9)	Unclassified (5)	Anti-microbial (7)	Other drug (2)	Coeliac (2)	Carcinoma (2)	Irritable bowel (7)	

Fig. 7 Grade of initial rectal biopsy in each diagnostic group.

possibly in salmonellosis (Day *et al.*, 1978), and there is an obvious risk of circular argument in relating the diagnosis and the histological findings in these patients.

There were some patients in this series who had unequivocal inflammatory bowel disease on the basis of both clinical and histological features, but there were also six patients who, despite microbiological or clinical evidence that their diarrhoea was infective in origin, had some features in the rectal biopsy to suggest inflammatory bowel disease and two patients (one with proven *Salmonella* infection) had the typical histology of ulcerative colitis. These eight patients were classified as 'infective' despite the histological findings and the clinical diagnosis would appear to be correct, as the clinical and histological features resolved rapidly and there have been no recurrences to date.

These findings raise practical problems. Patients may present with clinical and histological features suggestive of inflammatory bowel disease secondary to an infective process which will resolve spontaneously. The diagnosis may be influenced by the type of unit to which the patient is referred. It would be important to avoid making a premature diagnosis of inflammatory bowel disease, with the attendant social and therapeutic implications, in such patients. Nevertheless, as fulminant colitis may occur in association with *Salmonella* infection (Dronfield *et al.*, 1974; Mandal, 1974) it is equally important to recognise that these patients may need urgent management similar to that of severe acute inflammatory bowel disease.

Information about the histological appearances in infective diarrhoeal disease is still too limited to provide a basis for the use of rectal histology in diagnosing these conditions, as the characteristic histological features of infective diarrhoeal disease have not been described except in shigellosis (see Morson and Dawson, 1972) and Salmonellosis (Day *et al.*, 1978).

The significance of mild chronic non-specific proctitis is unknown, as there are no adequate studies of normal control subjects. The apparent increase in the number of chronic inflammatory cells in the lamina propria may merely represent normal variation in mucosal cell populations or may indicate a response to non-specific stimuli such as diarrhoea of any cause (Morson and Dawson, 1972). In the latter respect it is interesting that there were four patients with severe diarrhoea in whom the rectal biopsy was normal. This finding demonstrates that an abnormal rectal biopsy is not a necessary consequence of severe diarrhoea. An alternative interpretation is that grade B changes may be pathological and represent a mild but significant in-

flammatory response and the present study gives support to this suggestion as grade B changes were unusual except in patients with clinical features of an inflammatory episode.

The biopsy appearances in the cases related to antimicrobial therapy are of interest in view of the association with pseudo-membranous colitis. Although no patient in this study had the typical changes of pseudo-membranous colitis, three biopsies had appearances of the type which we have associated with a probably infective aetiology. It is of interest that the features of this group bear some similarity to the type 1 lesion of pseudo-membranous colitis described by Price and Davies (1977), although the inflammatory changes in our infective group are more diffuse and lack the characteristic localised surface epithelial erosion with the spray of exudate. The similar appearances of the mucosal reaction in these situations may reflect a common causative factor.

We consider that this study has gone some way to fulfilling its first aim, which was to describe and classify abnormalities in rectal histology in patients referred to an infectious diseases unit because of diarrhoea. The attempt to correlate clinical and histological features suggested that there may be histological changes which are, if not typical, at least suggestive of an infective aetiology, although the overlap between these appearances and those of chronic inflammatory bowel disease may raise diagnostic problems. In those cases where the histological findings were in conflict with a clear clinical history of infective disease, the clinical diagnosis appears to have been correct, as the patients' symptoms resolved rapidly and they have stayed well. Nevertheless, the existence of this group of patients emphasises the need for additional studies of the relationship between infectious diarrhoeal disease and chronic inflammatory bowel disease.

We wish to thank Dr J. McC. Murdoch, Dr G. Sangster, and Dr J. A. Gray for allowing us to study their patients and for their encouragement and advice. In addition, we thank all the staff of the Infectious Diseases Unit at the City Hospital, Edinburgh, for their help.

#### References

- Chaudhary, N. A., and Truelove, S. C. (1962). The irritable colon syndrome. A study of the clinical features, predisposing causes, and prognosis in 130 cases. *Quarterly Journal of Medicine*, **31**, 307-322.
- Day, D. W., Mandal, B. K., and Morson, B. C. (1978). The rectal biopsy appearances in *Salmonella* colitis. *Histopathology*, **2**, 117-131.

- Dronfield, M. W., Fletcher, J., and Langman, M. J. S. (1974). Coincident salmonella infections and ulcerative colitis: Problems of recognition and management. *British Medical Journal*, **1**, 99-100.
- Lennard-Jones, J. E., Ritchie, J. K., and Zohrab, W. J. (1976). Proctocolitis and Crohn's disease of the colon: A comparison of the clinical cause. *Gut*, **17**, 477-482.
- Mandal, B. K. (1974). Ulcerative colitis and acute salmonella infection (Letter). *British Medical Journal*, **1**, 326.
- Morson, B. C., and Dawson, I. M. P. (1972). In *Gastrointestinal Pathology*. (Inflammatory disorders), pp. 448-492. Blackwell: Oxford.
- Phillips, I. (1974). Microbial infections and intoxications of the small intestine. In *The Small Intestine*, pp. 190-204. Edited by B. Creamer. Heinemann: London.
- Price, A. B., and Davies, D. R. (1977). Pseudomembranous colitis. *Journal of Clinical Pathology*, **30**, 1-12.
- Watts, J. McK., Thomson, H., and Goligher, J. C. (1966). Sigmoidoscopy and cytology in the detection of microscopic disease of the rectal mucosa in ulcerative colitis. *Gut*, **7**, 288-294.