

Case report

Enterochromaffin cell hyperplasia and megacolon: report of a case

G B M LINDOP

From the Department of Pathology, University of Glasgow, Western Infirmary, Glasgow

SUMMARY A case of megacolon is described in which there was an unusual and focal hyperplasia of enterochromaffin cells in the mucosa. These formed discrete spherical acini in the lamina propria. These acini were not neoplastic and their significance is discussed.

Enterochromaffin cells are found in the gut epithelium from the gastro-oesophageal junction to the anus.^{1,2} As their secretion of 5-hydroxytryptamine and polypeptide hormones are thought to be important in the regulation of gut motility,³⁻⁵ they have been studied in a variety of disorders. This paper reports the study of a case of megacolon in which enterochromaffin cells were not only markedly increased in number, but were disposed in discrete acini in the lamina propria separate from the overlying epithelium.

Case report

The patient, a 28 year old man, first came to medical attention six years ago complaining of intermittent abdominal distension and discomfort over the previous three to four years. On examination, his rectum was anaesthetic and full of faeces and he was thought to have faecal retention owing to faulty bowel habit. In the following few years, while attempts were being made to correct his bowel habit, he had several episodes of large bowel obstruction which were relieved by enemas given by his general practitioner. During this time, a barium enema showed faecal retention and suggested the diagnosis of idiopathic megacolon.

He was eventually admitted to hospital six years later with large bowel obstruction which was thought clinically and radiologically to be because of a volvulus of his sigmoid colon. His condition improved markedly with conservative treatment, but one week later he again developed obstruction.

This time he was taken to theatre where a large redundant loop of sigmoid colon was resected and an end-to-end anastomosis carried out.

PATHOLOGY

The specimen was a 50 cm long piece of colon. It was markedly dilated and hypertrophied, its maximum width when opened being 21 cm and the muscle coat attaining a thickness of 6 mm.

Histological sections taken from the full length and breadth of the specimen were examined. Examination of these confirmed the muscular hypertrophy and showed several abnormalities in the mucosa. Most strikingly, there was marked hyperplasia of the enterochromaffin cells which are normally fairly scanty in large bowel epithelium.² Instead of being situated singly, mainly at the base of the glands, they were present in groups and in the surface epithelium. In addition, some sections showed the presence of definite acini composed only of enterochromaffin cells and scattered sparsely in the mucosa (Fig. 1). They were present at all levels in the lamina propria but were confined to the mucosa. They were mainly disposed singly, but occasionally in groups of two or three. Serial sections showed that they were roughly spherical acini with a small central lumen which sometimes contained a small amount of eosinophilic material (Fig. 2). The acini did not communicate with one another nor with rectal glands. Histochemical studies showed these acini to be strongly stained by both the diazo and Masson-Fontana techniques (Fig. 2 and 3) as were the enterochromaffin cells in the surface epithelium and glands. Their fine structure, within the limits imposed by formalin

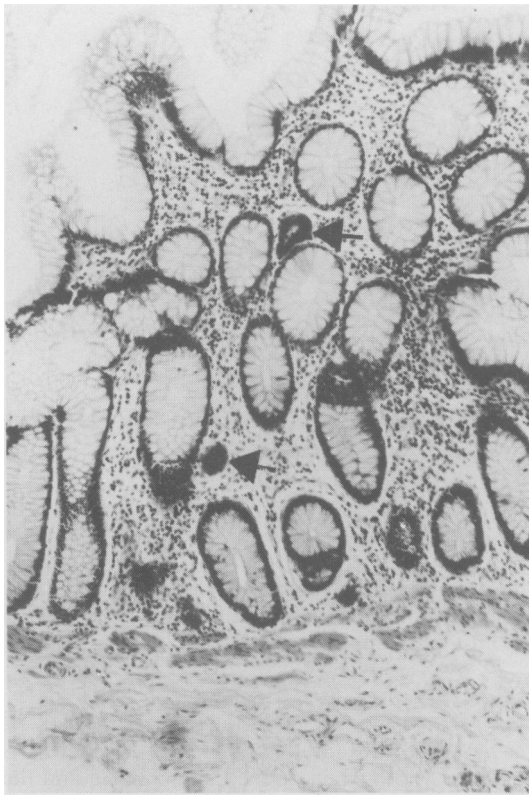


Fig. 1 Colonic mucosa showing irregularity of glands and two acini composed entirely of enterochromaffin cells (arrowed) Haematoxylin and eosin $\times 100$ (original magnification).

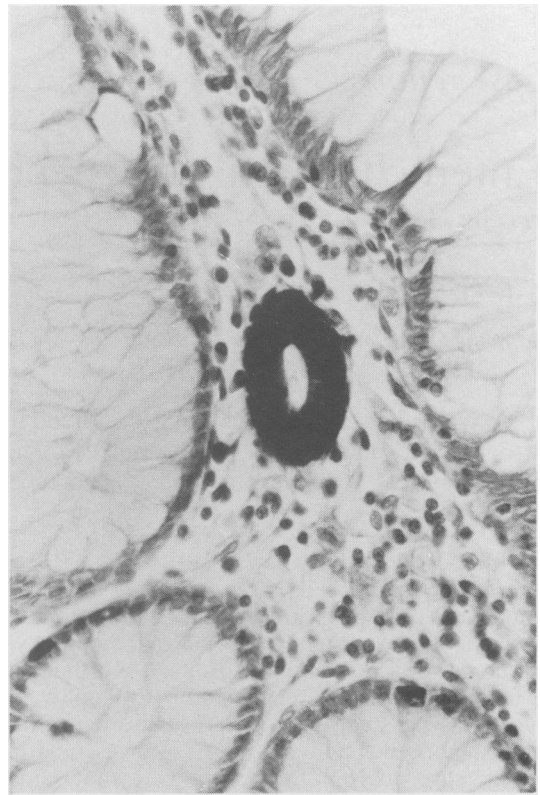


Fig. 2 Enterochromaffin cell acinus near surface of the mucosa with normal enterochromaffin cells in adjacent epithelium for comparison. Note lumen which contains small amount of amorphous material. Masson Fontana $\times 250$ (original magnification).

fixation, was that of normal enterochromaffin cells except that they were slightly larger and contained more secretory granules than the normal enterochromaffin cells in the surface epithelium (Fig. 4 and 5).

The distribution of these enterochromaffin acini within the specimen was limited to a transverse band about 10 cm wide ending approximately 8 cm from the distal end of the specimen. Within this band the acini were sparsely distributed and were not present elsewhere in the specimen. There was no evidence that these were neoplastic in nature. Study of many tissue sections revealed occasional areas which suggested that these acini were formed from groups of enterochromaffin cells in the gland or surface epithelium (Fig. 3).

Other mucosal abnormalities were branching and loss of parallelism of the glands and the presence of macrophages filled with mucin in the lamina propria (Fig. 3).

Cryostat sections of 100–300 μ in thickness were cut parallel to the lumen at various areas of the colon. These were stained by a silver impregnation technique,⁶ and examined by the method of Smith⁷ to show the nerve plexuses. These showed no definite abnormality when compared with similar sections from normal parts of colons excised for carcinoma.

Discussion

Enterochromaffin cells in the colon are normally found singly in the epithelium, predominantly of the lower parts of the glands.³ They are thought to be important in regulating the motility of the gut.³⁻⁵ In the present case, the enterochromaffin cell acini are clearly not part of a carcinoid tumour. There are three main possibilities: they may be a hamartomatous malformation, perhaps analogous to cutaneous naevi; they may be an unusual response

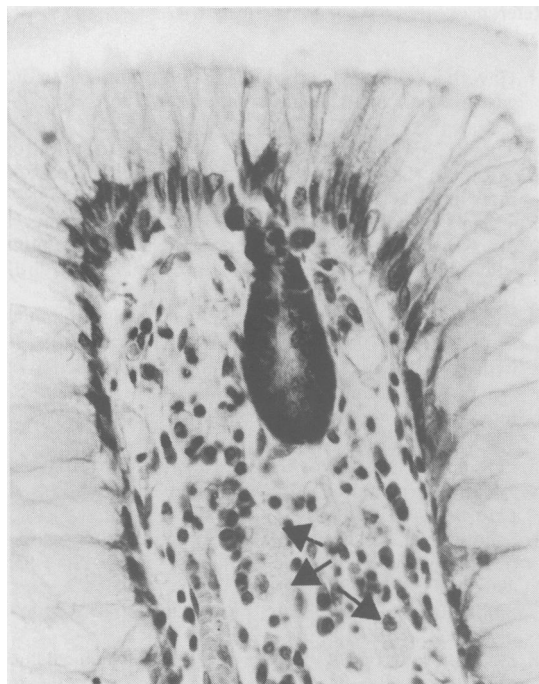


Fig. 3 Enterochromaffin cell acinus which appears to be formed from group of enterochromaffin cells in surface epithelium. Note numerous enterochromaffin cells in adjacent epithelium and mucin-containing macrophages in lamina propria (arrowed). Diazo $\times 250$ (original magnification).

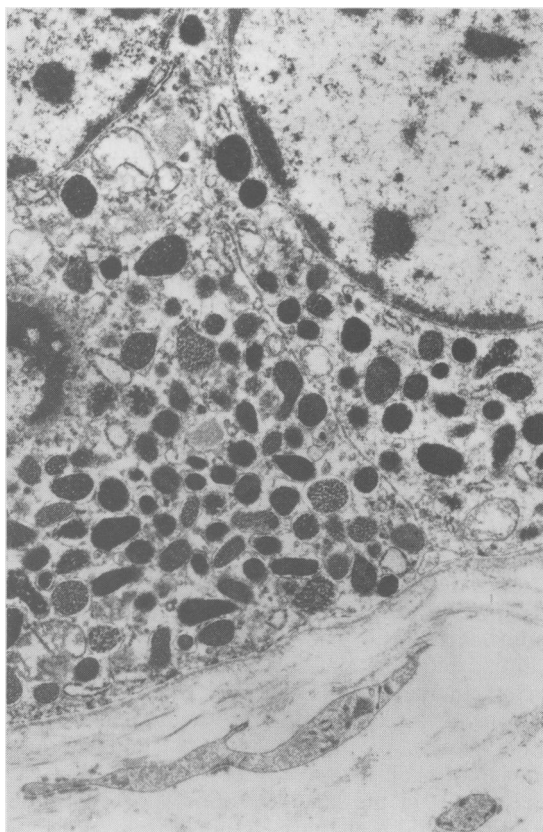


Fig. 5 Fine structure of the enterochromaffin cells of acini showing abundant secretory granules. Electron micrograph (formalin fixation) $\times 22000$ (original magnification).

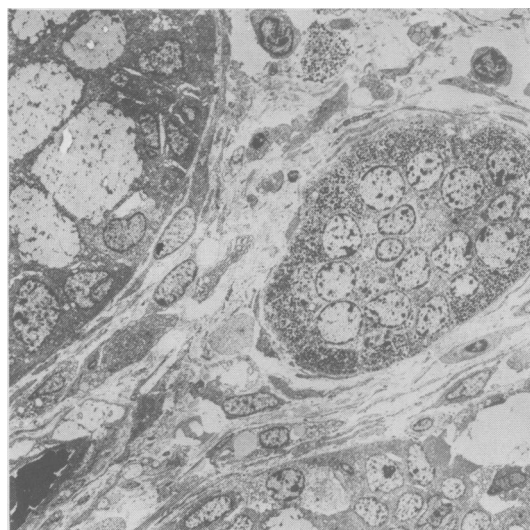


Fig. 4 Enterochromaffin cell acinus between two mucosal glands. Electron micrograph (formalin fixation) $\times 1700$ (original magnification).

to functional hyperplasia; or they may be a preneoplastic lesion. The presence of hyperplasia of the enterochromaffin cell population in the overlying epithelium and the histological appearances illustrated in Fig. 3 may be evidence that the formation of acini is a response to proliferation of enterochromaffin cells in the surface epithelium. Argyrophilic 'endocrine-like' cells were described as forming groups of two to five cells in the lamina propria in cases of chronic gastritis^{8,9} but these authors did not comment on the total number present in the mucosa. In a study of 1200 appendices Masson¹⁰ described enterochromaffin cells migrating from the gland epithelium into the lamina propria. Rarely a process of 'bourgeoisment' or budding was observed where the enterochromaffin cells formed acinar structures within the lamina propria. These resembled the appearances described here. A similar budding process was called 'endophytie' by Feyrter¹¹ who postulated that the

pancreatic endocrine cells originated from such a process of budding from foregut endoderm.

The relationship of the argentaffin cell hyperplasia to the megacolon seems obscure. On the one hand, it seems unlikely that hyperplasia of the enterochromaffin cells caused the megacolon as the hyperplasia is focal and the maximum hyperplasia is not present at the most distal aspect of the megacolon. On the other hand, it seems unlikely that megacolon would produce a focal hyperplasia, and hyperplasia of enterochromaffin cells is not known to be associated with megacolon which is a common condition. Thus it seems unlikely that the hyperplasia was secondary to the megacolon. It is therefore possible that this is a chance association.

Enterochromaffin cell hyperplasia has been described in some other gut disorders – untreated coeliac disease¹² and the chronic gastritis of pernicious anaemia.¹³ Similarly, in Masson's¹⁰ massive study of the appendix already mentioned the hyperplastic enterochromaffin cells occurred in cases of chronic obliterative appendicitis with neural hyperplasia. In all of these diseases the role of the enterochromaffin cell hyperplasia is unclear. Chronic inflammation, however, may be the linking factor. In the present case the inflammatory cell content of the lamina propria was normal but the gland pattern of the mucosa was abnormal and branching glands were present: also there were muciphages in the lamina propria. Both of these features could well have resulted from previous inflammation.

Enterochromaffin cells may be present in epithelial neoplasms of the gut and in some of these large numbers may be present.¹⁴⁻¹⁷ There is very little information available in the literature, however, on the enterochromaffin cell population of the gut epithelium adjacent to tumours, and more particularly, adjacent to carcinoid tumours. In the case described by Black and Haffner¹⁸ multiple gastric carcinoid tumours were associated with diffuse hyperplasia of argyrophil cells which formed non-neoplastic acini separate from the tumours. In their review of the literature, they thought, from analysis of the illustrations in other authors' cases, that hyperplasia of these cells may occur in relation to carcinoid tumours. It is therefore possible that the unusual hyperplasia of enterochromaffin cells reported here may be a pre-neoplastic process. Further quantitative studies of these cells in the region of carcinoid tumours may shed some light in this area.

References

- 1 Haverback BJ, Davidson JD. Serotonin and the gastrointestinal tract. *Gastroenterology* 1958; **35**: 570–8.
- 2 Tobe T, Fujiwara M, Tanaka C. The distribution of serotonin (5-hydroxytryptamine) in the human gastrointestinal tract. *Am J Gastroenterol* 1966; **46**: 34–7.
- 3 Solcia EL, Polak JM, Pearse AGE *et al*. Classification of gastro entero pancreatic endocrine cells. In: Bloom SR, ed. *Gut hormones*. Edinburgh: Churchill Livingstone, 1978: 40–8.
- 4 Bulbring E, Lin RCY. The effect of intraluminal application of 5-hydroxytryptamine and 5-hydroxytryptophan on peristalsis: the local production of 5-hydroxytryptamine and its release in relation to intraluminal pressure and propulsive activity. *J Physiol* 1958; **192**: 823–46.
- 5 Pentilla A, Lempinen M. Enterochromaffin cells and 5-hydroxytryptamine in the human intestinal tract. *Gastroenterology* 1968; **54**: 375–81.
- 6 Schofield GC. Experimental studies on the innervation of the mucous membrane of the gut. *Brain* 1960; **83**: 490–512.
- 7 Smith B. The myenteric plexus in Hirschsprung's disease. *Gut* 1967; **8**: 308–12.
- 8 Stachura J, Urban A, Bigaj M *et al*. Histochemical and ultrastructural observation of endocrine cells in pathological gastric mucosa. *Folia Histochem Cytochem (Krakow)* 1978; **16**: 287–8.
- 9 Stachura J, Krause WJ, Ivey KJ. Ultrastructure of endocrine-like cells in lamina propria of human gastric mucosa. *Gut* 1981; **22**: 534–41.
- 10 Masson PC. Carcinoids (argentaffin-cell tumours) and nerve hyperplasia of the appendicular mucosa. *Am J Pathol* 1928; **4**: 181–212.
- 11 Feyrter, F. Uber diffuse endokrine epitheliale organe. *Zentralbl Inn Med* 1938; **545**: 31–41.
- 12 Challacombe DE, Robertson K. Enterochromaffin cells and coeliac disease. *Lancet* 1976; **1**: 370–1.
- 13 Rubin W. Proliferation of endocrine-like (enterochromaffin) cells in atrophic gastric mucosa. *Gastroenterology* 1969; **57**: 641–8.
- 14 Bates JR, Belter LF. Composite carcinoid tumour (argentaffinoma-adenocarcinoma) of the colon: report of two cases. *Dis Colon Rectum*; 1967; **10**: 467–70.
- 15 Gibbs NM. Incidence and significance of argentaffin and Paneth cells in some tumours of the large intestine. *J Clin Pathol* 1967; **20**: 826–31.
- 16 Kubo T, Watanabe H. Neoplastic argentaffin cells in gastric and intestinal carcinomas. *Cancer* 1971; **27**: 447–54.
- 17 Watanabe H. Argentaffin cells in adenoma of the stomach. *Cancer* 1972; **30**: 1267–74.
- 18 Black WC, Haffner HE. Diffuse hyperplasia of gastric argyrophil cells and multiple carcinoid tumours. *Cancer* 1968; **21**: 1080–99.