

Technical note

Overtubes (sleeves) for upper gastrointestinal endoscopy

P B COTTON

From the Department of Gastroenterology, The Middlesex Hospital, London

SUMMARY Overtubes are short sleeves designed to fit over the shaft of fibrescopes. Several home made overtubes have been described.¹⁻⁶ We have reviewed design principles and many potential applications, which are not widely appreciated.

PRINCIPLE AND OVERALL DESIGN

Overtubes are usually placed over the proximal part of the fibroscope shaft (Fig. 1). Once the tip of the endoscope has been swallowed, the overtube is slid down over the shaft, to 'splint' the pharynx and oesophagus. The internal diameter of the overtube is determined by the size of fibroscope, leaving a small gap which allows smooth passage of the instrument, without danger of catching or pinching the mucosa. The tube wall should be soft and relatively thin so as to minimise discomfort during passage, but it should also be firm enough to resist damage when sharp objects are passed through it, and to maintain its shape when the endoscope is removed. It is convenient to be able to examine the mucosa through the overtube wall, but transparent tubes are too floppy for many purposes. In order to prevent them being swallowed completely, overtubes should incorporate a mouthguard (Fig. 1), or a loop for an assistant to hold (Fig. 2), or a flange which fits behind a standard mouthguard (Fig. 3). The length of an overtube is determined by the indications for its use.

LONG OVERTUBES

Overtubes designed to transgress the cardia should be about 50 cm long, and may need to incorporate a proximal valve or cuff to prevent escape of air.

Extraction of foreign bodies There are hazards in using fibrescopes to extract foreign bodies. Sharp objects may damage the oesophagus and pharynx during withdrawal, and there is a danger of dropping small objects into the trachea. These risks can be

Address for correspondence: Dr P B Cotton, The Middlesex Hospital, London W1N 8AA.

Received for publication 2 November 1982




Fig. 1 Short overtube incorporating mouthguard placed over proximal shaft of fibroscope before passage.

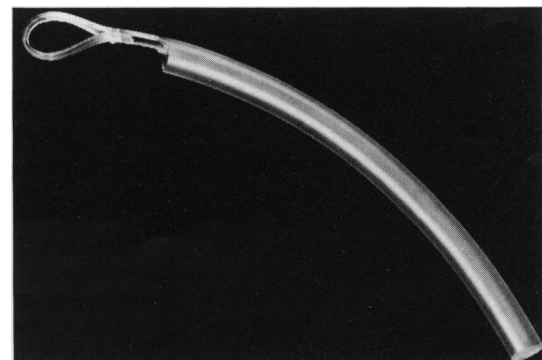


Fig. 2 Short plastic overtube with loop made from tube wall for assistant to hold.

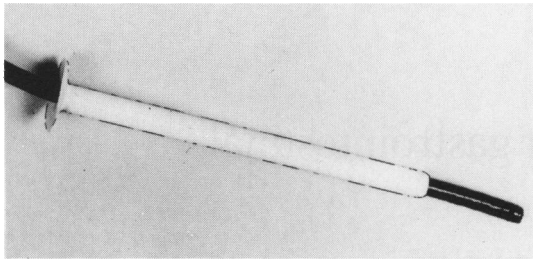


Fig. 3 Thinner walled soft overtube with proximal flange which fits behind standard mouthguard.

minimised by using an overtube, which provides all the advantages which made the rigid oesophago-scope popular.^{1 2 7} The overtube is slid down over the lubricated instrument until its tip is close to the object in the oesophagus or stomach. The foreign body is grasped and withdrawn into the tube (Fig. 4); object, overtube, and fibrescope are withdrawn together. Suction can be applied directly to the overtube mouth (after removing the endoscope); this method has been recommended for removing food impacted in the oesophagus.³ The optimum diameter of an overtube for foreign body extraction will depend upon the foreign body and the fibre-

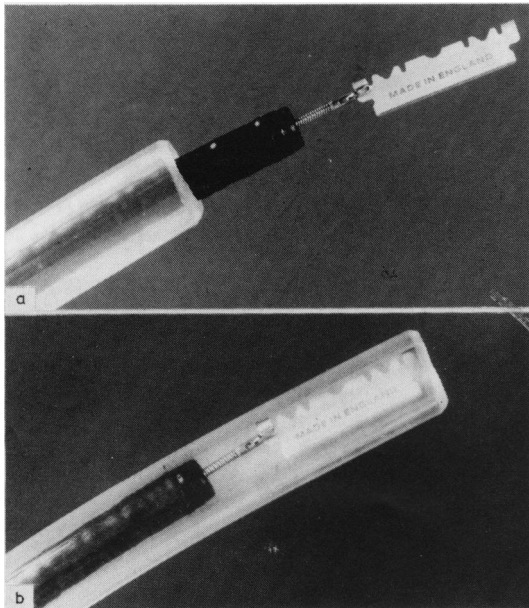


Fig. 4 (a) Standard fibrescope with large long overtube for use with sharp foreign bodies. (b) Foreign body withdrawn into overtube before extraction of both.

scope to be used. General anaesthesia may be necessary with the largest tubes.

Sclerotherapy of oesophageal varices Injection sclerotherapy was performed initially with rigid instruments, which allow the operator to apply pressure on the varices, and to use adequate suction. Now, sclerotherapy is mainly done with fibrescopes; some experts use a special overtube with a distal window⁸ (Fig. 5). The overtube is slid down just beyond the tip of the fibrescope in the oesophagus, until a varix bulges into view through the window; the injection is made, and the tube is then rotated to compress the injected varix, and to reveal another one. The injections are continued as the tube is withdrawn in a corkscrew manner. When necessary, suction can be applied directly to the overtube after temporary removal of the fibrescope. An overtube also makes it easier to place tamponade devices.

Laser photocoagulation Most laser probes incorporate a co-axial gas jet to keep the tip clean, and to prepare the lesion for treatment. It is essential to provide a venting system, and many groups have found it necessary to use a double channelled endoscope. Gas venting can be provided much more simply by using a long overtube, without a proximal valve or cuff; gas leaks out between the endoscope and the overtube. The tube also provides a route for rapid suction and lavage if the endoscope is withdrawn temporarily.

SHORT OVERTUBES

Overtubes designed to protect the pharynx and crico-pharynx need be only 25 cm long, and do not affect the competence of the cardia. There are many possible applications.⁴

Repeated intubations With a short overtube in place, it is easy to make many passes with fibrescopes – for example, to remove multiple polyps or to change instruments – with minimal patient discomfort.



Fig. 5 Distal half of overtube designed for variceal sclerotherapy, showing distal window.

Muzzle-loaded ancillaries Overtubes make it possible to use devices which are too large to pass through the biopsy channel of an endoscope, using the technique of 'muzzle-loading'. An overtube is placed in the upper oesophagus and the endoscope is withdrawn. The device, such as a pair of 'jumbo' biopsy forceps, is loaded retrogradely through the instrument channel. The endoscope is then passed through the overtube, with the jaws protruding in front of it (Fig. 6). Multiple biopsies can be taken by repeated passage.⁹ The same technique makes it possible to take multiple specimens with biopsy capsules, and many other devices and probes could be introduced in the same way.

Lavage and suction Many experts do not use gastric lavage routinely before endoscopy in patients with acute bleeding. If the view is obscured by blood, the fibroscope is removed and replaced after performing lavage. This process can be speeded by using an overtube; when lavage is required, the endoscope is removed and temporarily replaced by a large bore suction tube. When the need for suction is anticipated – for example, in patients with pyloric stenosis, achalasia, and massive bleeding – it is helpful to pass the overtube first, with a large bore suction tube as the introducer (Fig. 7). The introducer is removed and replaced by the endoscope when lavage has been completed.

An alternative method for introducing fibroscopes In the above clinical situations we found that the overtube and introducer were easier for patients to swallow than a blunt ended fibroscope, and we therefore tried using the same system in routine diagnostic endoscopy. The patient first swallows an overtube riding on a soft rubber introducer (Fig. 7). The introducer is replaced by the fibroscope once the overtube tip is in the oesophagus. This method reduces the discomfort

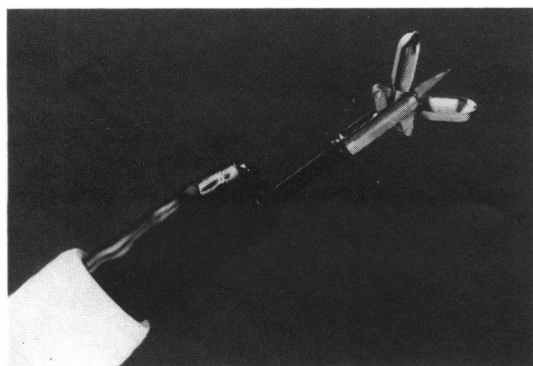


Fig. 6 Muzzle loaded jumbo biopsy forceps being used through an overtube.




Fig. 7 Alternative method for introducing fibroscopes. Soft overtube is first passed with rubber introducer.

normally produced by movements of the endoscope within the pharynx, and makes it easier for patients to tolerate endoscopy without sedation.

PRECAUTIONS AND CONCLUSIONS

All departments performing upper gastrointestinal endoscopy will find some indication for the use of overtubes. Although no specific complications have been reported, great care must be taken, particularly with home made tubes. Overtubes should not be passed blindly in patients with upper oesophageal symptoms.

ADDENDUM

Since this paper was submitted, Rogers and colleagues have given further details of a long overtube for extraction of foreign bodies (*Gastrointestinal Endoscopy* 1982; 28: 256–7).

The overtube shown in Figs 1 and 7 is available through Keymed Ltd, Stock Road, Southend-on-Sea, Essex.

References

- 1 Witzel L, Scheurer U, Muhlemann A, Halter F. Removal of razor blades from the stomach with fiberoptic endoscope. *Br Med J* 1974; 2: 539.
- 2 Martin WC, Jones SA, Nagai N, Texter EC Jr. Fibreendoscopic removal of long foreign bodies from the stomach using a colon stiffening tube as a protective sheath. *Am J Gastroenterol* 1979; 71: 505–7.
- 3 Rogers BHG. A new method for extraction of

- impacted meat from the oesophagus using a flexible fibreoptic endoscope and an overtube. (Abstract.) *Gastrointest Endosc* 1979; **25**: 47.
- 4 Cotton PB. An over-tube (sleeve) concept at upper GI endoscopy. (Abstract.) *Gut* 1981; **22**: A415.
- 5 Szpak MW. Endoscopic overtubes. (Abstract.) *Gastrointest Endosc* 1981; **27**: 129-30.
- 6 Norfleet RG, Skerven G. Large bore tube for both lavage and passage of endoscopes. *Soc Gastrointest Assistants J* 1980; **3**: 18-9.
- 7 Schiller KFR. Foreign bodies of oesophagus and stomach. In: Bennett JR, ed. *Therapeutic endoscopy and radiology of the gut*. London: Chapman and Hall, 1981: 87-106.
- 8 Williams KGD, Clark A. Oesophagal varices - endoscopic obliteration. In: Bennett JR, ed. *Therapeutic endoscopy and radiology of the gut*. London: Chapman and Hall, 1981: 47-58.
- 9 Cotton PB. Muzzle-loaded jumbo biopsy at gastroscopy. *Acta Endoscopica* 1983. (In press.)