

Meralgia Paresthetica, The Elusive Diagnosis

Clinical Experience With 14 Adult Patients

Gregory K. Ivins, MD, FACS

From the Department of Surgery, Callaway Community Hospital, Fulton, Missouri

Objective

To discuss the diagnosis and treatment of meralgia paresthetica as reported in the literature and as experienced by the author.

Summary Background Data

Meralgia paresthetica is a mononeuropathy of the lateral femoral cutaneous nerve that can lead to significant disability when the diagnosis and treatment is delayed or missed. This condition is relatively common but is frequently mistaken for other disorders.

Methods

Fifteen cases of meralgia paresthetica were identified in 14 patients in a private surgical practice during a 4-year period. All patients were initially treated conservatively and seven patients subsequently underwent surgical treatment. Follow-up ranged from 3 to 6 years.

Results

Conservative management consisting of local analgesics, steroids, nonsteroidal antiinflammatories, rest, and reduction or elimination of aggravating factors yielded long-lasting improvement in five patients with meralgia paresthetica. Nine patients with 10 cases of meralgia paresthetica did not benefit in the long term from conservative management. Seven of these patients, representing eight cases of meralgia paresthetica, ultimately opted for surgical management, and all obtained good long-term relief of symptoms.

Conclusion

Surgical management of meralgia paresthetica is a viable option for patients in whom medical management fails. Based on the published literature and the author's experience, a rationale is presented for determining the appropriate surgical management of these patients.

Meralgia paresthetica is a mononeuropathy of the lateral femoral cutaneous nerve (LFCN) that can lead to significant disability when the diagnosis is missed or delayed. Fifteen cases of meralgia paresthetica were identified in 14 patients in a private surgical practice during a 4-year period. All patients were initially treated conservatively, and this yielded long-lasting improvement in five patients. The remaining patients did not respond adequately to medical management. Seven of these patients subsequently opted for surgical management, and all had long-term relief of symptoms in follow-up lasting 3 to 6 years.

Meralgia paresthetica was first described by Hager in 1885.¹ Bernhardt reported more extensively on the condition in 1895, and 2 weeks later Roth published a paper in

which he coined the term meralgia, from the Greek words *meros* for thigh and *algos* for pain.²

Numerous articles concerning meralgia paresthetica were published in the first half of this century; one author even prefaced his report with an apology for discussing "so commonplace a topic as meralgia paresthetica."³ Despite its early widespread recognition, meralgia paresthetica has since become an obscure diagnosis, and few practicing physicians seem to be aware of the condition or recognize the symptoms. The purpose of this paper is to review this condition briefly and present my experience with 14 meralgia paresthetica patients.

Classically, meralgia paresthetica is described as a syndrome of dysesthesia or anesthesia in the distribution of the LFCN. Patients typically describe burning, coldness, lightning pain, deep muscle achiness, tingling, frank anesthesia, or local hair loss in the anterolateral thigh. The symptoms may be mild and resolve spontaneously or may severely limit the patient for many years.

Correspondence: Gregory K. Ivins, MD, FACS, 26 S. Hospital Dr., Fulton, MO 65251.

E-mail: gkivins@ktis.net

Accepted for publication February 28, 2000.

Patients may have secondary hip, knee, and calf pain as they try to modify their activities to minimize the symptoms. Symptoms may be exacerbated when the hip is extended, and patients may avoid standing erect or may have difficulty sleeping. Sitting may relieve the symptoms in some patients but exacerbate them in others. Eventually, there may be no position that provides relief. Frequently patients have been treated for presumed back, hip, and groin pathology before meralgia paresthetica is correctly diagnosed. Patients often find it difficult to describe their symptoms and may come to believe that their problem is psychiatric.

ANATOMY

The LFCN is primarily a sensory nerve but also includes efferent sympathetic fibers carrying vasomotor, pilomotor, and sudomotor impulses.⁴ It is quite variable and may be derived from several different combinations of lumbar nerves, including L2 and L3, L1 and L2, L2 alone, and L3 alone.⁵ The LFCN may be associated with the femoral nerve as it passes through the inguinal ligament or may anastomose with the femoral nerve distal to the inguinal ligament. Piersol⁶ reported that the LFCN may be partially or entirely derived from the adjacent genitofemoral or femoral nerve, and Keegan and Holyoke⁷ noted this variation in 30% of their cadaver dissections. On occasion, the LFCN is absent and may be replaced by a branch of the ilioinguinal nerve.⁵

The LFCN passes behind the psoas muscle and runs beneath the iliac fascia as it crosses the surface of the iliacus muscle. As the nerve approaches the anterior superior iliac spine, it pierces the iliac fascia and exits through a fibrous tunnel into the thigh. Roth noted that the nerve is vulnerable to pressure or stretching where it emerges beneath the psoas muscle, passes around the anterior superior iliac spine, courses through the fibrous canal of the fascia lata, and finally exits the fascia lata.² The site at which the LFCN exits the pelvis varies, and symptoms of meralgia paresthetica have been reported with each of five known variants.

The LFCN is most frequently found passing through the split lateral attachment of the inguinal ligament. As the nerve curves medially and inferiorly around the anterior superior iliac spine, it may be subjected to repetitive trauma in this fibroosseous tunnel. Nathan⁸ observed thickening of the LFCN at this level in 60% of his cadaver dissections and postulated that this was a direct response to chronic irritation.

The nerve may pass posterior to the inguinal ligament and anterior to a sharp ridge of iliacus fascia. Ghent⁹ noted that this variation may lead to a bowstring deformity of the nerve when the patient is supine.

Occasionally, the LFCN enters the thigh within or beneath the substance of the sartorius muscle. Stookey¹⁰ reported that in some instances the nerve passed through a shallow bony groove posterior to the sartorius. Ghent and

Stookey both reported symptomatic patients with this variation.

Several cases have been reported in which the LFCN crosses over the iliac crest lateral and posterior to the anterior superior iliac spine. The nerve typically lies in a groove in the ilium and is subject to pressure from tight garments or belts.^{9,10} Hager's initial case report involved this location.²

The nerve may exit the pelvis in multiple branches with entrapment of a single branch. Williams and Trzil¹¹ reported displacement of the branches as much as 6 cm medial to the anterior superior iliac spine.

METHODS

Fifteen cases of meralgia paresthetica were identified in 14 patients. The LFCN was affected unilaterally in 13 patients and bilaterally in 1 patient. Involvement of the LFCN was confirmed in each instance by injecting a small amount of bupivacaine with epinephrine around the LFCN where it passed near the anterior superior iliac spine. The accuracy of the injection was confirmed by obtaining anterolateral thigh paresthesia, and in each case the symptoms were completely relieved for several hours. On follow-up visits, the patients were given a second injection in the same area using a mixture of bupivacaine and methylprednisolone, and they again obtained complete relief. Five patients had no further symptoms in follow-up ranging from 28 to 60 months. Nine patients had recurrence of their symptoms 2 to 4 weeks after the second injection. These patients were typically injected a third time to ensure that the results were reproducible. These patients also underwent computed tomography or magnetic resonance imaging examinations of the lower back and pelvis to rule out discogenic disease or other pathology. Seven patients in this group subsequently opted for surgical treatment of their meralgia paresthetica.

RESULTS

Between 1992 and 1996, four women and three men underwent surgery for meralgia paresthetica. Symptoms had been present from 2 to 15 years. Three of the patients had a total of five previous operations performed elsewhere, but none of the operations resulted in relief. These operations included femoral head core decompression, groin exploration, iliotibial Z-plasty, and ilioinguinal nerve resection.

Typical anterolateral thigh dysesthesias associated with meralgia paresthetica are depicted in Figure 1. Patients frequently could not stand to wear tight clothing or carry keys in the pocket of the affected side. One patient with an above-knee amputation could not wear his prosthesis because of the thigh dysesthesia. In addition, three patients also had lower lateral leg pain on the affected side (Fig. 1C). This lower leg pain was perceived by the patients as being

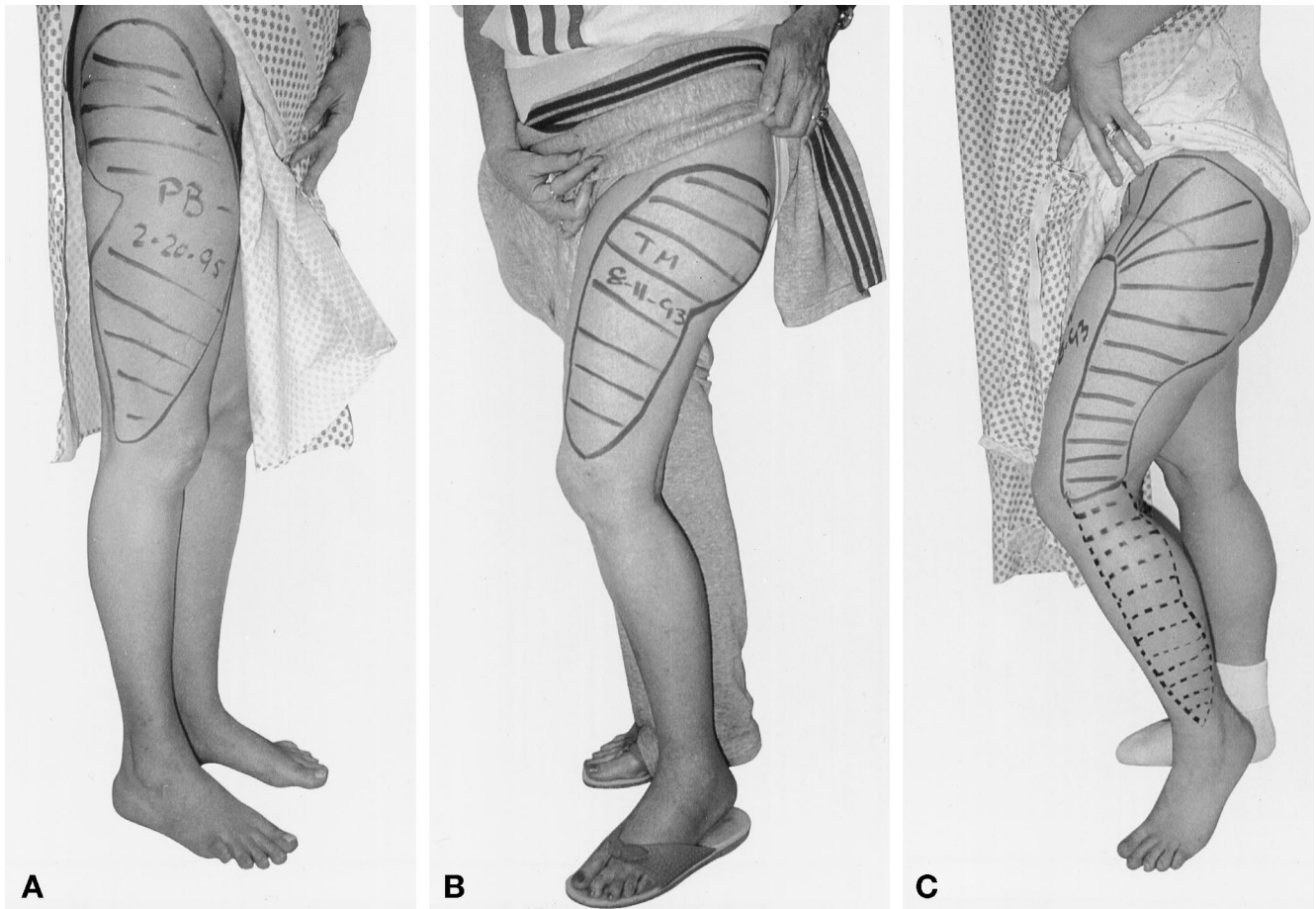


Figure 1. Solid lines (A–C) represent area of dysesthesia; broken lines (C) represent area of additional pain with standing.

related to but distinct from the thigh dysesthesias. All of these symptoms were relieved after resection of the LFCN.

Results are summarized in Table 1. Follow-up ranged from 3 to 6 years.

DISCUSSION

As the LFCN exits the pelvis, it is subject to compression and stretching injuries (Fig. 2) by such conditions as obesity, pregnancy, ascites, tight garments, seat belts, braces, direct trauma, leg length changes, scoliosis, and muscle spasm.¹¹ It may also be injured by lower abdominal and pelvic incisions, such as for appendectomies,¹² iliac wing bone grafts,¹³ and Chiari pelvic osteotomies.¹⁴ The lateral femoral cutaneous nerve may also be compressed or injured within the pelvis, and cases have been reported in association with uterine myoma, cecal tumor, appendiceal abscess,² retroperitoneal lipofibrosarcoma,¹² and periostitis of the ilium.² The recent surge in laparoscopic hernia repairs has resulted in a significant number of LFCN injuries within the pelvis.^{15,16}

The LFCN typically separates into an anterior and a posterior branch several centimeters distal to the anterior superior iliac spine. Various authors in the past have pos-

tulated isolated involvement of either the anterior or posterior branch, based on the surface distribution of symptoms.^{2,17} Williams and Trzil¹¹ have surgically confirmed that this can occur. Some variations in the surface distribution of symptoms are also likely due to variations in nerve root derivation.

Meralgia has been described in patients from 1 to 80 years of age, but most cases have occurred between the ages of 30 and 65.¹⁸ Ecker and Woltman,¹⁹ Stookey,¹⁰ Aird,²⁰ Brain,²¹ Chhuttari et al,²² Kitchen and Simpson,²³ and Huddleson²⁴ all reported a male predominance. Rosenheck³ noted an equal distribution between the sexes in his series, whereas King,²⁵ Rhodes,²⁶ and Williams and Trzil¹¹ reported a female predominance. In the present series, 10 of the 14 patients were female.

The incidence of bilateral involvement was reported as 10% by Kitchen and Simpson,²³ 15% by Chhuttari et al,²² 20% by Ecker and Woltman¹⁹ and Musser and Sailer,²⁷ and 50% by Rosenheck³ and Edelson and Stevens.²⁸ Sigmund Freud published his description of bilateral meralgia paresthetica in himself in 1895 and noted that one side was improving as the other side worsened.²⁹ One case of bilateral involvement (7%) was encountered in the present series.

The diagnosis of meralgia paresthetica is primarily clin-

Table 1. RESULTS OF SURGERY FOR MERALGIA PARESTHETICA

Patient	Age	Sex	Side	Duration	Previous Surgery	Meralgia Surgery	Results
WW	36	F	R	2 years	Femoral head core decompression	R LFCN neurolysis	Initial relief, recurrence at 12 months
WW	36	F	L	2 years	Femoral head core decompression	R LFCN resection L LFCN neurolysis	Persistent relief Initial relief, recurrence at 3 months
TM	58	F	L	15 years	Groin exploration, iliotibial Z-plasty	L LFCN resection L LFCN neurolysis	Persistent relief Initial relief, recurrence at 2 months
PB	41	F	R	4 years	None	L LFCN resection R LFCN neurolysis	Persistent relief Initial relief, recurrence at 24 months
CB	48	F	L	11 years	None	R LFCN resection L LFCN resection	Persistent relief Persistent relief
CK	66	M	L	7 years	None	L LFCN resection	Persistent relief
NB	47	M	L	3 years	None	L LFCN resection	Persistent relief
MD	45	M	L	5 years	L ilioinguinal nerve resection	L LFCN resection	Persistent relief

LFCN, Lateral femoral cutaneous nerve.

ical. Nerve conduction velocity testing has been used^{30,31} but generally has been ineffective because of the difficulty in obtaining sensory potentials for the nerve. Gateless et al³² reported a qualitative difference in contact thermograms in six patients with meralgia paresthetica when compared with six controls. I have no experience with this technique and am not aware of any other reports concerning thermography in the diagnosis of meralgia paresthetica. Magnetic resonance imaging and computed tomography have been ineffective in visualizing the affected portion of the LFCN but are helpful in ruling out more proximal pathology. The diagnosis can consistently and reliably be made by accurately mapping the area of dysesthesia, confirming the involvement of the LFCN by judiciously injecting a small amount of anesthetic at the site where the lateral femoral cutaneous nerve exits the pelvis, and ruling out more proximal sources of L1, L2, or L3 nerve root involvement. Anesthetizing the LFCN is helpful in confirming the diagnosis and may be curative, but it is also useful in allowing the patient to experience the anticipated results of a nerve resection.

The initial treatment of meralgia paresthetica is conservative, and patients may benefit from analgesics, nonsteroidal antiinflammatory drugs, looser clothing, weight loss, and the judicious use of local anesthetics and steroids. In pregnancy, conservative therapy is indicated because the symptoms generally resolve after the patient has given birth.

Patients who fail to respond to conservative therapy should be considered for surgery, but there is no consensus as to the best surgical treatment. Hager,² King,²⁵ and Williams and Trzil¹¹ recommended resection. Stookey¹⁰ ad-

vised transecting the nerve. Ghent⁹ advocated excision of the posterior slip of the inguinal ligament to decompress the nerve, or transection of the nerve when this was impossible. Edelson and Stevens²⁸ recommended decompression in their pediatric patients, whereas Macnichol and Thompson¹⁵ concluded that decompression was effective in less than half of their adult patients. Lee³³ and Mack³⁴ transposed the nerve laterally by cutting a slot in the iliac wing. Keegan and Holyoke⁷ divided the posterior slip of the inguinal ligament and transposed the nerve medially. Aldrich and Van den Heever³⁵ advocated neurolysis with or without transposition and advised against transection.

Many of the earlier authors did not report long-term follow-up. To the best of my knowledge, the only published series of meralgia paresthetica patients with long-term follow-up are those of Macnichol and Thompson,¹⁵ Williams and Trzil,¹¹ and Edelson and Stevens.²⁸

In a series of 25 patients aged 22 to 72 years treated with decompression, Macnichol and Thompson¹⁵ reported 11 patients with long-term complete relief and 4 patients with significant improvement. Two patients had temporary improvement, and eight patients had no benefit. Reexploration was not helpful, and they concluded that decompression was not indicated if symptoms had been present more than 1 year.

Williams and Trzil¹¹ reported on 24 patients treated with nerve resection. The patients ranged in age from 19 to 68 years, and follow-up was 4 to 25 years. Twenty-three of the patients had sustained satisfactory relief.

Edelson and Stevens²⁸ reported long-term follow-up of 21 cases of meralgia paresthetica in 13 patients age 1 to 17

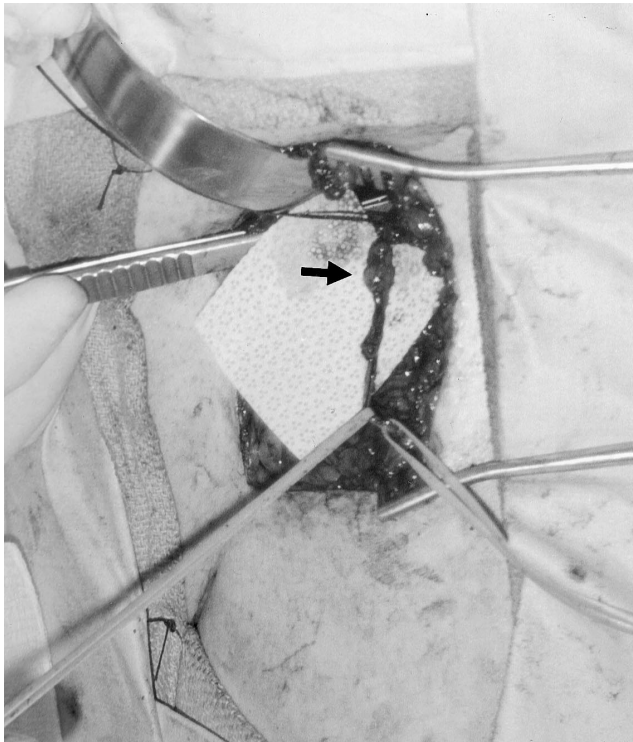


Figure 2. Arrow indicates gangliform swelling of the lateral femoral cutaneous nerve as it crosses under the anterior superior iliac spine.

years. Patients were treated with decompression, resulting in complete relief in 14 cases and significant improvement in 5. Two patients initially had complete relief but subsequently developed recurrent symptoms.

In the present series, the first four cases of meralgia paresthetica in three patients were treated with decompression. This consistently yielded prompt relief of symptoms, but each of these patients developed recurrent symptoms within 2 to 24 months of the initial decompression. Reexploration in these patients with resection of the LFCN has yielded long-lasting relief in each patient. The last four patients in this series underwent primary resection of the LFCN and have had good results without recurrence.

Considering the preceding reports as well as observations from the present series, it appears that meralgia paresthetica patients who have failed to respond to conservative management can be considered in three subsets:

1. Adults with less than 1 year of symptoms and all pediatric patients should undergo simple decompression.
2. Patients in the first group who have persistent or recurrent symptoms should be considered for resection.
3. Adult patients with symptoms present more than 1 year should be considered for primary resection.

When resection is indicated, the LFCN should be divided several centimeters posterior to the anterior superior iliac spine. This has the advantage of avoiding any scar tissue

from previous decompression surgery and provides a single larger nerve for dissection. In addition, this places the transected nerve trunk in a protected area that is not likely to be stimulated. In my experience the anesthetic area created by resection is well tolerated and tends to shrink during several months.

Previous authors have discussed the anterolateral thigh dysesthesias associated with compression of the LFCN, but there are no previous descriptions of the lower lateral leg pain that was found in four extremities on three patients. In each case, more proximal sources of nerve compression were ruled out and the lower leg pain consistently resolved after LFCN transection. The cause of this lower leg pain and its relation to the LFCN is not clear, but it may be the result of altered body mechanics caused by the discomfort of meralgia paresthetica.

The resected nerve specimens were initially submitted in formalin for standard histopathologic examination, but this generally failed to give significant microscopic information other than to confirm that the specimen was indeed a peripheral nerve. In the past three cases, I have gotten the fresh, unpreserved specimen to a neuropathologist within 1 hour of resection. Ultramicrotomal analysis of these fresh specimens has revealed degenerative changes in the endoneurium, characterized by endoneural Renault bodies with architectural distortion of the endoneurium, phagocytic Schwann cells containing myelin and lipid debris, and endoneural and subperineural fibrosis. Preti² reported cystic nodules involving the nerve. Chipualt and Bellat² reported a nerve involved with varicosities. Hanael³⁶ described an extensive degeneration of the nerve with nodular and concentrically arranged deposits of connective tissue. King²⁵ noted that the axis cylinders could not be identified and the nerve fibers were reduced to nucleated neurolemma cells with shrunken nerve fibers, loss of myelin, and considerable interstitial edema. Bailey² reported microscopic fibrous thickening of the nerve sheath with degenerative changes in many of the fibers. Sougues and Andrae-Thomas² reported the nerve to be grossly and microscopically normal.

CONCLUSION

Meralgia paresthetica remains an obscure diagnosis for many physicians and is frequently overlooked or misdiagnosed. Many of the previous authors have not had the benefit of magnetic resonance imaging or computed tomography, and it is likely that some of the patients reported in the earlier series were actually suffering from discogenic disease or other disorders of the central nervous system. The confusion in diagnosis by some of the earlier authors, plus the fact that many of these authors reported results with very brief follow-up, probably accounts for some of the disagreement concerning the treatment of meralgia paresthetica.

Despite this, meralgia paresthetica is not rare, it is readily recognized, and it responds favorably to adequate treatment.

References

1. Wilson SAK. *Neurology*, 2nd ed. Baltimore: Williams & Wilkins; 1955:369.
2. Lee FC. Meralgia paresthetica. *Int Clin* 1936; 1:210.
3. Rosenheck C. Meralgia paresthetica—its relation to osteoarthritis of the spinal vertebrae. *JAMA* 1925; 85:416.
4. Reichert FL. Meralgia paresthetica; a form of causalgia relieved by interruption of the sympathetic fibers. *Surg Clin North Am* 1933; 13:1443.
5. Sunderland S. *Nerves and Nerve Injuries*. Edinburgh: E & S Livingstone, Ltd; 1968.
6. Piersol GA. *Human Anatomy*, 9th ed. Philadelphia: JB Lippincott; 1930:2104.
7. Keegan JJ, Holyoke EA. Meralgia paresthetica—an anatomical and surgical study. *J Neurosurg* 1962; 13:341.
8. Nathan H. Gangliform enlargement on the lateral cutaneous nerve of the thigh. *J Neurosurg* 1960; 17:843.
9. Ghent WR. Further studies on meralgia paresthetica. *Can Med J* 1961; 85:871.
10. Stookey B. Meralgia paresthetica: etiology and surgical treatment. *JAMA* 1928; 90:1705.
11. Williams PH, Trzil KP. Management of meralgia paresthetica. *J Neurosurg* 1991; 74:76.
12. Pecina M, Kimpotic-Nemanic J, Markiewitz A. *Tunnel Syndromes*. Boca Raton: CRC Press; 1991:105–111.
13. Flowers RS. Meralgia paresthetica—a clue to retroperitoneal malignant tumor. *Am J Surg* 1968; 116:89.
14. Massey EW. Meralgia paresthetica secondary to trauma of bone graft. *J Trauma* 1980; 20:342.
15. Macnichol MF, Thompson WJ. Idiopathic meralgia paresthetica. *Clin Orthop* 1990; 254:270–274.
16. Corbitt JD Jr. Laparoscopic herniorrhaphy: a preperitoneal tension-free approach. Presented at the 2nd International Minimal Access Surgery Symposium, Kansas City, MO, November 21–23, 1992.
17. Arregui ME, Navarrete JL, Davis CJ. Laparoscopic preperitoneal repair of inguino-femoral hernias with large prostheses. Presented at 2nd International Minimal Access Surgery Symposium, 1992.
18. Schneck JM Jr. Meralgia paresthetica: age incidence. *J Nerv Ment Dis* 1947; 105:77.
19. Ecker AD, Woltman HW. Meralgia paresthetica—a report of one hundred and fifty cases. *JAMA* 1938; 110:1650.
20. Aird I. *A Companion in Surgical Studies*. Edinburgh: E & S Livingstone, Ltd.; 1949.
21. Brain RW. *Diseases of the Nervous System*. London: Oxford University Press; 1977:912.
22. Chhuttari PN, Chanla LS, Sharma TD. Meralgia paresthetica. *Acta Neurol Scand* 1966; 42:483–490.
23. Kitchen D, Simpson J. Meralgia paresthetica, a review of sixty-seven patients. *Acta Neurol Scand* 1972; 48:547–555.
24. Huddleson JH. Meralgia paresthetica. *Am J Med Soc* 1928; 175:823.
25. King BB. Meralgia paresthetica—report of five cases. *Am J Surg* 1941; 52:364.
26. Rhodes P. Meralgia paresthetica in pregnancy. *Lancet* 1957; 273:831.
27. Musser J, Sailer J. Meralgia paresthetica (Roth) with the report of ten cases. *J Nerv Ment Dis* 1900; 27:16.
28. Edelson R, Stevens P. Meralgia paresthetica in children. *J Bone Joint Surg [Am]* 1994; 76:993–999.
29. Schiller F. Sigmund Freud's meralgia paresthetica. *Neurology* 1985; 35:557–558.
30. Stevens A, Rosselle N. Sensory nerve conduction velocity of n. cutaneous femoris lateralis. *Electromyography* 1970; 10:397.
31. Sarala PK, Nishihara T, Oh SJ. Meralgia paresthetica: electrophysiologic study. *Arch Phys Med Rehabil* 1979; 60:30.
32. Gateless D, Cucllis P, Ingall J, Mahmud M., Gilroy J. Thermography in meralgia paresthetica. *Neurology* 1983;33(supp 2):128.
33. Lee FC. An osteoplastic neurolysis operation for the cure of meralgia paresthetica. *Ann Surg* 1941; 113:85.
34. Mack WW. Meralgia paresthetica. New causal observations. *West J Surg Obstet Gynecol* 1946; 54:390.
35. Aldrich EF, Van den Heever CM. Suprainguinal ligament approach for surgical treatment of meralgia paresthetica. *J Neurosurg* 1989; 70:492–494.
36. Atkinson FRB. Meralgia paresthetica. *Med Press* 1938; 197:177.