

## Class II major histocompatibility complex (Ia) antigen-bearing dendritic cells within the iris and ciliary body of the rat eye: distribution, phenotype and relation to retinal microglia

P. G. McMENAMIN, I. HOLTHOUSE & P. G. HOLT\* *Department of Anatomy and Human Biology, University of Western Australia, Nedlands, Western Australia and \*Western Australian Research Institute for Child Health, Western Australia*

*Accepted for publication 15 June 1992*

### SUMMARY

The density, distribution and surface phenotype of dendritic cells (DC) and macrophage populations within the ciliary body and iris of Wistar Furth rats were studied by a combination of flat mounting, tangential sectioning, pre-embedding fixation, with single and double immunohistochemical techniques. Monoclonal antibodies included anti-Ia (OX6) and other dendritic cell/macrophage (ED1 and ED8) or mature tissue macrophage markers (ED2). Single and double staining revealed a network (~400 cells/mm<sup>2</sup>) of Ia<sup>+</sup> cells within the epithelium of the ciliary processes with the morphological and surface phenotypic characteristics of DC populations in other tissues. A minor proportion of DC co-expressed ED1 and ED8, but not ED2. In contrast the immunopositive cells in the lamina propria displayed a more generalized phenotype, including ED2 expression, and pleiomorphic morphology suggesting a preponderance of cells of macrophage lineage. Flat mounts of iris revealed a remarkably regular network of Ia<sup>+</sup> DC at a density of 450 cells/mm<sup>2</sup>. The network of DC in the ciliary epithelium terminated at the cilioretinal junction where they formed a continuous syncytium with retinal microglia which did not display Ia staining. The demonstration of networks of cells with relevant morphological and phenotypical properties of professional antigen-presenting cells at strategic locations within the eye has important implications in relation to ocular immune regulation and on the theories of the mechanism of anterior chamber-associated immune deviation (ACAID). Namely, until now it has been assumed that 'immune privilege' in the anterior chamber of the eye is partly a consequence of there being a paucity of class II<sup>+</sup> cells in the surrounding tissues. Dendritic cells in the eye may function as antigen-presenting cells, sampling endogenous and exogenous intraocular antigens and possibly migrating from the eye to draining lymphoid organs (the spleen) where they may generate systemic immune responses. Equally dendritic cells could potentially regulate local immune responses for example in various forms of autoimmune uveoretinal inflammatory disease.

### INTRODUCTION

The phenomenon of anterior chamber-associated immune deviation (ACAID) is well recognized although the mechanism is still not fully resolved.<sup>1,2</sup> A number of factors have been identified which are essential to inducing this form of altered immune response in which cell-mediated effector responses to intracamerally inoculated antigens are impaired. These include (1) the link to the vascular system via the aqueous humour

Abbreviations: ACAID, anterior chamber-associated immune deviation; APC, antigen-presenting cell; DC, dendritic cell; Mφ, macrophage(s); NPCE, non-pigmented ciliary epithelium; PCE, pigmented ciliary epithelium; RPE, retinal pigmented epithelium.

Correspondence: Dr P. G. McMenamin, Dept. of Anatomy and Human Biology, University of Western Australia, Nedlands, WA 6009, Australia.

outflow pathway,<sup>2</sup> (2) an intact and functional spleen,<sup>1</sup> i.e. a camero-splenic axis, and (3) an anatomically intact eye.<sup>3</sup> The apparent paucity of major histocompatibility complex (MHC) class II (Ia)<sup>+</sup> cells in the tissues lining the anterior chamber (inner corneal surface, iris and trabecular meshwork) or those in contact with the aqueous humour (ciliary body and lens) has also been suggested as a necessary condition for the induction of ACAID, and has led to the proposal that such cells may be functionally unimportant in ocular immunity.<sup>4</sup> This view derives from earlier immunohistochemical investigations of class II expression in the tissues of the anterior segment in a variety of species<sup>5-8</sup> which produced varied reports of class II staining of ciliary epithelium,<sup>7</sup> vascular endothelium<sup>8</sup> and only rare or scattered cells within the uveal tract. Furthermore, it has been reported that ACAID may be broken by infiltration of Langerhans' cells into the central cornea<sup>9</sup> or introduction of class II-

bearing cells into the anterior chamber (AC).<sup>10,11</sup> However recent immunohistochemical studies have demonstrated a low/moderate density of Ia<sup>+</sup> dendritiform cells in the rat aqueous humour outflow pathways<sup>12</sup> and a distinct network of Ia<sup>+</sup> dendritiform cells in the mouse iris stroma<sup>13</sup> which would appear to contradict previous studies. In the present investigation we provide confirmatory evidence that cells with the morphological and phenotypical characteristics of DC are present in the iris and ciliary body of the rat eye. Dendritic cells (DC), now recognized as important 'professional' antigen-presenting cells (APC),<sup>14</sup> are noted in other tissues for their capacity to migrate from the site of antigen 'capture', where they form distinct networks in epithelia,<sup>15-19</sup> to the paracortical zones of draining lymphoid organs<sup>14</sup> where they are involved in the inductive phase of T-cell immunity.

In order to elucidate the role of ocular DC populations preliminary data are required on their density, distribution and surface phenotype. In the present study we have used a combination of flat mounting, non-conventional section planes, pre-embedding fixation and immunohistochemical techniques to delineate the nature of DC populations in the epithelium and lamina propria of the ciliary body and iris. A similar approach has been pivotal to our successful demonstration of the intraepithelial DC population in airway tissues.<sup>18,19</sup> In view of reports of the presence in these tissues of significant numbers of cells bearing characteristic macrophage surface markers,<sup>20</sup> we have also performed double colour immunostaining to distinguish Ia<sup>+</sup> macrophages from classical DC.

## MATERIALS AND METHODS

### *Animals*

Female Wistar Furth rats (specific pathogen free) were obtained from the Animal Resource Centre, Murdoch University, Western Australia. Twelve 15-week-old rats were used for single-staining studies. A further three 10-week and six 15-week-old animals were used for double immunohistochemical analysis and iris flat mounts.

### *Monoclonal antibodies (mAb)*

The ED series of mAb against a series of markers on macrophages (M $\phi$ ), DC and other leucocytes<sup>21,22</sup> were kindly supplied by Drs C. D. Dijkstra and G. Kraal (Dept. of Histology, Vrije University, Amsterdam, The Netherlands). ED1 stains a cytoplasmic antigen found in most monocytes and subpopulations of macrophages and dendritic cells: ED2 is a membrane marker restricted to mature tissue macrophages: ED3 stains macrophages in lymphoid tissues and is possibly an activation marker: ED8 marks cell expressing  $\beta$ -chain of CD11/CD18. The mAb OX6 (Ia), OX41, OX42 ( $\beta$ -chain of CD11/CD18) and W3/25 (CD4) were obtained from commercial sources (Serotech, Oxford, U.K.) and have been described in detail elsewhere.<sup>23,24</sup> The mAb supplied as ascites were diluted to optimal levels in phosphate-buffered saline (PBS) (pH 7.4-7.6, 290-320 mOsm).

### *Tissue preparation and immunoperoxidase staining*

The tissue fixation and sectioning method have been described previously.<sup>12,18,19</sup> In summary, the anesthetized animals were perfused with heparinized PBS followed by cold absolute ethanol. This served to both prevent antigen diffusion and to remove all blood (a source of pseudoperoxidase activity) from

the vascular bed. Eyes and lymph nodes were removed and placed in absolute ethanol overnight. This was followed by rehydration and infiltration with a PBS/OCT mixture (Tissue Tek II freezing medium; Miles Laboratories, Elkhart, IN). Tissues were embedded in OCT for cryostat sectioning (10  $\mu$ m). Tangential sections of the eyes were chosen in preference to conventional meridional sections due to the greater numbers of ciliary processes included in each section (cf. Fig. 1a, b) and furthermore some tangential sections contained 'islands' of ciliary epithelial cells cut in the horizontal plane, i.e. parallel to their basement membrane, thus providing an 'en face' or plan view of the epithelium. Lymph nodes were cut in the conventional plane.

Dissected iris and ciliary processes were air dried as whole mounts onto slides for immunostaining.

A standard indirect immunoperoxidase procedure using mouse mAb, biotinylated sheep anti-mouse (SHAM) and streptavidin-horseradish peroxidase (HRPO) (Amersham International, Amersham, U.K.) was used in this study. The HRPO was visualized using 3,3 diaminobenzidine tetrahydrochloride (DAB; Sigma Chemical Co., St Louis, MO) (12 mg/10 ml PBS) and 5  $\mu$ l H<sub>2</sub>O<sub>2</sub> (30% vol/vol). Endogenous peroxidase activity was not blocked as it was found to compromise antigenicity. Cells displaying endogenous peroxidase activity were easily distinguishable, on the basis of morphology and intensity of staining, from immunostained cells. Sections in which the primary mAb was omitted and either PBS or an inappropriate antibody (OKT4—directed against the human CD4 marker) was substituted, acted as negative controls. Positive control tissue was stained in parallel and consisted of lymph node (for all mAb) and conjunctival Langerhans' cells (for Ia staining) within the eye sections. Sections were lightly counterstained with haematoxylin before mounting.

### *Quantitative analysis*

The density of intraepithelial immunopositive staining cells in the ciliary processes (pars plicata) in conjunction with the number of epithelial cell nuclei within delineated areas were recorded using a calibrated eyepiece graticule. Cells staining positively with the panel of mAb were classified as either dendritic-shaped cells (DC) (possessing one, two or more large dendritic processes) or non-dendritic cells (NDC), which were subdivided into irregular (pleiomorphic) or regular (round or ovoid profiles). Five or six fields were counted from at least two sections/animal. Values are expressed as mean number of cells/1000 epithelial nuclei (group means  $\pm$  SEM,  $n=5$ ). For the purposes of comparison to other DC populations the mean number of ciliary epithelial nuclei/mm<sup>2</sup> was calculated using the calibrated eyepiece. Quantitative analysis was performed on immunostained sections from 15-week-old animals.

Immunopositive cells and connective tissue nuclei in the lamina propria were also recorded. It is not possible to convert this to area data as is the case with epithelial monolayers. Equally, due to the disparate densities of nuclei within epithelia and connective tissues a direct comparison between the data generated at these two sites is not considered appropriate. However the lamina propria densities are comparable between adjacent sections treated with the mAb panel.

As a consequence of the vascular perfusion technique very few leucocytes were present in the blood vessels in this tissue.

The density of Ia<sup>+</sup> cells in the iris flat mounts were determined per mm<sup>2</sup>.

#### Double immunohistochemical staining

Double staining was performed on both 'en bloc'-fixed eyes and fresh frozen sections post-fixed in cold ethanol prior to staining. Sections cut as previously described were double stained with OX6/ED1, OX6/ED2 and OX6/ED8 combinations. Sections were double stained using a previously described method.<sup>25</sup> The distribution of OX6/alkaline phosphatase conjugate was visualized as a blue reaction product, while the ED series was a red reaction product (3-amino-9-ethylcarbazole); double-stained cells appeared purple. Slides were mounted in aqueous mounting medium without counterstaining with haematoxylin.

The validity of the double staining was assessed in positive control tissues, namely lymph node and conjunctival epithelium/lamina propria.

#### Qualitative analysis

The staining pattern in areas adjacent to the epithelium of the pars plana were assessed for comparison; however, due to the small areas of the tissues involved, i.e. pars plana epithelium and peripheral retina, quantitative analysis was not considered appropriate. Therefore a qualitative investigation of staining patterns was performed. The density of these cells was scored qualitatively as: +++ (extremely high); ++ (moderate); + (low); ± (rare or occasional); - (absent).

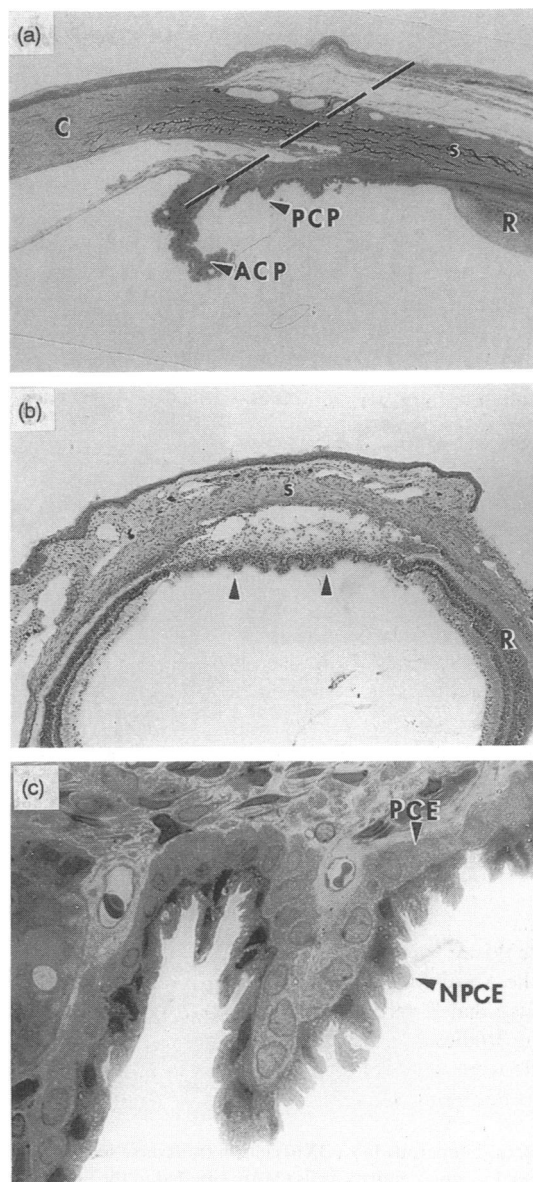
## RESULTS

### The normal morphology of the rat ciliary body

The ciliary body of the eye consists of two regions: the smooth pars plana posteriorly which terminates at the cilioretinal junction and the pars plicata anteriorly which consists of a series of 120 highly folded radiating ridges (0.14–0.17 mm in height), known as ciliary processes (*corona ciliaris*), arranged in a circumferential manner around the globe (Fig. 1a). The ciliary processes consist of a vascular connective tissue stroma, or lamina propria, lined internally by a double layer of epithelium, the innermost (vitread) is the non-pigmented ciliary epithelium (NPCE) and the outer (sclerad) layer consists of the pigmented ciliary epithelium (PCE) (Fig. 1c). Posteriorly, the NPCE is continuous with the neural retina whilst the PCE is continuous with the retinal pigment epithelium (RPE) (Fig. 1a,b). Anteriorly the NPCE is continuous with the posterior epithelium of the iris, whilst the PCE is continuous with the iris dilator muscle. The RPE and PCE are non-pigmented in the albino rat strains used in this investigation. The epithelial lining of the ciliary processes constitute an important component of the blood-aqueous barrier, and is the site of aqueous humour production.

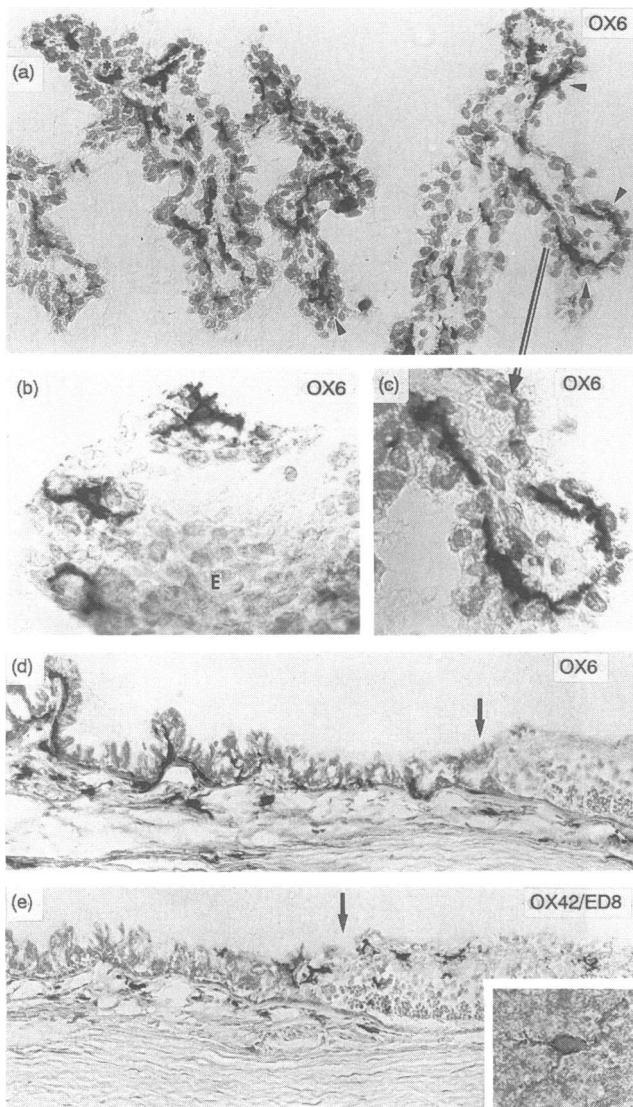
### The density, distribution and phenotype of dendritic cells in the epithelium of the ciliary processes

In conventional meridional sections of the anterior segment the nature of Ia (OX6) staining was difficult to interpret. However in oblique or tangential sections in which several ciliary processes were bisected Ia<sup>+</sup> elongated or bipolar cells were frequently observed between the two layers of epithelium in the ciliary processes (Fig. 2a,c). The intensity of Ia staining was slightly less



**Figure 1.** (a) Conventional meridional section (1  $\mu$ m plastic) of the rat anterior segment. Note the short posterior (PCP) and longer anterior (iridial) ciliary processes (ACP). (b) Low power of tangential frozen section cut approximately in the plane of the dotted line in (a). Note the greater number of ciliary processes ( $\Delta$ ) sectioned using this orientation. (c) High power of ciliary processes showing the pigmented ciliary epithelium (PCE) and non-pigmented ciliary epithelium (NPCE). R, retina; C, cornea; s, sclera. Original magnifications: (a)  $\times 200$ ; (b)  $\times 85$ ; (c)  $\times 800$ .

than the conjunctival Langerhans' cells (not shown). The distribution of Ia<sup>+</sup> cells in the ciliary body closely followed the contours of the ciliary processes (Fig. 2a), however, their true dendritic morphology and regular network pattern of distribution was fully revealed in tangential sections, i.e. section plane parallel to underlying basement membrane thus producing 'en face' or plan views of small 'islands' or sheets of purely ciliary epithelial nuclei (Fig. 2b). The full extent of the cell network was confirmed in examinations of the iris/ciliary body whole mount preparations (not illustrated). The majority of the Ia<sup>+</sup> cells were located between the NPCE and the PCE (Fig. 2c) or at the basal



**Figure 2.** (a) Numerous Ia<sup>+</sup> (OX6) cells in transverse sections of ciliary processes. Ia<sup>+</sup> non-dendritic cells (\*) are situated in the lamina propria of the processes. Note the dendritic-shaped cells following the contours of the lining epithelia (◄) and at higher magnification (c) it is evident that these cells are interposed between the pigmented and non-pigmented epithelium. (b) A tangential section through the ciliary epithelia (E) convincingly demonstrates the dendritic nature of the Ia<sup>+</sup> cells. (d) Meridional section of the pars plana which illustrates the posterior limit of Ia<sup>+</sup> cells at the cilioretinal junction (↓). (e) The same region as in (d) stained with ED8 (identical results for OX42) to illustrate immunopositive retinal microglial cells terminating at the anterior limits of the retina or cilioretinal junction (↓). (Inset) Higher power of OX42<sup>+</sup> retinal microglial cell. Original magnifications: (a) × 415; (b) × 840; (c) × 810; (d) × 110; (e) × 80.

aspect of the PCE. Quantitative analysis (Fig. 3a) reveals that the incidence of Ia<sup>+</sup> dendritic shaped cells was 21.1/1000 epithelial nuclei (equivalent to  $412 \pm 98$  cells/mm<sup>2</sup>).

Immunostaining with the panel of mAb which react with both Mφ and DC revealed a significant number of cells with a dendritic shape which were positive for ED1, OX42 and ED8. Expressed as a proportion of Ia (OX6)<sup>+</sup> cells, these represented

21.3, 9.7 and 17.9% respectively. No dendritic-shaped cells in the epithelium displayed ED2, ED3 or W3/25 staining.

At the conclusion of the above experiments, salient features of the study were repeated employing double colour immunostaining, in order to validate the main conclusions drawn from the results of the single staining obtained above. In particular, cells expressing class II MHC (OX6<sup>+</sup>) were examined for expression of tissue macrophage markers (ED2, classically regarded as a pan-specific macrophage marker)<sup>21,22</sup> and macrophage/DC markers (ED1 and ED8, that are known to stain subpopulations of DC in other tissues).<sup>21,22</sup> The double staining confirmed that ED1<sup>+</sup> cells in the epithelium were rare and few Ia<sup>+</sup> dendritic-shaped cells co-expressed ED1 (<10%). There were low numbers of ED8<sup>+</sup> dendritic-shaped cells within the epithelium. These were remarkably similar to and continuous with the ED8<sup>+</sup> retinal microglia (see below). Only a small fraction (<10%) of Ia<sup>+</sup> dendritic-shaped cells double stained with ED8. No ED2 staining was evident in the ciliary epithelium.

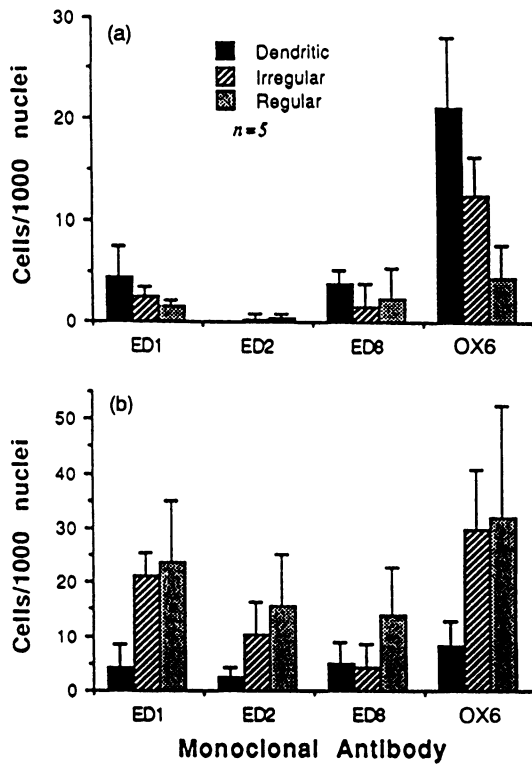
In summary, the double-staining studies confirmed the single-staining observations that a variable proportion of the intraepithelial Ia<sup>+</sup> dendritic-shaped cells expressed ED1 and ED8 but not ED2 which is specific for tissue macrophages. Only a small fraction of dendritic-shaped cells in the epithelium were ED1<sup>+</sup> or ED8<sup>+</sup> but Ia<sup>-</sup>, and thus could possibly be cells of monocyte/macrophage lineage. In conclusion, the single- and double-immunostaining studies indicate that the majority of the dendritic-shaped cells in the ciliary epithelium of the mature rat are morphologically and phenotypically similar to true DC as described in other tissues.<sup>14</sup> In addition the ciliary DC form a network of a similar density ( $\sim 400$ /mm<sup>2</sup>) to other well-recognized DC populations,<sup>14, 19</sup> e.g.  $770 \pm 90$  cells/mm<sup>2</sup> in mouse abdominal skin,<sup>26</sup>  $675\text{--}880$  cells/mm<sup>2</sup> in rat tracheal epithelium,<sup>19</sup> and  $160\text{--}890$  cells/mm<sup>2</sup> in rat oral mucosa.<sup>17</sup>

#### *Non-dendritic cells in the ciliary epithelium*

Single-staining analysis indicated that of the total numbers of Ia<sup>+</sup> cells in the ciliary epithelium in mature animals approximately 33% displayed an irregular morphology while only 12% were regular in shape. Some of these may represent incomplete portions of dendritic-shaped cells. Indeed observations on flat-mounted preparations have confirmed this view. Quantitative data (Fig. 3a) suggest that 25% of the Ia<sup>+</sup> irregular cells may be ED1<sup>+</sup> and around 10% may be OX42 or ED8<sup>+</sup>, i.e. similar proportions to dendritic-shaped cells. The numbers of ED1<sup>+</sup>, ED2<sup>+</sup>, OX42<sup>+</sup> and ED8<sup>+</sup> regular cells expressed as a percentage of Ia<sup>+</sup> cells ( $\sim 32, 8, 26$  and  $50\%$  respectively) was similar to irregular cells. Double staining revealed only a small number (<5%) of non-dendritic cells which co-expressed Ia/ED1 and Ia/ED8 and few were ED1<sup>+</sup> or ED8<sup>+</sup> but Ia<sup>-</sup>, i.e. of monocyte/macrophage lineage or phenotype.

#### **The phenotype of dendritic and non-dendritic cells in the lamina propria of ciliary processes**

Ia<sup>+</sup> DC in the lamina propria were greatly outnumbered by irregular and regular cells (Fig. 3b), which contrasts with the situation in the epithelium (Fig. 3a). The great majority of cells which were positive for ED1, ED2 and ED8 displayed a non-dendritic profile in sections (Fig. 3b) which was strong evidence that the majority of these cells displayed a generalized pheno-

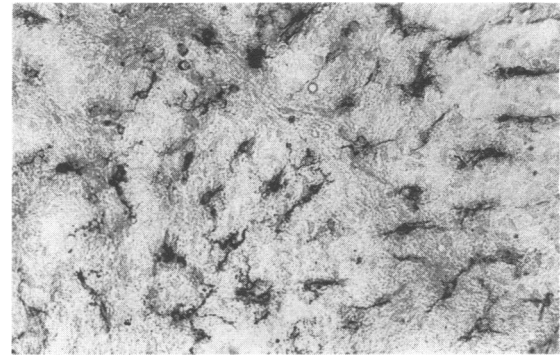


**Figure 3.** Quantitative evaluation of incidence of immunopositive cells in the ciliary body in (a) epithelium and (b) lamina propria. Values are group mean  $\pm$  SEM,  $n=5$ /group.

type and were morphologically similar to tissue macrophages or histocytes. The numbers of ED2<sup>+</sup> cells was particularly notable, as this mAb failed to stain any cells within the ciliary epithelium. Broadly similar staining patterns and morphology were observed in the lamina propria of the conjunctiva. Double-stained preparations confirmed these observations. In summary the cells in the ciliary body lamina propria in contrast to the epithelium were dominated by non-dendritic cells which displayed a more generalized phenotype, including ED2 expression<sup>19</sup> suggesting a preponderance of mature macrophages with possibly some DC precursors.

**Pars plana-retinal junctions: relation of ciliary epithelial DC to retinal microglia**

Ia<sup>+</sup> DC with two to five short stout processes were present between the PCE and NPCE and beneath the PCE of the pars



**Figure 4.** Dendritiform Ia<sup>+</sup> cells in rat iris whole mount. Original magnification  $\times 140$ .

plana (Fig. 2d). Their pseudopodia were observed to interdigitate between adjacent epithelial cells in a similar fashion to those in the ciliary processes. The Ia<sup>+</sup> DC of the pars plana were clearly continuous anteriorly with Ia<sup>+</sup> DC within the epithelium of the ciliary processes and posteriorly they terminated at the pars plana-neural retinal junction (arrow in Fig. 2d,e).

Qualitative evaluations of the density, morphology and phenotype of immunopositive cells were performed and compared to DC in the pars plicata and the retinal microglia (Table 1). The phenotype (OX42<sup>+</sup> and ED8<sup>+</sup>; Ia<sup>-</sup>, ED1<sup>-</sup> and ED2<sup>-</sup>), distribution and dendritic morphology of retinal microglia (Fig. 2e inset) was consistent with previous descriptions of these cells in the mouse and rat.<sup>27</sup> The microglia at the cilioretinal junction were less ramified than those in the remainder of the retina (cf. Fig. 2e to inset), and indeed were similar in form to the Ia<sup>+</sup> cells of the pars plana. Double-staining experiments revealed small numbers of single-stained ED8<sup>+</sup> dendritic-shaped cells, identical to microglia in the pars plana (i.e. the transition between retina and ciliary processes) and even in the most posterior portions of the ciliary processes.

**Iris flat mounts**

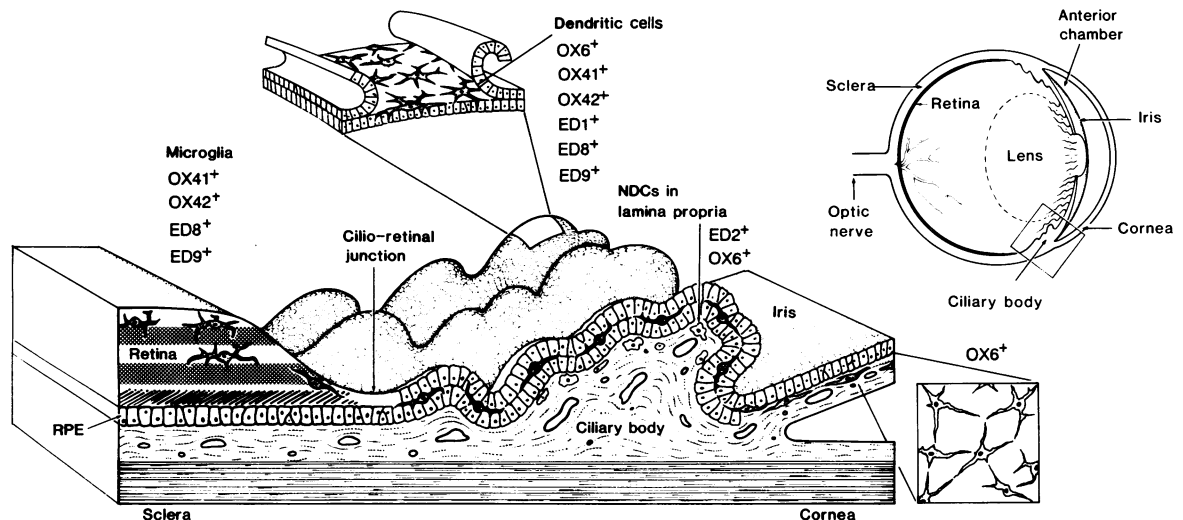
In light of our demonstration of a regular DC network in the ciliary epithelium and the recent report of DC in the mouse iris<sup>13</sup> we performed single immunostaining of flat-mounted rat iris. This technique revealed a remarkably regular network ( $450 \pm 25$  cells/mm<sup>2</sup>, SEM,  $n=5$ ) of Ia<sup>+</sup> DC throughout the iris stroma (Fig. 4).

In summary, using a combination of tangential sectioning

**Table 1.** Qualitative analysis of phenotype of immunopositive cells in the pars plicata, pars plana and retina (microglia)

	OX6		ED1		ED2		OX42		ED8	
	DC	NDC	DC	NDC	DC	NDC	DC	NDC	DC	NDC
Pars plicata epithelium	+++	+	+	+	±	±	+	±	++	±
Pars plana epithelium	+	±	+	±	-	-	+	-	+	-
Retina (microglia)	-	-	-	-	-	-	+	-	++	-

-, absent; ±, rare or occasional; +, low density; ++, moderate density; +++, high density.



**Figure 5.** Diagrammatic summary of the major findings with regard to the phenotype and distribution of dendritic cells and non-dendritic cells in the various tissues of the anterior segment in the rat eye.

planes and flat mounting we have demonstrated a novel network of Ia<sup>+</sup> DC within the ciliary body epithelium and iris stroma of the rat eye at densities of 400–450/mm<sup>2</sup>. These cells displayed morphological and phenotypical features of classical DC populations in other tissues.<sup>15–19</sup> Double immunostaining experiments confirmed that the vast majority of Ia<sup>+</sup> cells in the ciliary epithelium were DC with only a minor population (< 10%) of single staining ED1<sup>+</sup> or ED8<sup>+</sup> cells which could be macrophages. The Ia<sup>+</sup> cells in the lamina propria were generally non-dendritic and displayed a predominantly macrophage phenotype. Those in the pars plana are phenotypically and morphologically identical to those in the epithelium of the ciliary processes. Furthermore our observations would lead us to suggest that the DC of the ciliary body epithelia form a continuous syncytium with the iris DC anteriorly and with the retinal microglial network posteriorly as diagrammatically summarized in Fig. 5.

## DISCUSSION

Class II MHC expression together with pleiomorphic morphology and lack of expression of surface markers which identify mature macrophages are hallmarks of DC,<sup>14</sup> which represent major populations of professional APC in various peripheral tissues and in lymphoid tissues, distinct from cells of the monocyte/macrophage lineage. The vast majority of the Ia immunopositive cells detected within the epithelial covering of the ciliary processes in the present study fulfil both these above criteria and most likely represent a population of functional APC. Despite the current lack of a specific anti-rat DC mAb satisfactory identification can be based on staining with anti-Ia mAb and other Mφ pan-specific mAb in conjunction with demonstration of a dendritic morphology.

Until recently class II MHC (Ia) expression in the tissues lining the anterior chamber was believed to be rare and heterogeneously distributed. Reports of Ia staining were restricted to small numbers of round cells<sup>8</sup> or single scattered cells<sup>5,7</sup> in the human ciliary body and iris stroma, rare, scattered cells in the rat ciliary body,<sup>6</sup> patchy, ill-defined strong staining in the

mouse ciliary body;<sup>28</sup> some reports have additionally noted Ia<sup>+</sup> non-pigmented ciliary epithelial<sup>7</sup> and vascular endothelial cells.<sup>8</sup> Williamson and co-workers<sup>20</sup> reported the isolation of F4/80<sup>+</sup> macrophages, one-third of which were Ia<sup>+</sup>, from the mouse iris and ciliary body stroma; however no morphological details were presented. Therefore none of these previous studies have demonstrated Ia staining in conjunction with dendritic morphology. The failure of previous studies to demonstrate any consistent pattern of Ia immunostaining in ocular tissues such as the ciliary processes is most likely related to factors such as orientation of section plane and inadequate preservation of Ia antigenicity and dendritic morphology. Sectioning parallel to the basement membrane (i.e. to provide 'plan views' of the epithelia) and the pre-embedding fixation protocol used in the present study produces optimum preservation and visualization of the morphology and surface antigenicity of DC. This approach has been crucial to our successful demonstration of intraepithelial DC networks in rat and human airway tissues,<sup>18,19</sup> and DC in the aqueous outflow pathways of the rat eye.<sup>12</sup>

The density of DC in the ciliary epithelium was calculated to be 412 ± 98 cells/mm<sup>2</sup> and 450 ± 25 cells/mm<sup>2</sup> in the iris. These are considerably higher than those sites which classically have been regarded as immunologically privileged, such as hamster cheek pouch (130 ± 25 cells/mm<sup>2</sup>) and mouse tail epidermis

**Table 2.** Comparison of ciliary epithelial DC phenotype with DC populations in other tissues. Densities are expressed as a percentage of total OX6 (Ia)<sup>+</sup> cells

Tissue <sup>Ref</sup>	OX6	OX42	ED1	ED2	ED8	W3/25
Lymph node IDC <sup>28–30</sup>	100	Majority	90	0	50	—
Thymus DC <sup>28–30</sup>	100	Some	91	0	26	—
Airway epithelia <sup>25</sup>	100	25	65	0	16	95
Ciliary epithelia <sup>†</sup>	100	9.7	21.3	0	17.9	0

† Present study.



(110–260 cells/mm<sup>2</sup>).<sup>17</sup> The density of the recently described Ia<sup>+</sup> dendritic cell network in the mouse iris<sup>13</sup> was calculated as 468.5 ± 37.5, a value remarkably similar to the density in the rat ciliary processes and iris in the present study. Thus theoretically these cells appear to be present in sufficient numbers required to produce normal immunological sensitization following exposure to antigen.

Single and double immunohistochemical staining results provide compelling evidence that variable numbers of dendritic-shaped cells within the ciliary epithelium express ED1, ED8 and OX42, which are known to recognize DC subpopulations in other tissue microenvironments<sup>22</sup> as well as cells of macrophage lineage. The density of DC expressing other mAb in the ciliary processes (expressed as a percentage of total Ia<sup>+</sup> cells in single-staining studies) showed a similar pattern to airway epithelial DC with regard to staining with ED8 and OX42 (Table 2) which both recognize the common β-chain of the CD11/18 complex. However only 20% of the DC in the ciliary epithelium were ED1<sup>+</sup> (compared to 65% in airways) and all were W3/25 (CD4)<sup>-</sup>, in contrast to 95% positive staining of DC in airway epithelium.<sup>19</sup> This may reflect different microenvironmental stimuli experienced by ciliary epithelial and airway DC. Cells expressing only pan-macrophage markers were mostly restricted to the lamina propria although occasionally ED8<sup>+</sup>/Ia<sup>-</sup> cells (microglial phenotype) were identified in the ciliary epithelium.

Evidence from sections cut in the meridional, transverse (through the apices or bases of several processes) and tangential planes (passing obliquely through epithelium) together with flat mounts lead us to conclude that the cell bodies of the DC are located between the NPCE and PCE or at the base of the PCE, with fine cytoplasmic processes interdigitating between the PCE cells (Fig. 5). Retinal microglia, which are of monocyte/Mφ lineage,<sup>24,26</sup> become less ramified and less dense as the anterior limitation of the retina is approached. The homologous location and similar dendritic morphology (Fig. 5) suggests that the DC in the ciliary epithelium and retinal microglia are closely related and may form a continuous syncytium in which both the cell types are slightly intermingled at the point of transition—the cilioretinal junction. This sharp alteration in tissue microenvironments may account for the change in phenotype. The potential space between PCE and the inner NPCE is continuous posteriorly with the subretinal space. Dendritiform cells with phagocytic capacity have recently been demonstrated in morphological studies of the peripheral subretinal space/cilioretinal junction during development in human foetal eyes.<sup>30,31</sup>

There are interesting homologies between the macrophage and DC populations of the eye and the brain in the rat. For example the microglial network in the brain parenchyma is phenotypically identical to retinal microglia;<sup>27,32</sup> the subretinal macrophages could be considered comparable to the intraventricular macrophages (supraependymal and epiplexus cells—for review, see ref 33); and there is evidence that the stroma of the choroid plexus in the rat and mouse brain contains a network of dendritiform macrophages which constitutively express class II,<sup>27,34</sup> however, only small numbers of cells staining with an anti-mouse DC marker were identified. The similarities between the choroid plexus and the ciliary body in respect to function (i.e. production of cerebrospinal fluid and aqueous humour respectively) and anatomical configuration (fenestrated capillaries lying beneath epithelial tissue ‘barriers’) would support

the proposal that there are strong homologies between the macrophage and DC populations at these two sites.

It has been generally accepted that the phenomenon of ACAID is due to the ‘immunological privilege’ of the anterior chamber which in turn is a result of a complete or partial lack of class II MHC antigen-bearing cells in the tissues in contact with the circulating aqueous humour or lining the anterior chamber of the eye.<sup>10,35</sup> This tenet may have to be re-examined in light of evidence of networks of Ia<sup>+</sup> DC in the rat ciliary epithelium and iris shown in the present study and recent demonstrations of similar cells within the aqueous humour outflow pathways,<sup>12</sup> and in the mouse iris.<sup>13</sup> The mechanism of ACAID induction is still unclear, although it is known that an intact functional spleen<sup>1</sup> and eye<sup>3</sup> are essential. It has been postulated that antigen-specific signals leave the AC via the outflow pathways to the blood (due to the absence of lymphatics within the eye) and ultimately reach the spleen, where induction of antigen-specific T-suppressor populations occur (hence the term ‘camerosplenic axis’). The implications of the present findings in relation to ocular immune regulation are self-evident. We have demonstrated the presence of a network of cells with relevant morphological and surface phenotypical properties at a strategic location in the eye which would enable them to engage intraocular antigens (e.g. exogenous or autoantigens such as S-antigen). Functional data on their effectiveness as APC are not yet available and is one potential area for future research.

Recently, Wilbanks and Streilein<sup>36</sup> reported that the antigen-specific signal in the mouse ACAID model is borne by blood leucocytes bearing the mature macrophage marker F4/80 (but class II, Thy-1, surface Ig<sup>-</sup>). They postulated that these cells had originated from the eye. In an earlier study<sup>20</sup> these authors had demonstrated that the iris/ciliary body contained F4/80<sup>+</sup> cells in significant numbers (600–700/mm<sup>2</sup>) of which about one-third were class II<sup>+</sup>; however the phenotypical analysis performed was incapable of differentiating macrophages from DC. Cell suspensions from iris/ciliary body have been reported to be incapable of activating allogeneic T cells<sup>4</sup> and thus were assumed to lack APC. However, it is now recognized that DC do not express their APC activity while present in peripheral tissue microenvironments, but function instead as ‘sentinels’ to trap and process antigen.<sup>14</sup> Their APC activity is not revealed until they undergo further maturation, which is presumed to occur *in vivo* only after their migration to lymphoid organs.<sup>37</sup> It is known that F4/80 is expressed on fresh Langerhans’ cells, the dendritic cell population of the epidermis;<sup>38</sup> however these cells are Ia<sup>+</sup> unlike the cells proposed by Wilbanks and Streilein<sup>36</sup> to be transmitting the antigen-specific signal from the mouse eye which would appear to be of the mononuclear phagocyte lineage. Unfortunately to date no information has been presented on the detailed morphological and phenotypical characteristics of these F4/80<sup>+</sup> cells and their exact distribution and density in the mouse ciliary body. In light of our findings it would be particularly useful to know whether they are situated between the ciliary epithelial layers or within the lamina propria where we have discovered cells in the rat with the phenotypical and morphological characteristics of macrophages.

Class II expression by ciliary epithelial cells from a variety of species has been noted *in vivo*<sup>6,39</sup> and *in vitro*<sup>40</sup> following exposure to interferon-γ and during endotoxin-induced inflammation or anterior uveitis.<sup>41,42</sup> Many of these studies have concluded that antigen presentation by ciliary epithelial cells may perpetuate

immune responses in the ciliary body. In light of our findings it must now be recognized that *in vitro* experiments using isolated ciliary epithelial cells most likely contain DC and possibly macrophages which would considerably alter the results in studies of class II expression and the effects of these 'isolated' epithelial cells on T-cell proliferation and activation.

Various factors have been suggested to explain the selective sensitivity of the ciliary body to circulating endotoxins. These include the rich fenestrated capillary bed with high blood flow rates (readily damaged by thrombocyte adherence—leading to cellular infiltration) immediately adjacent to the site of the blood-ocular barrier.<sup>41</sup> Hoekzema *et al.*<sup>42</sup> have recently suggested that aberrant class II expression is secondary to inflammatory cell infiltration in endotoxin-induced uveitis. In light of our findings it is tempting to speculate that the sensitivity of the ciliary body and iris is a consequence of the large numbers of class II<sup>+</sup> dendritic cells and resident macrophages which may act as potential sources of cytokines on exposure to circulating endotoxins. Dendritic cells in the respiratory<sup>19</sup> and alimentary tracts<sup>43</sup> respond rapidly (within 12–24 h) to inflammatory stimuli, such as endotoxins, by increasing their density and rate of passage through the tissue as well as altering their surface phenotype. These changes most likely increase their effectiveness in trapping and processing antigen. Dendritic cells in the anterior uveal tract (iris and ciliary body) probably play an important, but as yet unrecognized, role in the aetiology of anterior and posterior uveitis which are characterized by inflammation of the iris and ciliary body in both clinical and experimental situations. Future studies of iris and ciliary body DC will concentrate on their functional capacity as APC and on the dynamics of this cell population in response to inflammatory stimuli.

#### ACKNOWLEDGMENTS

The authors would like to thank Mrs S. Morrison for technical assistance, and Mr M. Schon-Hegrad and Mrs D. Nelson for assistance with double immunostaining. This study was supported by the National Health and Medical Research Council.

#### REFERENCES

- STREILEIN J.W. & NIEDERKORN J.Y. (1981) Induction of anterior chamber associated immune deviation requires an intact, functional spleen. *J. exp. Med.* **153**, 1058.
- NIEDERKORN J.Y. & STREILEIN J.W. (1982) Induction of anterior chamber-associated immune deviation (ACAID) by allogeneic intraocular tumors does not require splenic metastases. *J. Immunol.* **128**, 2470.
- WILBANKS G.A. & STREILEIN J.W. (1989) Studies on the induction of anterior chamber-associated immune deviation (ACAID). 1. Evidence that antigen-specific, ACAID-inducing, cell-associated signal exists in the peripheral blood. *J. Immunol.* **146**, 2610.
- STREILEIN J.W. & COUSINS, S.W. (1990) Aqueous humor factors and their effect on the immune response in the anterior chamber. *Curr. Eye Res.* **9** (suppl.), 175.
- BAKKER M. & KIJLSTRA A. (1985) The expression of HLA-antigens in the human anterior uvea. *Curr. Eye Res.* **4**, 599.
- HAMEL C.P., DETRICK B. & HOOKS J.J. (1990) Evaluation of Ia expression in the rat ocular tissues following inoculation with interferon-gamma. *Exp. Eye Res.* **50**, 173.
- BAUDOIN C., FREDJ-REYGRABELLET D., GASTAUD P. & LAPALUS P. (1988) HLA DR and DQ distribution in normal ocular structures. *Curr. Eye Res.* **7**, 903.
- LATINA M., FLOTTE T., CREAN E., SHERWOOD M.E. & GRANSTEIN R.D. (1988) Immunohistochemical staining of the human anterior segment. Evidence that resident cells play a role in immunologic responses. *Arch. Ophthalmol.* **106**, 95.
- WILLIAMSON J.S.P., DIMARCO S. & STREILEIN W. (1987) Immunobiology of Langerhans cells on the ocular surface. I. Langerhans cells within the central cornea interfere with induction of anterior chamber-associated immune deviation. *Invest. Ophthalmol. Vis. Sci.* **28**, 1527.
- WILLIAMSON J.S. & STREILEIN J.W. (1989) Induction of delayed hypersensitivity to alloantigens coinjected with Langerhans cells into the anterior chamber of the eye. Abrogation of anterior chamber-associated immune deviation. *Transplantation*, **47**, 519.
- BENSON J.L. & NIEDERKORN J.Y. (1991) The presence of donor-derived class II-positive cells abolishes immune privilege in the anterior chamber of the eye. *Transplantation*, **51**, 834.
- McMENAMIN P.G. & HOLTHOUSE I. (1992) Immunohistochemical characterisation of dendritic cells and macrophages in the aqueous outflow pathways of the rat eye. *Exp. Eye Res.* (in press).
- KNISELY T.L., ANDERSON T.M., SHERWOOD M.E., FLOTTE T.J., ALBERT D.A. & GRANSTEIN R.D. (1991) Morphologic and ultrastructural examination of I-A<sup>+</sup> cells in the murine iris. *Invest. Ophthalmol. vis. Sci.* **32**, 2432.
- STEINMAN R.M. (1991) The dendritic cell system and its role in immunogenicity. *Annu. Rev. Immunol.* **9**, 271.
- GILLETTE T.E., CHANDLER J.W. & GREINER J.V. (1982) Langerhans cells of the ocular surface. *Ophthalmology*, **89**, 700.
- ROWDEN G. (1980) Expression of Ia antigens on Langerhans cells in mice, guinea pigs and man. *J. invest. Dermatol.* **75**, 22.
- AHLFORS E.E., LARSSON P.A. & BERGSTRESSER P.R. (1985) Langerhans cell surface densities in rat oral mucosa and human buccal mucosa. *J. Oral Pathol.* **14**, 390.
- HOLT P.G., SCHON-HEGRAD M.A., PHILLIPS M.J. & McMENAMIN P.G. (1989) Ia-positive dendritic cells form a tightly meshed network within the human airway epithelium. *Clin. exp. Allergy*. **19**, 597.
- SCHON-HEGRAD M.A., OLIVER J., McMENAMIN P.G. & HOLT P.G. (1991) Studies on the density, distribution and surface phenotype of intraepithelial class II MHC (Ia)-bearing dendritic cells (DC) in the conducting airways. *J. exp. Med.* **173**, 1345.
- WILLIAMSON J.S.P., BRADLEY D. & STREILEIN J.W. (1989) Immunoregulatory properties of bone marrow-derived cells in the iris and ciliary body. *Immunology*, **67**, 96.
- DIJKSTRA C.D., DOPP E.A., JOLING P. & KRAAL G. (1985) The heterogeneity of mononuclear phagocytes in lymphoid organs: distinct macrophage subpopulations in the rat recognised by monoclonal antibodies ED1, ED2 and ED3. *Immunology*, **54**, 589.
- DAMOISEAUX J.G., DOPP E.A., NEEFJES J.J., BEELEN R.H.J. & DIJKSTRA C.D. (1989) Heterogeneity of macrophages in the rat evidenced by variability in determinants: two new anti-rat macrophage antibodies against a heterodimer of 160 and 95 kd (CD11/CD18). *J. Leukoc. Biol.* **46**, 556.
- MASON D.W., ARTHUR R.P., DALLMAN M.J., GREEN J.R., SPICKETT G.P. & THOMAS M.L. (1983) Functions of rat T-lymphocyte subsets isolated by means of monoclonal antibodies. *Immunol. Rev.* **74**, 57.
- ROBINSON A.P., WHITE T.M. & MASON D.W. (1986) Macrophage heterogeneity in the rat as delineated by two monoclonal antibodies MRC OX-41 and MRC OX-42, the latter recognizing complement receptor type 3. *Immunology*, **57**, 239.
- CLAASEN E., ADLER L.T. & ADLER F.L. (1986) Double immunocytochemical staining for *in situ* study of allotype distribution during an anti-TNP immune response in chimeric rabbits. *J. Histochem. Cytochem.* **34**, 989.
- BERGSTRESSER P.R., FLETCHER C.R. & STREILEIN J.W. (1980) Surface densities of Langerhans cells in relation to rodent epidermal sites with special immunologic properties. *J. invest. Dermatol.* **74**, 77.



27. PERRY V.H. & GORDON S. (1988) Macrophages and microglia in the nervous system. *Trends Neurosci.* **11**, 273.
28. WANG H., KAPLAN H.J., CHAN W.C. & JOHNSON M. (1987) The distribution and ontogeny of MHC antigens in murine ocular tissue. *Invest. Ophthalmol. vis. Sci.* **28**, 1383.
29. SEDWICK J.D., SCHWENDER S., IMRICH H., DORIES R., BUTCHER G.W. & TER MEULEN V. (1991) Isolation and direct characterisation of resident microglial cells from the normal and inflamed central nervous system. *Proc. natl. Acad. Sci. U.S.A.* **88**, 7438.
30. MCMENAMIN P.G. & LOFFLER K. (1990) Cells resembling intravitreal macrophages are present in the subretinal space of human foetal eyes. *Anat. Rec.* **227**, 245.
31. LOFFLER K. & MCMENAMIN P.G. (1990) Evaluation of subretinal macrophage-like cells in the human foetal eye. *Invest. Ophthalmol. vis. Sci.* **31**, 1628.
32. PERRY V.H. & GORDON S. (1987) Modulation of CD4 antigen on macrophages and microglia in the rat brain. *J. exp. Med.* **166**, 1138.
33. JORDAN F.L. & THOMAS W.E. (1988) Brain macrophages: questions of origin and interrelationship. *Brain Res. Rev.* **13**, 165.
34. MATYSZAK M.K., LAWSON J.L., PERRY V.H. & GORDON S. (1992) Stromal macrophages of the choroid plexus situated at an interface between the brain and peripheral immune system constitutively express MHC class II antigens. *J. Neuroimmunol.* (in press).
35. TOMPSETT E., ABI-HANNA D. & WAKEFIELD D. (1990) Immunological privilege in the eye; a review. *Curr. Eye Res.* **9**, 1141.
36. WILBANKS G.A. & STREILEIN J.W. (1991) Studies on the induction of anterior chamber-associated immune deviation (ACAID). *J. Immunol.* **146**, 2610.
37. SCHULER G.R. & STEINMAN R.M. (1985) Murine epidermal Langerhans cells mature into potent immunostimulatory dendritic cells *in vitro*. *J. exp. Med.* **161**, 526.
38. AUSTYN J.M. (1987) Lymphoid dendritic cells. *Immunology*, **62**, 16.
39. LEE S.F. & POPOSE J.S. (1990) Cellular immune response to Ia induction by intraocular gamma-interferon. *Ophthal. Res.* **22**, 310.
40. HELBIG H., GURLEY R.C., REICHL R.J., MAHDI R., NUSSENBLATT R.B. & PALESTINE A.G. (1990) Induction of MHC class II antigen in cultured bovine ciliary epithelial cells. *Graef. Arch. clin. exp. Ophthalmol.* **288**, 556.
41. OKUMURA A., MOCHIZUKI M., NISHI M. & HERBERT C.P. (1990) Endotoxin-induced uveitis (EIU) in the rat: a study of inflammatory and immunological mechanisms. *Int. Ophthalmol.* **14**, 31.
42. HOEKZEMA R., VERHAGEN C., VAN HAREN M. & KIJLSTRA A. (1992) Endotoxin-induced uveitis in the rat. The significance of intraocular interleukin-6. *Invest. Ophthalmol. vis. Sci.* **33**, 532.
43. MACPHERSON G.G., FOSSUM S. & HARRISON B. (1989) Properties of lymph borne (veiled) dendritic cells in culture. II. Expression of IL-2 receptor: role of GM-CSF. *Immunology*, **68**, 108.