

CHRONIC PHAGEDÆNA DUE TO MIXED
INFECTION.¹

By H. R. LOUX, M.D.,

OF PHILADELPHIA,

CHIEF CLINICAL ASSISTANT, GENITO-URINARY DEPARTMENT OF THE JEFFERSON
MEDICAL COLLEGE HOSPITAL,

AND

W. M. L. COPLIN, M.D.,

OF PHILADELPHIA,

PROFESSOR OF PATHOLOGY AND BACTERIOLOGY, JEFFERSON MEDICAL COLLEGE;
DIRECTOR OF THE LABORATORIES OF THE JEFFERSON
MEDICAL COLLEGE HOSPITAL.

HISTORY OF CASE BY DR. LOUX.—J. B. McC.; aged twenty-five years; occupation, dentist; nativity, England.

Family History.—One sister died at the age of nineteen from diabetes; father is suffering from gall-stones; other than this the family history is negative.

Personal History.—Patient denied ever having chancre or chancroid. He states that at the age of sixteen years he contracted gonorrhœa, which was followed by stricture, and was treated by gradual dilatation. There was a tendency to recontract (apparently from the history of the case of resilient stricture), so much so that the patient was trained to pass his own instrument, and was instructed to do so, with the view of preventing a stricture of small calibre. He further states that there was ever present at the meatus a slight discharge of a mucopurulent character, and, as the discharge had never been examined microscopically, its character and the contained flora are not known.

Whenever the patient indulged freely in the use of alcoholic liquors, he would suffer with retention of urine, requiring catheterization.

¹ From the Laboratories of the Jefferson Medical College Hospital. Read before the Philadelphia Academy of Surgery, December 2, 1901.

Present History.—In January, 1901, after a night's debauch (followed by retention of urine), the patient attempted to catheterize himself, using considerable force. In the attempt he broke the catheter about one inch behind the meatus, causing a free hæmorrhage. Following this trauma to the urethra (discovered two weeks afterwards), a hard induration on the floor of the urethra appeared one inch behind the meatus; the nodule rapidly increased in size. It developed into a periurethral abscess, rupturing externally. He now consulted a surgeon, who incised the abscess freely, followed by irrigation and the usual antiseptic precautions. He further states that under this careful treatment he noticed a rapid destruction of the surrounding parts and a communication into the urethra. He was then advised to remain in the hospital, but this he refused to do.

I saw the case in consultation for the first time on February 20, 1901. The tissue on the under surface of the penis (from the frænum back one and a half inches) was destroyed apparently through a phagedænic process, involving the skin, subcutaneous tissue, and floor of urethra, including the corpus spongiosum; the skin showed the greatest resistance to the necrotic process, since the destruction extended well underneath the overlying skin, which was irregular along the edges.

The base of the diseased area was markedly indurated, not limited, but was gradually lost in the surrounding tissues, resembling the œdematous infiltration of chancroid.

On examining the urethra I found two strictures,—the first was a filiform stricture about three and a half inches from the meatus, and the second was at the bulbomembranous junction.

On March 6 I operated upon the strictures, doing an internal urethrotomy on the anterior stricture and a modified rapid dilatation on the posterior one, with continuous drainage of the bladder with a soft catheter. At the same time I curetted the necrotic area, cutting away the diseased overlying edges of skin, followed by a free application of carbolic acid to the diseased surface. Unfortunately, this did not control the phagedæna. I then decided to drain the bladder through the perineum, using a Watson tube, and attempted a plastic operation on the penis, which was done a few days after the perineal drainage was established. The plastic operation was done with great precaution, first cauterizing the surface of the ulcer, which was then removed,

including the adjacent induration; a second set of instruments was used for the plastic work, which consisted in making a new urethra and covering the same and adjacent denuded area with skin flaps taken from the side of the penis. The operation was followed by primary union. The perineal tube was removed, the sinus closed, and the patient was discharged from the hospital April 2 as cured.

On April 25 the patient returned to my office with a recurrence in the right skin flap at the junction of the glans penis. The patient was placed in the hospital, and the ulcer excised by an elliptical incision, including a portion of the corona of the glans penis; the edges were brought together with a few stitches, followed by primary union. At the same time it was noticed that the corresponding left skin flap was becoming indurated, with a tendency to break down along the edges. So rapid was the destruction of the skin and deeper structures that any further operative procedure was abandoned.

An attempt was now made to control the phagedæna with the Paquelin cautery, but without any result. We then tried an application of formalin, 20 per cent. solution, which seemed to check for a short period the rapid progress of the disease. New areas then became involved; there was already much of the penis destroyed, as shown by the plate (Fig. 1), and we decided to amputate the penis at the penoscrotal junction. After his return to the hospital, it was noticed that one superficial inguinal gland on the right side was enlarged about the size of a hazel-nut; this gland showed a tendency to break down.

On September 6 the amputation of the penis was performed, and at the same time the broken-down gland of the right groin was removed; both wounds recovered primarily. There has been no recurrence of the disease to the stump of penis, but a marked recurrence in the right groin, destroying skin and superficial tissue about three and a half inches long and two inches wide. On November 6 the ulcerated area was thoroughly curetted, the diseased areas of the skin cut away, and the entire surface of the ulcer wiped out with pure nitric acid. The wound granulated, and the patient was discharged from the hospital on November 30 as cured.

PATHOLOGIC REPORT BY DR. COPLIN.—The first material for examination in this case consisted of ‘A,’ Inoculations on vari-

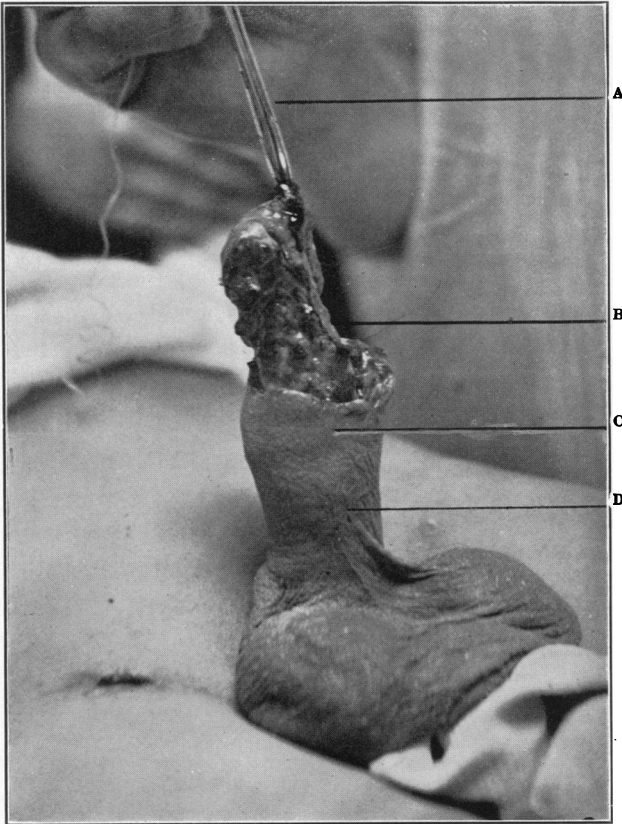


FIG. 1.—Phagedæna of the Penis. Photograph before operation. (Case reported by Dr. Loux and Dr. Coplin.) A, Hæmostat by which organ is extended. B, Fibrous septum marking superior margin of corpus spongiosum. Just below the leader from B is seen the necrosing end of the spongy body. C, The undermining extended down to about this line; at points, *e.g.*, around the urethra, the subcutaneous necrosis extended somewhat deeper. From C to D is the zone of induration. The amputation line was about the point marked by the leader from D.

ous media; "B," Material for spreads; "C," Fragment of tissue; all from penis.

The following is a summary of the result of the examination made by Dr. R. C. Rosenberger:

"A." Inoculations were made from the material upon glucose agar, bouillon, and liquid blood serum. Incubated for forty-eight hours, a growth was demonstrable in the glucose and urine agar. After incubation for this period, cultures were made and placed in an anaërobic condition. These cultures may be dismissed at this point, as they yielded no information not obtained by the aërobic method.

Upon urine agar there developed small, pinhead-sized colonies, yellowish in color, granular in appearance, and more or less discrete.

Spreads made from these growths and stained by the ordinary methods contain cocci .9 micron in diameter, occurring in pairs, grouped and ungrouped. Some of the pairs consist of cocci with flattened sides in apposition. They retain the dye when treated by Gram's method.

In glucose agar the growth follows the stab, and is also seen upon the surface; it is of a golden yellow color.

Spreads made and stained by ordinary methods show the same organisms described above as found in urine agar, and possessing the same morphologic and tinctorial properties.

The tubes of bouillon and serum showed a growth in seventy-two hours. Each medium was clouded, and a delicate, easily broken-up pellicle formed upon the surface.

Spreads were made and stained by ordinary methods. Upon microscopic examination two organisms were seen,—a bacillus and a coccus. The bacillus was slender, 1 micron to 3 microns in length, and .4 micron in thickness, and occurred in groups, short filaments, and ungrouped. It decolorized when treated by Gram's method.

The coccus measured .9 micron in diameter, occurring in small groups and presenting the morphologic and tinctorial characters of the staphylococci of suppuration. Plates were made, and after isolation of the organisms the bacillus was inoculated into milk, gelatin, and upon potato and other test media. Upon these different media the bacillus yielded the reactions common to organisms of the colon group,—generating a small quantity of

gas, turning blue litmus red, growing with a brownish color upon potato, etc. The coccus is evidently the *Micrococcus pyogenes aureus*.

Inoculations from fresh material were also made subcutaneously into the ears of a rabbit. In seventy-two hours there was noticed swelling and redness around the site of inoculation, followed by pus formation.

Inoculations made upon plain and glycerin agar from the pus showed in forty-eight hours a pure culture of the *Micrococcus pyogenes aureus*.

Spreads made from the pus and stained by ordinary methods for bacteria contain a few polynuclear leucocytes, granular detritus, and shreds of fibrin. A few micrococci are seen, .9 micron in diameter, occurring principally ungrouped and retaining the stain when treated by Gram's method. No bacilli were demonstrable.

In six days the inflammation in the inoculated ear subsided, and since that time the animal has remained apparently healthy.

"B." Spreads made and stained by ordinary methods show numerous polymorphonuclear leucocytes and a few lymphocytes. Numerous cocci are seen, some of which are .9 micron in diameter, occurring in small groups, but mostly ungrouped. A few are found within the cells; they retain the dye when treated by Gram's method. An occasional bacillus is seen which measures 3 microns to 4 microns in length, with rounded ends and occurring extracellular. The cocci resemble the micrococci of suppuration. The bacillus was not obtained in culture, but from its morphology resembles the *Bacillus subtilis*, probably a contaminating organism, and having no bearing upon the suppurative process.

"C." The specimen consists of a small, irregular wedge-shaped mass of tissue, .7 centimetre in its greatest, .5 centimetre in its shortest diameter, and .3 centimetre in thickness. It is of a pinkish color and the surfaces are irregular and rough.

Specimen was fixed in a saturated alcoholic solution of bichloride of mercury, and embedded in paraffin; sections were cut and stained by the usual laboratory methods.

Histologic Examinations.—One surface of the section is nearly covered by stratified squamous epithelial cells. In the middle portion of the surface the epithelial cells have entirely disappeared, or rather been converted into a mass of necrotic and

richly granular *débris*. Beneath the necrotic surface a moderate degree of tissue reaction is present. The cells found here are for the most part polynuclear leucocytes, although lymphoid and spindle-shaped cells are also present in abundance. A few mast-cells are also noticeable in the sections stained with toluidin blue. Beneath the surface the mass is made up mostly of a delicate, connective-tissue reticulum. Throughout this latter tissue abundant new and newly-forming capillaries are present; some of these contain a few erythrocytes, others a few leucocytes, and still others are comparatively empty. At points a large number of polymorphonuclear leucocytes and wavy spindle-shaped cells are seen, together with a few mast-cells.

The lower surface of the mass shows a few areas of necrotic tissue, throughout which are scattered a few polymorphonuclear leucocytes.

A number of sections were stained with Löffler's methylene blue and by Gram's method.

In the preparation stained with Löffler's methylene blue a large number of bacilli and cocci are seen. Most of the bacilli are thin, 1.5 microns in length, and occur in groups and in short filaments. Where a few are seen in a field a tendency to polar staining can be recognized. This latter feature is not seen in all the bacilli. The bacilli are situated generally between the cells, though some can be seen within the cells. They do not stain by Gram's method. A second organism is a large bacillus, 3 microns to 4 microns in length, with rounded ends, occurring mostly individually.

The cocci mentioned are .9 micron in diameter, and occur principally in pairs, with their flat sides in apposition. They retain the dye when treated by Gram's method and are intra- and extra-cellular. A few other cocci are seen that are slightly smaller than those just mentioned, but possess the same peculiarities as to situation and staining reaction.

All the bacteria mentioned above are scattered through the specimen. They are most abundant deep in the tissue, although some (bacilli and cocci) are found in the most superficial layers of the necrotic epithelial cells. The small bacillus referred to resembles very closely the bacillus of Ducrey, both morphologically and tinctorially. Every peculiarity of the bacillus, however, is not present, but the size, situation, and staining properties sug-

gest this probability very strongly. The cocci are undoubtedly the ordinary micrococci of suppuration.

Diagnosis.—"A." Inoculations upon glucose and urine agar. Pure culture of the *Staphylococcus pyogenes aureus*. Inoculations in bouillon and liquid serum, a bacillus probably of the colon group and the *Staphylococcus pyogenes aureus*.

"B." The spreads contain cocci possessing the usual mor-

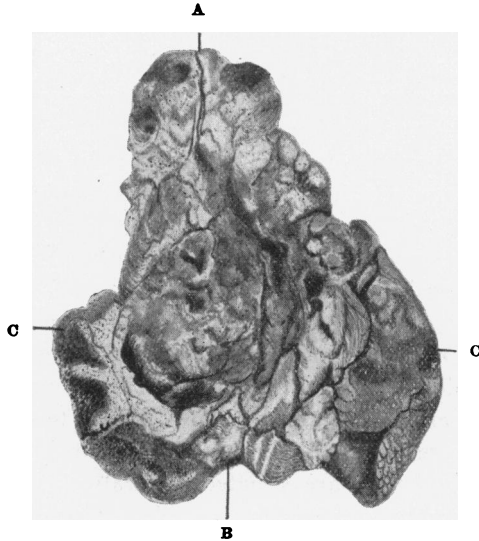


FIG. 2.—Penis after amputation; inferior surface. Natural size. (Case reported by Dr. Loux and Dr. Coplin.) A, Fissured ulcer marking area of urethra beneath the glans. B, Urethra at point of amputation; laid open. C C, Undermined skin incised on inferior surface and turned back (dorsalwards) in order to indicate the extent of the undermining. Just below the leaders from C C the intense induration is indicated.

phology and tinctorial reactions of the micrococci of suppuration.

"C." The tissue shows a widely destructive inflammation, the necrosis being of the liquefaction type. Bacteria are present in abundance; one of the organisms present cannot be differentiated from the bacillus described by Ducrey; it is not our intention, however, to insist upon the identity of the germ found with the microbe described by that observer. The histology of the tissue excludes malignant disease. At the time of this examina-

tion tuberculosis was not suspected, even after most careful search for the bacillus as well as close study of the histology of tissue submitted.

Result of the examination of the amputated penis. The specimen delivered to the laboratory consists of an irregular cylindrical mass of tissue measuring 8 centimetres in length. (Fig. 2.) One end of the cylinder is surrounded by skin, which at the extreme end is normal in appearance. This end measures 3.5 centimetres in diameter, and evidently corresponds to the line of amputation. The corpora cavernosa are somewhat retracted below the surface and appear slightly denser than normal, the right being somewhat more resistant than the left. The spongy body—*corpus spongiosum*—is inconspicuous, but the urethra can readily be identified in its centre. The subcutaneous tissue and the tunica albuginea present nothing noteworthy. Upon laying the urethra open, it is found that its length does not exceed 0.5 centimetre. Its mucous membrane at the line of incision is apparently normal, but at the external opening is ragged and ulcerated and undermined to within 0.3 centimetre of the line of incision. The width of the band of attached skin varies; at its widest point it is 4.5 centimetres, and at its narrowest point a little less than 2 centimetres. As already stated, the skin is normal along the line of incision. The free margin of the skin is ulcerated, ragged, undermined, and presents areas of superficial necrosis which extend from 5 to 20 millimetres from the free margin of the ulcer upward and backward upon the otherwise normal skin. The free margin of this ulcerated portion is slightly indurated, the amount of induration varying in different areas. At all points the margin is undermined, and in the neighborhood of the urethra the undermining at one point extends 2.5 centimetres. The urethra for a distance of about 4.5 centimetres has been entirely destroyed, and with it practically all of the spongy body. The glans has been for the most part destroyed. The remaining portion of the glans measures 3 centimetres by 2 centimetres. The superior surface of the glans (all the remaining portion) is covered by a wrinkled mucosa, the margin of which forms the ragged, indurated, and necrotic edge of the ulcer. There is but little undermining of the mucosa. The surface of the ulceration is beset with minute granules and covered by a grayish pellicle which can be removed with very little manipulation. The ulcerated portion is somewhat indurated, the degree

of induration varies in different parts, but is usually more marked near the margins of the ulcer.

Small masses were cut from different areas, fixed, dehydrated, and embedded in paraffin.

Sections cut from the region of the glans show the specimen to be covered by stratified squamous epithelial cells. Beneath the epithelium is a quantity of loose connective tissue and a few bundles of non-striated muscle.

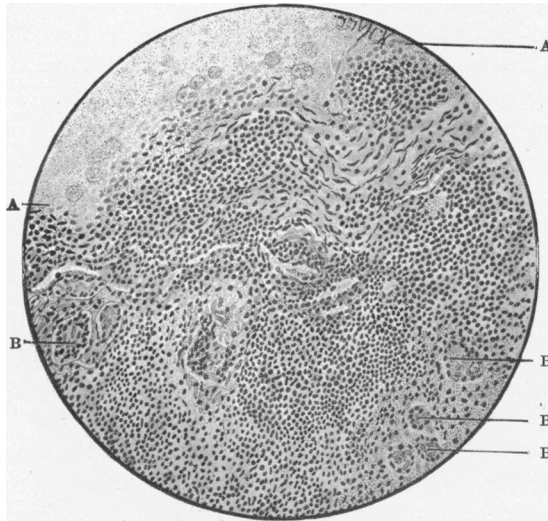


FIG. 3.—Section of floor of ulcer, case of chronic phagedæna. (Reported by Dr. Loux and Dr. Coplin.) A, A, The area between these two points is superficial and composed of the tissue undergoing liquefaction necrosis. Aside from the contained granules, a few granular and necrotic cells showing fragmentation and karyolysis are also present. B, B, B, B, Giant cells; other giant cells are also seen at several points in the field. Lymphoid cells are abundant throughout the field, and just above the centre and to the right are a number of fibroblasts. No area of caseation is present in this field.

Sections taken from the dorsum of the penis (Fig. 3) show it to be covered by stratified squamous epithelium upon one surface. Beneath this epithelial layer is a large quantity of rather dense connective tissue and non-striated muscle. Here and there can be seen accumulations of small round cells, polymorphonuclear leucocytes, a few epithelioid cells, and giant cells,—distinctly suggestive of tubercles.

They are for the most part discrete, but in one or two areas

a beginning coalescence of two tubercle-like agminations can be detected. Beginning caseation is also noticeable in other areas.

Sections taken from the region of the urethra show the mass to consist almost wholly of granulation tissue. The lining epithelium of the urethra is in some parts destroyed and encroached upon by the granulation tissue. No well marked tubercles are seen in these sections, but a few giant cells are scattered throughout. The sections were also stained for bacteria, and especially for the tubercle bacillus.

Upon examination of sections stained with Löffler's methylene blue, in the blood-vessels, intracellular and scattered irregularly through the tissue, numberless bacilli were demonstrable.

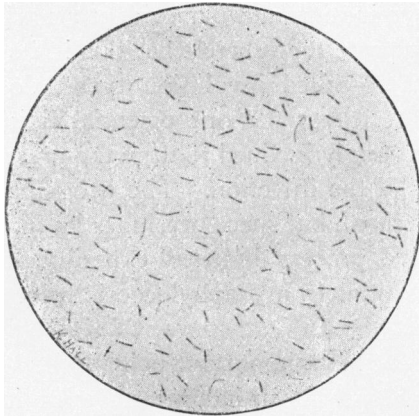


FIG. 4.—Bacillus of soft chancre (Ducrey). The irregular staining of the organism and variations in morphology are well shown. From section stained with methylene blue. Zeiss 2 mm. homo. im., projection eyepiece No. 2.

They average 1.5 microns in length, possess rounded ends, and exhibit polar staining. They do not retain the dye when treated by Gram's method. (These bacilli are similar to the organisms met with in sections from the same case made some time before, and which were then thought to be the bacilli of Ducrey.) A few cocci were also seen. No tubercle bacilli nor any other acid resisting bacilli were demonstrable.

The tissue removed from the groin was not examined; it was ordered sent to the laboratory, but was not delivered in a condition permitting examination.

Diagnosis and Remarks.—The process is clearly not a simple one. The profound tissue alterations are evidently the

result of a violent infection, mixed in character, and rapidly extending; a careful histologic study fails to show satisfactory evidence that the tissues are making any efficient effort to limit the spread of the bacteria. Not only do the bacterial findings clearly show the existence of a mixed infection, but the histology discloses the presence of two forms of necrosis occurring separately and only together in the sense that one may be consecutive to the other, a view not supported by a study of the sections. The liquefaction necrosis is evident superficially, restricted to the skin and outer layer of granulation tissue, while the caseation is present at or near the areas of giant cell agmination and not evident elsewhere. Our inability to demonstrate the tubercle bacillus in its usual form, or in some of its so-called involution types, does not exclude tuberculosis, but leaves the one essential link missing; personally, I am strongly inclined to urge the presence of tuberculosis as a part of the infection. The pyogenic infection is of course demonstrated, but space precludes its further discussion. The suppurative process induced experimentally seemed to differ in no essential from staphylococcal infections frequently seen.

Probably the most important point to be settled, if settled it can be, is whether the fundamental lesion in this case was chancroidal; should we accept the bacillus of Ducrey as the cause of soft chancre, then the bacteriologic findings are to be weighed against the clinical aspects of the case. If the clinicians decide that the lesion is not chancroid, then the bacteriologic finding is of still greater import, as I think we have demonstrated the presence of an organism that at least cannot be differentiated from the bacillus in question if it be another germ.

The bacillus of Ducrey¹ (Fig. 4) is given by Cornil and Ranvier² as the cause of chancroid. After the appearance of the papers by Krefling³ and Unna,⁴ I sectioned a number of soft chancres and studied the pus from others. I was greatly impressed with the constancy of the organism, although occasionally I examined lesions, clinically thought to be typical instances of chancroid, in which the organism

could not be found. Since that time, Peterson,⁵ Nicolle,⁶ Istamanoff and Akspiantz,⁷ Leuglet,⁸ F. Bezançon, V. Griffon, and Le Sovrd,⁹ and others have done much to establish the specificity of the organism described by Ducrey. Nicolle maintains the value of finding the organism as a test differentiation from the initial lesion of syphilis.

If the writers quoted, and others that could be mentioned, are correct in their view, then the case is one of chancroid running an unusually lengthy course and with an unusual destruction of tissue. Although, as already stated, we have failed to demonstrate the tubercle bacillus, I cannot ignore the histologic picture quite faithfully portrayed in some of the sections. Admitting the doubtful points, this lesion would be regarded as a manifestation of (1) staphylococcic infection, (2) infection by the colon bacillus, (3) infection by the streptobacillus of Ducrey, and (4) tuberculosis, the morbid processes not necessarily occurring in the order given.

[NOTE.—Since the foregoing report was submitted there have been no recurrences at points of previous operations. About the middle of February, 1902, the left epididymis became tender and slightly enlarged, and rapidly increased in size. On March 4, Dr. Loux removed the left testicle with the cord as far as the left external ring; although the examination is not as yet completed, it is sufficiently advanced fully to establish the diagnosis, and proves the testicular enlargement to be due to an acute, rather disseminated tuberculosis involving both the globus major and globus minor.

In the light of the added information, the conclusion previously reached, that the condition was primarily either chancroidal or septic, the probabilities favoring the former, and that upon the initial infection was engrafted tuberculosis, seems to be thoroughly established.]

REFERENCES.

- ¹ Monatsheft für praktische Dermatologie, ix, 1899.
- ² Manuel d'Histologie, 1901, Tome i, p. 676.
- ³ Archiv für Dermatologie, 1892, p. 41.
- ⁴ Monatsheft für praktische Dermatologie, xiv, 1892.
- ⁵ Centralblatt für Bakt., xiii, 1893.
- ⁶ Thèse de Paris, 1893.
- ⁷ Société Méd. du Cancase, 1897.
- ⁸ Société de Dermatol., 1898.
- ⁹ La Presse Médicale, December 12, 1900.