

## TOOTH GERM CYSTS OF THE JAW

BY M. G. WOHL, M.D.

OF OMAHA, NEBRASKA

(From the Pathological Department of the Nicholas Senn Hospital and the Clinical Laboratory of Frank J. Hall, Kansas City, Mo.)

THE subject of cystic tumors of the jaw has been considered quite extensively by Bland Sutton,<sup>1</sup> Kaufmann,<sup>2</sup> Bloodgood,<sup>3</sup> Scudder,<sup>4</sup> and others. The conventional terms applied to these cysts are, in our estimation, inadequate and misleading, since they neither designate the origin nor describe the clinical character of the tumor.

We shall, therefore, divide the cystic tumors of the jaw into, (*A*) inflammatory cysts, (*B*) tooth germ or chorioblastomatous\* cysts. The cysts of class *A*, generally called dental and root cysts, will not be considered in this paper because they do not originate in the embryonal epithelial remnants of the enamel organ as claimed by Magitot.<sup>6</sup> We fully agree with Partch<sup>7</sup> that these cysts are of inflammatory nature. Whether or not the wall of the cysts is lined by epithelium, as described by Turner,<sup>8</sup> is immaterial. Suffice it to state, they invariably originate in a periodontitis, as a result of which a granuloma forms. With softening and breaking down in the centre of the granuloma, a cyst follows. Should there by chance be present remnants of the epithelial cord of the enamel organ, they will become included in the granuloma, and this undoubtedly accounts for the epithelial lining of some of these cysts, the prime cause of which is, however, an inflammatory process.

The true tooth-germ cystic tumors that we have put into class *B* are divided into the (*a*) unilocular cyst, commonly known as the dentigerous or follicular cyst; and (*b*) multilocular cyst, conventionally designated as adamantine epithelioma, multilocular dentigerous cyst; and (*c*) the solid tumor.

These cysts of the jaw are rather of infrequent occurrence. We have been able to collect for our study six cases of this type; three cases from the surgical material of Dr. A. P. Condon, Nicholas Senn Hospital, and three cases from the material of Dr. Frank J. Hall of

---

\* By the term Chorioblastoma, Albrecht<sup>5</sup> designates all tumors that are derived from embryonal rests.

## TOOTH GERM CYSTS OF THE JAW

Kansas City, Missouri. (I wish to express my thanks to these men, not only for access to their material, but also for much kindly advice and criticism.)

These cases form the basis of the present writing.

The embryonal cysts have a positive relationship to that part of the epithelial cord that does not enter into formation of the enamel organ, the "*débris épithéliaux paradentaires*" of Malassez.<sup>9</sup> This view, originally proposed by Falkson<sup>10</sup> and later confirmed by Malassez,<sup>11</sup> Kruse,<sup>12</sup> and others, is undoubtedly the correct one. However, there are some who deny the embryonal origin of these tumors. Bland Sutton<sup>13</sup> and his school believe that the multilocular cysts originate from the oral mucous membrane, for were they derived from embryonic enamel organ, they would have occurred at an earlier period. This argument against the embryonal theory of the cysts, we believe, is not well founded, for other tumors that arise from aberrant embryonal tissue, *e.g.*, hypernephroma, occur in persons past middle life and not necessarily in youth. Again the histopathology of the tumor speaks against the above assumption, as it will be described below in one of our cases that there was a distinct formation of dentin, which property can hardly be ascribed to the oral mucous membrane (Fig. 8). That these tumors are not endotheliomas will be pointed out in the differential diagnosis. That both the unilocular and multilocular cysts originate from one and the same source is evident from their concomitant occurrence; and, as it will be mentioned in one of our cases, one half of the cyst presented the picture of a unilocular cyst while the other half that of a multilocular (Fig. 5).

Our case of simple unilocular cyst had a distinct adamantine epithelial lining which strengthens this assumption (Fig. 2). Barrie<sup>14</sup> has described a similar case of unilocular cyst with an adamantine lining. Why in one instance aberrant epithelium will form teeth and a unilocular cyst, and in another a multilocular with more solid parts, is difficult to explain. One finds a similar condition in the ovarian cystoma; where, in one case, there is a simple, smooth-walled cyst, and in another, or, very frequently, in parts of the same cyst, a marked proliferation of epithelial lining, with the formation of well-sized solid masses, which may completely fill out the greater part of the cyst.

The recent anatomical work of Cryer<sup>15</sup> upon the mandible as a possible explanation for the multilocular character of these cysts will be touched upon later.

The course of development of the unilocular cyst is well illustrated by the following case:

CASE I.—Mrs. T. S., aged twenty-three, was operated upon at the Nicholas Senn Hospital, February 18, 1913. She had a swelling that she had noticed for six months in the left lower jaw, back of the second molar tooth, and a constant dull pain for the past few weeks.

An incision was made over the swelling from within the mouth and the bony wall of the cyst was chiseled away, a tooth removed from the depth of the cyst, and a lining membrane, about 2 to 4 mm. in thickness, was peeled out of the cystic cavity. She left the hospital well on March 1st. No recurrence was reported (Fig. 1).

*Pathological Report.*—Size of the cyst is twice that of a large olive; cyst contains a thick, colloid-like material, blood-tinged. The walls of the cyst are thickened, and at the bottom there is lying free in the cavity a molar tooth, which appears to be well developed.

*Microscopical Report.*—The wall of the cyst consists of connective tissue stroma containing many blood-vessels. The inner surface of the wall is lined by a layer of epithelium of adamantine type. The basal cells have a spindle nucleus; the cells nearer the superficial surface show the stellate adamantine form which conveys the impression of mucoid tissue (Fig. 2).

The unilocular cysts may occur at any age. Brophy<sup>16</sup> has seen only 12 cases of such cysts associated with deciduous teeth. They are found more frequently, however, during, or after, second dentition; rarely after 30 years. The usual seat of their location is the region of wisdom or bicuspid teeth, which fail to erupt. Both jaws are affected with equal frequency. The tumor is benign in character and runs a long course. The prognosis in these cases is good, as no recurrence follows after a complete excision of the cyst.

The multilocular chorioblastomatous cyst of the jaw is of less frequent occurrence than the unilocular. Lewis<sup>17</sup> has collected 70 cases from the literature. Since then, New<sup>18</sup> has added 8 more cases. With the report of 4 of our cases of this type, the total would be 82 cases. By far the most common seat of involvement is the molar region of the lower jaw. Only in 9 instances have they occurred in the upper jaw (New). In our series the seat of involvement in one instance was the upper jaw and three occurred in the lower jaw. Although Massin<sup>19</sup> has described the occurrence of such a tumor in a new-born infant, and Coats<sup>20</sup> observed one in a child 5 months old, yet the age at which they commonly occur is between 20 and 40 years. The oldest case on record was 75 years old (Lewis).

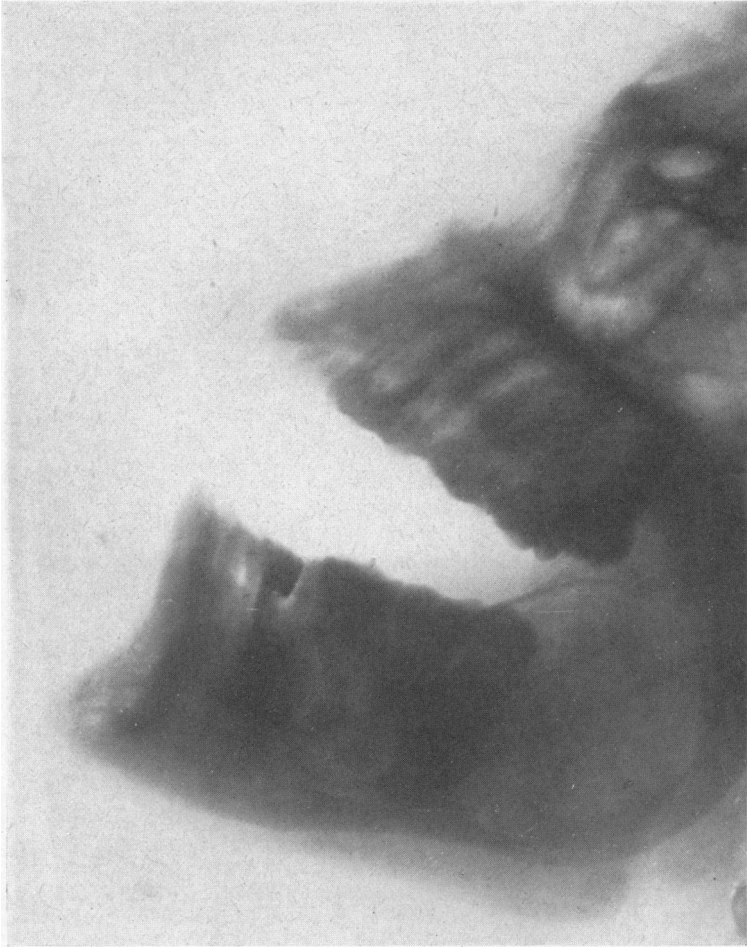

FIG. 1.—Case I. X-ray of unilocular cyst of jaw. Tooth seen in the cavity of the cyst.

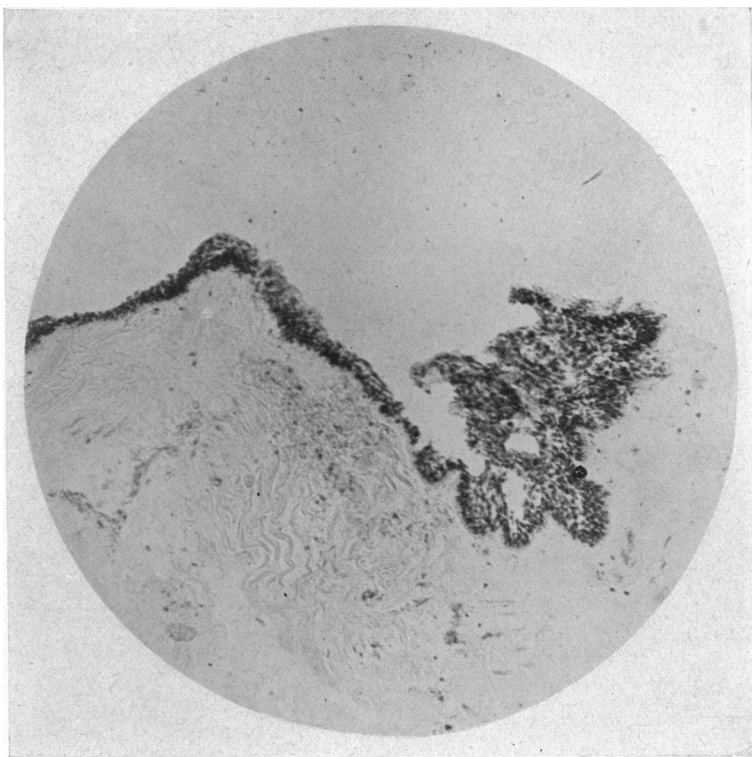


FIG. 2.—Case I. Photomicrograph showing the adamantine lining of a unilocular cyst.

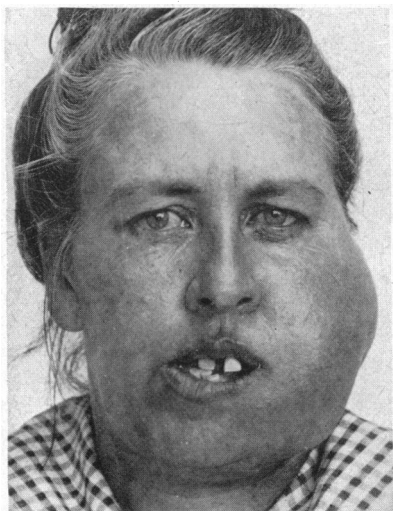

FIG. 3.—Case II. Multilocular chorioblastomatous cyst of jaw before operation.

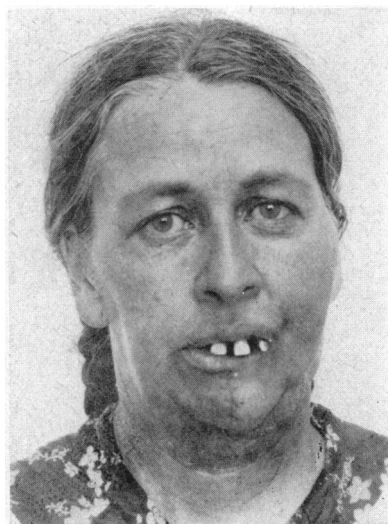


FIG. 4.—Same as Fig. 3, after operation.

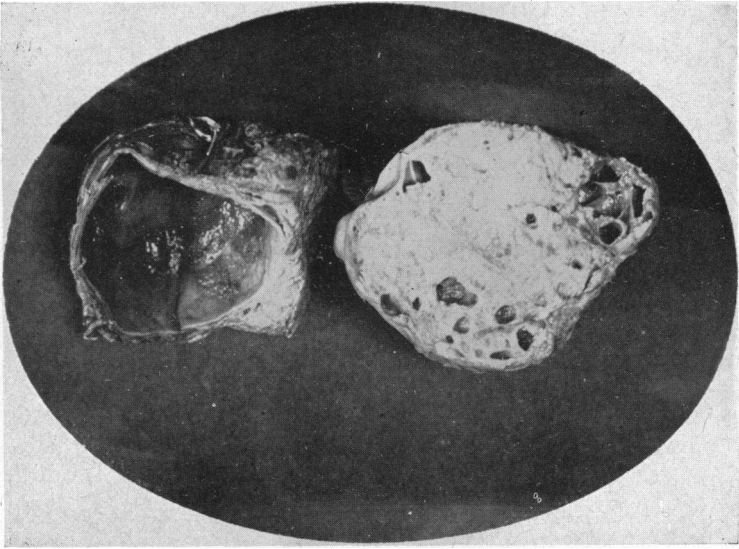


FIG. 5.—Case II. Multilocular and unilocular cyst of jaw (gross specimen).

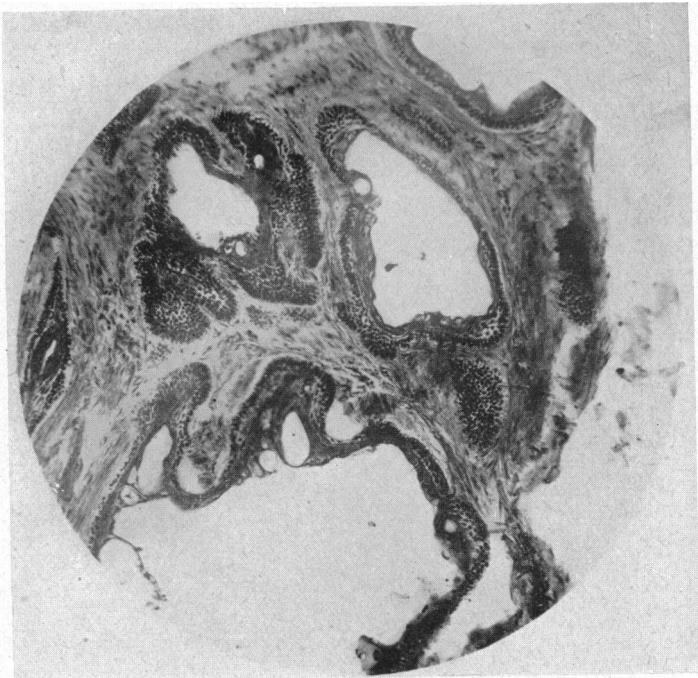

FIG. 6.—Case II. Photomicrograph showing epithelial villi and cysts.

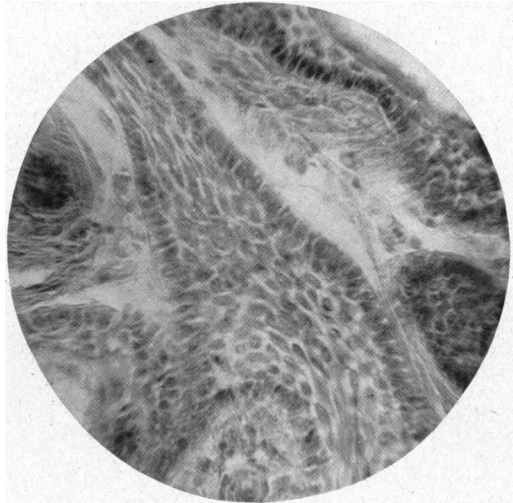


FIG. 7.—Case II. Photomicrograph showing part of a villus. Note the cylindrical cells in the outer layer and the stellate shaped cells in the centre.

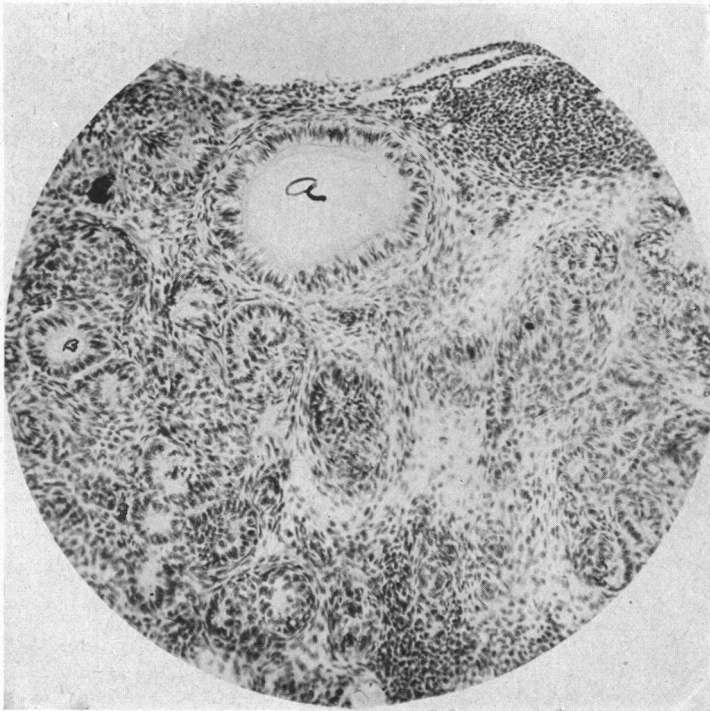


FIG. 8.—Case III. Photomicrograph showing dentine formation A and B.

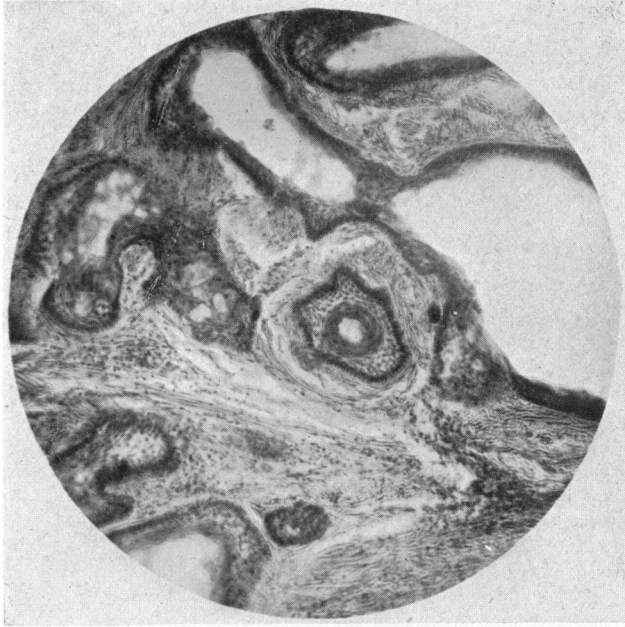


FIG. 9.—Case V. Photomicrograph showing the formation of epithelial cords surrounded by cement.

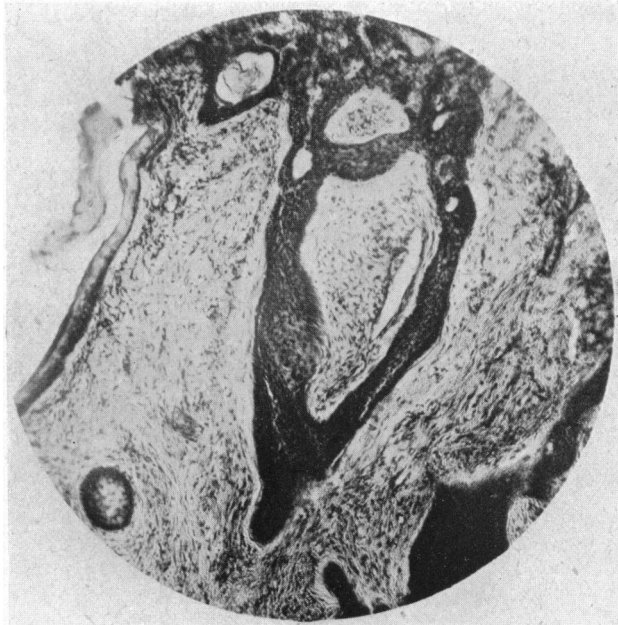


FIG. 10.—Case VI. Photomicrograph of section of solid tooth-germ tumor in upper lip.



## TOOTH GERM CYSTS OF THE JAW

The growth of the tumor is very slow, as illustrated in the following cases.

CASE II.—Miss A. C. entered the Nicholas Senn Hospital on Tuesday, July 22, 1913, with the following history: Age 42 years, unmarried. Twenty-four years ago a swelling began in the lower jaw on the left side in the molar region. About nine years ago it was about half the size it is now and was operated upon by another surgeon. The patient says the surgeon told her it was a sarcoma and could not be removed. Following this operation a sinus kept discharging and a year later was operated upon by a different surgeon and piece of the wall of the tumor taken out, she says. The tumor remained about the same until three years ago and it began to grow rapidly.

Upon examination the tumor presented a solid growth, extending to the hyoid bone and well up into the temporomaxillary articulation. The whole mass had a bony feel, excepting the part near the lobe of the ear, which had a tense cystic feel. The mass extended a finger's breadth above the lobe of the ear. There was no ulcerated area.

The patient was operated upon July 26th. The jaw was cut through at the symphysis and disarticulated at the temporomaxillary joint. She left the hospital August 16th and has since remained well (Figs. 3 and 4).

*Pathological.*—The tumor is size of man's fist enclosed within a thin bony wall of the lower jaw. Tumor has a honey-comb appearance. The small cysts are filled with a gelatine-like fluid. The solid parts of the tumor are of rather soft consistency and of grey-white color. One-half of the tumor presents a single cyst, size of a small hen's egg, having smooth walls and is filled with thick gummy substance. There being no direct communication between it and the multilocular part of the tumor (Fig. 5).

*Microscopical.*—Sections taken from solid parts of tumor show a connective tissue stroma which is poor in blood-vessels. In the stroma there are found epithelial villi which form interlacing twigs having the picture of an epithelioma. The villi are made up of an outer layer of cells which are cylindrical and placed perpendicular to the stroma. Centrally from this layer there are cells of cubic shape and some are flat. In the centre of some of these villi there are interlacing stellate shaped cells. In other parts of the tumor there are macroscopic and microscopic cysts of varying size. The cysts are lined by similar cylindrical and flattened cells. Inside the cyst there is contained granular degenerated material (Figs. 6 and 7).

As Steensland<sup>21</sup> has suggested in the study of his cases that the cylindrical cells correspond probably to inner epithelial layer of enamel organ and the cubic cells to the outer epithelial layer. The flattened

cells are likely the precursor of the stellate cells of the stratum intermedium. Section taken through wall of outer half of tumor of Case II shows a dense connective-tissue wall, within which are found solid masses of epithelial cells. The inside of the cyst is lined by epithelial cells of adamantine type.

CASE III.—Miss A., 20 years old; tumor noticed for the last 4 years. Tumor located in the upper jaw of right side at the first molar region. No teeth erupted through the gum over the tumor. The tumor was slow and painless. Opposite side presented an accessory molar tooth erupting behind the normal teeth. Tumor excised and no recurrence reported.

CASES IV and V.—The tumor occurred in the lower jaw. Duration of growth was several years. One of these cases occurred in a female and the other in a male, aged twenty-eight. We regret that a more definite clinical history could not be obtained since we lost track of these cases.

The Cases III and IV present a pathologic picture similar to Case II, except that in Case III there is marked formation of dentin (Fig. 8).

Case V differs from the rest. The epithelial structure of the tumor is continuous with the epithelium of the gum. This tumor might be mistaken for a true malignant epithelioma. However, the tendency of the epithelial cords to be surrounded by true cement formation and the appearance of cells obviously attempting to form stellate adamantine, stamp the character of the tumor (Fig. 9).

The pathogenesis of this type of tumor has been dwelt upon above. Its multilocular character can be probably explained by Cryer's work<sup>22</sup> who demonstrated the "inferior dental canal to be a cribriform structure; that an abundant communication exists between the vacuoles or loculi of the cancellated tissue of the bone; that the alveoli of the teeth are not only in communication with the inferior dental canal but with the loculi of the cancellated tissue in all directions and with one another through the same channels."

We are inclined to accept this as a plausible explanation of the nature of the above tumor. Since one can readily understand that a large single cyst, in which the epithelial lining is undergoing a marked proliferation with formation of solid masses, may become multilocular by the growth following the communicating canals. If this view be correct one can explain the recurrence of these tumors after incomplete excision.

## TOOTH GERM CYSTS OF THE JAW

Multilocular embryonal cysts are benign in character although as we mentioned they may recur if excision is incomplete. In our cases no recurrence is reported, the oldest being 6 years after operation.

Solid tumors, arising from rests of the adamantine epithelium, are of great rarity. In the case to be described below a tumor of this kind occurred in the upper lip.

CASE VI.—Young man, age 25. Had a small cherry-sized tumor in upper lip. Tumor was easily shelled out.

*Pathological.*—Size of tumor, that of a cherry—encapsulated. Hard consistency.

*Microscopical.*—Same picture as described under Case II except that the solid masses were in greater preponderance than in Case II.

After careful search of the literature I was unable to find a single instance of adamantine tumor occupying the position above indicated.

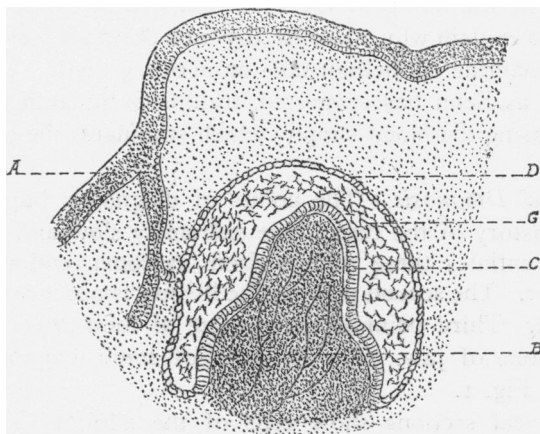


FIG. 11.—Schematic representation of the embryology of a tooth (after Kaufmann). *A*, epithelial cord; *B*, tooth papilla; *C*, inner layer, cylindrical cells; *D*, outer layer, cubical and flat cells; *G*, stellate reticulum.

Cases of unilocular embryonal cyst were reported to occur in the gums and orbital region. The unusual position of the tumor can be explained by the embryology of the teeth (Fig. 11).

The epithelium over rudimentary alveolar process dips down into mesodermic connective tissue and constitutes the epithelial cord, *A*. From the epithelial cord the future enamel organ is formed. The enamel organ becomes invaginated by the underlying mesoblastic tissue and this forms the tooth papilla from which dentin, cement, and tooth pulp are produced, *B*. The bell-like enamel organ possesses three

kinds of cells; the inner cells, tall and cylindric, *C*; outer layer cells, which are flat and cubical, *D*; the layer between the two consists of stellate reticulum, *G*, stellar cells which anastomose with each other and form mucoid tissue.

Only the upper part of the inner layer of cells which invests the tooth crown is capable of producing enamel. The cells at the lower part of the enamel organ lose property to produce enamel and grow deeper into mesoderm, forming a covering for the root of the tooth. By and by, this epithelial covering becomes absorbed and replaced by mesodermic cells. However, epithelial rests remain in the embryonic jaw. Malassez found such rests in most of the cases studied by him. One can readily see how epithelial tissue may become dislodged into the under surface of oral mucous membrane, and, when aroused to activity, proliferate, forming a solid tumor, as was the case with our patient, Case VI. Or, when the tissue is displaced into the body of jaw, cysts form which may be unilocular or multilocular, depending upon the proliferation of the lining of the cyst. Of course, some other factor is necessary to explain why, after having been dormant for years, bits of aberrant adamantine epithelium take on active growth.

Probably, as Senn has suggested, trauma or inflammation plays a rôle by increasing the blood supply, which stimulates the cells to active proliferation.

*Differential Diagnosis.*—The points of diagnostic importance are: the clinical history of the case. The extremely slow and symptomless growth differentiates these tumors from sarcoma, endothelioma and myeloid tumor. The second point in the history is absence of teeth over area involved. Third point is the absence of infiltration and no fixation to the bone of jaw. The X-ray is of some diagnostic value as illustrated in Fig. 1.

Microscopical sections show cells of the adult type corresponding to the cells forming enamel and dentin; arrangement is in long strings and gland-like structures, the latter sometimes presenting dentin formation in the lumina of the gland-like masses. Intact basement membrane always found sharply demarked by cell masses and gland-like structure from surrounding connective tissue. The occurrence somewhere in these masses of the characteristic stellate cells. The great variation of cells found in adamantine tumors will differentiate them from endothelioma, in which the cells are a uniform shape and type.

## TOOTH GERM CYSTS OF THE JAW

### CONCLUSIONS

1.—The conventional terms employed for cystic tumors of the jaw are neither descriptive nor accurate.

2.—Cystic tumors of the jaw are divided into (A), inflammatory; (B), tooth germ (chorioblastoma)—(a), unilocular; (b), multilocular; (c), solid.

3.—Chorioblastomatous cysts of the jaw originate from the embryonal rests of epithelial cord of enamel organ.

### BIBLIOGRAPHY

- <sup>1</sup> Bland Sutton: Tumors, Innocent and Malignant, 1901, Cassel & Co., N. Y.
- <sup>2</sup> Kaufmann: Lehrbuch d. spec. Pathologie, 1911, vol. i, p. 377.
- <sup>3</sup> Bloodgood: Jour. Amer. Med. Assoc., 1904, p. 1124.
- <sup>4</sup> Scudder: Tumors of Jaws, Saunders & Co., 1912, pp. 163, 240.
- <sup>5</sup> Albrecht: Frankf. Zeitschrift f. Pathologie, vol. i, No. 1, 1907, pp. 221, 234.
- <sup>6</sup> Magitot: Arch. gén. de Med., 1892, vol. ii, pp. 339, 413.
- <sup>7</sup> Partch. Schles: Gesel. f. Vaterl. Cultur 3, xii, 1909, Ref. B. 51, 1909.
- <sup>8</sup> Turner: Cited by Sutton-Keen's Surgery, Saunders & Co., vol. i, p. 778.
- <sup>9</sup> Malassez: Arch. des physiol. nor. et path., 1885, vol. v, p. 129.
- <sup>10</sup> Falkson: Quoted by Lewis, Surg., Gyn. and Obst., 1910, x, pp. 28, 36.
- <sup>11</sup> Malassez: loc. cit.
- <sup>12</sup> Kruse: Virchow's Arch., 1891, vol. cxxiv, p. 137.
- <sup>13</sup> Bland Sutton: loc. cit.
- <sup>14</sup> Barrie: ANNALS OF SURGERY, vol. xlii, September, 1905, p. 357.
- <sup>15</sup> Cryer: Brophy, Oral Surgery, Blakiston & Co.
- <sup>16</sup> Brophy: Oral Surgery, Blakiston & Co.
- <sup>17</sup> Lewis: Surg., Gyn. and Obst., 1910, x, pp. 28-36.
- <sup>18</sup> New: Jour. Amer. Med. Assoc., 1915, xiv, pp. 34-39.
- <sup>19</sup> Massin: Virch. Arch., 1894, cxxxvi, p. 328.
- <sup>20</sup> Coats: Brophy, Oral Surg., p. 859.
- <sup>21</sup> Steensland: Journal Experim. Med., 1904.
- <sup>22</sup> Cryer: loc. cit.