

STUDIES IN PLASTIC SURGERY OF THE FACE

I. USE OF SKIN FROM THE NECK TO REPLACE FACE DEFECTS. II. PLASTIC OPERATIONS ABOUT THE MOUTH. III. THE EPIDERMIC INLAY

BY J. F. ESSER, M.D.

OF HOLLAND

SPECIAL SURGEON FOR PLASTIC OPERATIONS AT THE K.U.K. RESERVEHOSPITAL NR. 8, VIENNA

I. USE OF SKIN FROM THE NECK TO REPLACE FACE DEFECTS

IN this war I went to Austria to help to repair and undo a little part of the cruel mangling that millions of men have produced over all Europe. First, during eight months, I was chief surgeon of a very large barrack-hospital with 3600 beds, in Moravia, and afterwards I worked till now in my special branch of plastic work in different hospitals of Vienna and in the University surgical clinic of Hofrath Prof. von Hochenegg. As I made in Austria over 700 plastic operations on war-cripples I enlarged my practical experience, especially in repairing defects of the face in an important manner. In the present paper I desire to present a new operative system, which I introduced for repairing upper lips, cheeks, eyelids and noses.

The methods in general use did not satisfy me, as the results were not sufficient in an æsthetic and functional way. The use of the pedicle flap of skin from the arm or wandering flap from the breast is generally, besides its disagreeable technic for the patients, decidedly disfiguring. The color, paleness, hairlessness, flaccidness and other particulars or qualities differ so much from the skin of the face, especially in the neighborhood of the nose, that such a technical successful plastic only succeeds in closing the defect, but does not construct a proper lip.

Perhaps a temple pedicle flap is better, partly hairless for mucous membrane, partly with hair for the skin of the lip (Lexer). I saw a case in Prof. v. Hochenegg's clinic, where Dr. Demmer had used for replacing an under lip and mucous membrane a very large temple pedicle flap; partly with and partly without hair, with a pedicle scarcely finger broad; the temporal artery, with its branches, had been found and marked out with lapis before the operation. The result was very satisfactory. In general I do not like this method, as the temple defect is most difficult to heal æsthetically.

My cuts for upper-lip-cheek defects vary according to the size and place of the defect. They all have the same principle, that the arteria maxillaris externa lies in the centre and the cut first rises, then makes a broken curve, passing under the ear and taking more or less of the

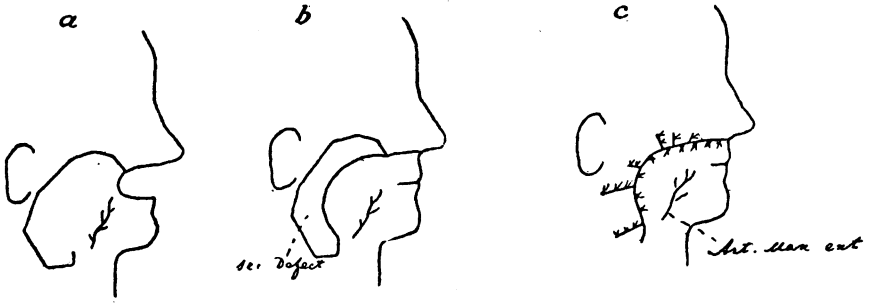


FIG. 1.—Upper lip defect.

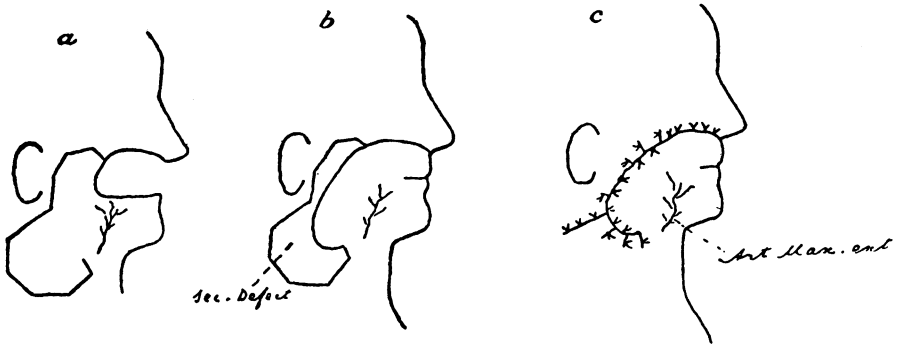


FIG. 2.—Lip-cheek defect.



FIG. 3.—Eyelid-cheek defect.

PLASTIC SURGERY OF THE FACE

neck, according to size of defect (Figs. 1-3). The end of cut is always suddenly vertical, so as to make the whole movable. In some cases both cheeks are used, but mostly one side suffices, even for very large defects. After making the piece as movable as required, it is then turned and placed in the defect. The cut varies according to the presence or absence of hair, and if the defect also extends to the eyelid. Further, a somewhat similar cut is necessary in the mucous membrane of the mouth, again commencing at the same place and in the same direction, but turning before reaching the ductus stenoianus. At the end of this cut is also a sudden perpendicular incision to facilitate its removal. The mucous membrane cut is not only important for the removal of the whole part, but also because the sewing together of the mucous membrane wound after the removal supplies a surplus to be used for the inside of the new lip. The first part of the cut may split the entire cheek, but further on it must gradually be less deep for fear of injuring the facial nerve or the ductus stenoianus. That the nourishment of this turned cheek piece, one can scarcely call it a pedicle flap, is very good, is shown in the sketches attached and in the good results of the operations. The healing is without exception beautiful, as nowhere is any great difference in color or quality of the joined skin parts. The tension is, as far as the neck, quite regular. At the neck itself it is the greatest, so that we can say, practically, the defect is replaced by skin from the neck. The secondary defect, after the primary defect is closed, is mostly shown by a great gap in the neck. The wound edge at the back is then diminished by sewing the edge together at the cut intervals (*vide* diagrams). These stitches can bear very much tension. In this way the back edge approaches the front one, till they can be easily sewn together. I never leave any part unclosed. This I do in all my facial plastics. It is only possible because a beautiful plastic is always a mathematically correct and maximally economical one, and there remains no unused folded skin in the turned pedicle.

The apparent danger of injuring the ductus stenoianus and nervus facialis is, by careful technic, very small. Only once I met with a temporal facial paresis, which did not appear directly after the operation, nor the next day (as I never give dressing, I at once see any disturbance), but only some time later. It has arisen in consequence of the inflammation of a few stitches near the ear-lobe, where the healing did not immediately set in, but followed later on with good result.

Sometimes small salivary fistulas appear which heal in a few days without lapis treatment. I don't like the use of this, as it leaves scars. In such cases, after thoroughly cleaning with ether, I put two drops of

collodion on the fistula and as soon as the liquid is nearly dry, I press a little cotton wool with the finger for some moments on the fistula. If pus has collected under the wool, the next day, I take off the collodion skin and wait till the wound has cleaned itself. This collodion treatment is repeated till healing ordinarily appears. I never saw a fistula remain which had to be operated, which can only be explained by the fact that I never cut through the ductus stenonianus, but only injure the gland tissue of the frontal terminals of the parotis or parotis accessorius.

I will give some specimen cases of my material in this method, showing how different kinds of defects may be treated.

CASE I.—Soldier S. (Figs. 4-7), K. u. K. Reservespital Nr. 8 at Vienna. The patient had lost an eye, the greater part of the cheek and of the under eyelid by granat-shot. He had been operated elsewhere, but the plastic had not succeeded. There was placed a pedicle flap partly hairless, partly without hair from the temple, and turned till the axis stood horizontally, and was then sewn into the eyelid-cheek defect. The flap had not sufficed as Fig. 4 shows and finally had shrunk through necrose, besides it had wrinkled and was very hairy. The temple (secondary defect) was very deformed as the substitute was quite hairless and consisted only of scar, wound and Thiersch islands. Therefore I tried to undo this work as far as possible. After cutting out the original temple wound, I unfolded the flap of the cheek, which was very difficult to do, as the folds were deeply seamed. Finally, the replacement of the flap succeeded very well, as shown in Figs. 5 and 6. After that the new cheek-eyelid defect was repaired with cheek-neck skin flap as described and shown in the diagrams. The healing retarded only in some stitches near the ear-lobe where a temporary paresis of the mouth facialis branches arose which soon disappeared. After this first operation skin material was present everywhere, as Fig. 5 shows. Afterward some corrections had to be made. Fig. 6 shows the result after the second one, which enlarged the length of the cheek at the cost of the width by taking a pedicle flap including the vertical scar of the nasolabial fold, turning it upward till it was horizontal, then placing it under the eyelid in horizontal incision so as to elevate the lid. Fig. 7 shows the situation after another correction of the eyelid and levelling the cheek.

CASE II.—Soldier B.T. (Figs. 8-11), K.u.K. Reservespital Nr. 17 at Vienna. Complete upper lip defect after a gunshot—broad, deep scar in the right cheek, besides defect of processus alveolaris on the right and in the middle. The mucous fornix was missing there. After the first operation in my method here given the

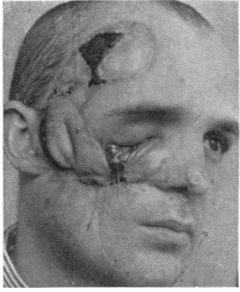


FIG. 4.

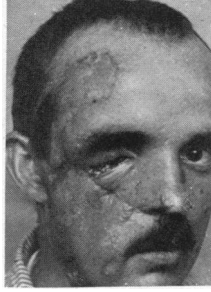


FIG. 5.

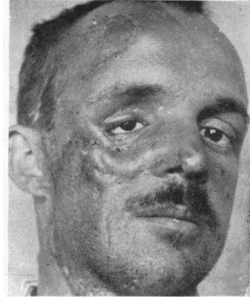


FIG. 6.

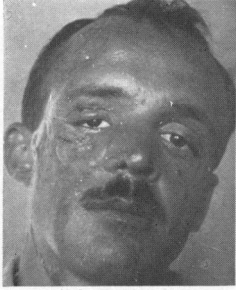


FIG. 7.

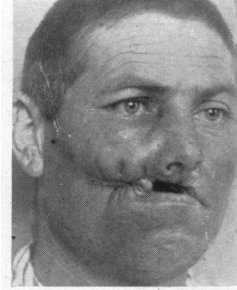


FIG. 8.




FIG. 9.

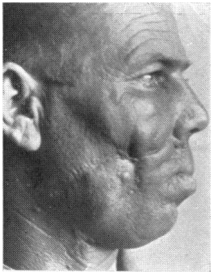

FIG. 10.



FIG. 11.




FIG. 12.

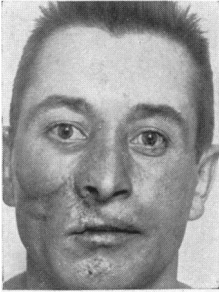

FIG. 13.

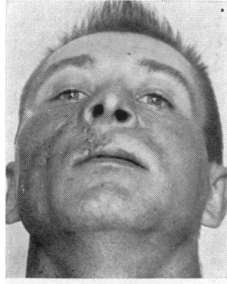


FIG. 14.

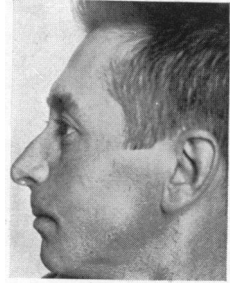


FIG. 15.

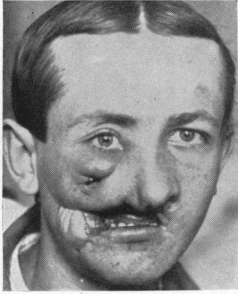


FIG. 16.

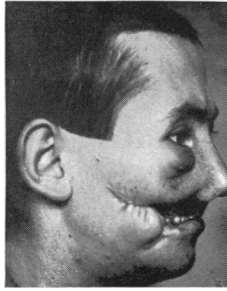


FIG. 17.

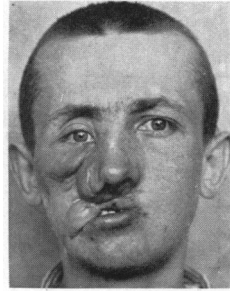


FIG. 18.

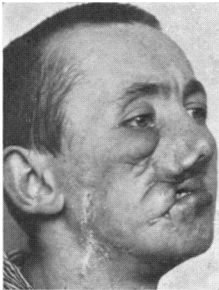


FIG. 19.

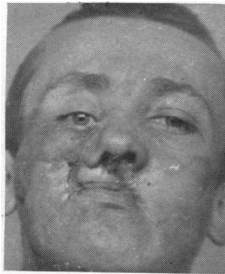


FIG. 20.

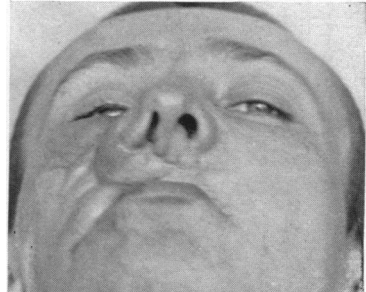

FIG. 21.

PLASTIC SURGERY OF THE FACE

practical and æsthetical results were already good, though on the right cheek was a large scar. The jaw and the face muscles were all freely movable, only the mucous fornix was failing to receive the dental prosthesis. On the left side, where the same method had been used, the healing was beautiful. Some small corrections still have to follow. Figs. 10 and 11 show the patient after the first operation *before any correction*. As the correcting operations are not yet ready, I mention only the first result.

CASE III.—Soldier H. (Figs. 12–15), K.u.K. Reservespital Nr. 17 at Vienna. Shot injury of the right upper lip; nostril quite drawn aside, and mucous fornix defect. By cutting the cheek only to the neck, I could obtain a sufficient flap to cover the defect caused by the excision of the scars. The nostril was at the same time released and set right. Some small corrections were made afterward. The upper lip shows still a little œdema, which disappeared afterward by massage. Fig. 13 shows the result of the first operation, Fig. 14 after the correction of the cheek scars, Fig. 15 after lip correction.

CASE IV.—Soldier L. (Figs. 16–21), K. u. K. Reservespital Nr. 8 at Vienna. Total defect of the upper lip. Processus alveolaris nearly fully absent, perforation of the bony palate, cheek scarred, upper jaw grown together in a downward position after fracture. The right eye, quite blind, had slipped down, following its support. The nose was quite crooked and turned inward.

Here I came out with my method by making a large cut only on the right side, put besides, however, the skin part from between the two cheek scars as a pedicle flap (pedicle near the nose), first into the lip defect and joining the large patch to it, which also filled up the secondary defect made by the first flap. The new defect caused by the displacement of the large flap was closed in the ordinary way.

This particularly complicated proceeding made more after-corrections necessary, but was requisite on account of the situation of the two large, very deeply branched scars. Figs. 18 and 19 show the result after the first operation, Fig. 20 after a plastic of orbicularis oris muscle with mucous membrane (a pedicle flap from the under lip), Fig. 21 some weeks later on. There must still be made many small corrections before the case is finished; and because it is very important that between two corrections a very long time elapses till the vessel communications in the connecting lines are good, it will take several months before all is finished.

As this publication only intends to show the principles of my method of repairing facial defects from the neck, it was not necessary to wait till all the corrections of the cases were ready.

II. PLASTIC OPERATIONS ABOUT THE MOUTH

In defects and deformations of the under lip many and various methods by plastic operation have been applied. Mouth operations have occupied surgeons since the ages of antiquity, and belong to the most difficult plastics that exist when a fine result is desired; however, they are very easy when patient and surgeon are soon satisfied. The elastic surroundings, with loose fixture on the bones at a distance and with excellent vascularization, make it possible to close the defects after various methods with good healing results. Later the continual work of the free and muscular surroundings helps to improve the results.

Nevertheless, after all, a mouth result almost always in respect to movement, shape or size, leaves much to be desired. The absence of bony fixture of the mouth tissue, however it may facilitate the joining of the defects, demands an independent regular construction of the new mouth, as one finds nowhere any firm support.

The great number of procedures which are all used satisfactorily, declare that every one affords good help but no one gives entire satisfaction. We find drawings and descriptions of these methods *in extenso* by Bockenheimer (Plastische Operationen), Lexer (Handbuch der chirurgischen Technik, edited by Bier, Braun and Kümmel, or in the Handbuch der Chirurgie, by von Bruns, Garré and Küttner) and F. Krause (Lehrbuch der chirurgischen Operationen) and in other surgical books.

Confining ourselves to the lower lip plastics, after mentioning the simple vertical sewing together of wedge-shaped defects, and a similar procedure on horizontal ones (Bockenheimer), the methods of Dieffenbach, Langenbeck, Jaesche, Trendelenburg, Sultan, Burow, Blasius, Lexer and Morgan, who all take their flaps from underneath the mouth line, are to be mentioned. Then follow those who take the substitute for the lower lip from above the mouth line (von Bruns (two kinds), Estländer). Israel with his neck flap forms a separate group, as does Lexer with his temporal flap.

Each of these methods has its certain advantages and disadvantages which I cannot detail here. I will only mention that till now not a single one has fully satisfied me—some for logical mathematical reasons, *e.g.*, the simple vertical and horizontal sewing; and the method of Burow for sacrificing too much tissue.

It should be the greatest exception to cut out pieces of sound skin and tissue to facilitate a plastic closure; all the proportions will unneces-

PLASTIC SURGERY OF THE FACE

sarily decrease. There is nearly always a way to be found for applying tissue, which can be spared and taken from the immediate neighborhood for covering the defect in a beautiful and practical way. It is still to be mentioned that the procedures of Trendelenburg, Sultan, and Blasius work in a too narrow circuit to produce a sufficiently large and free under lip. The larger the surface over which the tension difference is to be spread without much cutting, the more satisfactory will the result be.

There still remain the plastics of Dieffenbach, Langenbeck, Jaesche, Lexer, Morgan, Israel, von Bruns (two kinds), and Estländer. Dieffenbach's procedure has proved itself to be a very useful, direct, definitely sufficient method, which is mathematically correct; the deficit is divided over a large space, and the flap is well nourished by the arteria maxillaris externa. It only has the disadvantage of deforming the cheek. Also the Langenbeck and Lexer plastics, the one with, the other without, spur, satisfied me, in case of very broad, not high defects, in regard to the cosmetic side, but less on account of the bad movability of the new lip.

Morgan's method I would only use modified, as the sewing of the mouth corners is too unnatural; therefore I combined it with my method mentioned below, in cases of complete lip defects, without practising his sewing together the corners of the mouth.

With high and large lip defects, Jaesche's method is the best, only I made the curve cut much wider and higher, so as to keep the arteria maxillaris externa in the centre of it. In this way I approached more the Dieffenbach method, and got the advantages without the disadvantages of both, so that the result was both practically and cosmetically good. This operation had arisen by diminishing the cut in my method for the substitute of larger upper-lip-cheek defects described in "Plastic Operations on War-crippled Soldiers with Indirect Usage of Skin of the Neck to Replace Defects of the Face."

The Israel and Lexer plastics with the neck and temporal substitute give (with the favorable healing conditions in defects with bad nourishment, in which cases a plastic from the neighborhood of the defect was not advisable), in general, a disfiguring result. Near the mouth, the new flap contrasts strongly with its surroundings, and the place from where it was taken is closed with difficulty and disfigurement, so that these operations can only be advised in special cases of bad local conditions.

The cheiloplastic after von Bruns, with almost circular incision round the mouth, nearly from one nostril to the other, destroys too many

vessels and nerves; his other method with two square flaps, rising from the mouth corners, has great advantages, only the scars of the secondary defects, which go up and aslant from the corners of the mouth, are very ugly.

Finally, Estländer's plastic has satisfied me in certain localizations, but a correction of the mouth corner had always to follow.

The shape and place of the defect play a great rôle in choosing the method, and its results much depend on the right choice being made.

My plastic consists in taking a more or less highly-pointed triangular flap with the pedicle at the bottom. The flap is taken either from the nasolabial fold, or also extending higher up between the nose and the

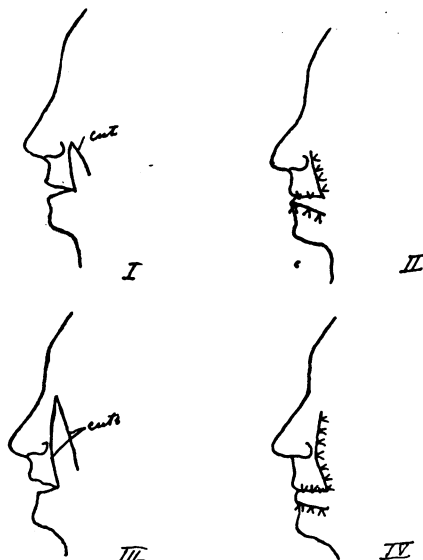


FIG. 22.—The nasolabial flap.

cheek. When requiring mucous membrane the cuts penetrated into the mouth, otherwise more or less muscular tissue was taken in the flap according to the requirements for active movement in the under lip (see Fig. 22). After first completely closing the nasolabial defect, the flap presented itself ready for being placed in the under lip. The flap is used either for a defect or, if the lip be too short or too immovable, is placed in an incision between the red of the lip and the skin.

The advantages of this method are the following:

(1) The flap contains the entire *arteria angularis* (continuation of the *arteria maxillaris externa*).

(2) The flap may, if required, supply excellently functioning muscle

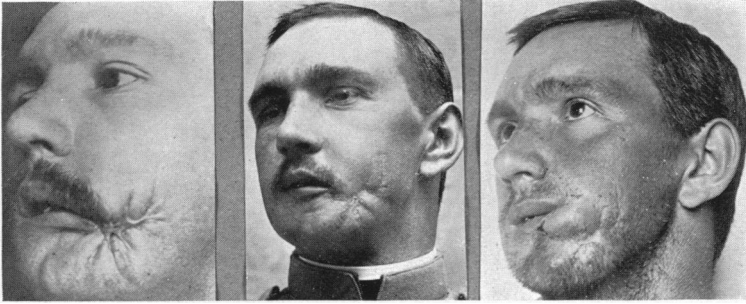


FIG. 23.

FIG. 24.

FIG. 25.




FIG. 26.

FIG. 27.

FIG. 28.

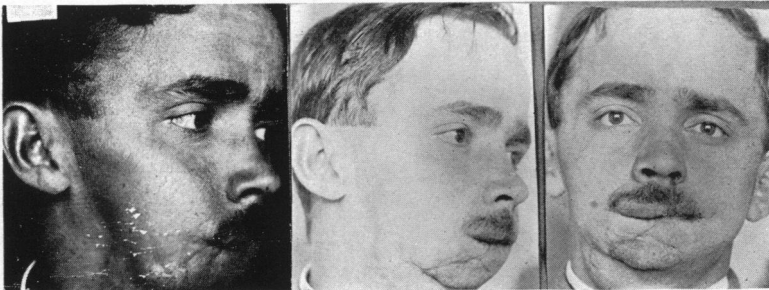


FIG. 29.

FIG. 30.

FIG. 31.

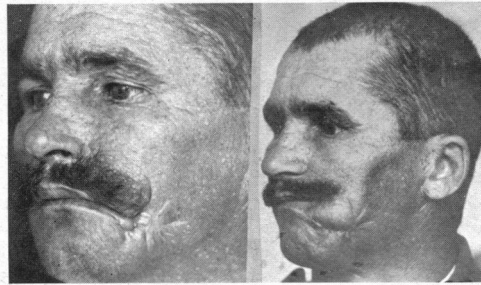


FIG. 32.

FIG. 33.

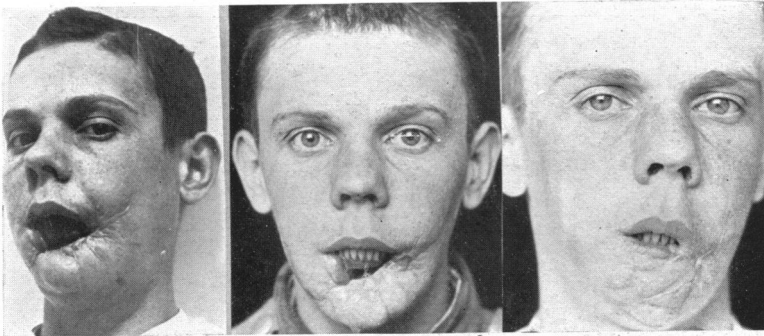


FIG. 34.

FIG. 35.

FIG. 36.




FIG. 37.

FIG. 38.

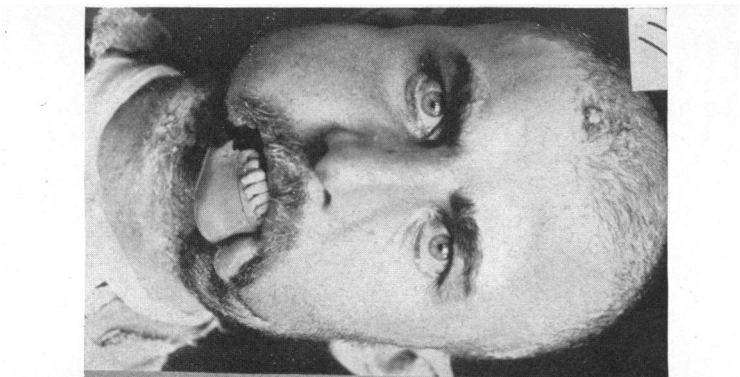


Fig. 39.

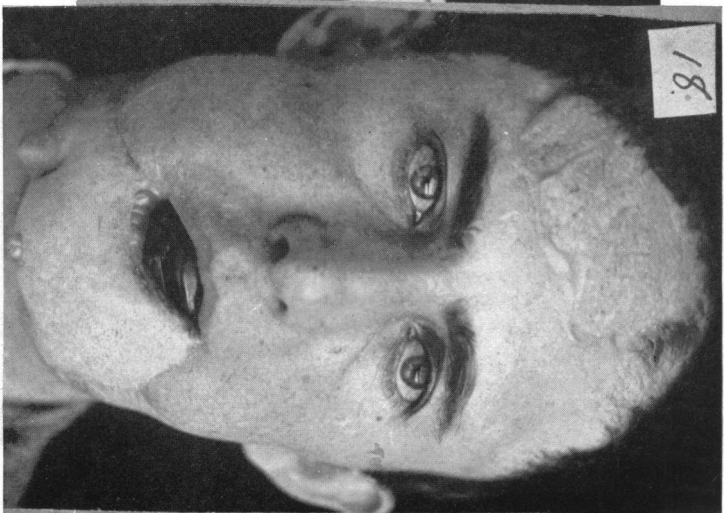

Fig. 40.

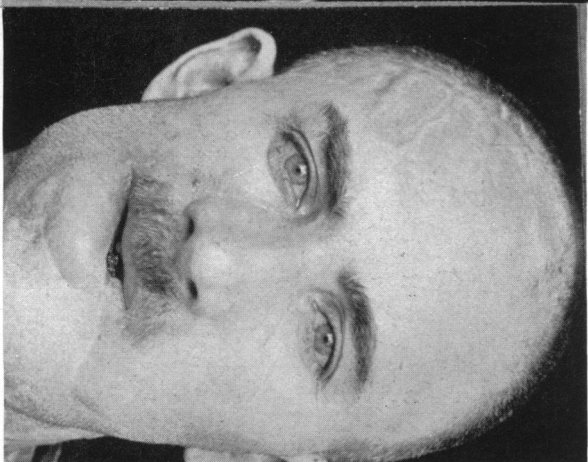


Fig. 41

tissue (muscularis levator angularis) for moving the under lip. (As mentioned above, can considerably improve the Morgan plastic without its corner sewing.)

(3) The sewing together of the secondary defect *disappears exactly in the nasolabial fold*. (Only with very large defects and extensive corrections the flaps extend to near the inner eye corner and then the seam goes higher up exactly in the nose-cheek separating line.)

(4) The upper flap line is sewn together, either with its own mucous membrane (when the flap also contained this membrane) or with other mucous membrane, but *always forms the natural border of the red of the lip*. Only the suture of the much shortened under flap line remains visible after the operation.

(5) In contrast to the somewhat similar method of von Bruns, I can make my operation *either only on one side or on both sides*. In the latter case I have the free choice of the intermediate time. That is because my flap-ends are pointed and easily disappear quite in the lip, while von Bruns's flap-ends are square, and must find another wound edge opposite to join. When I use two flaps (which, however, is seldom necessary) the second flap partly crosses the first. After the complete healing of the first, one has the choice of the size and time of the second operation. It is clear that also the healing is surer than by performing both sides at once.

Here follow some of these mouth plastics made for different reasons.

Soldier D. (Figs. 23-27) (K. u. K. Reservespital Nr. 17 in Vienna), after a shot, had a deep, broadly branched scar at the corner of the mouth, which was drawn much to the side and downward. The scar was deeply spread in the muscles and mucous membrane. The real plastic only followed a preparatory one which removed all the deep scars as far as in the mouth, so that the principal operation could occur later on without entering the mouth. A flap was taken in the manner described, and placed in an incision along the red of the lip.

Of the three seams, only the under one in connection with the little scars of the first preparatory operation underneath it are visible, and can be completely removed later on (see Fig. 37).

As Fig. 37 shows, the flap protrudes a little; this was done purposely, because it is better to be too thick than too thin: First, the secondary defect can be closed more beautifully, when the deep tissue is also removed; secondly, the superfluity of the flap can easily be removed, when after a long time it has not disappeared by the shrinking. A principal thing is that the flap after a long time has enough muscles and does not sink in.

Soldier W. was kindly sent to me for treatment in the Clinic v. Hochenegg, by Docent Dr. Finsterer.

Besides an under-jaw-bone defect, which I also operated (local bone plastic), the patient had a gunshot wound through the left upper and the right under lip. The relatively too large upper lip half was somewhat diminished and drawn by the above described operation, which at the same time raised the under lip and made it more movable (see Figs. 28-31). The remaining prominence of the right upper lip is still to be corrected by a long and deep excision out of its inner side, parallel with the red of the lip.

Soldier D. (Figs. 32-33) (Clinic von Hochenegg). The dentist had made an enlarged mouth by cutting, in order to have more room for his prosthese preparation. Round about the incision there was an extensive growth of scars, so that the left mouth corner was quite immobilized, and, notwithstanding the size of the mouth, speaking, eating and mimic were extremely difficult. The above described mouth plastic corrected them completely. Respecting the protruding of the flap, see remarks on the first patient. The remaining small scars must be removed with the last correction.

Soldier P. (Clinic von Hochenegg) (Figs. 34-37). Here the operation was only a correction after a Langenbeck kind of total under lip plastic, combined with a pedicle flap for mucous membrane substitute. I give here no more details of the first operation but refer to the illustrations. The correction had, as chief object, to make the under lip more movable for speaking and eating; at the same time by lifting the corner, the shape and height of the lip were improved. The patient was not finished after this operation, as the centre of the lip had to be raised. This could be done from the inside of the mouth, as it was caused by the lip having turned inward (entropion), but had not been performed when the last photograph was taken.

Quite another indication was formed with Cadet M., with a very old paresis of the facial nerve. I have also to thank Docent Finsterer for sending me this patient. The same operation was performed, and healed very beautifully, but unfortunately I have only Fig. 38 before the operation and the patient went to the front without being again photographed. The operation had proved its value very well for such cases of paresis.

With the Hungarian soldier M., in the Clinic von Hochenegg, a very successful temporal flap plastic (Lexer) as substitute for the completely missing under lip was made by Dr. Demmer. To correct the too deep immovable under lip he carried out with me a

PLASTIC SURGERY OF THE FACE

nasolabial flap plastic. Here the flap was very long, was also taken from the nose cheek border and was placed nearly along the entire under lip (see Figs. 39-41).

After this operation the patient could eat solid food which had been impossible before. A final correction should be made to raise the end of the flap and the corner of the mouth. A small nasolabial flap from the left side would do; the symmetry would be easily gained and the movement of the left under lip part would improve.

III. THE EPIDERMIC INLAY: NEW WAYS FOR SURGICAL PLASTIC BY USING DENTICAL TECHNIC

For a long time many surgeons have endeavored to obtain a skin covering, by laying on "Thiersch" skin pieces in hollows and on wounds. Still for hollows, these measures were mostly not sure of success, and have not been generally applied, though a keen interest has been taken through many good results. I thought the uncertain results could be avoided by improving the technic, as the bad results were caused by the irregular growing together of the skin and the pieces laid on; so that the complete covering resulted, after a long time, by the growing together of the skin islands where the "Thiersch" had attached.

It was a particular disadvantage that meanwhile a shrinking and cicatrizing through the development of scars was taking place in the granulating surface. Therefore I looked for means for applying the "Thiersch" faultlessly even, and under equal pressure, besides avoiding all infection and increase of saprophytes. This is possible by taking a negative impression of the wounds and covering it with one large Thiersch and placing this, under *equal pressure and immovable* for some days, on the wound. The Thiersch must be everywhere of the *same thickness* and *equally stretched* on the impression form, before this is placed on the wound. After creating aseptical hollows, by cutting under the normal skin adjoining the wound, and after lifting and exactly filling up this with an exact mould, completely surrounded with Thiersch (wound of the Thiersch outwards), the *equal pressure* follows by suture in firm tension of the incision. To prevent infection from increase of *saprophytes*, besides scrupulous asepsis, the greatest care must be taken in preparing the Thiersch. This must be very thin, and as far as *possible free from dead cells* which are always infected, and particularly overladen with saprophytes. Therefore I only use the *inner side of the upper arm*, because the skin is thinnest and most elastic there, and I have the part prepared, thoroughly and most carefully, till the skin is *pink* everywhere.

The Thiersch *suitably large and of equal thickness* can only be cut with *regular success* by great practice; one must always get a *tough, perfectly transparent* skin piece, the thinner the better, especially when it must replace the mucous membrane.

The application of an exact impression of sterilized dentist's impression material and the thorough covering of the same with Thiersch could, after my idea, avoid the dangers and assure a general sure result, if the mould, covered with Thiersch, were placed in the hollow or in the wound, and the opening were sewn firmly together. I carried out this treatment in 24 cases of different kinds, and the result was (with one exception) that the Thiersch healed *quite completely* and perfectly smooth. In the exceptional case, the mould was taken away too soon from a too small opening, and tore the whole Thiersch away. It was an inlay in the under eyelid, in order to enlarge the shrunken conjunctival sac, and in these cases the inlays require a long time to heal, as the tissue under the eyelid skin is very loose and has a weak circulation. It is very difficult to obtain, and to keep sufficient pressure round the inlay in this special region.

Till now I have operated on seven different types, which number may be considerably increased; the types are:

- I. Enlargement of the conjunctival sac.
- II. Construction of part or entire ear.
- III. Enlargement of the mucous membrane of the mouth.
- IV. Enlargement of the hollow of the mouth.
- V. Plastic of the hard and soft palate.
- VI. Preparation for different skin plastics: (a) Inner covering of flaps; (b) former covering of the secondary defect; (c) for both purposes at once.
- VII. Plastic of the urethra.

I. The enlargement of the conjunctival sac is very often required to make room for the eye prosthese. In these cases the eyelid skin is then cut parallel with the eye slit, higher or lower according to the case; generally scars must be taken away. And now after lifting the upper part of the cut, an impression can be taken (best with the assistance of a dentist) with sterilized wax material. This after hardening is carefully surrounded in the described manner with very thin Thiersch, which is then placed in the wound, and closed with pressure.

The mould must be made in a manner and with such pressure that its size is such that afterwards, on sewing the wound together, sufficient tension results. Before cutting the Thiersch, which only takes place when everything is prepared to receive it immediately, without first

placing it in a physiological solution, the hard mould must be placed in the hollow and the incision pressed together with the fingers, to see if the tension is correct, otherwise the mould can be altered. It is not practical to enlarge it by adding to it, as the join leaves a line where the Thiersch later on falls in, but it is better to make a new mould if the first prove too small. It is possible to decrease the size, if too large, by cutting before it is quite hard, and softening down the cuts.

The closing under pressure by the sewing is necessary for two reasons—first, the Thiersch is pressed everywhere for quick healing, and second, possible bleeding is prevented. Though I construct the hollows by *cutting* on purpose to open the most possible number of little blood- and lymph-vessels (by all free transplantations I prefer this method to the blunt preparation in general use, because it gives better healing condition). By sewing together under pressure, the small vessels are all closed—only the large arteries must be squeezed or twisted, but not tied, as no foreign substance may remain between inlay and wound. In consequence of the pressure a primary healing of the suture is not sure, but mostly of less importance, as an ugly scar can be easily corrected afterwards. After about two weeks the conjunctival sac is cut parallel to the eye split, and at such a distance from it where the inlay is nearest to the surface. The mould is removed, and the smoothly healed hollow is annexed to the eye-hole in order to receive the eye-prosthese, which must be placed directly, that the still elastic hollow can adapt itself to the prosthese form. It is now clear that the hollow must be constructed everywhere as near as possible to the mucous membrane (see Figs. 42-44).

II. With ear defects, a longer or shorter cut, according to the size of the defect, is made exactly along the hair growth, behind the ear. The skin in front with the periosteum is raised with the raspatorium, as far as the ear, and above and below the cut as required for the defect. The mould of dentical mass (Stent's) of this hollow, after hardening, is completely covered with Thiersch and placed in the hollow. The wound is then sewn together under pressure.

In all cases of this method it is important that the bottom of the wound is made as flat as possible that the Thiersch can be laid quite smoothly on the mould—and as the thin skin is very elastic this can be done without folds, though a fold would not prevent success. In very difficult cases I stick the Thiersch on the mould, and especially when deep tunnels with small openings are to be covered with epithelium, and where the mould with Thiersch must be pushed in with difficulty and under pressure. I stick with white of egg, but other

material may do perhaps. In my opinion the white of egg disappears quickly, and gives the possibility of removing the mould after one or two weeks without it sticking to the Thiersch. In the ear case after one week, the stitches are taken away,—the cut is again opened some days later, the mould removed, the hollow quite split from behind, and this cut enlarged above and below, till the flap is so movable that it can be used for a plastic of the ear. We have then two advantages over a direct plastic. First, the flap is already accommodated to its new pedicle nourishment, also the vessels of the pedicle have grown in that time; second, the flap is completely covered with skin at the back, and the place from where it was taken also, so that the conditions are not only advanced, but also clean.

III. The enlargement of the mucous membrane of the mouth often occurs in jaw injuries, or with patients who have retained, after extensive inflammation, scarred contractions of the mucous membrane, as with a patient in the "K. u. K. Reservespital, No. 17," where in consequence of intensive scorbutus, an inflammation of the gum and suppuration of the jaw, with ejection of sequestrum, arose and which healed with such a diminished mucous membrane, that the red of the under lip had grown to the jaw everywhere, and the entire fornix, on the sides, as far as both masseters had disappeared. In this case I made a vertical incision in the skin of the middle of the under lip, under the red part, and prepared from there to the left and right under the skin, in 3 inches depth and more than a thumb width, two hollows, which were filled with stents covered and stuck with Thiersch in the manner above described. A fortnight after, a cut was made inside the mouth, from one masseter to the other on the thinnest covering line of the stents, first with the knife, and after removing the inlay, the cavity was laid quite open with the scissors, which of themselves find the thinnest line of the cut. An impression of the under jaw was immediately taken, which had naturally not been possible before the operation, as one could not get down to the front surface; and immediately afterwards a prosthese was constructed (with all the teeth, which had been lost in consequence of the illness) and placed in the mouth. The under lip, which had formerly been perfectly immovable, had at once regained its use, both for speech and mimic. In other cases where the upper and under lip were curled inwards, the inlay was placed parallel with the mouth orifice, the same also removed after making a parallel cut in the mucous membrane. At both ends mobilization cuts were made so that the cavity formed could spread itself in an epithelial surface.

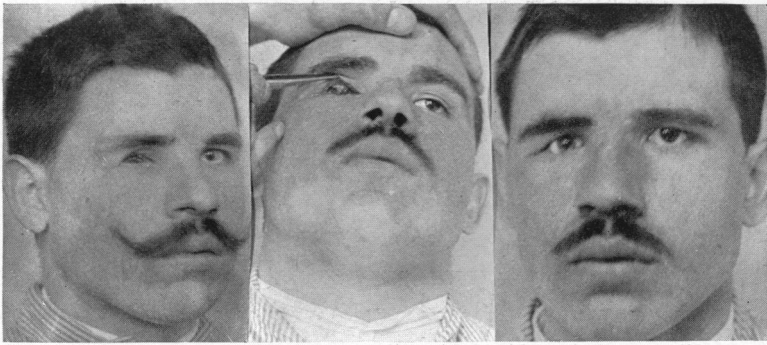


FIG. 42.

FIG. 43.

FIG. 44.

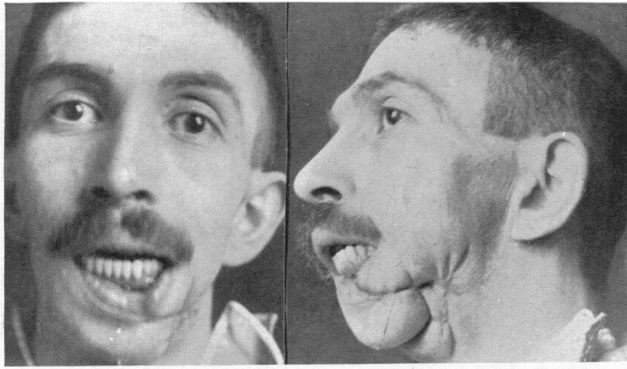
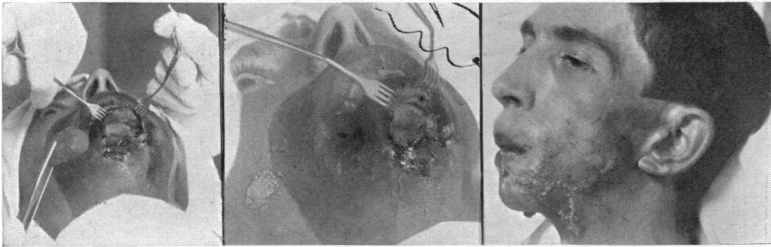


FIG. 45.

FIG. 46.

FIG. 47.

FIG. 48.



FIGS. 47 and 48.—Showing the procedure of "epidermic inlay," with the stents piece and the opened hollow entirely epithelized.

FIG. 49.—Patient after being operated (removing all scars and making the epidermic inlay). The sutures are not yet removed.

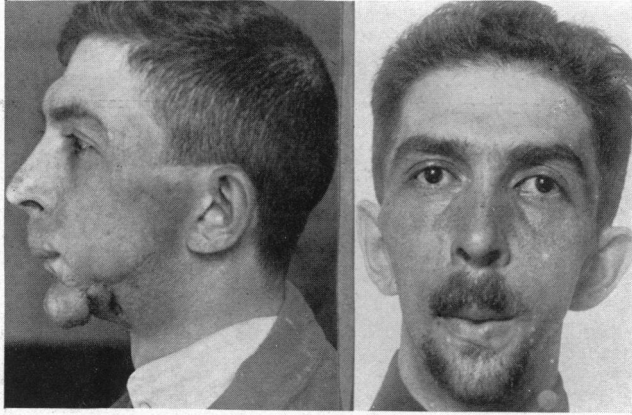
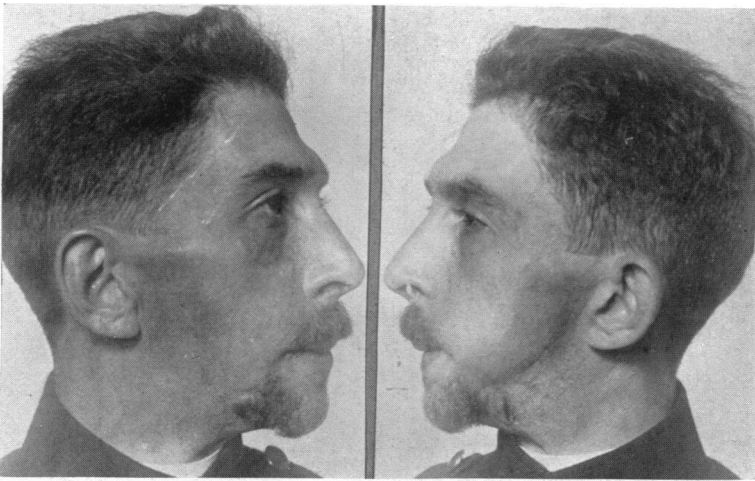


FIG. 50.—Patient with a maximal filling of the hollow with gauze in order to show its size.

FIG. 51.

FIG. 52.

FIG. 53.



FIGS. 51, 52 and 53.—Patient finished—the centre of the under jaw being replaced with a rubber lump of desired size and fixed in the definitive dental prosthesis.

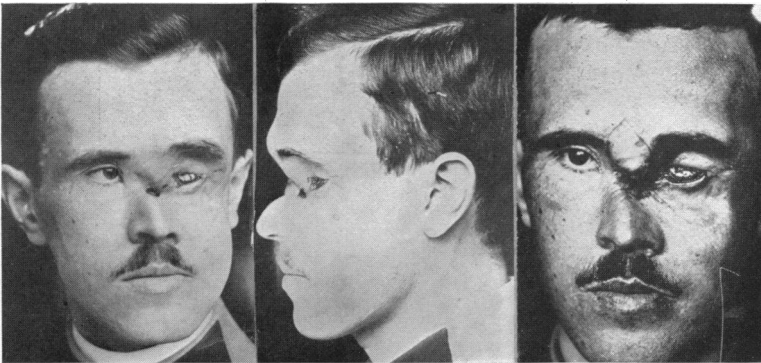


FIG. 54.

FIG. 55.

FIG. 56.

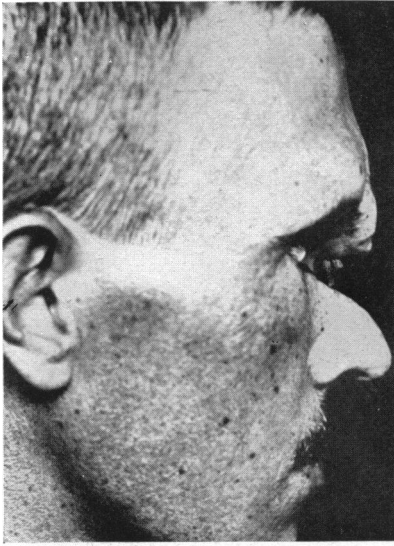


FIG. 57.

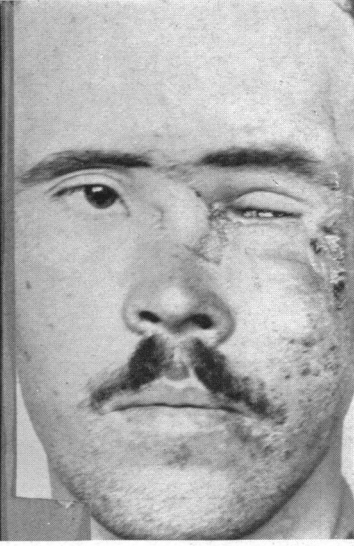


FIG. 58.

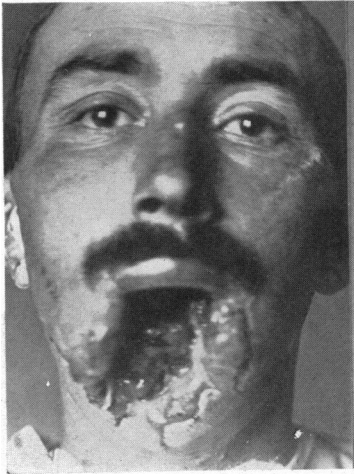


FIG. 59.

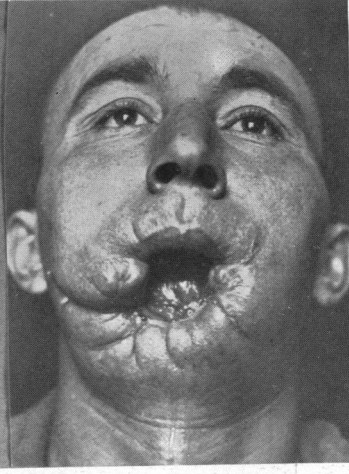


FIG. 60.

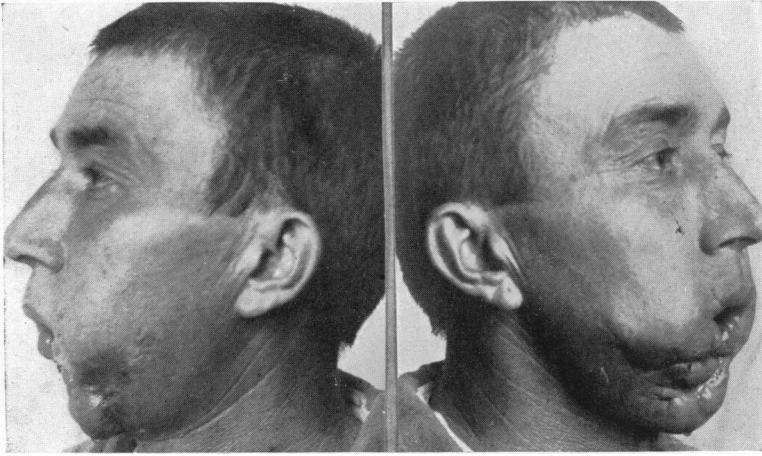


FIG. 61.

FIG. 62.

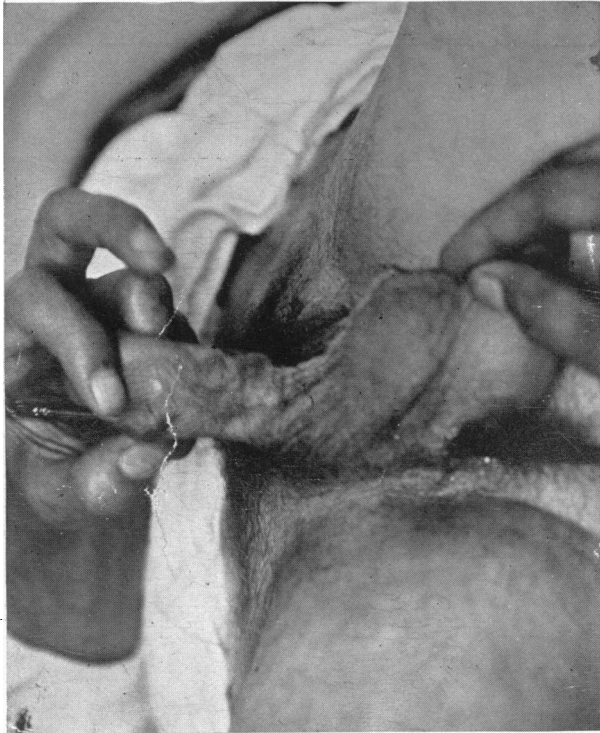

FIG. 63.

PLASTIC SURGERY OF THE FACE

IV. The enlargement of the mouth cavity is often necessary in normally large mucous membrane surfaces, if the tongue is so scarred at the front base as to affect speech and swallowing. In the same way as with the eye and ear plastics of this system, after removing the scar, a cross cut is made and a space formed, which is filled with stents mould, covered with Thiersch and then sewn together. Here also as with all such intra-oral plastics (contrary to my usual practice in order to avoid as far as possible the antiseptic), I have followed Professor Weiser's most emphatic advice, and put a layer of iodine gauze between the stents and the Thiersch. I have been very satisfied with the result. A still more frequent occurring indication lies in large bone defects of the centre of the under jaw, the so-called "bird face."

By cutting the outer skin, all inner scars in the ~~case~~ depicted in Figs. 45 and 46 (F., K. u. K. Res. Spit., 17, Vienna) were completely removed, and besides by internal enlargement, always working through the outer cut, a cavity was formed by pushing the jaw pieces apart, which when filled up under pressure presents normal anatomical conditions to the jaw line. This is not always possible without cutting the mucous membrane in vertical direction. When the elasticity of the membrane cut allows, this is sewn together horizontally, otherwise closed with a flap or left open, as an uncovered epidermical inlay, even in the mouth, may heal, but is not quite certain. After filling the cavity with stents mould, covered with Thiersch, ten days later this piece is removed, after cutting on it in the inside of the mouth. The cut enlarged with the scissors, as described above. Then the dentist, who must be present, takes an impression and quickly prepares a temporary prosthese without teeth. This must be exchanged later for the definite prosthese with teeth. This prosthese has to perform the following uses: To fill up the cavity, giving normal anatomical lines, and to support and connect, as in one piece, the jaw. The patient then looks quite normal and can always submit later to a bone plastic, whereby the soft tissues through their stretching and accommodating themselves to normal position offer better conditions for a bone plastic than was before. I speak here of patients who refuse a bone plastic, or of those who do not at present come into consideration. I show Figs. 45-49 of the proceeding so as to make easier to understand the method.

In palate plastics, particularly on hard palate defects, even of very large dimensions, this proceeding is of great value, as it not only considerably improves the prognosis of children born with divided palates, but also makes operations on very great defects possible, which were formerly considered practically inoperable. Case R, which I operated in the clinic of Professor Onodi (Budapest), belongs to the latter.

The mode of procedure is in a similar way as by Lane, but again more advantageous for the two reasons already mentioned in the ear plastic. First, on turning flap the same is everywhere skinned over and also the place from where it was taken, and besides the mouth clean. Second, for one or two weeks the flap has become accommodated to its new nourishment conditions, and the same has improved in the pedicle. In this interval the flap had no chance of shrinking or becoming infected, as in the procedure proposed by many surgeons, to perform the Lane operation in two instead of one treatment. Neither can granulations develop and cause later shrinking, which would in any case influence later the nourishment conditions and reduce the resistance and the bone growth of the periosteum flap.

According to the size of the defect, one makes at a greater or less distance from the defect, a curved cut on the processus alveolaris, through the gum and periosteum, raises it with the raspatorium, takes the impression, etc. In the second operation, after one or two weeks, the seam is again opened, enlarged above and below, till the flap is sufficiently mobile (naturally as little as possible, as the nourishment does not come from the centre of the pedicle but from the upper and under side, *vide* anatomy), then cut along the edge on the other side of the defect, and undermine till the turned flap, without being diminished, can be quite taken up (Lane). Then follows excoriation of both sides of that part of the flap which is to lie in the new wound and to be completely covered, then stitched. The sewing is in such a manner that the stitches which fix the turned flap edge into the depth of the wound are in pretty parallel line with the slit in palate. The second seam connects the free-made cut edge to the massive part of the over-turned flap.

Dr. Demmer (at the present time chief assistant in the clinic v. Hochenegg) has also successfully carried out my method, even in a very wide, totally double-sided slit of hard and soft palate.

V. The preparation of skin plastics has, first, the purpose of providing a flap with an inner covering of Thiersch where it has to cover a cavity, viz., in noses, eyes and mouth, second, for previous epithelialization of the place of removal of the pedicled flap, and, third, very often when wishing to combine simultaneously both the mentioned purposes. Such was the case with First Lieutenant K., in the clinic of v. Hochenegg, where a nose skeleton and soft part defect lay in the middle of the nose. Here, over the defect, an "epidermical inlay" was placed so that the pedicled flap, before being turned, received a skin covering on the inner side (Figs. 54-58).

Another case, R., in the K. u. K. Reservespital, Figs. 59-62, had a large under-lip defect. With this patient three chestnut-sized inlays were made; under, to the right and left of the defect, but not only to cover the inner part of the flap, but also under the chin to cover a secondary defect which would arise there.

VI. For strongly pronounced hypospadias this procedure is quite suitable, as shown in two cases in v. Hochenegg clinic, where in one case the urethra opened in the centre of the cloven scrotum. Finally, by pretty complete urethra plastic, I have applied an apparently similar, but in reality quite different, treatment. Instead of creating a cavity, or in this case a tunnel in the desired form, to take an impression of it, etc., I followed the contrary proceeding, which is not to be recommended except in this case. It would have been technically most difficult to take an impression of so long a tunnel without splitting the outer covering. Therefore I previously took a very wide rubber drainage-tube, 8 inches long, and made the tunnel freely according to the size of the tube. From a little cut on the perineum, a tunnel was made chiefly blunt under along the scrotum to the end of the præputium, by first pushing a trocar, then always thicker blunt instruments, till finally the handle of an elevator passed through the whole tunnel. It is clear that this work is more incorrect and in general cannot compete with the above-mentioned method; yet in this case I succeeded completely. I may mention that I split the rubber tube lengthwise, covered it with white of egg, let it dry, then cut the Thiersch in one piece, dried the same on the outer side of the skin, laid it along the tube so that the overturned parts joined on the split and were brought in and hidden in it. The result was a perfectly smoothly covered drain-tube, the Thiersch stuck on it with white of egg, and besides the edges were held fast in the split which had the inclination to close together; when introducing the tube into the tunnel the possible danger of rubbing the skin off the tube, which increases with the greatness of the pressure round the tube, will also diminish with it as the split is more firmly pressed together, and keeps the skin in its place. Also in this case (clinic v. Hochenegg) the flap, which was 8 inches long and 2 inches broad, healed completely. (See Fig. 63.)

By this method the following points are to be especially borne in mind:

(1) Correct choice and formation of the cavity, where care must be taken that when later on this is to be opened elsewhere, for instance, in the inside of the mouth, the epithelialized cavity has, as covering, the

least tissue possible there, so that only a very thin layer of the same must be cut; for this cut surface is not epithelialized and with time could become a very large scar.

Also the back part of the cavity must be as straight as possible, that the Thiersch may more easily be laid round the mould without creases. Of course the back of the mould must be laid in the centre of the Thiersch. The space should in a certain measure be funnel-shaped, that the first and last impression may be removed, and the skin-covered mould can be pushed in. Although a perforation of the wall must be carefully avoided, the Thiersch can bear much, and always heals quite smooth, even near chronic suppurations which are only dispersed with difficulty. I never saw a rise of temperature in the whole of my 24 cases. Once, in one case a necrose appeared on a very small part of the flap edge, and even the Thiersch round about it healed completely on the flap.

(2) The skin should be prepared only with tincture of iodine and careful avoidance of any other moisture. The skin is to be freed of all dead cells by thorough shaving, without soap or moisture, and then the Thiersch cut equally very thin, in one piece of the necessary size. It is important to cut the Thiersch only when its reception in the cavity can take place immediately, that this (as I rarely lay it in a physiological salt solution) can be laid at once around the mould and does not dry up on its wound surface.

(3) The mould should be very exact, and so large that the edges of the wound can be brought together, although it is of no essential disadvantage if the seam gapes even in the beginning.

(4) The stitches must be strong, and deeply taken so that they do not tear too soon.

(5) One must have patience before beginning the second operation; especially with tissues which are vascularized badly and are flaccid, for example the eyelids, so that they do not remain stretched over the mould, but will expand and slacken. With good technique the "epidermical inlay" is a sure procedure which may be still further used for new groups.

The seven named groups are all represented in my operations, but this method can be applied in many other cases, *e.g.*, for covering bone cavities, soft part defects; if a mould covered with Thiersch is put on the wound and pressed and fixed there, instead of being sewn. Professor Weiser used this variation of my method with good result for covering wounded surfaces inside the mouth. To keep a constant pressure with the mould on the Thiersch, he perforated the mould as well

PLASTIC SURGERY OF THE FACE

as the cheek with a kind of flat-headed nail, head in the mouth, and the projecting end was previously prepared to hold a nut, which pressed against a perforated plate, between which and the cheek iodine gauze was wrapped so thickly that the mould was firmly pressed on the Thiersch. The whole construction was very fine and functioned very well.

To make an outward auditory passage, this procedure can be used to prevent two parts from growing together, or to prevent definitively an existing growth. With penis skin or vagina plastics, even with bladder plastics, also rectum plastic, *e.g.*, when after extirpation of a rectum carcinoma an anus sacralis is laid on, the removed piece of intestine can be replaced by an epithelized cavity, which when perfectly ready, is bound on the one side with the central rectum piece, on the other with the sphincter, if it is still left—if not, it can be combined with a sphincter plastic (Schoemaker or other methods).

With carcinoma œsophagi the upper part of the œsophagus can be connected with the stomach with the "epidermical inlay" outside the chest, instead of the usual skin plastic, which is less sure.

In general the Thiersch application as substitute for mucous membrane has an important advantage, as the Thiersch accommodates more easily to the mucous membrane conditions, and undergoes a kind of successive membrane transformation, than is the case when using the entire skin with its complete skin formation, glands, etc. The skin in such conditions goes through a long stage of inflammation or eczema, while the Thiersch only shows particularly strong scaling in the mouth and eye cavities at the beginning.