

Visual evoked potential: a diagnostic tool for the assessment of hepatic encephalopathy

M L ZENEROLI, G PINELLI, G GOLLINI, A PENNE, E MESSORI,
G ZANI, AND E VENTURA

From the Clinica Medica III, Clinica Oculistica, Clinica Neurologica, Università di Modena, Modena, Italy

SUMMARY Visual evoked potential recordings were examined in 45 liver cirrhosis patients with (n=29) and without (n=16) encephalopathy, in 15 normal volunteers, and in one patient with an opioid induced stupor state. Visual evoked potential parameters were classified on the basis of EEG recordings. Plasma concentrations of amino acids, octopamine, and ammonia were assayed in order to document the metabolic change of hepatic encephalopathy. Latencies and wave patterns recorded after flash stimulation differentiated the four degrees of the coma one from another according to EEG classification in the 29 patients with encephalopathy. In the group of 16 patients without clinical and EEG evidence of encephalopathy the visual potential recordings discriminated a group of patients (n=10) in a preclinical stage of encephalopathy. Biochemical parameters and subsequent clinical observation of patients confirmed our judgement of a preclinical stage of encephalopathy. These results suggest that visual evoked potentials are a simple, suitable and objective method for differentiating the degrees of encephalopathy and for identifying the preclinical stage of encephalopathy.

Clinical observation of the neuropsychiatric condition,¹⁻⁴ psychometric tests,⁵⁻⁷ and EEG recordings^{1-3, 8} have been used to differentiate the degrees of hepatic encephalopathy due to liver cirrhosis, but none of them seems objective or sensitive enough to quantify the degree of coma, nor to detect, as well, the preclinical stages of hepatic encephalopathy.

Visual evoked potentials were first used in detecting abnormalities of the visual system⁹ and of many neurological diseases with visual symptoms such as multiple sclerosis,¹⁰⁻¹² Parkinson's disease,^{13, 14} and Friedreich's ataxia.¹⁵ They are now utilised in studying the effect on the brain of psychotropic drugs¹⁶ and, recently, in the evaluation of uraemic coma.¹⁷ This is because there is evidence that visual evoked potentials can reflect not only pure optic nerve diseases but also demyelination processes^{10, 18} and neurotransmitter changes¹⁹ in cortical and subcortical neurones. In fact, visual evoked potential recording has proved a reliable and specific method in the evaluation and quantification of the neurological changes of experimental hepatic encephalopathy.²⁰⁻²² A brief stimulus such as a flash

of light elicits postsynaptic potential changes of subcortical and cortical neurones through stimulation of visual areas. The resulting response of the cortex will appear at the same interval after the stimulus as opposed to the on-going EEG which is random. By storing the EEG trace for a preselected period after the stimulus and by averaging these tracers it is possible to cancel the random components of EEG and to average the evoked response.^{23, 24}

The aim of this investigation was to evaluate the diagnostic value of the visual evoked potential method as an objective measurement of hepatic encephalopathy in liver cirrhosis patients and possibly as a test for recognition of the preclinical stage of hepatic encephalopathy.

Methods

PATIENTS

Visual evoked potentials were first recorded in 15 normal subjects of both sexes with ages ranging between 32 and 60 years. In order to establish the reliability of the method several repetitions of visual evoked potential recording were performed on different days and at different hours.

Address for correspondence: Dr M L Zeneroli, Clinica Medica III, Università di Modena, Via del pozzo, 41100 Modena, Italy.

Received for publication 3 June 1983

After this preliminary investigation, 45 liver cirrhosis patients of both sexes, with ages ranging between 34 and 54 years and of mixed aetiology were studied. The diagnosis of liver cirrhosis was based on biochemical, scintigraphic, oesophago-gastroscopic findings and on liver biopsy. Three of the patients had portocaval anastomosis. Sixteen patients did not show any evidence of encephalopathy and two of them were further examined a few weeks after the first study when they showed symptoms of encephalopathy. The other 29 patients showed an impaired mental status of different degree; one of them with very severe encephalopathy and with portocaval anastomosis was tested again after a partial recovery from encephalopathy. With the aim of selecting patients with spontaneous episodes of encephalopathy, patients receiving therapies – that is, lactulose or neomycin – diuretics or sedatives or with hyperazotaemia, hyperglycaemia and gastrointestinal bleeding were excluded from this study. Patients were tested by EEG and visual evoked potential recording within one hour and venous blood samples were collected for ammonia, octopamine, and amino acid analyses at the same time as the tests.

During this study we had occasion to perform a visual evoked potential in one non-cirrhotic patient with a profound opioid induced stupor state.

ELECTROPHYSIOLOGICAL STUDIES

Electroencephalograms were performed on a Beckman Accutrace 200A using standard 20 electrode placements and they were read by a single neurologist, according to the Rohmer and Kurtz⁸ classification.

For visual evoked potential recording patients were in the dark in an electrically shielded Faraday room. Two AgCl electrodes were applied to the scalp with collodium. The active electrode was placed at Oz (international 10–20 system) and connected to the negative input (IT 2) of a differential amplifier (filter bandwidth: 2–70 Hz, 60 db/decade), while the reference electrode was placed at Fz.²⁵ The left earlobe was grounded. Interelectrode impedance was reduced to <5 K Ω with light abrasion of the scalp, using salt gel as a conducting medium. As a stimulating device a 50 cm diameter dome was used, which by reflection on its inner white wall provided the light stimulus, generated by a xenon lamp flash lasting 10 msec. The energy of the lamp was 1 J and the stimulation frequency 1 Hz. Patients were in a bed under the stimulator, the distance of the dome pole from the eyes being approximately 55 cm, pupils were fully dilated with 0.5% tropicamide and 10% phenylephrine (Visumidriatic fenilefrina) and they were examined

with closed eyes, in order to have normal subjects and comatose patients in similar conditions. The hemisphere gives a large field stimulation minimising any visual evoked potential variation due to changes of the position of the eyes, which occur in comatose patients. Furthermore, the closed lids act as a diffuser, so that fixation was not a factor appreciably influencing the response. After differential amplification the signals were fed into an Ortec Averager; 64 responses were averaged, shown on an oscilloscope and then recorded on paper by an X–Y plotter. Visual evoked potentials were classified according to EEG evaluation.

To exclude purely optical interference on visual evoked potential changes an ophthalmological examination was performed when patients were able to cooperate: this consisted of visual acuity, confrontation of visual fields, pupil reflexes and funduscopy. To the same end three patients with most severe liver cirrhosis were tested by electroretinography.³⁶

Student's *t* test was used to compare the visual evoked potential latency values.

BIOCHEMICAL PARAMETERS

In order to characterise better the hepatic encephalopathy, venous blood ammonia levels were assayed with enzymatic UV method;²⁷ octopamine was measured with a radioenzymatic method;^{28, 29} plasma amino acid analyses were performed using Kontron amino acid analyser (Liquimat III, Switzerland). Free plasma tryptophan was assayed with the chromatographic-fluorimetric method.^{30–32}

Student's *t* test was used for statistical analyses.

Results

ELECTROPHYSIOLOGICAL STUDIES

Electroencephalogram recordings divided the cirrhotic patients into: 16 cases having an EEG pattern degree 0 (HE₀), eight cases degree 1 (HE₁), seven cases degree 2 (HE₂), six cases degree 3 (HE₃), and eight cases degree 4 (HE₄) according to the Rohmer and Kurtz classification,⁸ as shown in Fig. 1. Two patients studied first in HE₀ were subsequently examined respectively in HE₁ and HE₂. The patient with portocaval anastomosis, studied first in degree 4, was subsequently examined when he had recovered to degree 2.

The visual evoked potentials recorded in normal subjects consisted of negative and positive waves labelled N₁, P₁, N₂, P₂, N₃ (Fig. 2). The range of the latencies of the peaks were respectively 34–40, 44–65, 60–90, 110–138, 168–190 msec.³³ As regard reliability, visual evoked potential waveforms recorded on different days in the same subject

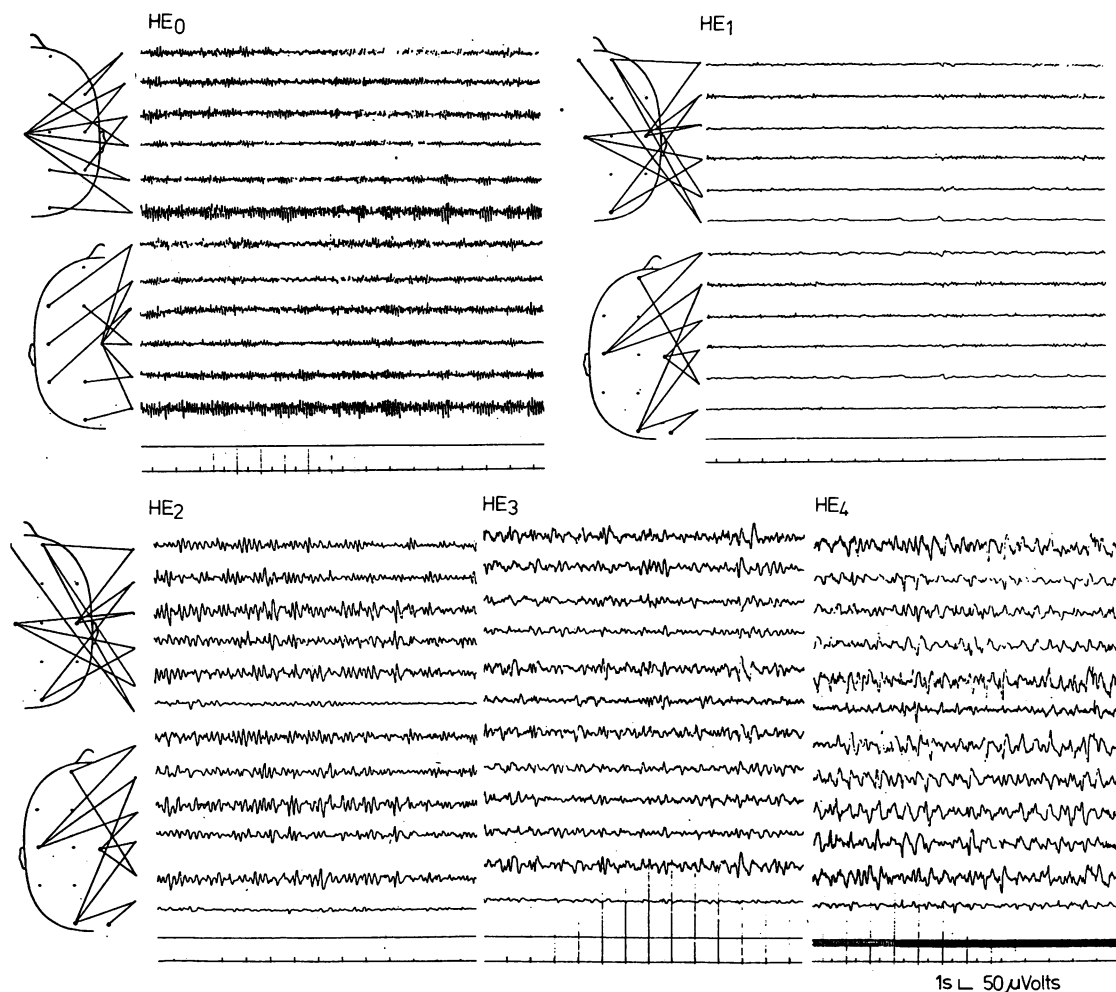


Fig. 1 Typical patterns of EEG recorded in one patient without encephalopathy (HE₀) and in patients with encephalopathy degree 1 (HE₁), 2 (HE₂), 3 (HE₃) and 4 (HE₄).

revealed a constant pattern with respect to the latencies, while a slight variation in the amplitudes was seen, as previously described.³⁴ For this reason we have taken into consideration in this study only the latency values and the general patterns.

The group of 16 liver cirrhosis patients free from any clinical and EEG symptoms of encephalopathy with regard to the visual evoked potential pattern apparently comprised two different populations (Fig. 2). Six patients (HE_{O-I}) had a visual evoked potential pattern similar to the visual evoked potential pattern recorded in normal subjects with a latency of N₃ ranging between 162–180 msec. Ten patients (HE_{O-II}) had a visual evoked potential pattern with delayed N₃ latency (range 220–260

msec, $p < 0.01$ vs controls and HE_{O-I}). Visual evoked potentials recorded in patients with encephalopathy are shown in Fig. 3. Patients classified in HE₁ group on the basis of EEG recording showed a waveform similar to those previously described but with a further delay of N₃ wave in comparison with HE_{O-II} (range 230–340 msec). These values were significantly different from controls and from HE_{O-I} ($p < 0.001$), but not from HE_{O-II}. Patients with degree 2 showed the disappearance of the first negative wave N₁; as a consequence the whole pattern consisted of only four waves, the first one being positive with a latency of the last negative wave ranging between 225–290 msec. The same four wave pattern was

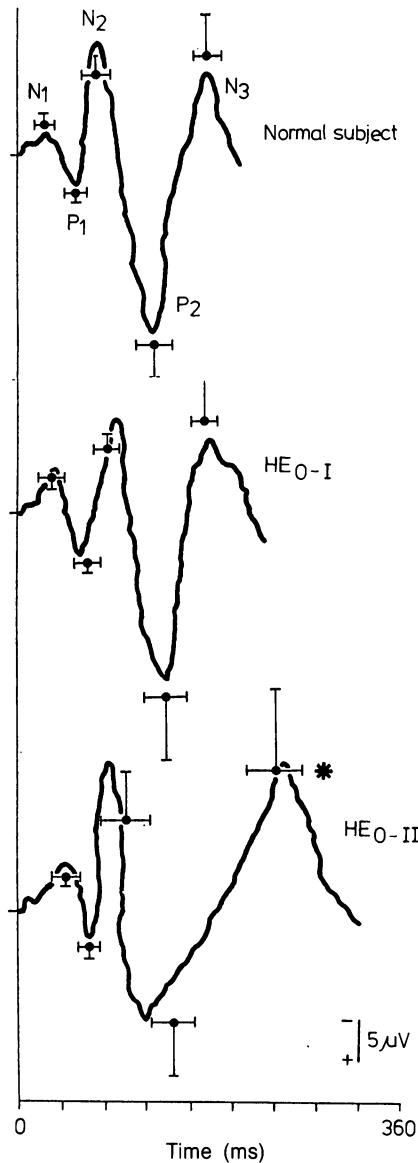


Fig. 2 Visual evoked potentials recorded in one normal subject (upper panel) and in liver cirrhosis patients without neurological and EEG symptoms of encephalopathy (HE_{0-I} in central panel and HE_{0-II} in lower panel). Vertical bars represent mean ± 1 SD of the amplitudes, horizontal bars represent the mean ± 1 SD of the latency of the nearest peak of all studied subjects. Student's *t* test: * $p < 0.01$ vs normal subjects and HE_{0-I} .

recorded in patients of group HE_3 , but with a further delay of the last negative wave (range 300–450 msec; $p < 0.01$ in comparison with the latency of HE_2 group). The pattern of HE_4 was further simplified, consisting only of three waves (negative, positive, negative) without changes in the latency of the last wave (range 290–400 msec).

Of the three patients recorded twice in different clinical conditions one of the two recorded first as HE_{0-II} entered HE_1 on the second examination and showed a delay of 30 msec of N_3 in comparison with the first recording; the other entered HE_2 showing the disappearance of the 1st negative wave reproducing the typical pattern of HE_2 .

This classification was in agreement with EEG recording. The patient with portocaval anastomosis, recorded firstly in HE_4 , revealed the reappearance of the first positive wave when he had recovered to degree 2 (Fig. 4).

We did not detect any visual evoked potential differences related to the different aetiology of liver cirrhosis.

As shown in Fig. 5, the patient in a profound stupor state due to an opioid overdose, had a shortening of N_3 latency (140 msec) indicating that the changes of visual evoked potential pattern recorded in hepatic encephalopathy were not simply related to the lack of attention or fixation of patients.

The three patients subjected to electroretinogram examination showed normal tracings excluding any influence of vitamin A depletion described in liver cirrhosis^{35 36} on visual evoked potential pattern.

BIOCHEMICAL PARAMETERS

Table 1 reproduces some of the biochemical data of patients showing the described^{37–41} variations of plasma essential amino acids, plasma amino acid molar ratios, octopamine, and of ammonia levels during coma. In order to clarify the reasons why patients without clinical and EEG evidence of encephalopathy had two different visual evoked potential patterns, we examined the biochemical parameters of these patients and found that patients with increased N_3 latency (HE_{0-II}) showed evidence of incipient encephalopathy. We therefore divided these parameters according to visual evoked potential classification. This distinguished HE_{0-II} and HE_1 from HE_{0-I} .

Discussion

The study in normal subjects showed that visual evoked potential is a reliable method and that latencies and waveforms are constant. This reliability depends on a few constant factors maintained

Fig. 3 Visual evoked potentials in liver cirrhosis patients with encephalopathy. HE₁ panel represents the visual evoked potential pattern in one patient with encephalopathy degree 1, HE₂ panel represents visual evoked potential in one patient with HE degree 2, HE₃ and HE₄ panels represent respectively visual evoked potentials recorded in patients with encephalopathy degrees 3 and 4. Means and SD of all studied subjects are reported as described in Fig. 1. Student's t test: ** $p < 0.001$ vs normal subjects, * $p < 0.01$ vs HE₂.

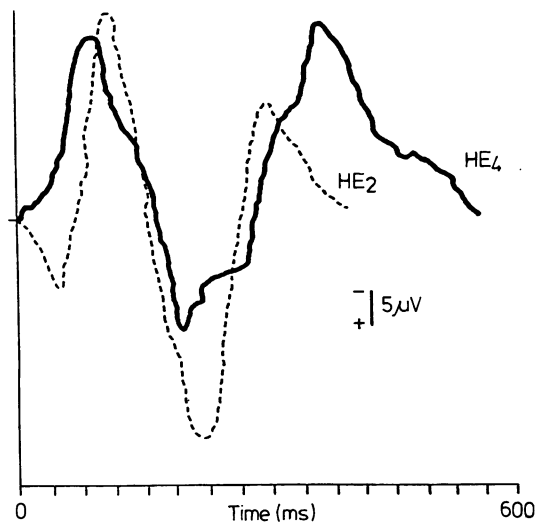
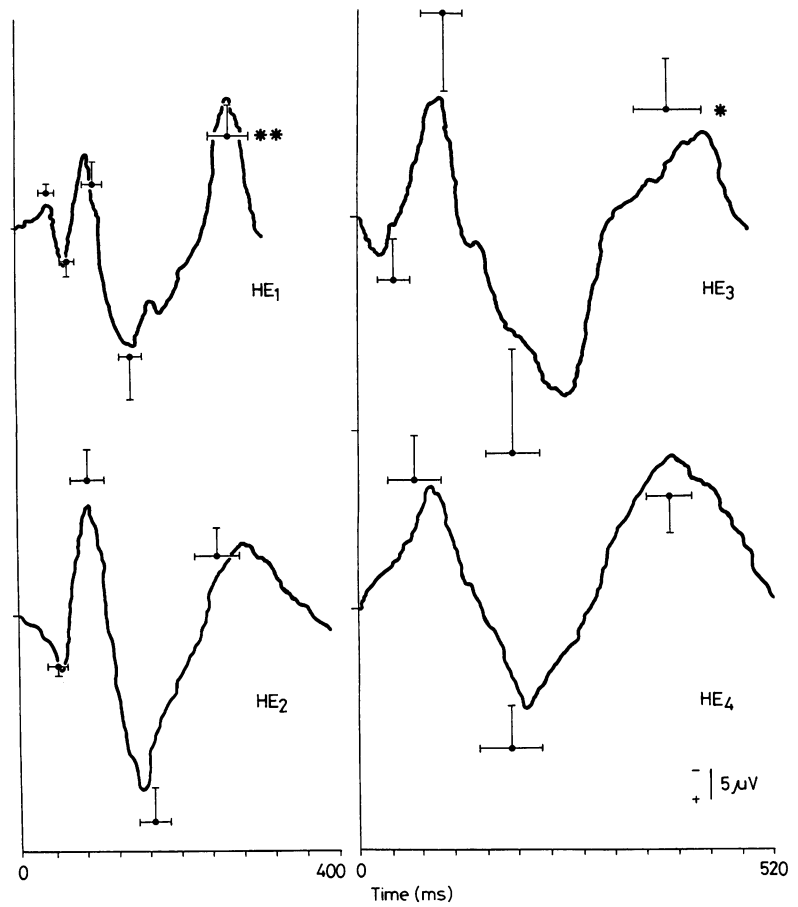


Fig. 4 Visual evoked potential patterns recorded in the patient with portocaval anastomosis examined twice in degree 4 of encephalopathy (—, HE₄) and in degree 2 of encephalopathy (---, HE₂).

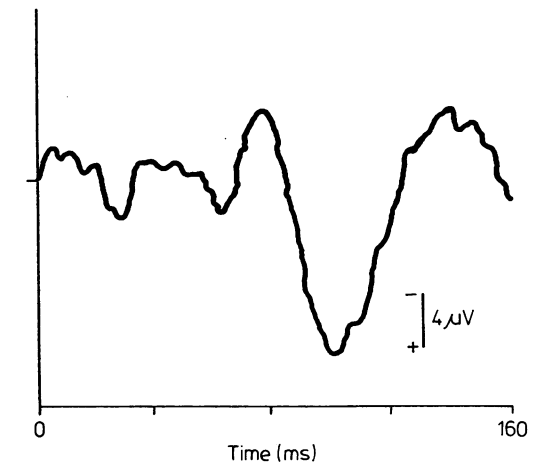


Fig. 5 Visual evoked potential recording in the patient with opioid induced stupor state.

Table Means \pm 1 SD of serological parameters of all studied subjects and Student's t test analyses between groups

Essential amino acids ($\mu\text{mol/l}$)	C	HE_{O-1}	HE_{O-II}	HE_1	HE_2	HE_3	HE_4	Student's t test		
								C- HE_{O-1}	HE_{O-1} - HE_{O-II}	HE_{O-1} - HE_1
Threonine	122 \pm 18	150 \pm 31	142 \pm 45	126 \pm 60	109 \pm 37	177 \pm 58	161 \pm 57	-	-	-
Valine (Val)	259 \pm 24	216 \pm 44	190 \pm 31	144 \pm 37	138 \pm 57	133 \pm 30	137 \pm 25	-	-	-
Leucine (Leu)	152 \pm 34	109 \pm 27	92 \pm 21	76 \pm 21	72 \pm 38	78 \pm 22	85 \pm 25	*	*	-
Isoleucine (Ileu)	78 \pm 14	58 \pm 12	49 \pm 11	40 \pm 10	40 \pm 12	48 \pm 18	39 \pm 12	*	-	-
Methionine (Met)	23 \pm 6	32 \pm 9	44 \pm 23	52 \pm 29	48 \pm 15	60 \pm 13	93 \pm 34	-	-	-
Tyrosine (Tyr)	68 \pm 11	77 \pm 13	138 \pm 30	141 \pm 71	136 \pm 80	151 \pm 31	156 \pm 29	-	+	-
Phenylalanine (Phe)	62 \pm 10	59 \pm 13	82 \pm 22	78 \pm 26	83 \pm 38	106 \pm 15	129 \pm 78	-	*	-
Lysine	183 \pm 25	173 \pm 32	149 \pm 57	155 \pm 101	183 \pm 102	223 \pm 28	219 \pm 107	-	-	-
Tryptophan (TRP) total	67 \pm 14	65 \pm 17	72 \pm 17	56 \pm 13	50 \pm 5	45 \pm 8	43 \pm 9	-	-	-
free	9 \pm 2	8 \pm 2	16 \pm 5	17 \pm 5	27 \pm 1	26 \pm 4	26 \pm 8	-	-	*
% free	13 \pm 4	13 \pm 6	26 \pm 3	35 \pm 14	54 \pm 5	62 \pm 19	59 \pm 2	-	-	*
Val + Leu + Ileu + Phe + Tyr	3.75 \pm 0.38	2.82 \pm 0.26	1.44 \pm 0.50	1.30 \pm 0.32	1.18 \pm 0.24	0.96 \pm 0.18	0.83 \pm 0.15	+	+	+
free TRP	0.013 \pm 0.001	0.014 \pm 0.005	0.032 \pm 0.008	0.034 \pm 0.012	0.062 \pm 0.024	0.044 \pm 0.009	0.045 \pm 0.018	-	*	-
Val + Leu + Ileu + Phe + Tyr + Met	0.85 \pm 0.36	1.02 \pm 0.15	1.71 \pm 0.58	2.0 \pm 0.58	3.9 \pm 2.2	5.2 \pm 1.0	6.0 \pm 2.1	-	+	-
Octopamine (ng/ml)	69 \pm 12	78 \pm 10	109 \pm 30	136 \pm 34	154 \pm 43	208 \pm 53	227 \pm 34	-	*	-
Ammonia ($\mu\text{g/dl}$)								-	-	-

C represents control group. Student's t test between groups is represented by - when NS, * $p < 0.05$, † $p < 0.01$, ‡ $p < 0.001$.

during the study: stimulus frequency and intensity, position of recording electrodes, size of pupils and distance of the lamp. For this reason results from one laboratory are not fully applicable to another when apparatus and recording conditions are different.^{34 42}

This method proved objective and sensitive enough in grading the different stages of hepatic encephalopathy as substantial differences between the four degrees of coma were documented. Differentiating parameters seem to be the latency of the N₃ wave for HE₁ vs HE_{0-I}, the wave pattern for HE₂ vs HE₁, the latency of the last negative wave for HE₃ vs HE₂, and the wave pattern for HE₄. On the basis of the visual evoked potential changes recorded in the same liver cirrhosis patients with different neurological conditions, and in accordance with study during sleep or anaesthesia,^{43 44} these patterns seem to reflect the neurological disturbance variations occurring in the brain during hepatic encephalopathy.

Both visual evoked potential and EEG are an expression of postsynaptic cellular potential activity,^{45 46} but the advantages of visual evoked potential as compared to EEG are (a) the synchronisation of cellular activity of the cortical neurons by flash stimulus, (b) the recording by averaging several responses to stimuli, (c) the performance not being time consuming, (d) the simplicity in quantifying and comparing waves so that every member of an intensive care unit can exactly evaluate the degree of coma.

Another important point in favour of the visual evoked potential is the fact that it appears to be a sensitive method in the recognition of the preclinical stage of hepatic encephalopathy. In fact, with this method we could select as abnormal a group of patients (HE_{0-II}) who appeared normal to neuropsychiatric examination and to EEG recording. Biochemical parameters and the observation of a clear encephalopathic state which two of these patients developed a few weeks later suggested that these subjects were in a preclinical stage of hepatic encephalopathy when tested.

So far, there are considerable difficulties in detecting the preclinical stage of hepatic encephalopathy. Electroencephalographic studies after administration of morphine or a high protein diet or ammonium salts⁴⁷⁻⁴⁹ cannot be considered as routine tests and psychometric tests^{5-7 50} are imprecise and liable to tolerance.^{7 51} Of all proposed tests, the continuous reaction time⁷ seems sensitive and objective in the evaluation of the latent state of hepatic encephalopathy, but it seems unsuitable in the evaluation of the severe stage of hepatic encephalopathy, while visual evoked poten-

tial recording is able to provide a complete examination in all stages.

In summary, on the basis of this preliminary study visual evoked potential recording seems to be a suitable and objective method for the comprehensive evaluation of the different degrees of encephalopathy due to cirrhosis of the liver and of the preclinical stage of encephalopathy. The advantages of visual evoked potential could therefore be of service in the follow up of outpatients with liver cirrhosis in order to prevent the occurrence of encephalopathy and it could be useful in monitoring inpatients during therapy.

These data were partially presented to the 17th EASL meeting, Göteborg, 1982. The authors are grateful to Mrs Giovanna Caselgrandi for her valuable technical assistance with the biochemical assay and to Mr Luciano Gatti for his technical assistance with the EEG recordings.

References

- 1 Adams RD, Foley JM. The neurological disorders associated with liver disease. *Res Publ Ass Nerv Ment* 1953; **32**: 198-237.
- 2 Sherlock S, Summerskill WHJ, White LP, Pear EA. Portal systemic encephalopathy. Neurological complications of liver diseases. *Lancet* 1954; **2**: 453-7.
- 3 Parson-Smith BC, Summerskill WHJ, Dawson AM, Sherlock S. The electroencephalograph in liver disease. *Lancet* 1957; **2**: 867-71.
- 4 Conn HO, Leevy CM, Vlahcevic ZR *et al*. Comparison of lactulose and neomicin in the treatment of chronic portal-systemic encephalopathy. *Gastroenterology* 1977; **72**: 573-83.
- 5 Conn HO, Lieberthal MM. Assessment of mental state. In: Conn HO, Lieberthal MM, eds. *The hepatic coma syndromes and lactulose*. Baltimore, London: Williams and Wilkinson, 1980: 169-88.
- 6 Zeegen R, Drinkwater JE, Dawson AM. Method for measuring cerebral dysfunction in patients with liver disease. *Br Med J* 1970; **2**: 633-6.
- 7 Elsass P, Christensen SE, Ranek L, Theilgaard A, Tygstrup N. Continuous reaction time in patients with hepatic encephalopathy. A quantitative measure of changes in consciousness. *Scand J Gastroenterol* 1981; **16**: 441-7.
- 8 Rohmer F, Kurtz D. EEG et ammoniémie dans les troubles nerveux des affections hépatiques. In: *Proceedings of VII International Congress of Neurology*, Rome: Società Grafica Romana, 1961: 171-219.
- 9 Halliday AM, McDonald WI, Mushin J. Delayed pattern evoked responses in optic neuritis in relation to visual acuity. *Trans Ophthalmol Soc UK* 1973; **93**: 315-24.

- 10 Halliday AM, McDonald WI, Mushin J. Delayed visual evoked response in optic neuritis. *Lancet* 1972; **1**: 982-5.
- 11 Halliday AM, McDonald WI, Mushin J. Visual evoked response in diagnosis of multiple sclerosis. *Br Med J* 1973; **4**: 661-4.
- 12 Milner B, Regan A, Heron JR. Differential diagnosis of multiple sclerosis by visual evoked potential recording. *Brain* 1954; **97**: 755-72.
- 13 Bodis-Wollner I, Yahr MD. Measurements of visual evoked potential in Parkinson's disease. *Brain* 1978; **101**: 661-71.
- 14 Gawel MJ, Das P, Vincent S. Visual and auditory responses in Parkinson's disease. In: Rose FC, Capilodea R, eds. *Research progress in Parkinson's disease*. Bath, England: Pitman Medical, 1981: 138-46.
- 15 Carroll WM, Kriss A, Baraitso M, Barrett G, Halliday AM. The incidence and nature of visual pathway involvement in Friedreich's ataxia: a clinical and visual evoked potential study of 22 patients. *Brain* 1980; **103**: 413-34.
- 16 Shagass C, Straumanis JJ. Drugs and human sensory evoked potentials. In: Lipton MA, Di Mascio A, Killam KF, eds. *Psychopharmacology. A generation of progress*. New York: Raven Press, 1978: 699-728.
- 17 Hamel B, Bourne JR, Ward JW, Teschan PE. Visually evoked potentials in renal failure: transient potentials. *Electroencephalogr Clin Neurophysiol* 1978; **44**: 606-16.
- 18 McDonald W, Sears TA. The effects of experimental demyelination on conduction in the central nervous system. *Brain* 1970; **93**: 583-98.
- 19 Bodis-Wollner I, Onofry M. System disease and visual evoked potential diagnosis in neurology: changes due to synaptic malfunction. *Ann NY Acad Sci* 1981; **388**: 327-48.
- 20 Schafer DF, Brody LE, Jones EA. Visual evoked potentials: an objective measurement of hepatic encephalopathy in the rabbit. [Abstract] *Gastroenterology* 1979; **77**: A38.
- 21 Zeneroli ML, Penne A, Parrinello G, Cremonini C, Ventura E. Comparative evaluation of visual evoked potentials in experimental hepatic encephalopathy and in pharmacological induced coma-like states in rat. *Life Sci* 1981; **28**: 1507-15.
- 22 Zeneroli ML, Ventura E, Baraldi M, Penne A, Messori E, Zieve L. Visual evoked potentials in encephalopathy induced by galactosamine, ammoniumdimethylsulfide and octanoic acid. *Hepatology* 1982; **2**: 532-8.
- 23 Dawson GD. A summation technique for the detection of small potentials. *Clin Neurophysiol* 1954; **6**: 65-84.
- 24 Halliday AM, Pitman JR. A digital computer averager for work on evoked responses. *J Physiol* 1965; **178**: 23P.
- 25 Jasper HH. The ten-twenty electrode system of the International Federation. *Electroencephalogr Clin Neurophysiol* 1958; **10**: 371-5.
- 26 Galloway NR. The visually-evoked potential. *Br Ortop J* 1979; **36**: 1-6.
- 27 Fonseca J, Wolheim FZ. Zeitschrift fur Klinische Chemie und Klinische biochemie. *Klin Chem Klin Biochem* 1973; **11**: 421-6.
- 28 Saavedra JM. Enzymatic-isotopic method for octopamine at the picogram level. *Anal Biochem* 1974; **59**: 628-33.
- 29 Axelrod J. Purification and properties of phenylethanolamine-N-methyl level. *J Biol Chem* 1962; **237**: 1657-60.
- 30 Stefanini E, Biggio G. A simple method for determination of free Tryptophan in serum. *Riv Farm Terap* 1975; **6**: 49-54.
- 31 Denckla WD, Denwey HK. The determination of tryptophan in plasma, liver and urine. *J Lab Clin Med* 1967; **69**: 160-6.
- 32 Costa E, Spano PF, Groppetti A, Algeri S, Neff NH. Simultaneous determination of tryptophan, tyrosine, catecholamines and serotonin specific activity in rat brain. *Atti Accad Med Lomb* 1968; **23**: 1100-4.
- 33 Zeneroli ML, Cremonini C, Pinelli G et al. Visual evoked potentials: a tool to discriminate preclinical and clinical stages of hepatic encephalopathy. [Abstract] *Gastroenterol Clin Biol* 1982; **6**: A812.
- 34 Chiappa KH, Ropper AH. Evoked potentials in clinical medicine (first of two part) *N Engl J Med* 1982; **306**: 1140-50.
- 35 Genest A. Vitamin A and the electroretinogram in humans. In: Francois J, ed. *The clinical value of electroretinography*. Basel, New York: Karger, 1968: 250-7.
- 36 Schmidt B. Electroretinographic investigation on dark adaptation in liver cirrhosis. In: Francois J, ed. *The clinical value of electroretinography*. Basel, New York: Karger, 1968: 267-73.
- 37 Zieve L. Hepatic encephalopathy: summary of present knowledge with an elaboration of recent developments. In: Popper H, Schaffner F, eds. *Progress in liver diseases*. New York: Grune and Stratton, 1979: 327-41.
- 38 Fisher JE, Baldessarini RJ. Pathogenesis and therapy of hepatic coma. In: Popper H, Schaffner F, eds. *Progress in liver diseases*. New York: Grune and Stratton, 1975: 363-97.
- 39 Cascino A, Gangiano C, Calcaterra V, Rossi-Fanelli F, Capocaccia L. Plasma amino acids imbalance in patients with liver disease. *Am J Dig Dis* 1978; **23**: 591-8.
- 40 Morgan M, Milson JP, Sherlock S. Plasma ratio of valine, leucine and isoleucine to phenylalanine and tyrosine in liver diseases. *Gut* 1978; **10**: 1068-73.
- 41 Fiaccadori F, Ghinelli F, Pelosi G et al. Selective aminoacid solutions in hepatic encephalopathy treatment. A preliminary report. *Ric Clin Lab* 1980; **10**: 411-22.
- 42 Taylor FM. The technique of recording visual evoked responses some pitfalls and results. *J Electrophysiol Technol* 1976; **2**: 211-22.
- 43 Corletto F, Gentilomo A, Rosadini A, Rossi GF, Zattoni J. Visual evoked responses during sleep in man. *Electroencephalogr Clin Neurophysiol* 1967; **26**: 61-73.
- 44 Bergamini L, Bergamasco B. Possibility of the clinical use of sensory evoked potentials transcranially recorded in man. *Electroencephalogr Clin Neurophysiol* 1967; **26**: 114-27.
- 45 Creutzfeldt OD, Fuster JM, Lux HD, Nacimiento AC.

- Experimenteller Nachweis von Beziehungen zwischen EEG-Wellen und Aktivität corticaler Nervenzellen. *Naturwissenschaften* 1964; **51**: 166–7.
- 46 Creutzfeldt OD, Watanabe S, Lux HD. Relations between EEG phenomena and potentials of single cortical cells. II. Spontaneous and convulsoid activity. *Electroencephalogr Clin Neurophysiol* 1966; **20**: 19–37.
- 47 Laidlaw J, Read AE. The electroencephalographic diagnosis of manifest and latent delirium with particular reference to that complicating hepatic cirrhosis. *J Neurol Neurosurg Psychiatry* 1961; **24**: 58–70.
- 48 Laidlaw J, Read AE. The EEG in hepatic encephalopathy. *Clin Sci* 1963; **24**: 109–20.
- 49 Jones DP, Binnie CD, Brown RL, Lloyd DSL, Watson BW. The contingent negative variation and psychological findings in chronic hepatic encephalopathy. *Electroencephalogr Clin Neurophysiol* 1976; **40**: 661–5.
- 50 Marchesini G, Zoli M, Dondi C *et al.* Prevalence of subclinical hepatic encephalopathy in cirrhosis and relationship to plasma amino acid imbalance. *Dig Dis Sci* 1980; **25**: 763–9.
- 51 Zeegan R, Drinkwater JE, Dawson AM. Method for measuring cerebral dysfunction in patients with liver disease. *Br Med J* 1970; **2**: 633–6.