

*Occasional report*

## Pancreatography in chronic pancreatitis: international definitions

A T R AXON, M CLASSEN, P B COTTON, M CREMER,  
P C FREENY, AND W R LEES

*International Workshop, King's College, Cambridge*

**SUMMARY** Terminology in classification of pancreatograms was discussed at a recent international workshop on chronic pancreatitis.<sup>1</sup> A new terminology based on morphological radiographic appearances and a new classification to describe the severity and localisation of pancreatogram changes were agreed. Pancreatograms in chronic pancreatitis are graded as normal or equivocal, or as showing mild, moderate, or marked changes, either diffuse or local. It is hoped that these definitions will help communication between centres, serve as a basis for prospective and comparative studies, and facilitate computerisation.

There is no generally agreed terminology or classification for the findings of endoscopic retrograde pancreatography (ERP) in patients with chronic pancreatitis. Most authors have used variations of the classification described by Kasugai *et al* in 1974.<sup>2</sup> Some aspects have remained controversial, however, particularly the concept of 'minimal change pancreatitis' which is based on minor abnormalities of the branch ducts; some consider such abnormalities to be pathological, others equivocal, and some normal (especially in the elderly). As well as disagreement about the significance of individual pancreatograms, confusion has arisen as a result of imprecise terminology, and the frequent lack of an independent diagnostic endpoint, or 'gold standard'. This lack of uniformity has made it difficult to compare results in different centres, and to judge the relevance of comparisons with other tests of pancreatic disease. We propose the 'Cambridge' terminology, evolved during a recent international workshop on pancreatitis, held in Cambridge under the auspices of the Pancreatic Society of Great Britain and Ireland. Details of the conclusions concerning pancreatitis are published elsewhere.<sup>1</sup>

Address for correspondence: Dr A T R Axon, Gastroenterology Unit, The General Infirmary, Leeds LS1 3EX.

Received for publication 24 February 1984

### Methods

Members of the group brought to the meeting their individual views on terminology and classification, based on extensive experience of pancreatography and pancreatic disease. Examples of pancreatograms were shown and discussed. The agreed terms were then tested for inter-observer error, which led to some minor modifications to the classification.

### Results

#### QUALITY OF PANCREATOGRAPHY

Many pancreatograms sent for independent review are inadequate for diagnosis. When reporting pancreatograms it may be helpful first to state whether the quality is good, adequate, poor, or overfilled. Good quality radiographs are obtained only when endoscopists collaborate with experienced radiologists using modern equipment. The series should include a pre-ERCP control film (Fig. 1). The main duct should be filled to the tail (or sufficiently to clearly define any obstruction), and the branches should be filled to the second generation. Movement blur and injection of air bubbles must be avoided (Fig. 2). Films should be taken during the filling phase to detect small filling defects, and also during emptying, in the supine

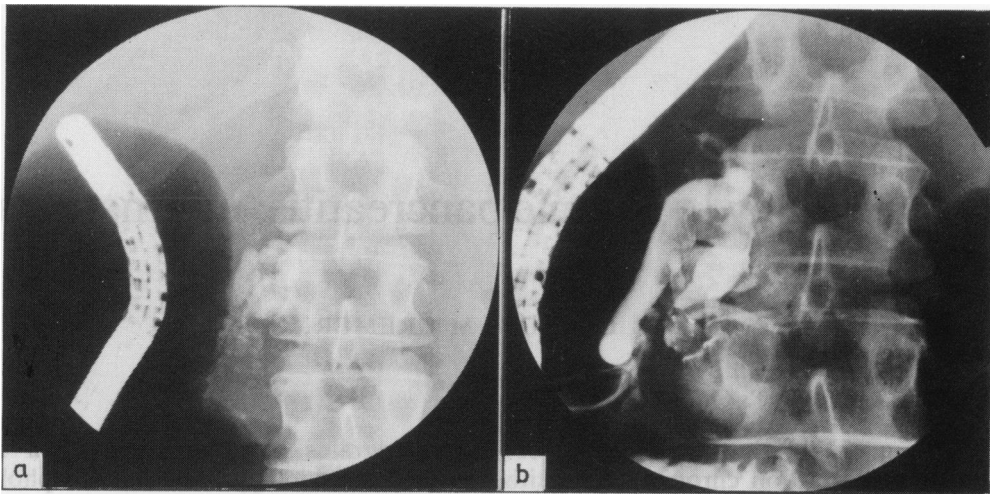


Fig. 1 (a) Control film taken before injection of contrast showing calcification in the head of the pancreas. (b) Following injection of contrast there is dilatation of the main pancreatic duct which contains filling defects and an abrupt obstruction at junction between the head and the body.

position. Parenchymal opacification (Fig. 3) should be avoided, at least with present materials. The non-ionic contrast medium metrizamide has been used to obtain parenchymograms, this was associated with a 4.6% incidence of clinical pancreatitis.<sup>3</sup>

#### TERMINOLOGY

##### (a) Main pancreatic duct

The main pancreatic duct (MPD) is defined as the duct providing the major drainage of the gland; in pancreas divisum it is clearer to describe dorsal and ventral duct systems. The terms upstream (meaning

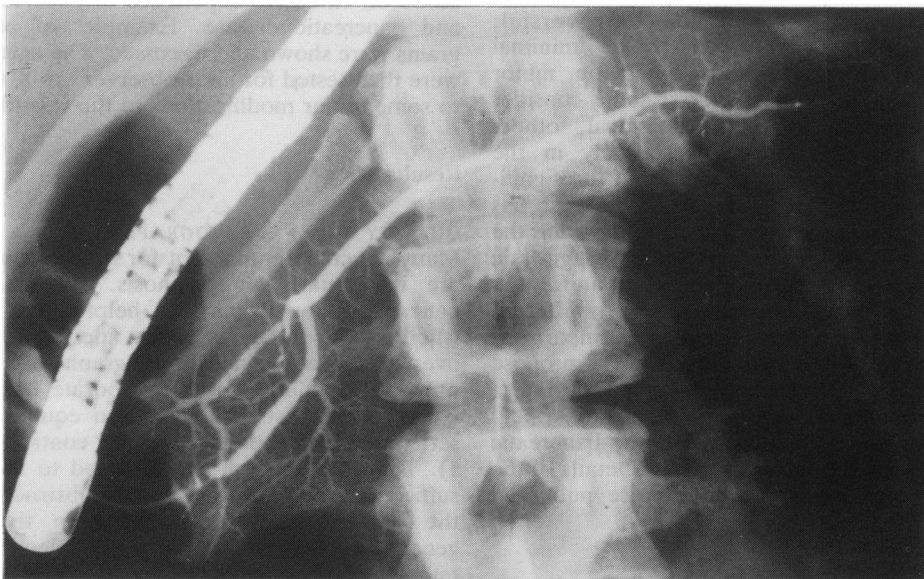


Fig. 2 Normal pancreatogram. Note side branches filled to second generation; absence of movement blur, air bubbles, and parenchymal opacification.

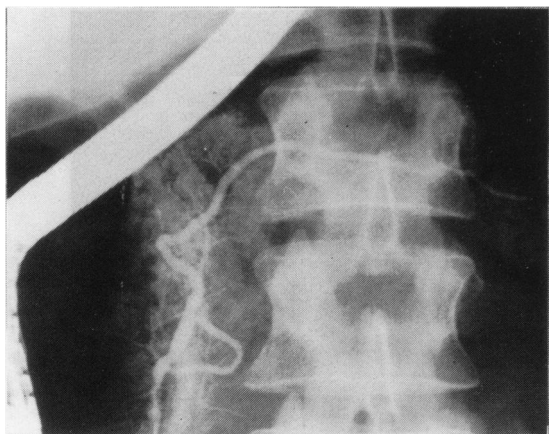


Fig. 3 Pancreatogram showing parenchymal opacification which obscures the appearances of the side branches.

towards the tail) and downstream (meaning towards the head) are preferred to proximal and distal. Intraduct filling defects may be seen; they should not be described as calculi.

(i) Calibre: the normal MPD tapers smoothly from the head to the tail (Fig. 2); it may be narrowed in the head of the gland near the point of embryonic fusion of the ventral and dorsal parts. Duct sizes vary according to age, sex, size of patient and racial origin, as well as disease; collected series<sup>4</sup> give average diameters of 3.6, 2.7 and 1.6 mm for head, body, and tail respectively. It is still difficult to define the upper limit of normal, which after correction for magnification is probably close to 6.5 mm in the head, 5 mm in the body, and 3 mm in the tail.<sup>5</sup> These figures are guidelines only, and absolute size of the main duct alone is rarely of crucial diagnostic significance. A dilated MPD is present when these dimensions are exceeded or when one section of the duct is wider than the rest of an apparently normal calibre duct (Fig. 4). Dilatation may be general affecting more than two thirds of the MPD or local affecting one third or less. Severe dilatation is present when the duct diameter exceeds 1 cm. Narrowing is a subjective assessment and may be general or local (Fig. 5). A stricture is a local narrowing measuring less than 5 mm in length.

(ii) Contour: the contour of the MPD may be described as smooth, irregular, or when the duct contains multiple strictures, severely irregular (Fig. 6). An obstructed MPD terminates prematurely; the type of obstruction may be abrupt, tapering, or irregular.

#### (b) Side branches

Normal limits for side branches are not yet fully

defined, and classification is subjective. The number of side branches may be normal, or decreased. If decreased this will be focal, multi-focal, or diffuse (few or no side branches). Side branches may be of normal length or shortened; their calibre may be normal, dilated or narrowed, and the contour may be smooth, or irregular. Nipping describes narrowing at the origin of a branch duct, and is usually associated with dilatation and shortening (Figs. 4, 5, and 6).

#### (c) Parenchymal changes

Radiographic contrast in the gland parenchyma is described as parenchymal opacification (Fig. 3) in preference to acinar opacification or filling; this may be coarse or smooth and is seen usually when the gland or part of the gland has been filled at a high pressure. Early parenchymal opacification means that the parenchyma is shown before the side branches are seen (sometimes even before the main duct); it occurs most commonly in patients with acute pancreatitis.

#### (d) Cavities

Cavities are pancreatic or peripancreatic collections which fill with contrast medium at ERP. These may represent cysts, pseudocysts, or abscesses; the term

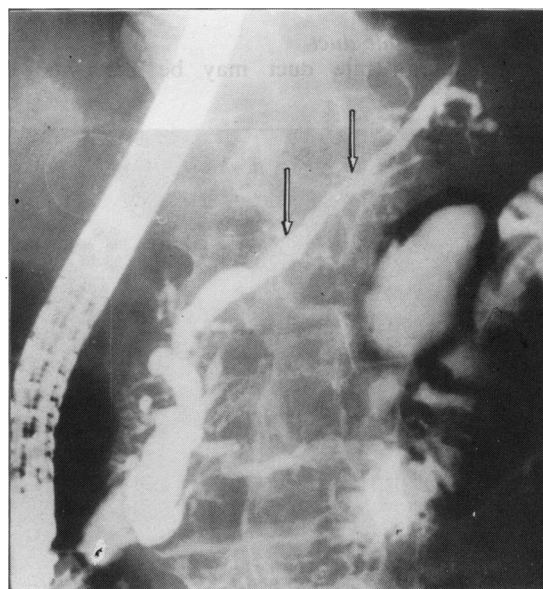


Fig. 4 Dilatation and irregularity of main pancreatic duct. Side branches are shortened, dilated, and irregular throughout. Nipping is seen in body of the pancreas (arrowed). Moderate diffuse changes of chronic pancreatitis.

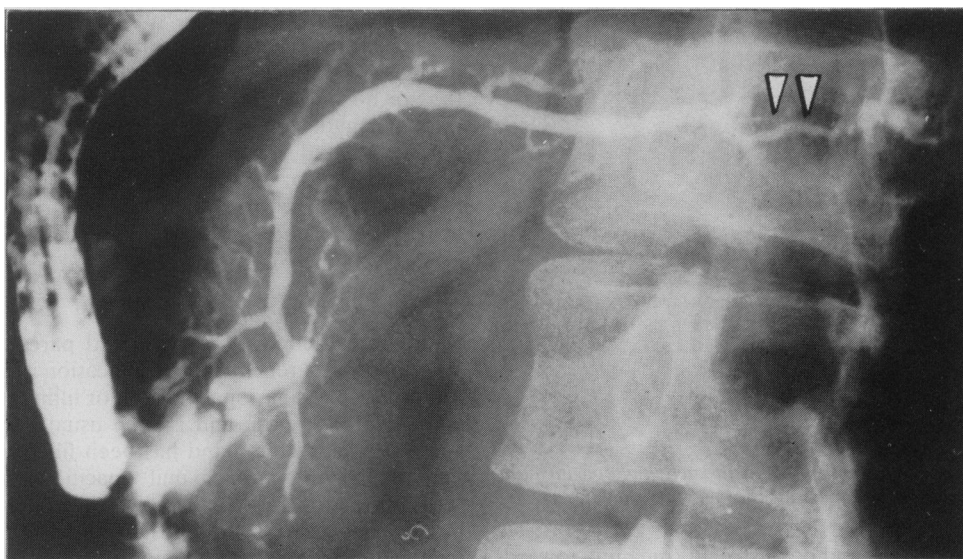

Fig. 5 Narrowing of the main pancreatic duct in body of the pancreas (arrowed). Main pancreatic duct in the tail is dilated and there are abnormal side branches in the body and tail. Moderate diffuse changes of pancreatitis.

cavity is preferred because of disagreement over nomenclature, and the fact that other terms indicate specific pathology. Cavities may be large (Fig. 7) or small (less than 10 mm in diameter).

*(e) Common bile duct*

The common bile duct may be narrowed or

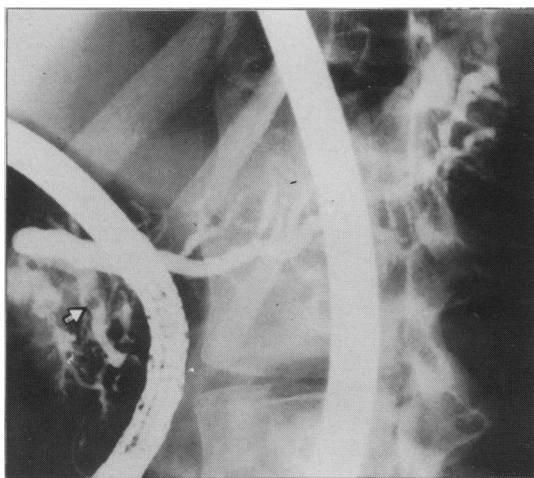


Fig. 6 Severe irregularity of main pancreatic duct in tail. There is also a filling defect in the head of the pancreas (arrowed). Side branches are generally involved showing generalised irregularity and dilatation. Marked diffuse changes of chronic pancreatitis.

obstructed in the region of the head of the pancreas, and there may be upstream dilatation. A full description of the biliary system was not within the remit of the Workshop.

PANCREATOGRAM CLASSIFICATION

The classification of pancreatogram findings does not imply coincidence with the severity of disease pathology or functional status. Patients with chronic pancreatitis may have a normal pancreatogram, and asymptomatic patients may have marked radiographic changes. We consider, however, that patients with mild, moderate, and marked changes all have chronic pancreatitis. The proposed classification is set out in the Table.

**Discussion**

Agreed pancreatogram definitions should enable centres to compare results more effectively, and to define regional variations and referral patterns. More important, agreed definitions will facilitate the comparison of pancreatograms with other parameters of pancreatic disease (function tests and non-invasive imaging), which are needed to validate diagnostic criteria. Defined categories may be found to have some prognostic significance.

Our agreed classification is based purely on the severity and distribution of morphological changes on radiographs in patients with chronic pancreatitis. We have not described the changes in patients with

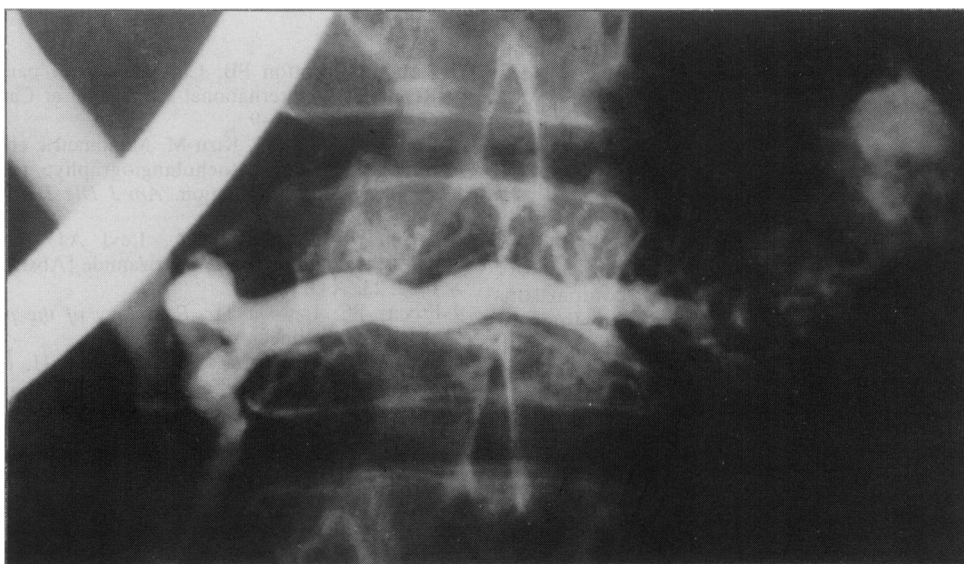


Fig. 7 Large cavity in the tail of pancreas. Main pancreatic duct is generally dilated and there are side branch changes in the body. Marked diffuse changes of chronic pancreatitis.

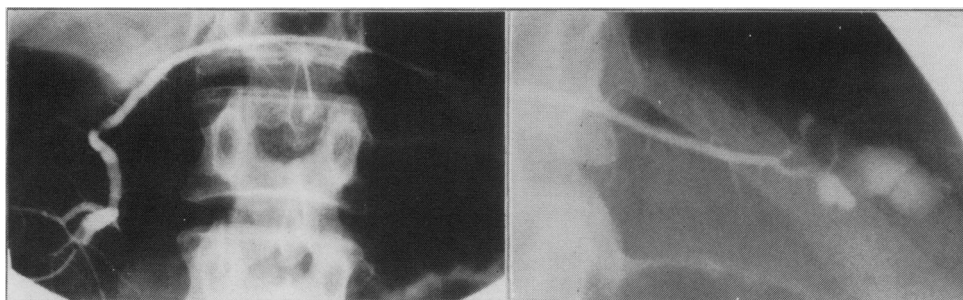


Fig. 8 There is a large cavity in the tail of pancreas with irregularity of some of side branches. Rest of the gland is normal: marked changes of chronic pancreatitis localised to the tail.

Table Classification of pancreatograms in chronic pancreatitis

Terminology	Main duct	Abnormal side branches	Additional features
Normal	Normal	None	
Equivocal	Normal	Fewer than 3	
Mild changes of chronic pancreatitis	Normal	3 or more	
Moderate changes of chronic pancreatitis	Abnormal	More than 3	
Marked changes of chronic pancreatitis	Abnormal	More than 3	One or more of: large cavity, obstruction, filling defects, severe dilatation or irregularity

If pathological changes are limited to one third or less of the gland they are said to be 'local' (Fig. 8) and designated as being in head, body, or tail; if more than one third is affected they are diffuse.

acute pancreatitis, as insufficient data are available; nor have we attempted to define the radiographic borderline area between cancer and pancreatitis. We have discarded the term 'minimal change' pancreatitis, because it was insufficiently defined. Enough experience has now been accumulated to indicate minimum ERP criteria for a diagnosis of chronic pancreatitis – abnormalities in at least three side branches in a pancreatogram of high quality. These definitions will be refined further as more detailed functional and histological comparisons become available; they need further testing for inter-observer variation, and comparisons with other diagnostic modalities, and should form the basis for computerisation of data.

#### References

- 1 Sarner M, Cotton PB. Classification of pancreatitis. Report of an international symposium at Cambridge. *Gut* 1984; **25**: 756–9.
- 2 Kasugai T, Juno N, Kizu M. Manometric endoscopic retrograde pancreatocholangiography: technique, significance and evaluation. *Am J Dig Dis* 1974; **19**: 485–502.
- 3 Twomey B, Wilkins RA, Levi AJ. Pancreatic parenchymography using metrizamide [Abstract]. *Gut* 1982; **23**: A432.
- 4 Freeny PC, Lawson TL. *Radiology of the pancreas*. New York: Springer-Verlag, 1982.
- 5 Cotton PB. In: Howat HT and Sarles H, eds. *The exocrine pancreas*. Eastbourne, Sussex: W B Saunders, 1979.