

## Case report

# Ketoconazole-induced fulminant hepatitis

E BERCOFF, J BERNUAU, C DEGOTT, B KALIS, A LEMAIRE, H TILLY, B RUEFF, AND J P BENHAMOU

From the Hôpital Beaujon, Clichy, and Hôpital Sébastopol and Hôpital Robert Debré, Reims, France

**SUMMARY** We report the cases of two adult patients in whom fulminant hepatitis developed after 17 and 103 days of ketoconazole administration. Histologic administration showed massive, predominantly centrilobular necrosis. Clinical manifestations of hypersensitivity and eosinophilia were absent in both patients, which suggests that ketoconazole hepatotoxicity is not mediated through an immunoallergic mechanism.

Toxicity to the liver is a recognised complication of administration of ketoconazole, an antifungal imidazole derivative. The hepatic reaction to the drug is usually limited to an asymptomatic increase in serum aminotransferases: the prevalence of this biochemical disorder would range from 3 to 5%.<sup>1</sup> Symptomatic non-fatal hepatitis is much less common: its prevalence would be of the order of 0.01%.<sup>1</sup> Fulminant hepatitis is likely to be still less frequent: only five cases have been mentioned so far, but with no or very few details.<sup>1-3</sup> The purpose of this report is to describe in detail two additional cases of ketoconazole-induced fulminant hepatitis.

### Case reports

The time and duration of ketoconazole administration, the concentrations of serum alanine aminotransferase (ALT), serum bilirubin, and prothrombin, and the time of death of our two patients are given in Figure 1. Serological markers of a recent infection with hepatitis A virus, hepatitis B virus, cytomegalovirus, Epstein-Barr virus, and herpes viruses were absent in both patients. Only specific details are given in the following reports.

#### PATIENT 1

A 38-year-old woman, suffering from a fungal infection of the toe nails ascribed to *Trichophyton rubrum*, received ketoconazole, 200 mg daily, for

103 days, from 16 June to 26 September, 1983. Serum ALT, which was normal on 16 June, 20 July

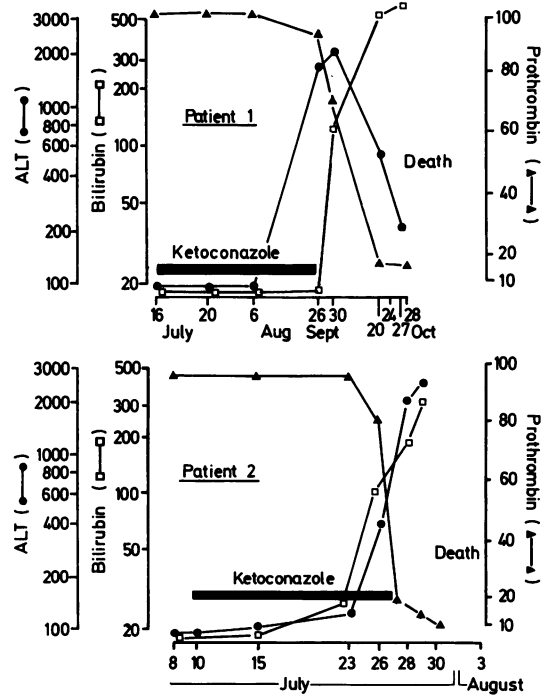


Fig. 1 Serum ALT (IU, normal: 10-40), serum bilirubin (μmol/l, normal: 7-17) and prothrombin (% of normal) in our two patients.

Address for correspondence: Dr J P Benhamou, Hôpital Beaujon, 92118 Clichy, France.

Received for publication 27 July 1984

and 6 August, markedly increased on 26 September (Fig 1). On 30 September, jaundice developed. On 10 October, ascites was noted. On 19 October, asterix was present. On 20 October, the patient was confused, and on 24 October, hepatic vein catheterisation was performed. The gradient between wedged and hepatic venous pressures was 18 mm Hg (normal: 2–4); histologic examination of a hepatic tissue specimen taken by transvenous liver biopsy<sup>3</sup> showed hepatocyte necrosis, predominantly centrilobular and extended to the portal triads, infiltration with mononuclear and polymorphonuclear cells, and normal portal triads without fibrosis (Fig 2). On 26 October, coma developed and on 28 October, the patient died.

#### PATIENT 2

A 59 year-old man, suffering from acute myeloblastic leukaemia, was treated with cytarabine and zorubicin from 25 June to 1 July, 1983, with blood transfusions from 6 to 12 July, 1983, and with colistin, amikacin and amphotericin B from 5 to 15 July. Because of a severe intestinal candidiasis, the patient received ketoconazole, 200 mg daily, for 17 days, from 10 to 27 July. Serum ALT, which was normal on 8 and 10 July, increased slightly on 15 and 23 July and markedly on 26 July (Fig 1). On 26 July, jaundice developed. On 27 July, confusion and ascites were noted, and three days later hepatic vein catheterisation was performed: the gradient between wedged and free hepatic venous pressures was 17 mm Hg; histologic examination of a hepatic tissue specimen taken by transvenous liver biopsy showed massive centrilobular necrosis, infiltration with mononuclear and polymorphonuclear cells, and

normal portal triads without fibrosis. Examination of a bone marrow smear showed intense regeneration and no blast cell. On 1 August, coma developed and after two days the patient died.

#### Discussion

The diagnosis of fulminant hepatitis in our two patients is based on the following arguments: (a) no clinical, biochemical or histologic evidence of previous chronic liver disease; (b) marked increase in serum ALT; (c) hepatic encephalopathy developing 19 days in patient 1 and one day in patient 2 after the onset of jaundice; (d) low level of prothrombin; (e) massive hepatic necrosis. Fulminant hepatitis in our two patients can be reasonably ascribed to ketoconazole for the following reasons: (a) viral infections, except for non-A, non-B hepatitis, which can cause acute hepatitis have been excluded; (b) the distribution of hepatic necrosis, predominantly centrilobular, is suggestive of drug-induced hepatitis; (c) patient 1 received only ketoconazole; patient 2 received drugs other than ketoconazole, none of which is likely to be responsible for hepatitis. The administration of cytarabine and zorubicin was interrupted 26 days before the onset of jaundice; colistin, although widely used, has been mentioned as a possible cause of hepatitis in a single report published in 1963;<sup>4</sup> amikacin and amphotericin B are not considered toxic to the liver.<sup>5,6</sup>

The mechanism of hepatic necrosis induced by ketoconazole is obscure. The absence of clinical manifestation of hypersensitivity and eosinophilia in our two patients as well as in the previously reported cases of hepatitis attributed to ketoconazole<sup>7–11</sup> suggests that the liver lesion might be related, not to an immunoallergic mechanism, but rather to a direct or a reactive metabolite-mediated toxicity. This view is consistent with the relatively high prevalence of asymptomatic increase of serum ALT in patients receiving the drug<sup>1</sup> and by the hepatic lesion observed in most of the dogs receiving high doses of ketoconazole.<sup>12</sup>

Because of the risk of severe liver lesion, we recommend bimonthly or weekly measurements of serum ALT in patients receiving ketoconazole; monthly measurements are likely to be inadequate as our patient 2 died of fulminant hepatitis less than a month after the beginning of the administration of the drug. Ketoconazole administration must be immediately interrupted in patients with increased serum ALT; however, despite cessation of ketoconazole administration, liver function continued deteriorating, progressively in our patient 1 and rapidly in our patient 2.

An incidental finding in our patients was an

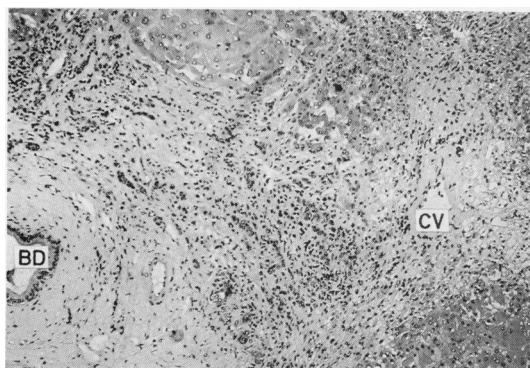


Fig. 2 Patient 2. Liver biopsy. Hepatic cell necrosis, predominantly centrilobular and extended to the portal triad. The necrotic area is infiltrated with inflammatory cells. CV, centrilobular vein. BD, bile duct (H & E  $\times$  110 original magnification).

increased gradient between wedged and free hepatic venous pressures, reflecting an increased portal venous pressure. A similar finding has been made in patients with fulminant viral hepatitis.<sup>13</sup> Portal hypertension is likely to be the consequence of disordered intrahepatic circulation resulting from massive necrosis, whether because of viral hepatitis or, as it was the case in our patient, to ketoconazole-induced hepatitis. Portal hypertension is probably responsible for the development of ascites affecting our patients.

We thank Professor P Zeitoun and Professor L Degos for referring the patients, and Drs C Bataille, S Castaigne and D Lebrech for assistance.

#### References

- 1 Janssen PAJ, Symoens J. Hepatic reactions during ketoconazole treatment. *Am J Med* 1983; **24**: 80-5.
- 2 Lewis JH, Zimmerman HJ, Benson GD, Ishak KG. Hepatic injury associated with ketoconazole therapy. Analysis of 33 cases. *Gastroenterology* 1984; **86**: 503-13.
- 3 Lebrech D, Degott C, Rueff B, Benhamou JP. Transvenous liver biopsy. An experience based on 1000 hepatic tissue samplings with this procedure. *Gastroenterology* 1982; **83**: 338-40.
- 4 Katz R. Renal and possibly hepatic toxicity from coly-mycin: report of a case. *Med Ann DC* 1963; **32**: 408, [Quoted by Zimmerman].<sup>5</sup>
- 5 Zimmerman HJ. *Hepatotoxicity. The adverse effects of drugs and other chemicals on the liver*. New York: Appleton-Century-Crofts, 1978.
- 6 Ludwig J, Axelsen R. Drug effects on the liver. An updated tabular compilation of drugs and drug-related hepatic diseases. *Dig Dis Sci* 1983; **28**: 651-66.
- 7 Heiberg JK, Svejgaard E. Toxic hepatitis during ketoconazole treatment. *Br Med J* 1981; **283**: 825-6
- 8 Svejgaard E, Ranek L. Hepatic dysfunction and ketoconazole therapy. *Ann Intern Med* 1982; **96**: 788-9.
- 9 Macnair AL, Gascoigne E, Heap J, Schuermans V, Symoens J. Hepatitis and ketoconazole therapy. *Br Med J* 1981; **283**: 1058.
- 10 Pegram S, Kerns FT, Wasilauskas BL, Hampton KD, Scharyj M, Burke JG. Successful ketoconazole treatment of protothecosis with ketoconazole associated hepatotoxicity. *Arch Intern Med* 1983; **143**: 1802-5.
- 11 Okumura H, Arakami T, Satomura K *et al*. Severe hepatitis during ketoconazole therapy. *Gastroenterol Jpn* 1983; **18**: 142-7.
- 12 Anonymous. Toxicology and Safety Study. In: Levin HB, ed. *Ketoconazole in the management of fungal diseases*. New York: Adis Press, 1982: 74-6.
- 13 Lebrech D, Nouel O, Bernuau J, Rueff B, Benhamou JP. Portal hypertension in fulminant viral hepatitis. *Gut* 1980; **21**: 962-4.