

Alimentary tract and pancreas

Palliative laser therapy for malignant dysphagia

N KRASNER, H BARR, CAROLE SKIDMORE, AND A I MORRIS

From Walton Hospital, Liverpool

SUMMARY Seventy six patients with dysphagia caused by malignant tumours of the oesophagus or gastric cardia have been treated using the Neodymium Yttrium Aluminium Garnet (NdYag) laser. The laser was set to deliver 80-100 watts of power for 0.5-1 second pulses. To obtain improvement, patients on average needed four treatment sessions with a mean energy per treatment of 3586 joules. Follow up endoscopy and laser treatment was at four week intervals, unless the clinical or endoscopic results indicated otherwise. The immediate result was to allow 32% of patients to swallow anything they liked, a further 54% were able to take most solids and 9% were improved, or maintained on liquids only. The mortality of laser recanalisation and associated treatment was 5%. The improvement in swallowing was maintained until death in all but 15% of these patients, some of the 15% needed intubation to allow adequate swallowing. Endoscopic, or surgical intubation was required immediately in five patients after an initial laser course failed to provide improvement. The mean survival of the whole group was 19 weeks (range one to 112 weeks).

Progressive dysphagia and inanition are common terminal features in carcinoma of the oesophagus and gastric cardia. Surgical resection for squamous cell and adenocarcinoma, and radiotherapy for squamous cell carcinoma offer the prospect of cure but with either treatment only 18% of patients survive to one year.^{1,2} In addition the operative mortality for oesophagogastrectomy rises with increasing age, reaching 40% for patients over 75 years.³ Radiotherapy is inappropriate for gastric and gastro-oesophageal adenocarcinoma⁴ and has rarely proved successful in achieving adequate palliation.^{2,4,5} As in 75% of patients, local tumour invasion makes curative resection impossible treatment is predominantly palliative.⁶ Several centres advocate aggressive surgical procedures as the most effective method of providing palliation.^{4,6,7} The resectability rates vary, however, being as low as 15-20% in the Transkei area of South Africa and as high as 75-90% in the United States and China.^{8,9} There remains a significant number of patients who require palliation by other means. Intubation of the malignant stricture both endoscopically and at laparotomy has proved a useful measure, the former being preferred.^{10,11} Opinions differ as to the efficacy

of these techniques as normal swallowing may not be achieved, the patient may only be able to eat liquids and soft food.⁴ In addition further dysphagia caused by tube dysfunction occurs in up to 44%.¹² Also in patients with complete or near complete oesophageal blockage endoscopic intubation may be impossible. Preliminary experience with the NdYag laser suggested that endoscopic laser recanalisation may be an effective measure for palliation of malignant dysphagia.^{13,14} This paper describes a consecutive series of 76 patients referred with gastric, gastro-oesophageal and oesophageal cancer for palliative laser therapy.

Methods

PATIENTS

Over a five year period, 76 patients, 44 men and 32 women were treated with the NdYag laser to relieve malignant dysphagia. Their mean age was 72 years (range 37-95) (Table 1). All 76 had dysphagia. Swallowing difficulty was graded on a simple 1 to 5 scale: (1) able to swallow all solids without difficulty; (2) difficulty with some hard solids but able to swallow semisolids; (3) unable to swallow any solids, managing liquids only; (4) difficulty in swallowing liquids; (5) unable to swallow anything.

The reason for palliative laser treatment is shown

Address for correspondence: Dr N Krasner, Gastrointestinal Unit, Walton Hospital, Rice Lane, Liverpool L9 1AE

Received for publication 10 October 1986.

Table 1 The age range of treated patients

Age range	Patients (n)
<65	18
65-75	20
75-85	31
>85	7

Table 2 Reason for palliative laser therapy

	Patients (n)
Advanced metastatic disease	29
Severe concomitant disease	8
Recurrent tumour after surgery	9
Tumour overgrowth of prosthetic tube	12
Recurrent tumour after radiotherapy	2
Dysphagia accentuated by radiotherapy	1
Extensive local disease and general debility	15

in Table 2. Twenty nine patients, 23 with adenocarcinoma and six with squamous cell carcinoma had advanced metastatic disease at presentation and were not fit for surgery. Eight patients had such severe concomitant disease that surgery was impossible. Three had ischaemic heart disease, two cerebrovascular disease, two chronic obstructive airways disease, and one had both respiratory and cerebrovascular disease. Nine patients presented with dysphagia caused by recurrent tumour at an anastomosis after surgery. Three had had an oesophago-gastrectomy, 50, 64, and 112 weeks before the development of dysphagia. Four patients had had a total gastrectomy with Roux en Y oesophagojejunal anastomosis 36, 39, 50, and 91 weeks before recurrence. One patient developed recurrence 44 weeks after an oesophagectomy with gastric reanastomosis and another 33 weeks after a palliative lower oesophageal transection with implantation of the oesophagus into the gastric fundus. Ten patients were referred who had initially been treated by endoscopic insertion of an Atkinson tube.^{15 16} In all the tube was occluded by extensive tumour overgrowth at the upper end. Two patients with a Celestin tube inserted at laparotomy had tumour either at the top or bottom end. Three patients with squamous cell carcinoma had received an earlier course of radiotherapy. One was referred urgently for laser recanalisation after initial radiotherapy had accentuated the dysphagia. The other two had radiotherapy and developed problems seven and 52 weeks afterwards. None of the other patients was considered fit for surgery because of extensive local disease and general debility.

TUMOUR DATA

Biopsies were taken from all tumours and histology

Table 3 The position of the upper end of the tumour

Position of the upper end of tumour (measured from the incisor teeth (cm))	Patients (n)
15-20	4
20-30	22
30-40	41
40-50	9

Table 4 The length of the tumour measured at endoscopy

Tumour length (cm)	Patients (n)
<5	8
5-10	42
10-15	19
>15	7

Table 5 The extent of luminal occlusion measured at endoscopy

Percentage luminal occlusion	Patients (n)
100	19
75-100	33
50-75	17
<50	7

showed 43 patients with adenocarcinoma, 32 with squamous cell carcinoma and one had a malignant melanoma of the oesophagus. The tumour was located entirely in the oesophagus in 26 patients, at the gastro-oesophageal junction in 21 and originated in the stomach in 18. Nine patients had anastomotic recurrence and two had bronchial neoplasms invading and obstructing the oesophagus. The upper ends of the tumours were located between 17-47 cm (mean 30) as measured from the incisor teeth at endoscopy (Table 3). The lower end of the stricture was at 20-53 cm (mean 37). The mean stricture length was 8 cm (range 1-20 (Table 4)). During initial endoscopic examination the extent of luminal occlusion was estimated. One hundred per cent occlusion meant that there was no visible lumen and a guide wire would not pass through. Between 75-100% occlusion there was a small lumen sufficient to take a feeding tube. Below this level the size was estimated (Table 5).

INSTRUMENTS

The laser used was the Molecron 8000 Neodymium Yttrium Aluminium Garnet laser (NdYag) (Molecron Medical, Cooper Lasersonics) emitting an invisible, infrared laser beam of wavelength 1064 nm. A separate Xenon aiming light allowed the invisible laser beam to be targeted precisely on to the area to be treated. The laser was set to deliver

between 80–100 watts as 0.5–1 second pulses and the beam was transmitted down a 400 μ flexible optical fibre. This laser fibre was in turn mounted in a 2 mm protective Teflon catheter that could be easily passed down the instrumentation channel of a standard fibreoptic endoscope (Olympus XQ,Q10 KeyMed) fitted with a protective filter. A stream of carbon dioxide gas was passed coaxially down inside the Teflon sheath to keep the laser fibre free from contamination by blood, secretions or debris and thus prevent damage to the tip by overheating. The patient was sedated with 4–10 mg of intravenous midazolam (Hypnovel) or diazepam. The tip of the laser fibre was held within 1.5 cm of the target because the power density falls off as the distance increases. A Ryles tube was placed alongside the endoscope to vent the insufflated carbon dioxide and smoke produced by vaporisation and thus prevent gaseous overdistension. The laser beam was fired parallel to the luminal axis shaving off the tumour from the lower edge first where possible and working upwards. In 16 patients it was necessary to dilate the stricture at the first laser session in order to see its extent and reach the lowest margin prior to treatment. A Celestin dilator passed over a guide wire was used. In six patients dilatation was required at subsequent sessions. In several patients it was not possible to pass the instrument through the tumour nor could a guide wire be passed to enable dilatation. In these circumstances the upper surface was treated first and progress continued downwards. Initially the patients were treated at three to seven day intervals until benefit was achieved. It was evident that trying to achieve total tumour vaporisation and destruction in one session was often inappropriate for large tumours. The laser produces thermal coagulation to a depth of 2–3 mm as well as superficial vaporisation; a gap between sessions allows the necrotic coagulated tumour to separate often making a remarkable improvement in the size of the lumen and allowing access to other parts of the tumour. This was particularly evident when treating the upper surface of large totally obstructing tumours. After the initial laser sessions had been effective, the patients were re-endoscoped after four weeks and treated if necessary. Follow up endoscopy was at monthly intervals until death to prevent and forestall recurrent dysphagia. The interval was left longer if the endoscopic and clinical situation were satisfactory. The patients were admitted overnight for each laser session. They remained in hospital if several sessions were necessary in the following days, or social and medical circumstances prevented early discharge. All were given clear fluids only for six hours after treatment and then encouraged to eat as freely as they were able. A problem found in some patients was lack of

confidence in their ability to swallow. They preferred to avoid certain foods that had been troublesome previously. Elderly patients sometimes out of preference ate a semisolid diet.

Results

Of the 76 patients treated using the laser, 36 had this as the sole form of treatment. Ten had had previous intubation, nine previous surgery, and three previous radiotherapy. Sixteen were initially treated by the laser and subsequently required intubation (14), surgery (two), radiotherapy (two). The total energy delivered per laser session was measured in watts/seconds (joules) and the mean was 3586 joules (range 300–12 706). The mean number of sessions to treat each patient was 4 (range 1–14). When we consider the energy required to treat one patient, the mean was 13 941 (range 670–52 660). One to four sessions were needed for the initial laser course with a mean of two. Only one session was generally needed at follow up endoscopy.

DYSPHAGIA AND NUTRITIONAL STATUS

The aim of treatment was to improve swallowing and maintain oral nutrition until death. The initial intensive course was to recannulate the oesophagus quickly and regular follow up was to prevent relapse with the subsequent effect on patient morale. The Figure shows the swallowing ability in all patients before and after the initial laser course. The serum albumin and the body weight were measured before

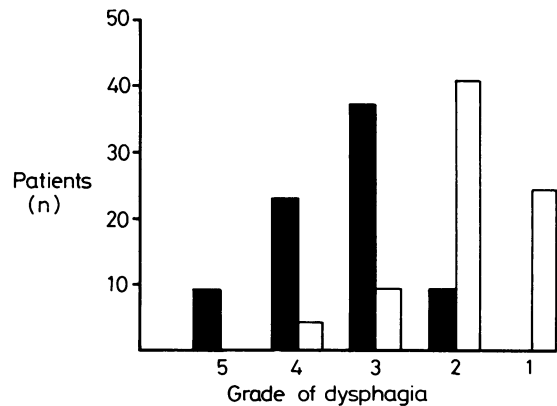


Figure: Improvement in dysphagia after laser treatment in 76 patients. Solid columns indicate the degree of dysphagia before laser therapy and open columns indicate the degree of dysphagia after laser treatment. Dysphagia grade: (1) able to swallow all solids; (2) difficulty with some hard solids, but able to swallow semisolids; (3) unable to swallow any solids, managing liquids only; (4) difficulty in swallowing liquids; (5) unable to swallow anything.

and after laser treatment. The data presented are the albumin level and weight collected before laser treatment and two to four weeks before the patient's death. Thirty patients had reliable weight measurements. Patients with ascites and fluid retention were excluded as were those not weighed by our ward scales. The mean weight before was 47.85 kg and after was 45.2 kg. Perhaps more important are the eight patients who gained between 2–5 kg over an eight to 26 week period. In two patients the weight was stable and 20 lost 1–7 kg in the weeks before death. The mean serum albumin was 35 g/l before treatment and fell by only 1 g/l two weeks before the patients' death.

PERIOD OF PALLIATION

Laser only

In 36 patients the laser was the only form of treatment. In three the laser failed to produce improvement in swallowing. Two with very advanced disease died one and two weeks after starting treatment and did not have time to gain any benefit. In one patient laser and dilatation caused a perforation and death two weeks later. Twenty six patients died between one and 50 weeks (mean 15) after starting treatment. All but two had continuous relief of dysphagia until death. In one recurrent dysphagia occurred three weeks after the initial laser course just before the first follow up session at four weeks. The other patient only obtained relief for two weeks between sessions. Immediately after treatment he could swallow all solids but returned managing only a liquid diet. Seven patients are still alive with satisfactory swallowing 6, 8, 12, 12, 19, 24, and 112 weeks after starting treatment. The patient who has survived over two years was 91 years old at presentation and was very frail with respiratory disease. Laser treatment removed all visible tumour initially. Local tumour nodules have recurred at intervals, however, and have been ablated using the laser. He remains frail but without evidence of systemic metastasis.

Intubation followed by laser

Ten patients had an intraluminal tube obstructed by tumour. Intubation had relieved the dysphagia for seven to 48 weeks (mean 18). The tumour was removed using the laser and swallowing ability was improved and maintained until death four to 26 weeks (mean 13) later. All patients responded in the same way.

Surgery followed by laser

Nine patients had surgical resection or bypass and were swallowing well for 33–112 weeks (mean 58) afterwards before recurrent disease caused dys-

phagia. Laser therapy returned the swallowing ability until death one to 26 weeks (mean 11) later in seven. Two are still alive, swallowing well four and nine weeks after the initial laser course.

Radiotherapy followed by laser

Two patients developed recurrent tumour and dysphagia seven and 52 weeks after a course of radiotherapy. They were able to swallow a normal diet after the laser treatment until death three and 26 weeks later. One patient was referred urgently when total dysphagia occurred during a course of radiotherapy, following the laser he was able to take a liquid diet until death three weeks later.

Laser followed by intubation

Fourteen patients after initial treatment using the laser required intubation of the malignant stricture. Three patients had long strictures of 10, 12, and 15 cm with complete occlusion. It was impossible to be sure of the direction of the oesophagus and a guide wire would not pass through the tumour. Initial laser therapy was applied to the upper surface in the hope of clearing a passage. There was no progress after several sessions, however, and it was obvious that further endoscopic therapy was dangerous. All three had a Celestin tube inserted at laparotomy and were able to swallow well at death 10, 12, and 38 weeks later. Six patients received good initial relief of dysphagia using the laser lasting for 9, 11, 12, 12, 16, and 25 weeks. When their swallowing deteriorated re-endoscopy showed no intraluminal tumour to treat, the obstruction being caused by extrinsic compression which was impossible to treat using the laser. Endoscopic intubation was performed and these patients died 5, 12, 19, 25, 25, and 34 weeks later with improved swallowing. In two patients it was clear at the initial laser sessions that the major component of the obstruction was extraluminal. The stricture was intubated and these patients were able to swallow well and died 15 and 38 weeks later. Two patients had an excellent initial response to laser treatment lasting 13 and 38 weeks. They developed a stricture that was resistant to dilatation however. This was probably a laser induced fibrous stricture. Both had endoscopic intubation which resulted in perforation and death within one week. One patient was improving well with laser treatment but found endoscopy very distressing. He had cerebral metastatic disease and it was felt that intubation under a quick anaesthetic would provide the simplest and swiftest form of palliation. He survived swallowing comfortably for 18 weeks.

Laser followed by radiotherapy

Two patients were referred before radiotherapy. In

both an adequate lumen and improved swallowing was achieved after a four week course. The lumen was maintained during the radiotherapy course and they died 22 and 31 weeks later.

Laser followed by surgery

One 81 year old man was referred as unfit for surgery. After laser recanalisation of his oesophagus, however, his nutritional state and aspiration pneumonia improved dramatically; he subsequently had an oesophagectomy. He tolerated this well and is still alive 34 weeks later. Similarly a 63 year old woman improved after laser therapy and had a palliative oesophagogastrrectomy. She is alive with metastatic disease 29 weeks after operation.

COMPLICATIONS

Patients developed little discomfort during treatment, although one patient did find endoscopy difficult to tolerate. During and immediately after the procedure some did complain of mild retrosternal chest discomfort, particularly if laser pulses had been directed intensively at one place. This was probably because of the heat transmission through the tumour. One patient developed a pneumonia within 48 hours of treatment. This was successfully treated by physiotherapy and antibiotics. Two patients had perforations related to laser treatment alone. One of these developed extensive surgical emphysema and cyanosis during treatment. Chest radiograph revealed a pneumothorax. The perforation sealed and she settled on conservative measures and was discharged nine days later. Another lady developed a subphrenic abscess eight days after treatment; she was in the terminal stages of the malignant disease and died shortly after. At postmortem examination the perforation was at the site of a previous anastomosis but it was impossible to say whether it was laser induced or spontaneous through the tumour. Two patients had perforation after laser and dilatation. One went for surgical repair and was found to have a longitudinal tear in the oesophagus which was sutured. She died two weeks later of the respiratory complications of shock and septicaemia. The other patient developed an oesophagopulmonary fistula and died with bronchopneumonia. Three patients developed a perforation during endoscopic intubation after previous laser therapy. Two with fibrous strictures developed mediastinitis and died; the other patient was perforated during intubation but settled on conservative management and survived 18 weeks.

Discussion

In world wide terms tumours of the oesophagus and gastric cardia are a common form of malignancy¹⁷ and

in recent years there is evidence of an increase in deaths from these tumours in England and Wales.¹⁸ Approximately 40% of patients will qualify for attempted curative treatment either by surgical resection or radical radiotherapy for squamous carcinoma.⁵ The initial clinical evaluation of these patients is notably unreliable generally underestimating the extent of the disease.¹⁹ Thus the overall result of surgery or radiotherapy is poor. There are sporadic encouraging reports of combination treatment for squamous cell carcinoma using preoperative radiotherapy and chemotherapy.²⁰ At present, however, it is still true to say that 90% of treatment is palliative.²¹ Despite this several authors advocate surgical resection or bypass as the best means of providing adequate palliation^{6,21} and favour an aggressive surgical approach.⁷ They do admit, however, that careful patient selection had a significant influence on the results.^{7,21} Intubation of the malignant stricture either endoscopically or at laparotomy has become the most widely used alternative method of palliation. Endoscopic intubation carries a much smaller risk, the hospital mortality being 15% compared with 40% in the operative group.²¹ Other studies have confirmed the relative safety of the endoscopic method.^{8,10} However, 44% of patients develop tube dysfunction and further dysphagia.¹² Some regard the quality of palliation provided as inadequate,⁴ the main problem being food bolus obstruction. Plastic tubes may disintegrate and pass through the stricture and occasionally cause perforation.²² If the distal end of the tube enters the stomach in lower third strictures, reflux oesophagitis can be a problem. Patients also rarely tolerate a tube in the upper oesophagus.⁴ The late complications, with 14% of patients developing obstruction because of tumour overgrowth and 13% getting severe aspiration pneumonia, have led some to conclude that alternative methods should be considered before intubation.²³ After advances in radiotherapy intracavitary radiation is now a practical method for palliation of both squamous and adenocarcinoma and provides relief of dysphagia in 70% with squamous carcinoma and 60% with adenocarcinoma.²⁴ The patients require a general anaesthetic, however, and, as with patients treated by intubation, total occlusion makes the technique inappropriate.

In this study all patients were considered for surgery for cure or palliation. Indeed two who were initially unfit had resection after laser therapy. No patient was considered too ill for laser treatment and several were in the terminal stages of the disease. This is reflected in the overall mean survival of 19 weeks (range one to 112). The prime consideration was relief of dysphagia as swiftly as possible. The

policy of regular follow up was to forestall recurrent dysphagia. If the clinical and endoscopic situation was good the patient was seen at three monthly rather than monthly intervals. Mellow and Pinkas found repeat laser sessions were required four to 15 weeks (mean seven) after the initial laser course.²⁵ If adequate progress was impossible or there was extrinsic compression the patient was treated by endoscopic intubation. If no lumen was visible, however, there was no alternative but operation.

The immediate result of laser therapy was to allow 32% of patients to eat everything until death. A further 54% were able to take most solids. Several of these patients were very elderly and had metastatic disease and despite an adequate oesophageal lumen did not feel inclined to eat fully. Nine per cent of patients were only able to take a liquid diet. This group only survived a short time and often further treatment was not pursued. Five per cent still encountered difficulty in taking liquids. These included three patients in whom a lumen could not be identified and they had operative insertion of a Celestin tube; the other patient died after perforation of the oesophagus. Despite advancing malignant disease there was only a small reduction in weight and serum albumin up to two weeks before death. Four patients died as a result of laser or laser related treatment, a procedural mortality of 5%. The two patients with a seemingly laser induced fibrous stricture both died when intubation was attempted. This combination was highly likely to produce perforation. An advantage of laser induced fibrosis, however, may be that it prevents regrowth of intraluminal tumour. Stricture formation may be prevented by an intraluminal tube placed early after laser treatment before extensive fibrosis renders the oesophagus inelastic. Tumour overgrowth would then be unlikely to block the tube and the combination may prove useful.

It has been suggested that adenocarcinoma is more sensitive to laser light destruction than the white less vascular squamous carcinoma.²⁶ Although it is difficult to match these tumours exactly we have not identified any difference between the two types.

The Washington Symposium²⁷ agreed there were certain factors that may help predict the immediate outcome of endoscopic laser therapy. A good outcome is probable if the tumour is less than 5 cm in length, if it is in a straight part of the mid-oesophagus and is predominantly exophytic and mucosal. Certainly we have found that laser therapy is of little use when the bulk of the tumour is extrinsic. In these situations intubation offers the best means of palliation. Endoscopic intubation has advantages for the treatment of long, rapidly growing tumours which would require very frequent laser sessions. It is also

the treatment of choice for oesophagobronchial fistulae. The laser in turn should be considered first for a stenosis high in the oesophagus or in the stomach; where there is near total or total obstruction, and when other methods fail.²⁸ Other ways of destroying tissue have not proved as satisfactory as the laser because they cannot predictably and precisely destroy areas of tissue under endoscopic control. At present there is no device that replicates the lasers spatial and temporal temperature distribution in tissue. An interesting development is the endoscopic microwave coagulator;²⁹ but this does need to be in contact with the tissues.

At present virtually all gastrointestinal laser treatment is palliative. Tajiri in Japan has treated early gastric cancer in patients unfit for surgery using endoscopic laser therapy. One year follow up has shown encouraging results.²⁷ Surgery, wherever possible, still offers the best prospect of cure and the most effective and lasting relief of dysphagia. For those unlikely to tolerate it, however, endoscopic laser therapy offers simple, relatively safe and satisfactory relief of dysphagia.

It is with pleasure that we acknowledge the assistance of Sister E C Smith and her staff in the Gastrointestinal Unit, and the technical help provided by the endoscopy theatre nurses. We are grateful also to the consultants who referred their patients for laser treatment. Mr H Barr is supported by a research grant from the Wellcome Trust.

References

- 1 Earlam R, Cunha-Melo JR. Oesophageal squamous cell carcinoma: I. A critical review of surgery. *Br J Surg* 1980; **67**: 381-90.
- 2 Earlam R, Cunha-Melo JR. Oesophageal squamous cell carcinoma; II. A critical review of radiotherapy. *Br J Surg* 1980; **67**: 457-61.
- 3 Leverment JN, Milne DM. Oesophagogastric resection in the treatment of malignancy of the thoracic oesophagus and cardia. *Br J Surg* 1974; **61**: 683-8.
- 4 Belsey RHR. Palliative management of oesophageal carcinoma. *Am J Surg* 1980; **139**: 292-5.
- 5 Watson A. Carcinoma of the oesophagus. *Surgery* 1984; **1**: 292-5.
- 6 Orringer MB. Palliative procedures for oesophageal cancer. *Surg Clin North Am* 1983; **63**: 941-50.
- 7 Hennessy TPJ, O'Connell R. Carcinoma of the hypopharynx, esophagus and cardia. *Surg Gynecol Obstet* 1986; **162**: 243-7.
- 8 Procter DSC. Esophageal intubation for carcinoma of the esophagus. *World J Surg* 1980; **4**: 451-61.
- 9 Wu Ying-kai, Chen Pao-tien, Fang Jung-pao, Lin Shun-sheng. Surgical treatment of esophageal carcinoma. *Am J Surg* 1980; **139**: 805-9.
- 10 Lishman AH, Dellipiani AW, Devlin HB. The insertion of oesophagogastric tubes in malignant strictures: endoscopy or surgery. *Br J Surg* 1980; **67**: 257-9.

- 11 Den Hartog Jager, Bartelsman JFWM, Tytgat GNJ. Palliative treatment of obstructing esophagogastric malignancy by endoscopic positioning of a plastic prosthesis. *Gastroenterology* 1979; **77**: 1008-14.
- 12 Pfeleiderer AG, Goodall D, Holmes GKT. The consequences and effectiveness of intubation in the palliation of dysphagia due to benign and malignant strictures affecting the oesophagus. *Br J Surg* 1982; **69**: 356-8.
- 13 Krasner N, Beard J. Laser irradiation of tumours of the oesophagus and gastric cardia. *Br Med J* 1984; **228**: 829.
- 14 Swain CP, Bown SG, Edwards DAW, Kirkham JS, Salmon PR, Clark CG. Laser recanalisation of obstructing foregut cancer. *Br J Surg* 1983; **70**: 1-4.
- 15 Atkinson M, Ferguson R, Parker GC. Tube introducer and modified Celestin tube for use in palliative intubation of oesophagogastric neoplasms at fiberoptic endoscopy. *Gut* 1978; **19**: 669-71.
- 16 Ogilvie AL, Dronfield MW, Ferguson R, Atkinson M. Palliative intubation of oesophagogastric neoplasms at fiberoptic endoscopy. *Gut* 1982; **23**: 1060-7.
- 17 Muir CS, Parkin DM. The world cancer burden: prevent or perish. *Br Med J* 1985; **290**: 5.
- 18 Earlam RJ, Cunha-Melo JR, Donnon SPB, Evans SJW. The epidemiology of oesophageal cancer with special reference to England and Wales. *Ital J Gastroenterol* 1982; **14**: 244-9.
- 19 Fein R, Kelsen DP, Geller N, Bains M, McCormack P, Brennan MF. Adenocarcinoma of the esophagus and gastro-oesophageal junction. Prognostic factors and results of therapy. *Cancer* 1985; **56**: 2512-8.
- 20 Campbell WR, Taylor SA, Pierce GE, Hermreck AS, Thomas JH. Therapeutic alternatives in patients with esophageal cancer. *Am J Surg* 1985; **150**: 665-8.
- 21 Watson A. A study of the quality and duration of survival following resection, endoscopic intubation and surgical intubation in oesophageal carcinoma. *Br J Surg* 1982; **69**: 585-8.
- 22 Shaw JFL, Coombes GB. Multiple intestinal perforation due to Celestin tube. *Br J Surg* 1979; **66**: 807-8.
- 23 Diamantes T, Mannell A. Oesophageal intubation for advanced oesophageal cancer: the Baragwanath experience 1977-1981. *Br J Surg* 1983; **70**: 555-7.
- 24 Rowland CG, Pagliero KM. Intracavitary irradiation in palliation of carcinoma of the oesophagus and cardia. *Lancet* 1985; **ii**: 981-2.
- 25 Mellow MH, Pinkas H. Endoscopic laser therapy for malignancies affecting the esophagus and gastroesophageal junction. *Arch Intern Med* 1985; **145**: 1443-6.
- 26 Mathus-Vliegen EMH, Tytgat NJ. Laser photocoagulation in the palliation of upper digestive tract tumours. *Cancer* 1986; **57**: 396-9.
- 27 Fleischer D. The Washington symposium on endoscopic laser therapy, April 18 and 19, 1985. *Gastrointest Endosc* 1985; **31**: 397-400.
- 28 Rieman JF, Ell Ch, Lux G, Demling L. Combined therapy of malignant stenoses of the upper gastrointestinal tract by means of laser beam and bougienage. *Endoscopy* 1985; **17**: 43-8.
- 29 Tabuse K, Katsumi M, Nagui Y, *et al.* Microwave tissue coagulation applied clinically in endoscopic surgery. *Endoscopy* 1985; **17**: 139-44.