

Progress report

Hepatic osteodystrophy: vitamin D metabolism in patients with liver disease

The current interest in hepatic osteodystrophy was stimulated by the discovery in 1969 that vitamin D undergoes 25-hydroxylation in the liver.¹ It has subsequently been shown that the metabolite thus formed, 25-hydroxyvitamin D (25OHD) is the major circulating metabolite of vitamin D; the major active metabolite, 1,25-dihydroxyvitamin D₃ is formed by 1 α hydroxylation of 25OHD, this step occurring almost exclusively in the kidney.² Although diet was formerly believed to be the major source of vitamin D in man it has been shown, both in the UK and North America, that endogenous skin synthesis is quantitatively the most important source,^{3,4} cholecalciferol (vitamin D₃) being produced from the precursor 7-dehydrocholesterol in the presence of ultraviolet irradiation.⁵

After the demonstration that 25-hydroxylation occurred in the liver many groups, both in Europe and North America reported low serum or plasma 25OHD concentrations in patients with chronic cholestatic, alcoholic and other forms of liver disease.^{6–22} The pathogenesis of this vitamin D deficiency aroused considerable controversy. Whilst impaired hepatic metabolism of vitamin D was an obvious possibility, other causes such as reduced exposure to ultraviolet irradiation, low dietary vitamin D intake, impaired cutaneous synthesis of vitamin D₃ caused by jaundice and malabsorption of vitamin D also required investigation.

Hepatic production of vitamin D

Hepatic production of vitamin D in man has been studied mainly by measurement of the serum 25OHD response to vitamin D administration, using either unlabelled or radioactive vitamin D. The former studies have often involved administration of pharmacological doses of vitamin D and the results obtained may thus not be of physiological significance although they are relevant when considered in the light of vitamin D therapy. Radiolabelled vitamin D studies, in most of which the vitamin is injected as an intravenous bolus, have also to be interpreted with some caution as both the rate of delivery of the vitamin to the circulation and the form in which it is delivered are unphysiological. The appearance of 25OHD in plasma after vitamin D administration reflects hepatic uptake and hydroxylation of the vitamin together with hepatic release and metabolism of the metabolite, so that these investigations do not directly measure 25-hydroxylation of 25OHD. In addition, changes in serum 25OHD levels after oral vitamin D will be affected by absorption of the vitamin from the intestine.

Early evidence for impaired hepatic production of 25OHD in liver

disease was reported by Hepner *et al.*,²³ who showed an impaired serum 25OHD response to parenteral vitamin D in 27 patients with alcoholic cirrhosis; however, in three patients with primary biliary cirrhosis, a normal response was seen. Wagonfeld *et al.*⁷ found no significant rise in serum 25OHD levels after large doses of oral or subcutaneous vitamin D in patients with primary biliary cirrhosis; however, these results could also be explained on the basis of poor intestinal absorption and low bioavailability respectively of the vitamin. In contrast, Skinner *et al.*,²⁴ showed that if provided with sufficient vitamin D, patients with severe chronic cholestatic liver disease could achieve normal serum 25OHD levels; this is confirmed by the finding by several other groups of normal serum 25OHD levels in vitamin D-treated patients with liver disease.^{13 17 21} In Skinner's study there was, however, some impairment of the serum 25OHD response to a single injection of vitamin D₂. Most subsequent studies have shown normal hepatic production of 25OHD in chronic cholestatic liver disease,^{25 26 15} particularly when the results are interpreted in the light of the prevailing vitamin D status²⁷; two studies have also demonstrated a normal plasma half-life of radiolabelled vitamin D₃ and 25OHD₃.^{26 15} In contrast, the data in alcoholics are conflicting, evidence for^{23 28} and against²⁹⁻³² impairment of hepatic 25OHD production being reported. One study also showed a reduced plasma half-life of radiolabelled vitamin D₃,²⁸ possibly reflecting increased hepatic uptake of the vitamin.

Intestinal absorption of vitamin D

Vitamin D absorption is bile acid dependent³³ and thus should be reduced in chronic cholestatic liver disease. The first report of vitamin D malabsorption by Thompson *et al.*³⁴ in two patients with biliary steatorrhoea has subsequently been confirmed by Krawitt *et al.*²⁵ and Barragry *et al.*³¹ in patients with primary biliary cirrhosis. 25OHD is also present in the diet and there is some indirect evidence for malabsorption of this metabolite in primary biliary cirrhosis.^{9 35} Therapy with the bile acid binding agent, cholestyramine, may further decrease absorption of vitamin D and 25OHD.^{9 36-38} The data in alcoholic liver disease are conflicting, some studies reporting impaired vitamin D absorption^{29 32} but another claiming no such abnormality.³¹

Urinary excretion of vitamin D metabolites

Evidence for increased urinary excretion of polar vitamin D metabolites in primary biliary cirrhosis has been reported,^{15 25} the amount of metabolite excreted being correlated with serum bilirubin levels. It is unclear whether increased urinary excretion represents an alternative excretory pathway to bile³⁹ in patients with cholestasis, altered vitamin D metabolism or reduced renal tubular reabsorption of the vitamin D metabolites. Although increased urinary loss may contribute to vitamin D deficiency in chronic cholestatic liver disease, it is unlikely to be quantitatively important in most cases.

Vitamin D binding protein

Both vitamin D and 25OHD are transported in human plasma bound to a

specific protein. DBP or group-specific component protein (Gc-globulin), an α_2 globulin.⁴⁰ Reduced serum DBP levels have been reported in patients with liver disease^{28 41-44}; however, because the saturation of the binding protein is normally very low (2-3%) the reduction in serum DBP levels encountered in chronic liver disease is insufficient to affect the serum 25OHD concentration.

Dietary intake of vitamin D

There are little data available on dietary vitamin D intake in patients with chronic liver disease, both low^{15 21} and normal²⁸ intakes being reported in small numbers of patients. Alcoholics may well have low intakes as part of their poor diet and patients with fat malabsorption may avoid dairy products and oily foods such as tinned fish, thus ingesting only small amounts of vitamin D.

Endogenous synthesis of vitamin D

Relatively little is known about the effects of jaundice on cutaneous vitamin D₃ synthesis. A normal serum 25OHD response to ultraviolet radiation in jaundiced patients has been reported,^{15 21} and Long *et al*⁴⁵ found no impairment of cutaneous synthesis of vitamin D₃ in rats with hyperbilirubinaemia when compared with anicteric controls. Thus the available data indicate that there is no significant impairment of cutaneous vitamin D₃ synthesis in jaundiced patients.

Other vitamin D metabolites

Normal production of radiolabelled 1,25(OH)₂D₃ and 24,25-dihydroxy-vitamin D₃ (24, 25(OH)₂D₃) from the radiolabelled precursor vitamin has been reported in primary biliary cirrhosis²⁷ and normal plasma 1,25(OH)₂D₃ levels have also been documented in vitamin D replete patients.^{46 47} In addition, low serum 1,25(OH)₂D₃ levels in vitamin D depleted patients with primary biliary cirrhosis can be restored to normal with small doses of vitamin D.²¹ The situations with regard to plasma concentrations of 24,25(OH)₂D₃ is less clear, Kaplan *et al*⁴⁶ reporting low levels in patients with primary biliary cirrhosis despite normal plasma 25OHD concentrations, but Davies *et al*²¹ demonstrating restoration of normal levels in vitamin D depleted primary biliary cirrhosis patients given small oral doses of vitamin D and Cuthbert *et al*⁴⁷ reporting normal or near normal levels in vitamin D replete patients.

Metabolic bone disease

Two major types of metabolic bone disease have been described in association with liver disease, namely osteoporosis and osteomalacia. The definition of these metabolic bone diseases is central to the issue of hepatic osteodystrophy and will now be discussed in more detail.

OSTEOPOROSIS

Osteoporosis is a heterogeneous skeletal disorder characterised by bone loss,⁴⁸ which may result in fracture, particularly of the vertebrae, hip, and

forearm.⁴⁹ Clinical and radiological changes appear only when bone loss is advanced and possibly irreversible.⁵⁰ Plasma and urine biochemistry are characteristically normal in osteoporosis although the plasma alkaline phosphatase may be raised after fractures. Because the distribution of osteoporosis is heterogeneous and loss of bone mineral in cortical and trabecular bone differs with respect both to onset and rate,⁵¹ early diagnosis requires measurement of bone mineral content at selected sites of clinical interest, particularly vertebral trabecular bone and both cortical and trabecular bone in the femoral neck. There are now three techniques available which provide accurate and reproducible measurements of bone mineral content in both axial and appendicular skeleton; quantitative computerised tomography,⁵² dual photon absorptiometry⁵³ and neutron activation analysis.⁵⁴ Quantitative computerised tomography is particularly well suited for measurements in vertebral trabecular bone, although it can also be used at other skeletal sites. Dual photon absorptiometry can also measure bone mineral content in appendicular or axial skeleton but unlike quantitative computerised tomography is unable to select out trabecular bone in the spine, where it measures combined cortical and trabecular bone mineral content together with any extravertebral mineral present in the area of measurement. The method is most commonly applied to the lumbar spine and femoral neck. Neutron activation analysis can measure either total or partial body calcium; partial body neutron activation analysis can be applied to a number of skeletal sites including the spine, hand, and forearm.

The advent of these techniques over the past few years invites reconsideration of the definition of osteoporosis. Its definition as a condition in which fracture has occurred will exclude many patients with abnormally low bone mineral content who may develop osteoporotic fractures in the future and who are most likely to benefit from treatment. Providing that adequate control data are available, osteoporosis is better defined as a condition in which bone mineral content at clinically relevant skeletal sites is greater than 2 standard deviations below the control mean value, matched for age, sex and, where relevant, number of years after menopause.

From the above discussion it is clear that if a diagnosis of osteoporosis is based on vertebral fractures or loss of vertebral height the true prevalence of pathological bone loss will be underestimated. In addition, trabecular bone volume measurements in iliac crest biopsies are not necessarily representative of the clinically relevant sites; indeed, the iliac crest trabecular bone volume may be normal in patients with osteoporotic fracture.¹⁷ Studies utilising metacarpal morphometry or single photon absorptiometry of the radius have provided valuable data on cortical bone loss but this information cannot be freely extrapolated to other skeletal sites, least of all vertebral trabecular bone.

OSTEOMALACIA

Osteomalacia is characterised by defective mineralisation of bone and is essentially a histological diagnosis. The commonest symptom is bone pain; in more advanced cases, bone tenderness, proximal muscle weakness and fracture may occur. The classical biochemical changes of hypocalcaemia, hypophosphataemia and raised plasma alkaline phosphatase are not

uniformly reliable indicators of bone disease and symptomatic, histologically proven osteomalacia has been documented in patients with normal plasma biochemistry.^{55 56} Plasma alkaline phosphatase is the most accurate indicator of bone disease in patients with normal liver function⁵⁷ but is obviously of much less value in patients with liver disease unless the contribution to total enzyme activity made by bone and liver isoenzymes can be accurately assessed. The radiological changes of pseudofracture and pathological fractures generally occur late in osteomalacia and may be absent even in severe cases. Examination of bone histology provides the only accurate method of diagnosis; as the histological changes of osteomalacia are distributed throughout the skeleton, biopsy at a single site is representative and in practice the iliac crest is chosen.

Histologically, osteomalacia is associated with an increase in the amount of osteoid or unmineralised bone but this may also be seen in a variety of other metabolic bone disorders. The cardinal feature of osteomalacia is defective mineralisation and proper documentation of this requires the use of double tetracycline labelling.⁵⁸ Tetracyclines are taken up at the mineralisation front in bone and can be visualised by fluorescence microscopy. The use of a double, time-spaced tetracycline label, given orally to the patient before the biopsy, allows examination both of the linear extent of mineralisation and its rate, from which in turn, bone formation rates at tissue and cellular level can be calculated.⁵⁹ Rigorous diagnostic criteria for osteomalacia, which should be used in prevalence studies, are as follows: – (1) increased osteoid seam width; (2) prolonged osteoid maturation period (calculated from osteoid seam width and bone formation rate at cellular level), and (3) reduced mineralisation rate.⁶⁰ In the absence of tetracycline labelling, an increase in osteoid amount together with reduced calcification fronts, as demonstrated by stains such as toluidine blue,⁶¹ comprise the absolute minimum criteria. As in the case of osteoporosis, control data are of prime importance and should ideally be derived from the same geographical area as the patient population. Unlike the techniques available for measuring bone mineral content, bone histomorphometry is associated with a considerable total measurement variance^{62–64} and small differences between control and patient populations, especially where control data from other laboratories are used, may be because of methodological or systematic interobserver differences rather than reflecting true differences between the two groups.

OSTEOMALACIA IN CHRONIC LIVER DISEASE

Estimates of the prevalence of osteomalacia in chronic cholestatic liver disease range between 0 and 72%.^{13 15 17 20 47 65–72} This enormous variation reflects several factors. First, few of the reported studies have been unselected, secondly, the severity of liver disease in the patients studied has varied, and thirdly, histological criteria for the diagnosis of osteomalacia have differed. Although reports of osteomalacia associated with chronic liver disease have appeared in the literature for many years,^{73–76} histological confirmation had to await techniques for cutting undecalcified sections of bone⁷⁷ and for demonstrating calcification fronts in bone.^{58 61} Atkinson *et al*⁶⁵ examined bone histology qualitatively in 25 patients with chronic liver disease, mainly cholestatic, and concluded that there was evidence of osteomalacia in nine; however, techniques for

examining calcification fronts were not available at that time and inspection of the data in the light of present day knowledge suggests that osteomalacia was probably only present in four patients. Quantitative histology in 11 jaundiced patients with chronic liver disease was reported by Paterson and Losowsky,⁶⁶ who found no osteomalacia on the basis of osteoid measurements. The first study in which both osteoid amount and calcification fronts were quantitatively assessed reported osteomalacia in four of 11 selected patients with primary biliary cirrhosis.⁹ Thus it was definitely established that osteomalacia occurred in patients with chronic cholestatic liver disease; however, the prevalence of this bone disease was less clear.

The study of Long *et al*¹³ in 1978 indicated a surprisingly high prevalence of osteomalacia in association with chronic liver disease, 22 of 32 patients studied being classified as osteomalacic in spite of long term high dose parenteral vitamin D prophylaxis in 50%. Decalcified sections only were examined, however, and thus bone mineralisation could not be assessed. Moreover, the upper limit of normal for absolute osteoid volume of 0.5% used in their study is not supported by published control data; if an abnormally high value is defined as >2 standard deviations above the control mean value, matched for age and sex, then values of up to 2% would be regarded as normal.⁶⁴ Using these criteria, only six (18.8%) patients would have excess osteoid. Results from a subsequent study of a similar patient population supported the contention that the prevalence of osteomalacia had been overestimated; quantitative assessment of both osteoid amount and calcification fronts revealed osteomalacia in only four of 32 unselected patients (12.5%), mild in two.¹⁷ Since then, a number of unselected studies both in Europe and North America have confirmed a low or absent prevalence of osteomalacia in chronic liver disease. Recker *et al*⁷¹ reported no osteomalacia in 27 American patients with primary biliary cirrhosis and seven with alcoholic cirrhosis and Herlong *et al*,⁶⁹ Matloff *et al*,⁷⁰ and Cuthbert *et al*⁴⁷ have all reported similar findings in smaller groups of American patients with primary biliary cirrhosis; in these studies a full histomorphometric evaluation was carried out. In the largest study to date, using the full diagnostic criteria referred to earlier, Stellan *et al*⁷² were unable to find a single case of osteomalacia in 36 British patients with chronic cholestatic liver disease.

RICKETS IN INFANTS AND CHILDREN WITH CHOLESTATIC LIVER DISEASE

Rickets has been reported in a high proportion of infants and children with hepatobiliary disease. Kobayashi *et al* reported radiological evidence of rickets in 59% of 21 with neonatal hepatitis and two of four with intrahepatic cholestasis.⁷⁸ The main pathogenetic factor is thought to be malabsorption of dietary vitamin D,^{16, 79} the major source of the vitamin in infants; however, evidence for reduced hepatic production of 25OHD has been reported in one patient with neonatal hepatitis.¹⁶

Parenteral vitamin D,^{78, 79} oral 25OHD₃⁸⁰ and parenteral 1,25(OH)₂D₃⁸¹ have all been shown to be effective in healing rickets associated with cholestasis, whereas even high doses of oral vitamin D appear ineffective. Because neither 25OHD₃ nor parenteral 1,25(OH)₂D₃ has a product licence in the UK, treatment with parenteral vitamin D is recommended, daily doses of 3000 IU apparently being effective.⁷⁹

PATHOGENESIS OF OSTEOMALACIA ASSOCIATED WITH CHRONIC LIVER DISEASE

The central role of vitamin D deficiency in the pathogenesis of osteomalacia associated with chronic liver disease is shown, first, by the presence of low serum 25OHD levels in osteomalacic patients^{9 17 21 82} and secondly, by the therapeutic response to vitamin D.^{18 21 83-85} Further indirect evidence for the pathogenetic role of vitamin D deficiency comes from the demonstration of secondary hyperparathyroidism in some osteomalacic patients, as evidenced by raised serum parathyroid hormone levels,^{17 21 82} decreased tubular phosphate reabsorption,^{82 86} increased urinary cyclic AMP excretion⁸² and histological evidence of osteitis fibrosa.^{21 82} It is important to note, however, that low serum 25OHD levels are also well documented in patients with no histological evidence of osteomalacia.^{17 18 20 47 69 70} Whether this reflects insufficient duration of vitamin D deficiency for the development of osteomalacia or the need for additional pathogenetic factors is unknown.

Calcium malabsorption has been reported in both parenchymatous and biliary liver disease.^{22 46 67 69 87 88} There is evidence that this is at least partly caused by vitamin D deficiency; thus some improvement has been reported after parenteral vitamin D,⁶⁷ oral 25OHD₃²² and oral 1,25(OH)₂D₃.⁸⁸ Precipitation of calcium salts by unabsorbed fats within the intestinal lumen may also contribute to calcium malabsorption.⁹⁰ Finally, malabsorption of phosphate has been reported in chronic liver disease,^{86 88 90} with some improvement after oral 1,25(OH)₂D₃⁸⁸ or oral 25OHD₃⁹⁰ administration.

TREATMENT OF HEPATIC OSTEOMALACIA

Both oral and parenteral administration of either vitamin D or its metabolites have been shown to be effective in healing osteomalacia associated with chronic cholestatic liver disease. Weekly injections of 100 000 IU of vitamin D₂ were shown to resolve the histological abnormalities of osteomalacia in two patients with primary biliary cirrhosis within six and 13 months respectively⁸⁴; oral 25OHD₃, in daily doses of 50⁸⁴ or 100-200 µg,¹⁸ parenteral 1,25(OH)₂D₃ 15 µg/month⁸³ and oral 1 α -hydroxyvitamin D₃, 2 µg/day,⁸⁵ have also been shown to heal hepatic osteomalacia. All these studies have focused on patients with chronic cholestatic liver disease; there are no corresponding data in alcoholic liver disease.

Experiments in animals indicated some vitamin D resistance in hepatic osteomalacia^{91 92} and large doses have traditionally been recommended for its treatment in man. If the main pathogenetic factors are privational, however, small doses should be sufficient. In addition, the parent vitamin itself should be effective as hepatic metabolism of vitamin D is relatively well preserved even in severe liver disease. Davies *et al*²¹ have shown that small amounts of oral vitamin D do indeed heal hepatic osteomalacia, doses of between 400 and 4000 IU being used, according to the degree of vitamin D malabsorption present.

Osteoporosis in chronic cholestatic liver disease

TRABECULAR OSTEOPOROSIS

Case reports of spinal osteoporosis associated with chronic cholestatic liver

disease date back to early this century.⁹³⁻⁹⁶ Ahrens *et al*⁷ described severe back pain, vertebral crush fractures and kyphosis in seven of 22 patients with chronic cholestatic liver disease, a further five patients having radiological evidence of skeletal demineralisation. A high prevalence of spinal osteoporosis was also reported by Atkinson *et al*,⁶⁵ 10 out of 25 patients showing radiological signs of osteoporosis. Subsequent studies, usually involving selected patients, have produced similar findings. Thus Kehayoglou *et al*⁶⁷ found radiological signs of demineralisation in 10 of 12 patients and Compston *et al*¹⁷ in 14 of 32. Long *et al*¹³ reported osteoporosis in 40% of 22 patients with chronic cholestatic liver disease; however, the diagnosis was based on a trabecular bone volume in iliac crest biopsies of <20%, a figure which is generally regarded as too high. Using the more acceptable criterion of an iliac crest trabecular bone volume > 2 standard deviations below the normal age and sex-matched mean value, varying prevalence rates of between 9% and 60% have been reported,^{47 69 70-72} two unselected studies reporting figures of 9% (1/11)⁴⁷ and 17% (6/36)⁷²; in the latter study, when both a subnormal iliac crest trabecular bone volume and vertebral fractures were used as criteria for osteoporosis, the prevalence rate rose to 36%.

CORTICAL OSTEOPOROSIS

The first quantitative study of cortical osteoporosis in chronic liver disease was reported by Paterson and Losowsky,⁶⁶ who carried out metacarpal thickness measurements in 38 patients with a variety of liver diseases. The majority of values were below the mean normal thickness although only three were > 2 standard deviations below this value. Subsequent reports have confirmed an increased prevalence of cortical osteoporosis in chronic cholestatic liver disease, using measurements of metacarpal thickness and/or single photon absorptiometry of the radius.^{7 69 70 72 98-100} In a study of 83 women with primary biliary cirrhosis, comparison of patients with age and sex matched controls revealed significantly increased medullary width together with a decreased combined cortical thickness and % cortical area, indicating increased endosteal resorption of the cortex.⁹⁸ Stellan *et al*,¹⁰⁰ using metacarpal morphometry, single photon absorptiometry of the radius and measurements of mean cortical thickness in iliac crest biopsies, found evidence of cortical osteoporosis in 28% of 36 unselected patients with chronic cholestatic liver disease, a figure similar to that reported by Epstein *et al*,⁹⁹ using metacarpal morphometry alone.

OSTEOPOROSIS IN OTHER FORMS OF CHRONIC LIVER DISEASE

Cortical and/or spinal osteoporosis have been reported in association with alcoholic liver disease,^{11 13 101-108} chronic active hepatitis,^{66 99 109} cryptogenic cirrhosis,⁹⁸ idiopathic haemochromatosis,^{110 111} glycogen storage disease¹¹² and primary benign hepatoma.¹¹² Increased bone loss in alcoholics is well documented^{113 114}; the risk of fractures, including osteoporotic vertebral fractures, is also increased.^{115 116} One study suggests that the mechanism of bone loss in alcohol induced osteoporosis may be defective osteoblastic function.¹¹⁷

The pathogenesis of osteoporosis associated with alcoholism is poorly understood and the relationship between bone loss and hepatic dysfunction rather than alcohol *per se* far from clear. Factors such as malnutrition with

low calcium and protein intake, vitamin D deficiency, calcium malabsorption,¹¹⁸ lack of physical activity,¹¹⁹ altered sex hormone status¹²⁰ and heavy tobacco consumption¹¹⁶ may all play a role. In addition, the higher risk of trauma in alcoholics clearly contributes to the increased fracture incidence.

Stellon *et al*¹⁰⁹ have recently studied the prevalence of osteoporosis in 36 unselected patients with chronic active hepatitis, maintained on corticosteroids, using measurements of trabecular bone volume and cortical thickness in iliac crest biopsies together with metacarpal morphometry and single photon absorptiometry of the radius. Forty seven per cent were found to have cortical and/or trabecular osteoporosis, bone loss in the iliac crest showing a weak inverse correlation with the total dose of steroids; in contrast the presence of cirrhosis was not related to the degree of bone loss at any of the sites studied.

TREATMENT OF OSTEOPOROSIS IN CHRONIC LIVER DISEASE

Very little is known about the treatment of hepatic osteoporosis. Oestrogens, which are effective in preventing postmenopausal bone loss, are generally regarded as contraindicated in chronic cholestatic liver disease, as are anabolic steroids. Fluoride therapy, effective in some patients with postmenopausal or senile osteoporosis, is not specifically contraindicated in liver disease, but no trials of its use in hepatic osteoporosis have been reported.

The small amount of data available relate to the use of calcium and vitamin D therapy. Evidence for,^{7 47} and against^{69 70} a protective effect of vitamin D or its metabolites on bone loss in chronic liver disease has been claimed, these studies being based on measurements of trabecular bone volume in iliac crest biopsies and/or bone mineral content in the radius. The length of the treatment period before reassessment, however, has been too short in all these studies for accurate determination of the long term effects of treatment on bone mass¹²¹ and no study has examined the effects of such treatment on spinal trabecular bone mineral content. The use of calcium supplements has also been advocated in hepatic osteoporosis; calcium infusions were reported to produce subjective relief of bone pain in 14 patients with primary biliary cirrhosis⁶⁸ and Epstein *et al*¹²² produced more objective evidence with the demonstration that metacarpal cortical bone loss in women with primary biliary cirrhosis could be prevented with either calcium gluconate or hydroxyapatite.

PATHOPHYSIOLOGY OF OSTEOPOROSIS ASSOCIATED WITH CHRONIC LIVER DISEASE

Osteoporosis may result from either a high or low turnover state. In the former, bone formation is normal or increased, but is exceeded by resorption, whereas in low turnover osteoporosis, bone formation is reduced. This classification bears important therapeutic implications, as therapy would be aimed primarily at reducing resorption in high turnover disease, but at stimulating bone formation in low turnover states.

Reduced osteoid volume and surface extent have been shown in several studies of patients with chronic cholestatic liver disease^{47 69 70 72} and, where reported, the mean osteoid seam width has also been reduced.^{70 72} Osteoid seam width depends on three factors; first, the rate of matrix

synthesis, secondly, the osteoid maturation period and thirdly the mineral appositional rate. In the presence of the prolonged osteoid maturation period⁷² and normal or low mineral appositional rate^{47 69-72} demonstrated in chronic cholestatic liver disease, reduced osteoid seam width indicates grossly reduced matrix synthesis. In support of this concept, there is increasing evidence that the rate of bone formation is reduced in chronic cholestatic liver disease, both at the cellular level and, to a greater extent at tissue level. Cuthbert *et al*⁴⁷ calculated bone formation rate at tissue level; comparison with control data from other sources^{59 123 124} reveals low formation rates in three patients and low-normal rates in the remaining four. In addition, the percentage of osteoid taking up a double label, expressed in this study as a percentage of osteoid surface, was considerably reduced.¹²⁵ Mean values reported by Herlong *et al*⁶⁹ for mineral appositional rate and bone formation rate at tissue level were at the lower end of the normal range. Finally, Stelson *et al*¹²⁶ have reported low bone formation rates at cellular and tissue level in 30 patients with primary biliary cirrhosis, using age and sex-matched control data for comparison. In this study, the mean wall thickness, or the thickness of the completed bone remodelling unit, was also shown to be reduced in the patient group, a further indication of impaired bone formation. As σ_{r} , the bone formation period, was normal or increased, impaired function of osteoblasts rather than a reduction in their life span is likely to be responsible.

The evidence regarding bone resorption in chronic cholestatic liver disease is more conflicting. Two studies have shown a modest increase in the surface extent of resorption^{47 126}; this does not necessarily imply an increase in resorption rate but might simply reflect impaired bone formation at the resorption sites, as formation always follows resorption in the normal sequence of bone remodelling. The observation in both studies that despite increased surface extent of resorption cavities, osteoclasts were sparse, would favour this explanation. In addition, biochemical indicators of increased resorption such as raised serum immunoreactive parathyroid hormone levels and increased urinary hydroxyproline and calcium excretion have been absent in the majority of patients studied.^{47 69 70} The demonstration by Cuthbert *et al*,⁴⁷ however, that resorption surfaces and serum immunoreactive parathyroid hormone levels fell after six months of vitamin D therapy would support the opposite view, namely that active bone resorption is increased.

The Figure illustrates the postulated chain of events in osteoporosis associated with chronic cholestatic liver disease. Osteoblasts are believed to be responsible for matrix synthesis, maturation and mineralisation. It is suggested that their function is selectively impaired so that matrix synthesis is affected to a much greater extent than maturation or mineralisation. Decreased bone formation results in reduced mean wall and trabecular plate thickness¹²⁶ and hence to a reduced trabecular bone volume. The possible role of increased bone resorption requires further investigation; studies using recently described methods to measure resorption cavity depths¹²⁷ should help to resolve this issue. Because the trabecular plate density remains normal,¹²⁶ however, erosion of whole trabecular plates does not appear to contribute to bone loss.

A recent study of bone histomorphometry in alcoholic liver disease¹⁰⁸ describes rather different findings. In contrast with chronic cholestatic liver

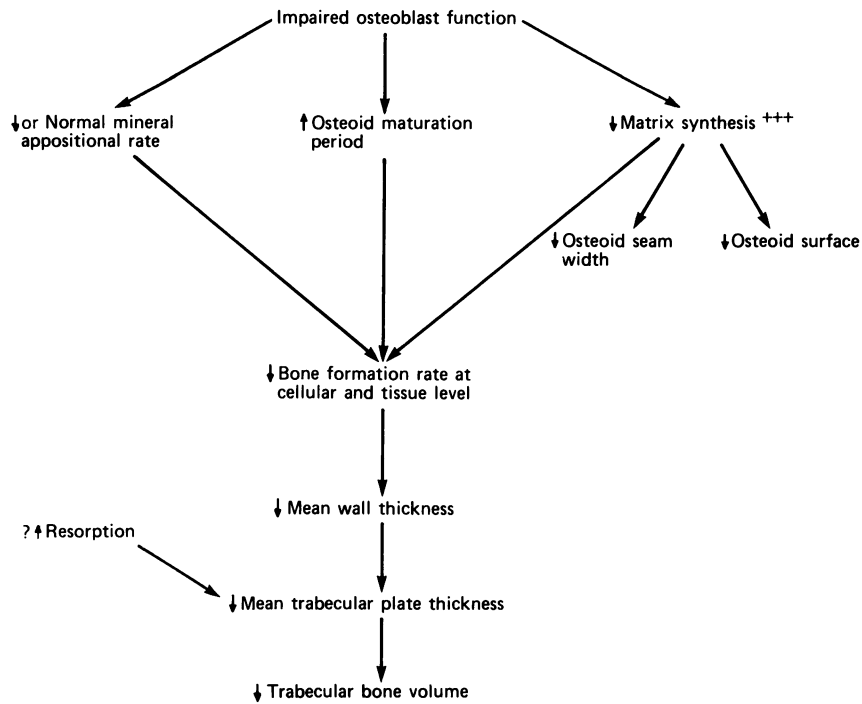


Figure Proposed pathophysiology of osteoporosis associated with chronic cholestatic liver disease.

disease, resorption surfaces were significantly reduced whilst osteoid seam width, mineral appositional rate and osteoid maturation period were normal. Bone formation rate and mean wall thickness were, however, reduced as in chronic cholestatic liver disease. The authors conclude that alcoholic liver disease is associated with low bone turnover and suggest that whilst the efficiency of osteoblasts is normal, as evidenced by the normal mineral appositional rate, there is a reduction in their life span resulting in reduced mean wall thickness. Measurement of the bone formation period, σ_{f} , would be required to confirm this theory. This report raises the interesting possibility that the pathophysiology of bone disease in alcoholic liver disease may differ from that seen in chronic cholestatic liver disease.

Conclusions

Privational factors are probably mainly responsible for the increased prevalence of vitamin D deficiency in patients with chronic liver disease. Although malabsorption of dietary vitamin D and 25OHD has also been shown, this is unlikely to be an important pathogenetic factor except in those patients with reduced endogenous synthesis of the vitamin. Other factors such as increased urinary losses of vitamin D and cholestyramine therapy may contribute to vitamin D deficiency in chronic cholestatic liver disease. There is little evidence for any significant impairment of hepatic

25OHD production in chronic cholestatic liver disease; in alcoholic liver disease, the evidence is more conflicting. Most evidence supports the view that formation of the dihydroxylated metabolites, 1,25 and 24,25(OH)₂D₃ is normal.

In the past, controversy over the prevalence of osteomalacia in chronic liver disease has arisen largely because of the use of inadequate histological criteria for its diagnosis and, in particular, failure to assess bone mineralisation. Early reports of a high prevalence have been disproved by subsequent studies in which more rigorous criteria have been used. There is no doubt that osteomalacia does occur in association with chronic liver disease, but its prevalence is low. Virtually all reported cases come from the UK, only one report coming from North America¹⁸; this supports the concept that privational vitamin D deficiency is an important pathogenetic factor in the development of hepatic osteomalacia, as the availability of ultraviolet irradiation in the UK is considerably less than in North America. The most recent studies from the UK indicate that the prevalence of osteomalacia is falling,⁷² probably reflecting the changing clinical spectrum of primary biliary cirrhosis.¹²⁸ Those patients most at risk appear to be jaundiced patients with chronic cholestatic liver disease; however, osteomalacia has also been reported in patients with alcoholic liver disease and chronic active hepatitis.^{11 13 10}

In view of the low prevalence of osteomalacia in chronic liver disease, routine vitamin D prophylaxis seems unwarranted. Prophylaxis may however, be indicated in high risk patients with severe prolonged cholestasis, and reduced exposure to ultraviolet irradiation. For these patients and for those with documented osteomalacia, oral doses of between 400 and 4000 IU are probably adequate in most cases²¹; these doses are much less likely to be associated with hypercalcaemia than the high dose parenteral therapy which has traditionally been advocated.

The investigation of osteoporosis has been revolutionised over the past few years by the development of techniques which accurately measure bone mineral content in clinically relevant skeletal sites. No large study in patients with chronic liver disease has yet been reported using these techniques; however, because prevalence rates of around 30% have been reported for both cortical and trabecular osteoporosis using relatively insensitive diagnostic techniques, it seems likely that osteoporosis will emerge as a major complication of chronic liver disease. Vertebral crush fractures appear to be the most common clinical complication of osteoporosis associated with chronic liver disease and thus measurements of spinal trabecular bone mineral content will be of particular interest.

The pathogenesis of osteoporosis in patients with chronic liver disease has received little attention. Calcium malabsorption, vitamin D deficiency with secondary hyperparathyroidism, alcohol and corticosteroid therapy^{129 130} are all possible factors; in addition, oestrogen deficiency will contribute in peri- and postmenopausal women. The pathophysiological basis of the osteoporosis appears to be osteoblastic dysfunction rather than excessive bone resorption.

The prevention and treatment of osteoporosis in patients with chronic liver disease pose many problems, partly because these topics have been so little studied and partly because oestrogens, known to be effective in preventing postmenopausal bone loss, are contraindicated in many

patients with liver disease, as are anabolic steroids. Calcium supplementation reduces cortical bone loss in chronic cholestatic liver disease¹²² but its effect on vertebral trabecular bone or on cortical and trabecular bone loss in the femoral neck is unknown. Fluoride therapy has not been evaluated. With the increasing availability of techniques such as quantitative computerised tomography and dual photon absorptiometry accurate documentation of the effects of agents on bone loss in chronic liver disease has become a practical possibility and provides an important area for research in the future. The choice of therapy is difficult, but fluoride is a possible candidate and calcium supplements deserve further investigation. Oestrogen therapy should also be evaluated in suitable patients; hepatic toxicity may be reduced by the use of oestrogen implants or transdermal administration, although the effect of these preparations on spinal trabecular bone loss in the normal population has not been documented. Once effective therapies have been established, prophylaxis may well be indicated in high risk patient groups – for example, those with corticosteroid treated chronic active hepatitis and postmenopausal women with primary biliary cirrhosis.

J E COMPSTON

*University of Wales College of Medicine,
Dept of Pathology,
Heath Park,
Cardiff CF4 4XN*

References

- 1 Ponchon G, Kennan AL, DeLuca HF. "Activation" of vitamin D by the liver. *J Clin Invest* 1969; **48**: 2032–7.
- 2 Fraser DR, Kodicek E. Unique biosynthesis by kidney of a biologically active vitamin D metabolite. *Nature* 1970; **228**: 764–6.
- 3 Haddad JG, Hahn TJ. Natural and synthetic sources of circulating 25-hydroxy-vitamin D in man. *Nature* 1973; **244**: 515–7.
- 4 Preece MA, Tomlinson S, Ribot CA, Pietrek J, Korn HT, Davies DM, Ford JA, Dunnigan MG, O'Riordan JLH. Studies of vitamin D deficiency in man. *Q J Med* 1975; **44**: 575–89.
- 5 Kobayashi T, Yasumura M. Studies on the ultraviolet irradiation of provitamin D and its related compounds. *J Nutr Sci Vitaminol* 1973; **19**: 123–38.
- 6 Ajdukiewicz AJ, Hamlyn AN, Preece MA, Ribot CA, O'Riordan JLH, Sherlock S. Vitamin D therapy and 25-hydroxyvitamin D levels in primary biliary cirrhosis. *Digestion* 1974; **10**: 332–3.
- 7 Wagonfeld JB, Nemchausky BA, Bolt M, Horst JV, Boyer JL, Rosenberg IH. Comparison of vitamin D and 25-hydroxy-vitamin-D in the therapy of primary biliary cirrhosis. *Lancet* 1976; **2**: 391–4.
- 8 Long RG, Skinner RK, Wills MR, Sherlock S. Serum 25-hydroxy-vitamin-D in untreated parenchymal and cholestatic liver disease. *Lancet* 1976; **2**: 650–2.
- 9 Compston JE, Thompson RPH. Intestinal absorption of 25-hydroxyvitamin D and osteomalacia in primary biliary cirrhosis. *Lancet* 1977; **1**: 721–4.
- 10 Sonnenberg A, Lilienfeld-Toal Hv, Sonnenberg GE, Rohner HG, Strohmeyer G. Serum 25-hydroxyvitamin D₃ levels in patients with liver disease. *Acta Hepato-Gastroenterol* 1977; **24**: 256–8.
- 11 Verbanck M, Verbanck J, Brauman J, Mullier JP. Bone histology and 25-OH vitamin D plasma levels in alcoholics without cirrhosis. *Calif Tiss Res* 1977; **22**: suppl. 538–41.
- 12 Garcia-Pascual B, Donath A, Courvoisier B. Plasma 25OHD, bone mass densitometry and ⁴⁷Ca intestinal absorption deficiency in chronic alcoholism. In: Norman AW, Schaefer K, Coburn JW, et al eds. *Vitamin D. Biochemical, chemical and clinical aspects related to calcium metabolism*. Berlin, New York: Walter de Gruyter, 1977: 819–21.
- 13 Long RG, Meinhard E, Skinner RK, Varghese Z, Wills MR, Sherlock S. Clinical,

- biochemical, and histological studies of osteomalacia, osteoporosis, and parathyroid function in chronic liver disease. *Gut* 1978; **19**: 85–90.
- 14 Meyer MS, Wexler S, Jedwab M, Spierer Z, Keysar N, Shibolet S. Low levels of serum calcium, phosphorus and plasma 25-hydroxyvitamin D in cirrhosis of the liver. *Israel J Med Sci* 1978; **14**: 725–30.
 - 15 Jung RT, Davie M, Siklos P, Chalmers TM, Hunter JO, Lawson DEM. Vitamin D metabolism in acute and chronic cholestasis. *Gut* 1979; **20**: 840–7.
 - 16 Kobayashi A, Kawai S, Ohkubo M, Ohbe Y. Serum 25-hydroxy-vitamin-D in hepatobiliary disease in infancy. *Arch Dis Child* 1979; **54**: 367–70.
 - 17 Compston JE, Crowe JP, Wells IP, Horton LWL, Hirst D, Merrett AL, Woodhead JS, Williams R. Vitamin D prophylaxis and osteomalacia in chronic cholestatic liver disease. *Dig Dis* 1980; **25**: 28–32.
 - 18 Reed JS, Meredith SC, Nemchausky BA, Rosenberg IH, Boyer JL. Bone disease in primary biliary cirrhosis: reversal of osteomalacia with oral 25-hydroxyvitamin D. *Gastroenterology* 1980; **78**: 512–7.
 - 19 Monnier LH, Colette C, Ribot C, Mion C, Mirouze J. Evidence for 25-hydroxyvitamin D deficiency as a factor contributing to osteopenia in diabetic patients with haemochromatosis. *Eur J Clin Invest* 1980; **10**: 183–7.
 - 20 Dibble JB, Sheridan P, Hampshire R, Hardy GJ, Losowsky MS. Osteomalacia, vitamin D deficiency and cholestasis in chronic liver disease. *Q J Med* 1982; **51**: 89–103.
 - 21 Davies M, Mawer EB, Klass HJ, Lumb GA, Berry JL, Warnes TW. Vitamin D deficiency, osteomalacia and primary biliary cirrhosis. Response to orally administered vitamin D₃. *Dig Dis* 1983; **28**: 145–53.
 - 22 Bengoa J, Sitrin MD, Meredith S, Kelly SE, Shah N, Baker AL, Rosenberg IH. Intestinal calcium absorption and vitamin D status in chronic cholestatic liver disease. *Hepatology* 1984; **4**: 261–5.
 - 23 Hepner GW, Roginsky M, Moo HF. Abnormal vitamin D metabolism in patients with cirrhosis. *Dig Dis* 1976; **21**: 527–32.
 - 24 Skinner RK, Long RG, Sherlock S, Wills MR. 25-hydroxylation of vitamin D in primary biliary cirrhosis. *Lancet* 1977; **1**: 720–1.
 - 25 Krawitt EL, Grundman MJ, Mawer EB. Absorption, hydroxylation and excretion of vitamin D₃ in primary biliary cirrhosis. *Lancet* 1977; **2**: 1246–9.
 - 26 Long RG, Skinner RK, Wills MR, Sherlock S. Formation of vitamin D metabolites from ³H- and ¹⁴C-radiolabelled vitamin D₃ in chronic liver diseases. *Clin Chim Acta* 1978; **85**: 311–7.
 - 27 Mawer EB, Lumb GA, Schaefer K, Stanbury SW. The metabolism of isotopically labelled vitamin D₃ in man: the influence of the state of vitamin D nutrition. *Clin Sci Mol Med* 1971; **40**: 39–53.
 - 28 Jung RT, Davie M, Hunter JO, Chalmers TM, Lawson DEM. Abnormal vitamin D metabolism in cirrhosis. *Gut* 1978; **19**: 290–3.
 - 29 Lund B, Sorensen OH, Hilden M, Lund B. The hepatic conversion of vitamin D in alcoholics with varying degrees of liver affection. *Acta Med Scand* 1977; **202**: 221–4.
 - 30 Posner DB, Russell RM, Absood S, Connor TB, Davis C, Martin L, Williams JB, Norris AH, Merchant C. Effective 25-hydroxylation of vitamin D₂ in alcoholic cirrhosis. *Gastroenterology* 1978; **74**: 866–70.
 - 31 Barragry JM, Long RG, France MW, Wills MR, Boucher BJ, Sherlock S. Intestinal absorption of cholecalciferol in alcoholic liver disease and primary biliary cirrhosis. *Gut* 1979; **20**: 559–64.
 - 32 Meyer M, Wechsler S, Shibolet S, Jedwab M, Harell A, Edelstein S. Malabsorption of vitamin D in man and rat with liver cirrhosis. *J Mol Med* 1978; **3**: 29–37.
 - 33 Greaves JD, Schmidt CLA. The role played by bile in the absorption of vitamin D in the rat. *J Biol Chem* 1933; **102**: 101–12.
 - 34 Thompson GR, Lewis B, Booth CC. Absorption of vitamin D₃-³H in control subjects and patients with intestinal malabsorption. *J Clin Invest* 1966; **45**: 94–102.
 - 35 Stamp TCB. Intestinal absorption of 25-hydroxycholecalciferol. *Lancet* 1974; **2**: 121–3.
 - 36 Thompson WG, Thompson GR. Effect of cholestyramine on the absorption of vitamin D₃ and calcium. *Gut* 1969; **10**: 717–22.
 - 37 Heaton KW, Lever JV, Barnard D. Osteomalacia associated with cholestyramine therapy for post-ileectomy diarrhoea. *Gastroenterology* 1972; **62**: 642–6.
 - 38 Compston JE, Horton LWL. Oral 25-hydroxyvitamin D₃ in treatment of osteomalacia associated with ileal resection and cholestyramine therapy. *Gastroenterology* 1978; **74**: 900–2.

- 39 Avioli LV, Lee SW, McDonald JE, Lund J, Deluca HF. Metabolism of vitamin D₃-³H in human subjects; distribution in blood, bile, feces and urine. *J Clin Invest* 1967; **46**: 983–92.
- 40 Daiger SP, Schanfield MS, Cavalli-Sforza LL. Group-specific component (Gc) proteins bind vitamin D and 25-hydroxyvitamin D. *Proc Natl Acad Sci USA* 1975; **72**: 2076–80.
- 41 Haddad JG, Walgate J. Radioimmunoassay of the binding protein for vitamin D and its metabolites in human serum. Concentrations in normal subjects and patients with disorders of mineral homeostasis. *J Clin Invest* 1976; **58**: 1217–22.
- 42 Imawari M, Akanuma Y, Itakura H, Muto Y, Kosaka K, Goodman DS. The effects of diseases of the liver on serum 25-hydroxy-vitamin D and on the serum binding protein for vitamin D and its metabolites. *J Lab Clin Med* 1979; **93**: 171–80.
- 43 Barragry JM, Corless D, Auton J *et al*. Plasma vitamin D-binding globulin in vitamin D deficiency, pregnancy and chronic liver disease. *Clin Chim Acta* 1978; **87**: 359–65.
- 44 Dibble JB, Sheridan P, Losowsky MS. A survey of vitamin D deficiency in gastrointestinal and liver disorders. *Q J Med* 1984; **53**: 119–34.
- 45 Long RG, Barragry JM, Mitchener P, Beer MS, Boucher BJ, Cohen RD. Effect of conjugated and unconjugated hyperbilirubinaemia on the plasma 25-hydroxy-vitamin D response to ultraviolet radiation in the rat. *Clin Sci* 1980; **59**: 293–6.
- 46 Kaplan MM, Goldberg MJ, Matloff DS, Neer RM, Goodman DBP. Effect of 25-hydroxyvitamin D₃ on vitamin D metabolites in primary biliary cirrhosis. *Gastroenterology* 1981; **81**: 681–5.
- 47 Cuthbert JA, Pak CYC, Zerwekh JE, Glass KD, Combes B. Bone disease in primary biliary cirrhosis: increased bone resorption and turnover in the absence of osteoporosis or osteomalacia. *Hepatology* 1984; **4**: 1–8.
- 48 Albright F, Smith PH, Richardson AM. Postmenopausal osteoporosis. *JAMA* 1941; **116**: 2465–74.
- 49 Nordin BEC. Clinical significance and pathogenesis of osteoporosis. *Br Med J* 1971; **1**: 571–6.
- 50 Doyle FH, Gutteridge DH, Joplin GF, Fraser R. An assessment of radiological criteria used in the study of spinal osteoporosis. *Br J Radiol* 1967; **40**: 241–50.
- 51 Riggs BL, Wahner HW, Dunn WL, Mazess RB, Offord KP, Melton LJ. Differential changes in bone mineral density of the appendicular and axial skeleton with ageing. *J Clin Invest* 1981; **67**: 328–35.
- 52 Genant HK, Cann CE, Ettinger B, Gilbert SG. Quantitative computed tomography of vertebral spongiosa: a sensitive method for detecting early bone loss after oophorectomy. *Ann Intern Med* 1982; **97**: 699–705.
- 53 Krølner B, Pors Neilson S. Measurement of bone mineral content (BMC) of the lumbar spine. 1. Theory and application of a new two-dimensional dual-photon attenuation method. *Scan J Clin Lab Invest* 1980; **40**: 653–63.
- 54 Cohn SH, Dombrowski CS. Measurement of total body calcium, sodium, chlorine, nitrogen and phosphorus in man by *in vivo* neutron activation analysis. *J Nucl Med* 1971; **12**: 499–505.
- 55 Chalmers J, Conacher WDH, Gardner DL, Scott PJ. Osteomalacia – a common disease in elderly women. *J Bone Joint Surg* 1967; **49(B)**: 403–23.
- 56 Compston JE, Horton LWL, Laker MF *et al*. Bone disease after jejunio-ileal bypass for obesity. *Lancet* 1978; **2**: 1–4.
- 57 Peach H, Compston JE, Vedi S, Horton LWL. Value of plasma calcium, phosphate, and alkaline phosphatase measurements in the diagnosis of histological osteomalacia. *J Clin Pathol* 1982; **35**: 625–30.
- 58 Frost HM. Tetracycline-based histological analysis of bone remodelling. *Calcif Tiss Res* 1969; **3**: 211–37.
- 59 Frost HM. A method of analysis of trabecular bone dynamics. In: Meunier PJ, ed. *Bone histomorphometry*. Second International Workshop. Toulouse, France: Société de la Nouvelle Imprimerie Fournié, 1977: 445–76.
- 60 Rao DS, Villanueva A, Mathews M *et al*. Histologic evolution of vitamin-D depletion in patients with intestinal malabsorption or dietary deficiency. In: Frame B, Potts JT, eds. *Clinical disorders of bone and mineral metabolism*. Amsterdam: Excerpta Medica, 1983: 224–6.
- 61 Rasmussen H, Bordier P. *The physiological and cellular basis of metabolic bone disease*. Baltimore, USA: Williams & Wilkins Co, 1974: 62–4.
- 62 Birkenhager-Frenkel DH, Schmitz PIM, Bruels PNWM, Lockefeer JHM, Heul ROvD. Biological variation as compared to interobserver variation and intrinsic error of measurement for some parameters, within single bone biopsies. In: Meunier PJ, ed.

- Bone histomorphometry*. Second International Workshop. Toulouse, France: Société de la Nouvelle Imprimerie Fournié, 1977: 63–8.
- 63 Delling G, Luehmann H, Baron R, Mathews CHE, Olah A. Investigation of intra- and inter-reader reproducibility. In: Jee WSS, Parfitt AM, eds. *Bone histomorphometry*. Third International Workshop. Sun Valley, Idaho, USA, Paris: Societé Nouvelle de Publications Médicales et Dentaires, 1980: 419–27.
 - 64 Vedi S, Compston JE, Webb A, Tighe JR. Histomorphometric analysis of bone biopsies from the iliac crest of normal British subjects. *Metab Bone Dis Rel Res* 1982; **4**: 231–6.
 - 65 Atkinson M, Nordin BEC, Sherlock S. Malabsorption and bone disease in prolonged obstructive jaundice. *Q J Med* 1955; **99**: 299–312.
 - 66 Paterson CR, Losowsky MS. The bones in chronic liver disease. *Scand J Gastroenterol* 1967; **2**: 293–300.
 - 67 Kehayoglou AK, Holdsworth CD, Agnew JE, Whelton MJ, Sherlock S. Bone disease and calcium absorption in primary biliary cirrhosis. *Lancet* 1968; **1**: 715–9.
 - 68 Ajdukiewicz AB, Agnew JE, Byers PD, Wills MR, Sherlock S. The relief of bone pain in primary biliary cirrhosis with calcium infusions. *Gut* 1974; **15**: 788–93.
 - 69 Herlong HF, Recker RR, Maddrey WC. Bone disease in primary biliary cirrhosis: histologic features and response to 25-hydroxyvitamin D. *Gastroenterology* 1982; **83**: 103–8.
 - 70 Matloff DS, Kaplan MM, Neer RM, Goldberg MJ, Bitman W, Wolfe HJ. Osteoporosis in primary biliary cirrhosis: effects of 25-hydroxyvitamin D₃ treatment. *Gastroenterology* 1982; **83**: 97–102.
 - 71 Recker R, Maddrey W, Herlong F, Sorrell M, Russell R. Primary biliary cirrhosis and alcoholic cirrhosis as examples of chronic liver disease associated with bone disease. In: Frame B, Potts JT, eds. *Clinical disorders of bone and mineral metabolism*. Amsterdam: Excerpta Medica, 1983: 227–31.
 - 72 Stellan AJ, Webb A, Compston J, Williams R. Lack of osteomalacia in chronic cholestatic liver disease. *Bone* (In press).
 - 73 Gerstenberger HJ. Rachitis hepatica. *Monatsschr Kinderheilkd* 1933; **56**: 217–21.
 - 74 Mayor G. Hepatogene Osteodystrophien. *Beitr Pathol* 1942; **106**: 408–46.
 - 75 Fraser HF. A case of vitamin D deficiency associated with cirrhosis of the liver and a dyscrasia of calcium and phosphorus metabolism. *J Paediatr* 1943; **23**: 410–20.
 - 76 Snapper I, Seely R, Falk S, Feder I. Osteomalacia in New York. *Ann Intern Med* 1954; **41**: 893–909.
 - 77 Duthie RB. A simple method for cutting sections from undecalcified bone for subsequent autoradiography and microscopy. *J Pathol Bact* 1954; **68**: 296–7.
 - 78 Kobayashi A, Kawai S, Utsunomiya T, Ohbe Y. Bone disease in infants and children with hepatobiliary disease. *Arch Dis Child* 1974; **49**: 641–6.
 - 79 Kooh SW, Jones G, Reilly BJ, Fraser D. Pathogenesis of rickets in chronic hepatobiliary disease in children. *J Paediatr* 1979; **94**: 870–4.
 - 80 Daum F, Rosen JF, Roginsky M, Cohen MI, Finberg L. 25-hydroxycholecalciferol in the management of rickets associated with extrahepatic biliary atresia. *J Paediatr* 1976; **88**: 1041–3.
 - 81 Heubi JE, Tsang RC, Steichen JJ, Chan GM, Chen I-W, DeLuca HF. 1,25-dihydroxyvitamin D₃ in childhood hepatic osteodystrophy. *J Paediatr* 1979; **94**: 977–82.
 - 82 Dibble JB, Sheridan P, Hampshire R, Hardy GJ, Losowsky MS. Evidence for secondary hyperparathyroidism in the osteomalacia associated with chronic liver disease. *Clin Endocrinol* 1981; **15**: 373–83.
 - 83 Long RG, Varghese Z, Meinhard EA, Skinner RK, Wills MR, Sherlock S. Parenteral 1,25-dihydroxycholecalciferol in hepatic osteomalacia. *Br Med J* 1978; **1**: 75–7.
 - 84 Compston JE, Horton LWL, Thompson RPH. Treatment of osteomalacia associated with primary biliary cirrhosis with parenteral vitamin D₂ or oral 25-hydroxyvitamin D₃. *Gut* 1979; **20**: 133–6.
 - 85 Compston JE, Crowe JP, Horton LWL. Treatment of osteomalacia associated with primary biliary cirrhosis with oral 1-alpha-hydroxyvitamin D₃. *Br Med J* 1979; **2**: 309.
 - 86 Long RG, Varghese Z, Skinner RK, Wills MR, Sherlock S. Phosphate metabolism in chronic liver disease. *Clin Chim Acta* 1978; **87**: 353–8.
 - 87 Whelton MJ, Kehayoglou AK, Agnew JE, Turnberg LA, Sherlock S. ⁴⁷Calcium absorption in parenchymatous and biliary liver disease. *Gut* 1971; **12**: 978–83.
 - 88 Farrington K, Epstein O, Varghese Z, Newman SP, Moorhead JF, Sherlock S. Effect of oral 1,25-dihydroxycholecalciferol on calcium and phosphate malabsorption in primary biliary cirrhosis. *Gut* 1979; **20**: 616–9.

- 89 Southgate DAT, Widdowson EM, Smits BJ, Cooke WT, Walker CHM, Mathers NP. Absorption and excretion of calcium and fat by young infants. *Lancet* 1969; **1**: 487-9.
- 90 Caniggia A, Gennari C. Intestinal absorption of radiophosphate after physiological doses of 25(OH)D₃ in normals, liver cirrhosis and chronic renal failure. In: Norman AW, Schaefer K, Coburn JW, et al, eds. *Vitamin D. Biochemical, chemical and clinical aspects related to calcium metabolism*. Berlin, New York: Walter de Gruyter, 1977: 755-7.
- 91 Taylor NB, Weld CB, Sykes JF. The relation of bile to the absorption of vitamin D. *Br J Exp Pathol* 1935; **16**: 302-9.
- 92 Heymann W. Metabolism and mode of action of vitamin D. III. Importance of the liver for its antirachitic efficacy. *Am J Dis Child* 1938; **55**: 913-23.
- 93 Seidel H. Permanente Gallenfistel und Osteoporose beim Menschen. *Munch Med Wochenschr* 1910; **57**: 2033-5.
- 94 Wangenstein OH. Complete external biliary fistula. *JAMA* 1929; **93**: 1199-204.
- 95 Loeper MM, Lemaire A, Lesobre R. Spondylomalacie dans la cirrhose biliaire. *Arch Fr Mal App Dig* 1939; **29**: 577-87.
- 96 Wernly M, Berdjis-Chamsi C. Les parathyroïdes humaines. Contribution à l'étude des hyperplasies et des adénomes. *Helv Med Acta* 1946; **13**: Suppl. 19: 1-144.
- 97 Ahrens EH, Payne MA, Kunkel HG, Blondheim SH, Eisenmenger WJ. Primary biliary cirrhosis. *Medicine (Balt)* 1950; **29**: 299-364.
- 98 Kato Y, Epstein O, Dick R, Sherlock S. Radiological patterns of cortical bone modelling in women with chronic liver disease. *Clin Radiol* 1982; **33**: 313-7.
- 99 Epstein O, Kato Y, Dick R, Sherlock S. The prevalence and pattern of cortical bone thinning in chronic cholestatic and parenchymal liver diseases. In: *16th Meeting of the European Association for the Study of the Liver* Lisbon: 1981, p. 44.
- 100 Stellon AJ, Davies A, Compston JE, Williams R. Osteoporosis in chronic cholestatic liver disease. *Q J Med* 1985; **57**: 783-90.
- 101 Lichtwitz A, Cachin M, Hioco D, Tutin M, de Sèze S. Le syndrome phosphocalcique des cirrhoses. *Sem Hôp Paris* 1959; **35**: 2399-409.
- 102 Huguenin P, Sudaka P, Monier JC, Monier Mme. Résultats de l'explorations phosphocalcique dans les cirrhoses du foie. *Algérie Méd* 1960; **64**: 713-21.
- 103 Summerskill WHJ, Kelly PJ. Osteoporosis with fractures in anicteric cirrhosis: observations supplemented by microradiographic evaluation of bone. *Proc Mayo Clin* 1963; **38**: 162-74.
- 104 Balabanski L, Hadzhidekov G. Modifications osseuses dans la cirrhose du foie. *Rev Int Hép* 1964; **14**: 81-91.
- 105 Colleson L, Grilliat J-P, Mathiew J, Laurent J. L'Ostéose raréfiante dans les cirrhoses du foie. *Presse Méd* 1965; **45**: 2571-4.
- 106 Saville PD. Changes in bone mass with age and alcoholism. *J Bone Joint Surg* 1965; **47A**: 492-9.
- 107 Meunier P, Dechavanne M, Prost G, Edouard C, Bernard J, Courpron P, Tolot F. L'os des cirrhotiques étudié par lecture quantitative de la biopsie osseuse. *Lyon Méd* 1973; **229**: 1089-95.
- 108 Mobarhan SA, Russell RM, Recker RR, Posner DB, Iber FL, Miller P. Metabolic bone disease in alcoholic cirrhosis: a comparison of the effect of vitamin D₂, 25-hydroxy-vitamin D, or supportive treatment. *Hepatology* 1984; **4**: 266-73.
- 109 Stellon AJ, Davies A, Compston JE, Williams R. Bone loss in autoimmune chronic active hepatitis on maintenance corticosteroid therapy. *Gastroenterology* 1985; **89**: 1078-83.
- 110 Delbarre F. L'ostéoporose des hémochromatoses. *Sem Hôp Paris* 1960; **36**: 3279-94.
- 111 Ross P, Wood B. Osteoarthropathy in idiopathic hemochromatosis. *AJR* 1970; **109**: 575-80.
- 112 Tseng Teng C, Daeschner CW, Singleton EB, Rosenberg HS, Cole VW, Hill LL, Brennan JC. Liver diseases and osteoporosis in children. *J Pediatr* 1961; **59**: 684-702.
- 113 Nilsson BE, Westlin NE. Changes in bone mass in alcoholics. *Clin Orthop* 1973; **90**: 229-32.
- 114 Dalén N, Lamke B. Bone mineral losses in alcoholics. *Acta Orthop Scand* 1976; **47**: 469-71.
- 115 Kristensson H, Lunden A, Nilsson BE. Fracture incidence and diagnostic roentgen in alcoholics. *Acta Orthop Scand* 1980; **51**: 205-7.
- 116 Seeman E, Melton JJ, O'Fallon WM, Riggs BL. Risk factors for spinal osteoporosis in men. *Am J Med* 1983; **75**: 977-83.
- 117 De Vernejoul MC, Bielakoff J, Herve M, et al. Evidence for defective osteoblastic

- function. A role for alcohol and tobacco consumption in osteoporosis in middle-aged men. *Clin Orthop Rel Res* 1983; **179**: 107–15.
- 118 Krawitt EL. Effect of ethanol ingestion on duodenal calcium transport. *J Lab Clin Med* 1975; **85**: 665–71.
- 119 Aloia JF, Cohn SH, Ostuni JA, Cane R, Ellis K. Prevention of involuntional bone loss by exercise. *Ann Intern Med* 1978; **89**: 356–8.
- 120 Pentikäinen PJ, Pentikäinen LA Azarnoff DL, Dujovne CA. Plasma levels and excretion of oestrogens in urine in chronic liver disease. *Gastroenterology* 1975; **69**: 20–7.
- 121 Parfitt AM. Calcitonin in the pathogenesis and treatment of osteoporosis. *Triangle* 1983; **22**: 81–102.
- 122 Epstein O, Kato Y, Dick R, Sherlock S. Vitamin D, hydroxyapatite, and calcium gluconate in treatment of cortical bone thinning in postmenopausal women with primary biliary cirrhosis. *Am J Clin Nutr* 1982; **36**: 426–30.
- 123 Melsen F, Mosekilde L. Tetracycline double-labelling of iliac trabecular bone in 41 normal adults. *Calcif Tiss Res* 1978; **26**: 99–102.
- 124 Vedi S, Compston JE, Webb A, Tighe JR. Histomorphometric analysis of dynamic parameters of trabecular bone formation in the iliac crest of normal British subjects. *Metab Bone Dis Rel Res* 1983; **5**: 69–74.
- 125 Compston JE, Vedi S, Webb A. Relationship between toluidine blue-stained calcification fronts and tetracycline-labelled surfaces in normal human iliac crest biopsies. *Calcif Tissue Int* 1985; **37**: 32–5.
- 126 Stellon AJ, Webb A, Compston JE, Williams R. Low bone turnover state in primary biliary cirrhosis. *Hepatology* (In press).
- 127 Eriksen EF, Mosekilde L, Melsen F. Trabecular bone resorption depth decreases with age: differences between normal males and females. *Bone* 1985; **6**: 141–6.
- 128 James OFW, Macklon AF, Watson AJ. Primary biliary cirrhosis: a revised clinical spectrum. *Lancet* 1981; **1**: 1278–81.