

## Alimentary tract and pancreas

# Oesophageal and gastric motility disorders in patients categorised as having primary anorexia nervosa

G STACHER, A KISS, S WIESNAGROTZKI, H BERGMANN, J HÖBART, AND C SCHNEIDER

*From the Psychophysiology Unit at the Departments of Psychiatry and Surgery I; Department of Medicine I; Division of Psychosomatic Medicine at the Department of Psychiatry; Division of Nuclear Medicine at the Department of Medicine II; and Ludwig-Boltzmann-Institute of Nuclear Medicine; University of Vienna, A-1090 Vienna, Austria*

**SUMMARY** Gastrointestinal motor function in patients with primary anorexia nervosa has rarely been investigated. We studied oesophageal motor activity in 30 consecutive patients meeting standard diagnostic criteria for primary anorexia nervosa (Feighner *et al*; DSM III). Seven were found to suffer from achalasia instead of primary anorexia nervosa, one from diffuse oesophageal spasm and one from severe gastro-oesophageal reflux and upper oesophageal sphincter hypertonicity, while partly non-propulsive and repetitive high amplitude, long duration contractions prevailed in the lower oesophagus of another six. In four patients with oesophageal dysmotility not responding to therapy and in 12 of 15 patients with normal oesophageal manometry, gastric emptying of a semisolid meal was studied. Emptying was normal in only three but markedly delayed in 13 cases (half emptying times 97-330 min, median: 147 min, as compared with 21-119 min, median: 47 min, in 24 healthy controls). In eight patients, the effects of domperidone 10 mg iv and placebo were compared under random double blind conditions. Half emptying times were shortened significantly ( $p < 0.01$ ) by domperidone. Conclusions: (1) symptoms of disordered upper gastrointestinal motor activity may be mistaken as indicating primary anorexia nervosa; (2) clinical evaluation of patients with presumed primary anorexia nervosa should rule out the possibility that disordered oesophageal motor activity underlies the symptoms; (3) delayed gastric emptying is a frequent feature in primary anorexia nervosa and might be returned to normal with domperidone.

Primary anorexia nervosa is a condition diagnosed primarily in women during adolescence and young adulthood. Traditionally, the driving motive for patients affected by this disorder is seen in a relentless pursuit of thinness, a phobic avoidance of being fat.<sup>1</sup> Severe weight loss often necessitates hospitalisation to prevent death by starvation and follow up studies indicate mortality rates between 15 and 21%.<sup>2</sup> The diagnosis, however, often is one of exclusion and the term primary anorexia nervosa is misleading as there is no true loss of appetite. Up to now, most studies have concentrated on the neuropsychiatric symptomatology. Although patients often

complain of postprandial gastric fullness or discomfort, which is relieved by belching and spontaneous or self-induced vomiting, only a few papers have dealt with gastrointestinal aspects of the disease. Of these papers, several have described acute gastric dilatation.<sup>3-7</sup> Gastric emptying of a water load was found to be significantly slower in primary anorexia nervosa patients than in healthy controls and this difference persisted after the patients had gained weight.<sup>8</sup> Others observed a delay in gastric emptying of a solid meal which was accelerated by metoclopramide in three of four patients.<sup>9</sup> Holt *et al*<sup>10</sup> found emptying of solid as well as of liquid gastric contents to be markedly delayed, whereas McCallum *et al*<sup>11</sup> observed a delay only in the emptying of solid food, which could be reversed partly by metoclopramide. Using barium radiograph examination, delays in gastric emptying could rarely be detected, while

Address for correspondence: Dr Georg Stacher, Psychophysiologisches Laboratorium, Psychiatrische Universitätsklinik, Währinger Gürtel 18-20, A-1090 Wien, Austria.

Received for publication 10 March 1986.

instead a dilatation of the duodenum<sup>5</sup> or a non-obstructive jejunal dilatation was reported.<sup>12</sup> Gastrointestinal symptoms were also noticed, although not given the attention they would have deserved, by authors concentrating more on the psychological aspects of the disorder. This deprecation of symptoms arising from the intestine was shared by Hilde Bruch, the most renowned researcher in this field, who stated: 'Anorexics will complain of feeling full after a few bites. . . One gains the impression that this sense of fullness is a phantom phenomenon, projection of formerly experienced sensations'.<sup>13</sup> A female patient categorised as having primary anorexia nervosa and treated accordingly for years, who was seen at our swallowing laboratory and revealed not to suffer from primary anorexia nervosa but from achalasia of the lower oesophageal sphincter,<sup>14</sup> prompted us to investigate oesophageal motor activity as well as gastric emptying in all patients referred as having primary anorexia nervosa to the Division of Psychosomatic Medicine at the Department of Psychiatry, University of Vienna. As it has been shown that administration of the peripherally acting dopamine antagonist, domperidone (Motilium<sup>®</sup>, Janssen Pharmaceutica, Beerse, Belgium), promoted gastric emptying in subjects with normal emptying rates<sup>15</sup> as well as in patients with idiopathic gastric stasis<sup>16</sup> and diabetic gastroparesis,<sup>17</sup> we investigated whether domperidone would also accelerate delayed gastric emptying in primary anorexia nervosa.

## Methods

### PATIENTS

Thirty female patients categorised as suffering from primary anorexia nervosa and presenting consecutively to the Division of Psychosomatic Medicine for hospitalisation and treatment participated in this study. The age of the patients ranged from 14–43 years ( $\bar{x}=23.1$  yr  $\pm 1.2$  SEM), their percentage of desirable weight from 51–74% ( $\bar{x}=63.8\% \pm 2.2$  SEM). None of the patients had any evidence of diabetes mellitus, connective tissue disease or neuropathy, and none had undergone gastric surgery or vagotomy. The diagnosis of primary anorexia nervosa was made by experienced psychiatrists in collaboration with competent physicians according to the specific criteria outlined by Feighner *et al*<sup>18</sup> and the DSM III.<sup>2</sup> Treatment included hospitalisation of six to eight weeks and psychotherapy according to accepted psychiatric practice as well as goal oriented weight programmes and caloric supplements. Tube feeding was routinely done in patients weighing less than 70% of their desirable body weight. None of the patients was on

any psychotropic drug or on drugs, which could have affected autonomous nervous system or smooth muscle function. Within the first week after admission to the hospital, oesophageal motor activity was recorded. In all patients with normal oesophageal motor activity and in those whose disordered oesophageal activity could not be demonstrated to be the cause of their symptoms, gastric emptying was studied. In eight of the latter patients, the effects of domperidone on gastric emptying were compared with those of placebo. These patients each underwent two gastric emptying studies separated by a one week interval. Immediately before one of the two studies, the patients received an intravenous injection of 10 mg domperidone and before the other an injection of saline placebo (0.15 M). The sequence of treatments was randomised according to a cross-over double blind design, so that half of the subjects received placebo on the first and domperidone on the second experimental day, and the other half received domperidone on the first and placebo on the second day. Studies of oesophageal and gastric motor activity were done only in patients who were not in an apparent state of psychological disturbance. Gastric emptying data of the patients were compared with those of a group of 24 healthy volunteers, who ranged in age from 20–39 years ( $\bar{x}=24.8$  yr  $\pm 0.9$  SEM) and in their percentage of desirable weight from 82–120% ( $\bar{x}=96.2\% \pm 2.2$  SEM). None of the healthy controls took any drugs at the time of investigation, except for oral contraceptives in the case of eight subjects. Informed consent was obtained from all patients and control subjects. The investigation was approved by the Institutional Committee on Studies Involving Human Beings. All studies were carried out between 0800 and 1100. The subjects were instructed to have their usual meal on the evening preceding the studies but to refrain from eating after 2200 and to eat and drink nothing before coming to the laboratory on the experimental day.

Oesophageal pressures were recorded by means of a Konigsberg model 31 probe (Konigsberg Instruments Inc, Pasadena, CA) fitted with three strain gauge force transducers spaced at 5 cm intervals and oriented radially 120° apart. The signals were processed by Beckman 9853A couplers and recorded by a R-411 Dynograph (Beckman Instruments Inc, Schiller Park, IL). The probe was passed into the stomach through the nose and slowly withdrawn at 5 mm steps and one minute intervals. During each one minute period, the patients were requested to take one wet swallow. The resting pressure within the lower oesophageal sphincter was measured, in millimetres of mercury (mm Hg), using end expiratory pressure with the mean fundic

pressure as the zero reference. Lower oesophageal sphincter resting pressures were expressed as the mean value of the recordings from each of the three transducers as obtained from the zone of maximal pressure. At each transducer site, at least three sphincter relaxations upon swallowing were recorded. Amplitude of contractions within the oesophageal body was measured from the oesophageal base line pressure to the peak of the complex. Duration of contractions was measured, in seconds, from the intersection of lines for mean resting intra-oesophageal pressure and the upstroke of the complex to its return to mean resting pressure. Propagation velocity was measured as the time elapsing from the onset of a swallow contraction at the oral transducer to the onset of contraction at the intermediate and from the intermediate to the aboral transducer. Mean values were determined from at least 10 swallows in the lower, middle, and upper third of the oesophageal body, respectively. The resting pressure within the upper oesophageal sphincter as well as the relaxation of the upper oesophageal sphincter upon swallowing were determined from at least three swallows at each transducer site and expressed as mean values. All recordings were scored independently and blindly by two investigators. The initiation of swallowing was recorded by a surface electromyogram of the submental muscles. Two Beckman biopotential electrodes were attached 1 cm from the right and left mandibular bow, respectively. The signal was integrated by a Beckman 9852A coupler.

Gastric emptying was recorded by means of an isotope technique.<sup>19,20</sup> A semisolid test meal labelled with a dose of 74 MBq (2 mCi) 99m-Technetium sulphur colloid diluted in isotonic saline (0.15 M) was used. The ingredients of the meal were 250 ml whole milk (8.75 g protein, 8.75 g fat, 12.5 g carbohydrates), 15 g sugar, 14 g maize starch (Maizena<sup>®</sup>, Knorr, Wels, Austria; 11.9 g carbohydrates), and, for flavouring, cinnamon. The meal was cooked slowly under continuous stirring until a semisolid consistency was reached. After cooling to a temperature at which it could be ingested, it was mixed thoroughly with the radioisotope by means of an electric mixer. The subjects were seated in an armchair tilted at an angle of 60° backwards to avoid possible overprojection of the stomach and the small intestine. Immediately after drug administration, the subjects sucked the test meal through a wide lumen polyethylene tube. A dual head large field of view gamma scintillation camera (Siemens ROTA camera, Siemens AG, Erlangen, West Germany) coupled to a computer system (Digital Equipments Corporation, System Gamma-11) was used. The heads were brought in anterior and

posterior positions, respectively, with the collimator surfaces exactly parallel to each other and the stomach appearing in the centre of the fields of view of both heads. Immediately thereafter, recording of the radioactivity was begun and continued for 50 min. Data were acquired in frame mode with serial images of 1 min frame time. After mirroring the image of the posterior head, the counts of the posterior and anterior images were added up, so that movements of the radionuclide in the axis between the collimators and resulting variations in tissue attenuation had only minor effects on the sum image. One region of interest was drawn over the stomach and a second over a small area in the right upper epigastrium, the latter being used for the quantification of background activity. Background activity was subtracted from the count in the stomach region, so that a falling count rate was representative of the rate of gastric emptying. The radioactivity count 10, 15, 20, 25, 30, 35, 40, 45, and 50 min after the start of recording was calculated as a percentage of the activity count at five minutes after the start of recording. In addition, the half emptying time ( $t_{1/2}$ ) was calculated from the slope of the linear regression line of the count rate plotted on a logarithmic scale against time on a linear scale.

## Results

### OESOPHAGEAL MOTOR ACTIVITY

Oesophageal manometry revealed that no less than 15 of the 30 primary anorexia nervosa patients studied had a disordered oesophageal motor activity: in seven there was an achalasia of the lower oesophageal sphincter (less than 75% relaxation from lower oesophageal sphincter resting pressure upon swallowing) together with non-propulsive contractions of low amplitude in the oesophageal body, and one patient complaining of retrosternal pain associated with eating and of food regurgitation had diffuse oesophageal spasms as defined by the manometric criteria proposed by Richter and Castell.<sup>21</sup> In one further patient, a hypertonic (resting pressure,  $\bar{x}$ =95 mm Hg) and, upon swallowing, inappropriately short relaxing upper oesophageal sphincter was found. This patient consequently was revealed to have massive gastro-oesophageal refluxes and a severe oesophagitis. Six more patients had contractions of high amplitude ( $\bar{x}$ >160 mm Hg) and long duration ( $\bar{x}$ >7.5 s) in the distal or distal and middle third of their oesophageal body, of which an increased proportion was repetitive (> two peaks) and non-propulsive. None of these patients, however, fulfilled all criteria for diffuse oesophageal spasm.<sup>21</sup> The gastrointestinal symptoms of the patients (Table 1) were, in retro-

Table 1 Gastrointestinal symptoms in patients with and without demonstrated oesophageal motor disorders

N	Achalasia 7	DOS 1	UOS-hypertonicity and GOR 1	DOCA 6	Normal motor activity 15
Dysphagia for solids	4	-	-	4	-
Dysphagia for solids and liquids	3	1	-	1	-
Vomiting spontaneous non-acidic	5	1	-	1	-
Vomiting spontaneous acidic	-	-	1	-	5
Vomiting selfinduced non-acidic	1	-	-	1	-
Vomiting selfinduced acidic	-	-	-	2	6
Excessive saliva regurgitation	5	-	-	-	-
Chest pain	3	1	-	-	-
Heart burn	-	-	1	-	1
Postprandial fullness and bloating	1	1	-	3	12
Epigastric pain	-	-	-	1	5
Belching	-	-	-	1	7
Constipation	4	-	1	2	11

DOS, diffuse oesophageal spasm; UOS, upper oesophageal sphincter; GOR, gastro-oesophageal reflux; DOCA, distal oesophageal contraction abnormalities – that is, partly non-propulsive and repetitive contractions of high amplitude and long duration.

spect, highly suggestive of the disorders demonstrated on manometry. In the patients with oesophageal motor disorders, therapeutical measures were taken immediately after manometry. Four of the seven patients with achalasia underwent a mechanical dilatation of their lower oesophageal sphincter. This treatment yielded complete symptom relief and weight gain in three cases, while in the remaining one a second dilatation was necessary to achieve this result. Weight gain ranged from 3–14 kg (5–23% of desirable weight) within a period of eight weeks after dilatation. In two patients, a second dilatation was necessary after 12 and 27 months, respectively. In two achalasia patients and in the one with diffuse oesophageal spasms, administration of the calcium antagonist, nifedipine (Adalat®, Bayer, Leverkusen, West Germany), led to a significant amelioration of symptoms and to weight gains of 5–10 kg (8–17% of desirable weight) within eight weeks. A fundoplication as well as a myotomy of the upper oesophageal sphincter were carried out in the patient with gastro-oesophageal reflux and upper oesophageal sphincter hypertonicity. Also this patient gained weight and her percentage of desirable weight after one year was 80% as compared with 69% before operation. The six patients with partly non-propulsive and repetitive contractions of high amplitude and long duration were treated with nifedipine as well. Only two of these patients reported symptom relief, however, and gained weight (4 and 6% of desirable weight, respectively, within eight weeks), whereas the condition of the other four remained unchanged.

#### GASTRIC EMPTYING

Gastric emptying was studied in four patients with partly non-propulsive, repetitive, high amplitude

contractions in the lower oesophagus who did not respond to nifedipine therapy and whose symptoms were felt not to be caused by oesophageal dysmotility as well as in 12 of the 15 patients with normal oesophageal manometry. In 13 patients, gastric emptying was found to be delayed more or less markedly, the  $t_{1/2}$  ranging from 97–330 min (median: 147 min) as compared with  $t_{1/2}$  values ranging from 21–119 min (median: 47 min) in the 24 healthy controls (Fig. 1). Only in the remaining three patients,  $t_{1/2}$  values (50, 72, and 75 min, respectively) were within the normal range (<2 median values of the control group). One of these patients, a 15 year old

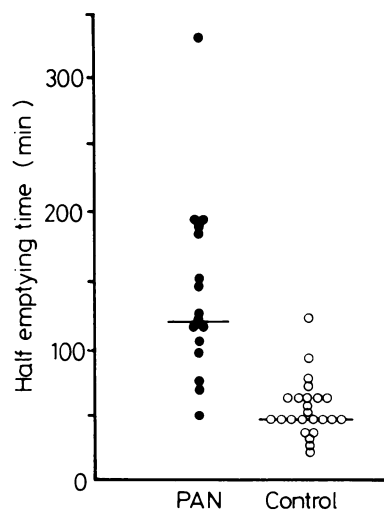


Fig. 1 Half emptying time, in minutes, of the isotopically labelled test meal in 16 primary anorexia nervosa patients and 24 healthy controls. Horizontal lines indicate median values.

girl, who had also normal oesophageal manometry, was consequently found to suffer from chronic appendicitis. As a group, the 16 anorectic patients studied had significantly greater  $t_{1/2}$  values than the 24 control subjects (Mann-Whitney test,  $p < 0.001$ ). Again, the symptoms of these patients, such as postprandial fullness and bloating, epigastric pain, and belching (Table 2), together with the fact that part of them indicated to get some relief from spontaneous or self-induced vomiting, were, in retrospect, suggestive of the demonstrated motility disorder. In the healthy controls, the  $t_{1/2}$  values were negatively correlated with body weight: the higher the body weight, the shorter was the  $t_{1/2}$  ( $r(22) = 0.452$ ,  $p < 0.05$ ). No such correlation was found in the primary anorexia nervosa patients. The mean per cent emptying rates of the two groups are shown in Fig. 2. In eight patients, the effects of 10 mg domperidone iv on gastric emptying were

compared with those of saline placebo (0.15 M). Domperidone accelerated emptying markedly in those patients in whom the delay in gastric emptying was more accentuated, but was less effectful when emptying was slowed to an only minor degree. The  $t_{1/2}$  values ranged from 50–330 min (median: 146 min) with placebo and from 50–120 min (median: 76 min) with domperidone, the difference being statistically significant (sign test for paired data,<sup>22</sup>  $p < 0.01$ ).

## Discussion

The results of the present study show that primary anorexia nervosa is a difficult diagnosis to make without very careful consideration and exclusion of disordered upper gastrointestinal motor activity and that symptoms of motility disorders, mainly vomiting together with weight loss, can be mistaken as indicating primary anorexia nervosa. As a necessary consequence, the last of the criteria for a diagnosis of anorexia nervosa listed in the Diagnostic and Statistical Manual of Mental Disorders,<sup>2</sup> – that is, 'No known physical illness that would account for the weight loss', must be given utmost attention to prevent misdiagnosis. Although the high incidence of oesophageal motor disorders found in our group of patients may not be present in other groups, such disorders might underly the symptoms in a substantial number of 'anorexics'. Hence, clinical studies should, in addition to a thorough history, always include oesophageal and gastric fluoroscopic examinations. When oesophageal and gastric motor functions appear to be compromised, oesophageal manometry and quantification of gastric emptying should be carried out to assist diagnosis and/or management. Failure to give due attention to upper gastrointestinal symptoms and to recognise a motility disorder is likely to precipitate severe damage to the patient. A slow gastric emptying rate, as found in most of our patients with normal oesophageal motor activity and in those with partly non-propulsive and repetitive contractions of high amplitude and long duration in the lower two thirds of the oesophageal body and whose symptoms did not respond to calcium antagonists, was reported to prevail in primary anorexia nervosa patients also by other authors.<sup>8–11</sup> Whether the delay in gastric emptying is a primary aetiological event or the consequence of malnutrition remains unclear. Although gastric emptying was found to be still slower in primary anorexia nervosa patients after weight gain than in healthy controls,<sup>8</sup> observations made in starving man seem to indicate that the nutritional state plays a crucial role. Incidences of acute gastric dilatation occurred in emaciated pris-

Table 2 Gastrointestinal symptoms in the 15 patients with normal oesophageal motor activity

N	Gastric emptying		
	Delayed 10	Normal 2	Not measured 3
Postprandial fullness and bloating	10	–	2
Epigastric pain	4	–	1
Belching	6	–	1
Vomiting spontaneous acidic	4	–	1
Vomiting self-induced acidic	4	1	1
Heart burn	1	–	–
Constipation	8	1	2

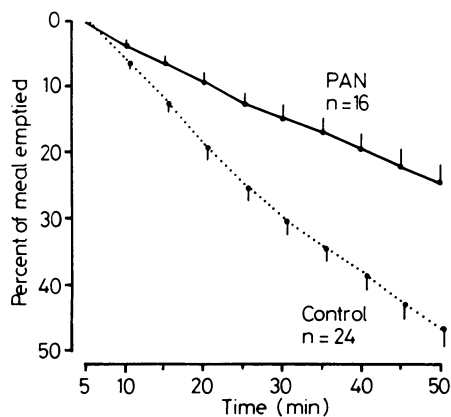


Fig. 2 Mean per cent rate  $\pm$  SEM of gastric emptying in 16 primary anorexia nervosa patients (—) and 24 healthy controls (.....).

oners of war during refeeding<sup>23</sup> and gastric emptying was found to be slowed in normal volunteers during starvation.<sup>24</sup> Furthermore, as described earlier<sup>25</sup> and found in the healthy controls used in this study as well, gastric emptying rate is correlated with body weight and obese subjects may empty their gastric contents abnormally rapidly.<sup>26</sup> Only a follow up study in primary anorexia nervosa patients having maintained a normal nutritional status for longer periods of time could give a conclusive answer to this question.

The treatment of primary anorexia nervosa traditionally is aimed at two distinct tasks: the correction of the severe malnutrition and the resolution of the psychological problems of the patient. The psychoanalytical approach has been singularly ineffective, as has been reported by many authors,<sup>13</sup> but also methods of behaviour modification have met with little success. The unsatisfactory results of psychotherapy have been commented on by Hilde Bruch hinting at the '... danger that psychiatrists do not give sufficient consideration to the self-perpetuating and destructive aspects of the nutritional deficiency itself, in the unrealistic expectation that resolution of the psychological problems would result in a correction of the weight'.<sup>13</sup> On the other hand, pharmacological treatment studies have been too few and too poorly designed in the past. This applies also to the studies indicating that metoclopramide might be of value to interrupt the vicious circle of gastric emptying being delayed and malnutrition resulting from vomiting and the feeling of fullness.<sup>9, 11</sup> The results obtained in the present study with the administration of 10 mg domperidone iv suggest that this drug also might be of therapeutic value, as it seems to act mainly in cases in which emptying is more severely delayed.

It is concluded (i) that primary anorexia nervosa is a difficult diagnosis to make without very careful consideration and exclusion of disordered upper gastrointestinal motor activity and that symptoms of such disorders might frequently be mistaken as indicating primary anorexia nervosa; (ii) clinical evaluation of patients with presumed primary anorexia nervosa should rule out the possibility that disordered oesophageal motor activity underlies the symptoms; (iii) delayed gastric emptying is a frequent feature in primary anorexia nervosa; (iv) domperidone accelerates delayed gastric emptying and might prove useful in the longterm management of primary anorexia nervosa patients; and (v) it remains to be investigated whether delayed gastric emptying is secondary to malnutrition and accelerates with weight gain or rather is of aetiological importance for the malnutrition characteristic for primary anorexia nervosa.

## References

- 1 Bruch H. *The golden cage*. New York: Vintage Books, 1978.
- 2 American Psychiatric Association. *Diagnostic and statistical manual of mental disorders*. 3rd ed. Washington, DC: APA, 1980: 67-9.
- 3 Russel GFM. Acute dilatation of the stomach in anorexia nervosa. *Br J Psychiatry* 1966; **112**: 203-7.
- 4 Evans DS. Acute dilatation and spontaneous rupture of the stomach. *Br J Surg* 1968; **55**: 940-2.
- 5 Scobie BA. Acute gastric dilatation and duodenal ileus in anorexia nervosa. *Med J Aust* 1973; **2**: 932-4.
- 6 Jennings KP, Klidjian AM. Acute gastric dilatation in anorexia nervosa. *Br Med J* 1974; **2**: 477-8.
- 7 Saul SH, Dekker A, Watson CG. Acute gastric dilatation with infarction and perforation. Report of fatal outcome in patients with anorexia nervosa. *Gut* 1981; **22**: 978-83.
- 8 Dubois A, Gross HA, Ebert MH, Castell DO. Altered gastric emptying and secretion in primary anorexia nervosa. *Gastroenterology* 1979; **71**: 319-23.
- 9 Saleh JW, Lebowl P. Gastric emptying studies in patients with anorexia nervosa: the effects of metoclopramide. *Gastroenterology* 1979; **76**: 1233.
- 10 Holt S, Ford MJ, Grant S, Heading RC. Abnormal gastric emptying in primary anorexia nervosa. *Br J Psychiatry* 1981; **139**: 550-2.
- 11 McCallum RW, Grill BB, Lange R, Planky M, Glass EE, Greenfeld DG. Definition of a gastric emptying abnormality in patients with anorexia nervosa. *Dig Dis Sci* 1985; **30**: 713-22.
- 12 Haller JO, Slovis TL, Baker DH, Berdon WE, Silverman JA. Anorexia nervosa: the paucity of radiological findings in more than fifty patients. *Pediatr Radiol* 1977; **5**: 145-8.
- 13 Bruch H. Anorexia nervosa. In: Lindner AE, ed. *Emotional factors in gastrointestinal illness*. Amsterdam: Excerpta Medica, 1973: 1-15.
- 14 Stacher G. Schlucken und Psyche. *Wien Klin Wochenschr* 1983; **95**: 502-111.
- 15 Baeyens R, van de Velde E, De Schepper A, Wollaert F, Reyntjens A. Effects of intravenous and oral domperidone on the motor function of the stomach and small intestine. *Postgrad Med J* 1979; **22**: Suppl 1: 19-23.
- 16 McCallum RW, Ricci D, DuBovik S. Effect of domperidone on gastric emptying and symptoms of patients with idiopathic gastric stasis. *Gastroenterology* 1984; **86**: 1179.
- 17 Horowitz M, Harding PE, Chatterton BE, Collins PJ, Shearman DJC. Acute and chronic effects of domperidone on gastric emptying in diabetic autonomic neuropathy. *Dig Dis Sci* 1985; **30**: 1-9.
- 18 Feighner JP, Robins E, Guze SB, Woodruff RA Jr, Winokur G, Munoz R. Diagnostic criteria for use in psychiatric research. *Arch Gen Psychiatry* 1972; **26**: 57-63.
- 19 Jacobs F, Akkermans LMA, Oei Hong Yoe, Hockstra A, Wittebol P. A radioisotope method to quantify the function of fundus, antrum, and their contractile activity in gastric emptying of a semisolid and solid

- meal. In: Wienbeck M, ed. *Motility of the digestive tract*. New York: Raven Press, 1982: 233–40.
- 20 Stacher G, Bergmann H, Havlik E, Schmierer G, Schneider C. Effects of oral cyclopropium bromide, hyoscine N-butylbromide and placebo on gastric emptying and antral motor activity in healthy man. *Gut* 1984; **25**: 485–90.
- 21 Richter JE, Castell DO. Diffuse esophageal spasm: a reappraisal. *Ann Intern Med* 1984; **100**: 242–5.
- 22 Conover WJ. *Practical nonparametric statistics*. New York: J. Wiley and Sons, 1971: 121–6.
- 23 Markowski B. Acute dilation of the stomach. *Br Med J* 1947; **2**: 128–30.
- 24 Keys A, Brozek J, Henschel A. *The biology of human starvation*. Minneapolis: University of Minnesota Press, 1950: 587–600.
- 25 Lavigne ME, Wiley ZD, Meyer JH. Gastric emptying rates of solid food in relation to body size. *Gastroenterology* 1978; **74**: 1258–60.
- 26 Wright RA, Krinsky S, Fleeman C, Trujillo J, Teague E. Gastric emptying and obesity. *Gastroenterology* 1983; **84**: 747–51.