

# Dynamic scanning defines a colonic defect in severe idiopathic constipation

M A KAMM, J E LENNARD-JONES, D G THOMPSON, R SOBNACK,  
N W GARVIE, AND MARIE GRANOWSKA

*From St Mark's Hospital, London and the London Hospital, London*

**SUMMARY** A technique is described in which a chemical stimulus applied to the mucosa of the right colon is used to assess colonic motor function. Peroral intubation of the right colon was achieved using a fine polyvinylchloride (PVC) tube. Bisacodyl was used to initiate colonic motor activity, and colonic transit was monitored using  $^{99m}\text{Tc}$  - DPTA and a gamma camera. In normal subjects there was rapid movement of the radiopharmaceutical from the right colon to the rectum. In patients with severe idiopathic constipation, a spectrum of colonic abnormality was observed from slow transit involving the rectum and sigmoid only to slow transit involving the whole colon. The hepatic flexure to rectum transit time for the 'head of the isotope column' in normals ranged from 1-10 minutes (mean 5.3 minutes), whereas in patients the transit time was 14-25 minutes in four patients and radioisotope did not reach the rectum by two hours in three other patients (controls *v* patients,  $p < 0.01$ ). Patients also showed relatively impaired transport of the isotope 'mass'. This technique has shown that the normal colon is capable of rapid effective transport in response to a standard stimulus, and that patients with severe idiopathic constipation have a definable colonic motor disorder.

Constipation in patients with an apparently normal colon can be disabling and unresponsive to laxatives.<sup>1,2</sup> Is it primarily an abnormality of colonic propulsion or of rectal expulsion? Many recent investigations have shown that these patients have difficulty in emptying the rectum.<sup>3-6</sup> Is this the whole reason for the slow passage of contents through the colon or are there colonic and anorectal components?

Under experimental conditions the right side of the colon has been stimulated with a contact laxative which normally induces immediate strong peristaltic contractions.<sup>7,8</sup> The propulsion of an isotope marker away from the point of stimulation has been used to determine whether colonic function is impaired in patients troubled by constipation. The defect observed shows that there is a colonic component to their symptoms and also explains their resistance to chemical laxatives.

## Methods

### SUBJECTS

Four men and two women, all aged 23 years, acted as healthy controls. None had any gastrointestinal complaints, and their bowel frequency ranged from one to three times per day.

Seven patients (one man and six women, aged 26-51 years) were studied. All complained of infrequent defecation, difficulty with rectal evacuation, and abdominal pain. The length of history varied from three to 40 years. None of the patients ever experienced diarrhoea suggestive of the irritable bowel syndrome. All patients had been investigated for their constipation to exclude metabolic and local causes. Defecatory function was assessed by their ability to expel a 50 ml water filled balloon in the left lateral position,<sup>4</sup> and colonic transit assessed by an abdominal radiograph five days after taking 20 radioopaque markers<sup>9</sup> (Table). All the patients had a normal diameter colon on barium enema and a positive rectoanal distention reflex, excluding Hirschsprung's disease.

Address for correspondence: Dr Michael Kamm, St Mark's Hospital, City Road, London EC1V 2PS.

Received for publication 19 February 1988.

Table Patient details

Patient and sex	Symbol	Age	Onset	Balloon constipation expulsion*	Five day shape transit study Shapes remaining (Normal<5)	Clinical features	Main features of scan
SB (F)	□	26	2	No	20	Spontaneous bowel action each 3 weeks	Slow transit from right colon. Isotope did not reach rectum by 120 minutes
AP (F)	●	26	23	No	0	Bowel action 2/week	Normal transit to descending colon, then slow transit to rectum
JM (F)	■	26	childhood	Yes	12	Bowel action each 1-3 weeks	Slow transit throughout colon. Repeat scan after bowel preparation gave same result
TC (F)	△	28	23	No	5	Bowel action 1/week	Normal transit to transverse colon but then delayed movement to rectum
JMM (M)	○	36	26	No	20	Bowel action less than every 2 weeks	Extremely slow transit throughout colon. Isotope did not reach rectum by 120 minutes
EF (F)	◆	31	20	No	20	Bowel action each 2-3 weeks	Normal transit to descending colon, then slow movement to rectum
FT (F)	▲	51	11	Not done	20	Bowel action each 3 weeks	Slow transit throughout colon. Isotope did not reach rectum by 120 minutes

\*Ability to expel a 50 ml water filled balloon from the rectum (see text).

The female controls and patients were all studied in the follicular phase of the menstrual cycle.

Each subject gave informed consent and the study was approved by the Tower Hamlets and City and Hackney District Health Authorities Ethical Committees.

#### EXPERIMENTAL METHOD

##### Patient preparation

Each of the constipated patients was asked to attempt to empty their bowel two days before having the test, either by the use of oral laxatives or enemas. Thereafter they were asked not to take any medication at all before the test but they continued with their normal diet.

##### Intubation technique

After an overnight fast, intubation of the right colon was achieved using the method described by Kerlin *et al.*<sup>10</sup> A 2 mm diameter triple lumen PVC tube with a mercury weighted capsule tip surrounded by an inflatable balloon was swallowed. One lumen was used to inflate and deflate the balloon, while the other channels were used as infusion ports 4 cm and 30 cm proximal to the tip. Passage through the pylorus was confirmed by screening, and the balloon was then inflated with 12 ml air. The subject was screened on one or two further occasions to confirm progress of the tube and allowed to eat an evening meal. The subjects were then fasted until completion of the study the next day. Exactly 3 m of the 4 m long tube was swallowed and on all occasions this was sufficient to reach the right colon.

The position of the end of the tube in the right colon was confirmed radiologically on day 2. On two

occasions the tube had entered the transverse colon, but one perfusion port was still positioned between the caecum and hepatic flexure. The perfusion ports were marked by radioopaque markers placed in the tube. Radiopharmaceutical and bisacodyl were infused through the proximal or distal infusion port depending on which port was situated between the caecum and hepatic flexure. Correct placement of isotope was confirmed by the subsequent characteristic scan appearance. Repositioning the tube was unsuccessful on the two occasions it was attempted, but these studies were still able to be carried out successfully. The tube was taken out at the completion of the test by gentle slow traction.

On all occasions the radiation dose from screening was minimised by utilising an 'image pulse store' facility which enables the image to be stored on the screen and entails 1.2 seconds screening per exposure.

##### Radionuclide imaging

The subject lay supine under a large field of view gamma camera (Siemens ZLC 7500) which encompassed the entire colon and rectum, and which was on line to a SSCI 100 Nodecrest computer. The gamma camera was peaked for <sup>99m</sup>Tc energy at 140 keV with 15% window and a low energy, general purpose, parallel hole collimator was used. 9 MBq <sup>99m</sup>Tc-DTPA in 10 ml 0.9% saline was infused into the right colon and observed for 10-15 minutes. Five and a half milligrams (5.5 mg) bisacodyl rectal solution (Dulcolax, Boehringer Ingelheim) made up to 10 ml with 0.9% saline was then infused *via* the same colonic port.

The scan was terminated when the bulk of the

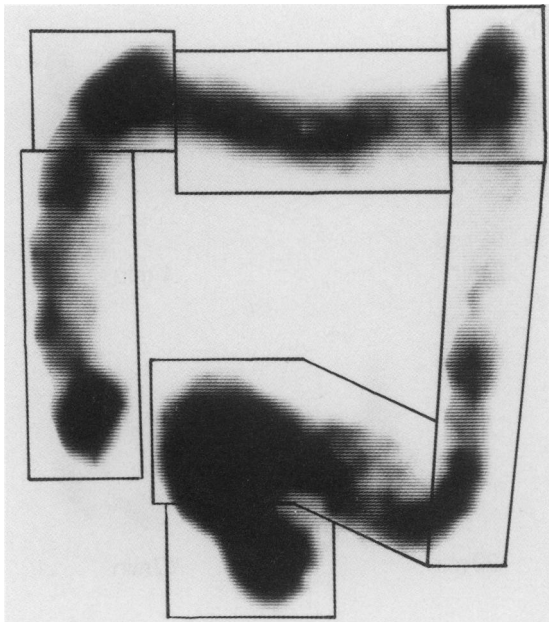


Fig. 1 To create regions of interest, an image is created which is a composite of all the acquired frames. The seven regions are caecum and ascending colon, hepatic flexure, transverse colon, splenic flexure, descending colon, sigmoid, and rectum.

isotope had moved to the rectum and a strong desire to defecate was experienced, or when two hours had elapsed.

The calculated maximum whole body radiation dose from the radionuclide was 0.1 mSv and the radiation dose from x-ray screening was 0.5 mSv.

#### Radionuclide measurements and data analysis

Data were acquired in the dynamic mode and frames were collected at one minute intervals. For the purpose of computer analysis seven anatomical regions of the colon were defined using a composite picture derived from all the frames (Fig. 1). The seven regions were caecum and ascending colon (region 1), hepatic flexure (2), transverse colon (3), splenic flexure (4), descending colon (5), sigmoid (6), and rectum (7). There was occasional slight overlap of the sigmoid and rectum, in which case the overlapping region was included in the sigmoid region. Time of arrival of the 'radionuclide head' in different regions was easily assessed visually. Because of the rapidity of the isotope movement it was not possible to obtain lateral or posteroanterior views to compensate for attenuation. The percentage count for each region was therefore expressed as a proportion of the total count in that frame.<sup>11</sup>

The isotope data were also used to generate a

number which would reflect the 'centre of mass' of the activity in each frame and therefore give a guide to the effectiveness of transport.<sup>12</sup> This figure represents the point in the colon (according to the predefined numbered regions) which lies ahead of 50% of the radioisotope mass. It can be calculated:

$$\text{COM}_n = \left[ \frac{\sum_{i=1}^n C_i \times i}{\sum_{i=1}^n C_i} \right]_n$$

where  $n$  = frame number,  $i$  = the number of the region of interest (in the order originally designated),  $C$  = count within the region  $i$ .

#### Results

##### HEAD OF THE COLUMN OF RADIOACTIVITY

There was no movement of isotope over a 10–15 minute observation period until bisacodyl was introduced into the right colon. There was then a uniformly rapid response in all the controls, with transport of nearly all the isotope to the rectum (Figs 2a, 3). The movement was associated with migratory abdominal cramping and an urge to defecate. The hepatic flexure to rectum transit time of the head of a column of radioactivity in the control group ranged from 1–10 minutes, with a mean of 5.3 minutes.

The patients all differed from the controls and showed a spectrum of abnormal response. In four patients there was normal rapid isotope movement to the splenic flexure or descending colon accompanied by abdominal cramping, with subsequent delayed transit into the sigmoid and rectum over a total of 14–25 minutes. The other three patients experienced no cramping, showed uniformly slow transit throughout the colon, and the radioactivity did not reach the rectum within two hours (Figs 2b, 2c, 3) (controls  $v$  patients,  $p < 0.01$ , Mann-Whitney U test).

Of the four patients who had previously retained all radioopaque markers five days after ingestion, three failed to propel the isotope to the rectum within two hours after bisacodyl.

##### MOVEMENT OF 'CENTRE' OF MASS OF RADIOACTIVITY (Fig. 4)

The 'centre of mass' moved from the region of the hepatic flexure to the descending colon in five of six normal subjects before observations ended at defecation. In five of seven patients, the rate of movement of the 'centre of mass' was slower than in the control subjects and the final position reached was proximal to the descending colon in all but one. The final position of the 'centre of the mass of radioactivity' during the scan period was significantly greater – that is, more distal – for the controls compared with the patients ( $p = 0.02$ , Mann-Whitney U Test).

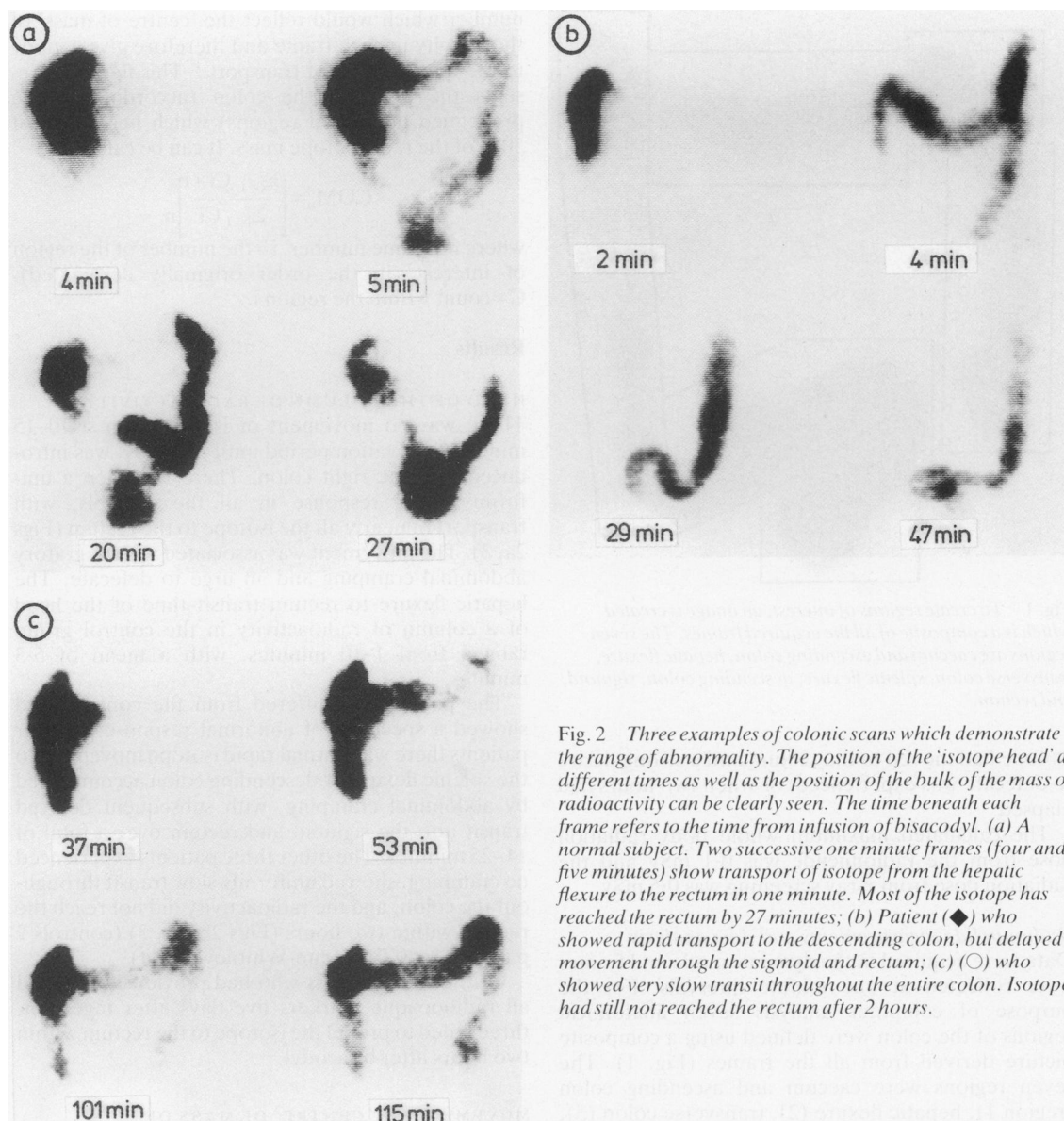


Fig. 2 Three examples of colonic scans which demonstrate the range of abnormality. The position of the 'isotope head' at different times as well as the position of the bulk of the mass of radioactivity can be clearly seen. The time beneath each frame refers to the time from infusion of bisacodyl. (a) A normal subject. Two successive one minute frames (four and five minutes) show transport of isotope from the hepatic flexure to the rectum in one minute. Most of the isotope has reached the rectum by 27 minutes; (b) Patient (◆) who showed rapid transport to the descending colon, but delayed movement through the sigmoid and rectum; (c) (○) who showed very slow transit throughout the entire colon. Isotope had still not reached the rectum after 2 hours.

#### DEFECATION AND ELIMINATION OF ISOTOPE

In all the control subjects, arrival of the isotope in the rectum resulted in a strong urge to defecate. Subjects were asked to resist this urge to enable accumulation of the isotope in the rectum, with subsequent elimination of 69–97% (median 84.5%) of the radioactivity by defecation in a single stool.

In four patients there was a desire to defecate, correlated with the arrival of isotope in the rectum.

The proportion of the total isotope excreted was 50%, 59%, 77%, and 86%. The three patients in whom the isotope front did not reach the rectum by 120 minutes had no urge to defecate and did not do so within the two hour imaging period.

#### MEASURES TO EXCLUDE COLONIC LOADING AS A CAUSE OF DELAYED TRANSIT

All patients were successful in achieving one or more

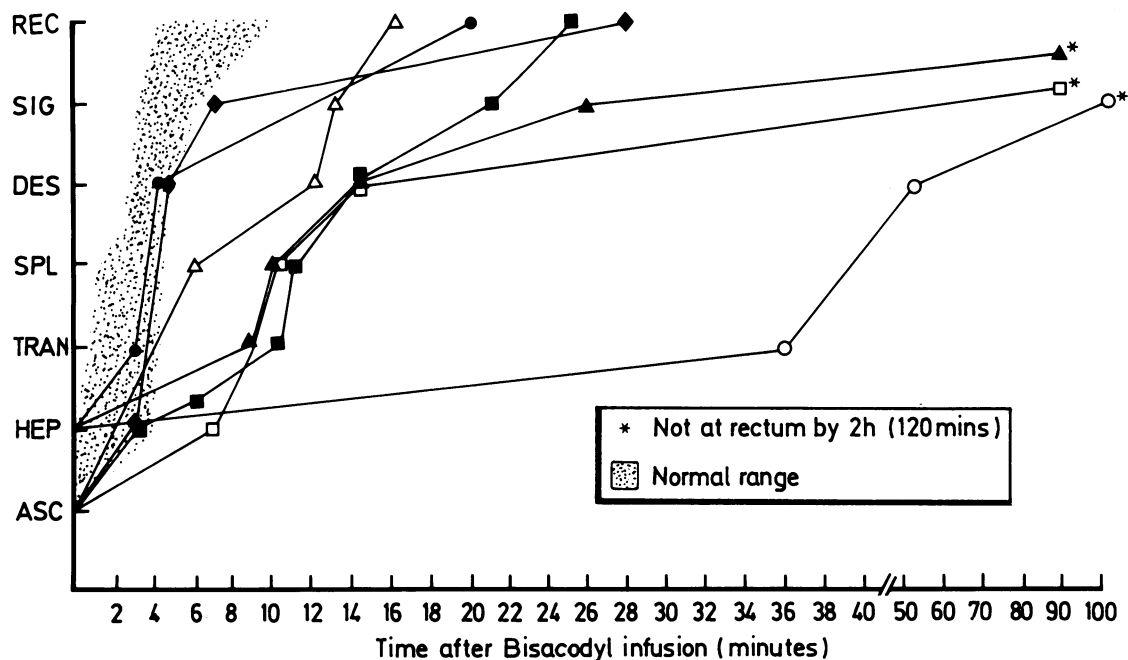


Fig. 3 Location of the radioactivity head at different times after infusion of bisacodyl into the right colon. The range of all the control lies within the shaded area.

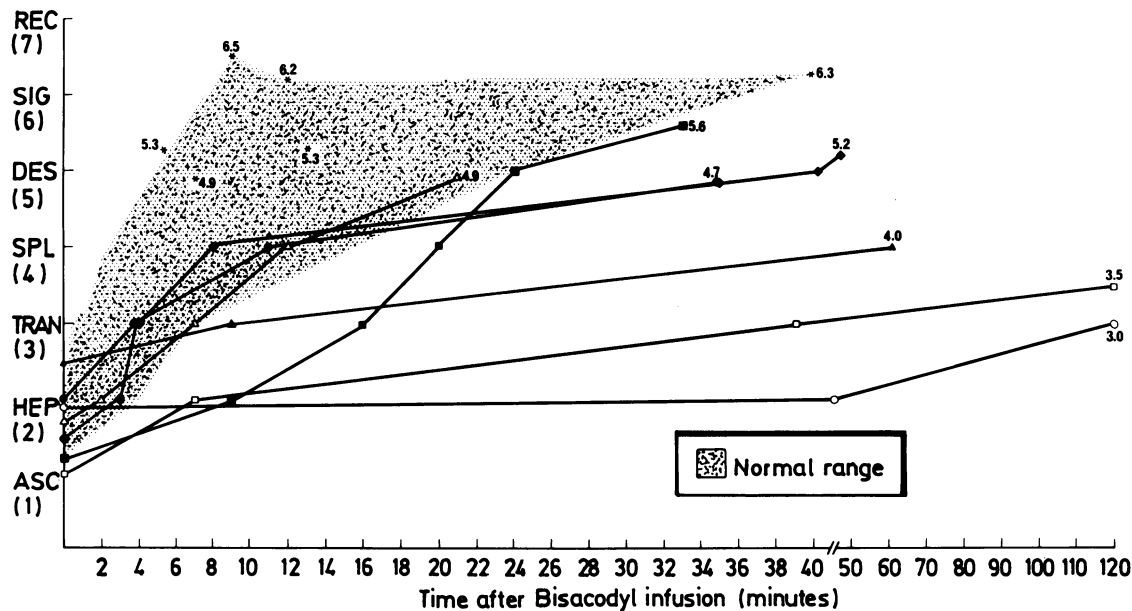


Fig. 4 The position of the 'centre of mass' of radioactivity in the colon at different times after infusion of bisacodyl. The range of all the controls lies within the shaded area. The numerals indicate the position in the colon reached by the centre of mass in each patient at the end of the study. \* = control.

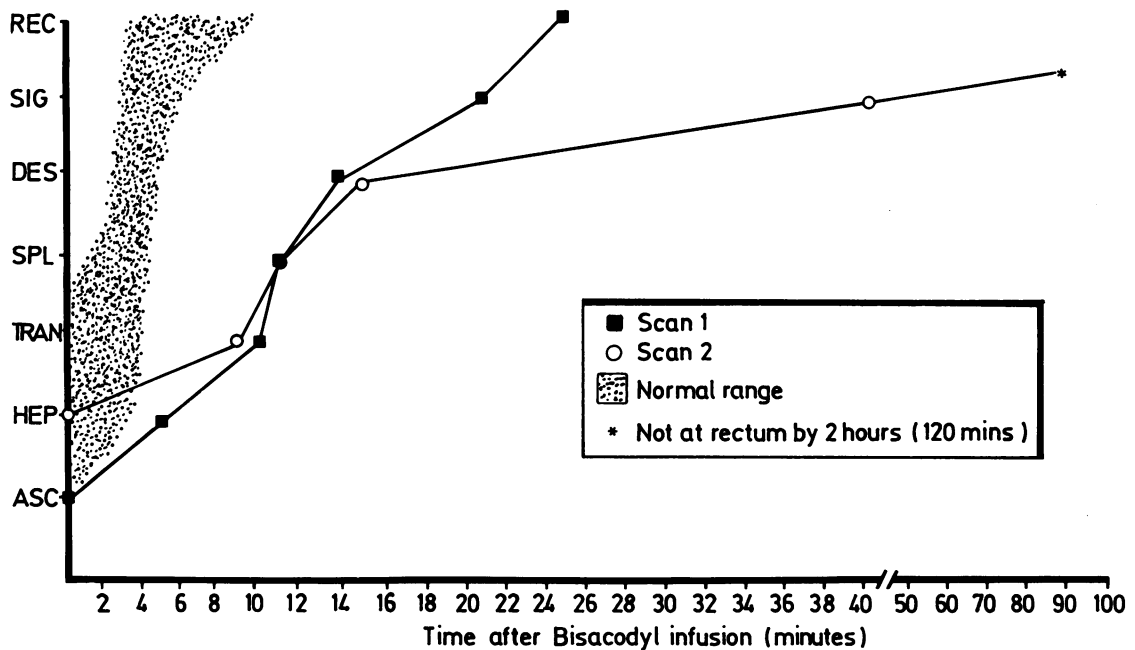


Fig. 5 Time of arrival of the 'radioactive front' after infusion of bisacodyl, in two scans performed in the same patient (JM). The second scan was performed after extensive bowel preparation. \*Radioactivity did not reach the rectum by 120 minutes.

bowel actions by the use of oral laxatives or enemas and suppositories two days before the test. During radiographic screening done to monitor progress of the peroral tube, the colon showed no evidence of faecal loading.

One patient had two studies carried out two days apart, using a reduced radionuclide dose of 6 MBq (for ethical reasons) but an identical stimulus. After the first scan the patient was maintained on clear fluids only for two days and bowel washouts were done. *x*-Ray screening confirmed the absence of residue. The second study gave very similar results to the first (Fig. 5).

### Discussion

Hardcastle and Mann first showed that bisacodyl induces high pressure peristaltic waves in the colon and that this effect can be blocked by the application of lignocaine to the mucosa.<sup>7</sup> The precise receptor site for bisacodyl and its mode of action remain unknown, although colonic instillation of bisacodyl is associated with increased sporadic spike bursts recorded myoelectrically.<sup>13</sup> These sporadic bursts, particularly the propagating ones, are associated with abdominal cramping and an urge to defecate.<sup>13</sup> In a study of patients with constipation, bisacodyl was introduced into the sigmoid colon.<sup>8</sup> Pressure

measurements in some patients showed a normal peristaltic response but others showed no activity.

Our aim was to initiate motor activity in the right side of the colon and to monitor transit. Because of the prolonged period of observation necessary the radiation dose from *x*-ray studies is unacceptably high. The use of a non-absorbable isotope allows accurate quantifiable imaging of the colon with a very small radiation dose. Spiller *et al* have used <sup>111</sup>In-DTPA to show shortened colonic transit time in normal individuals given an infusion of oleic acid, in a test of simulated steatorrhea.<sup>14</sup> Krevsky *et al* used the same isotope to accurately determine the colonic transit rate in normal individuals.<sup>12</sup> Our results have shown that the colon in normal individuals rapidly transports contents from the right side to the rectum in response to a standard chemical mucosal stimulus.

Patients with severe idiopathic constipation often complain that large doses of oral laxatives either have no effect at all, or produce abdominal cramping but do not result in a bowel action. The findings in this study provide a physiological basis for their observations. A high local concentration of bisacodyl in the right colon produced either minimal symptoms with slow transit of isotope or a normal response in the right colon with abdominal cramping and rapid isotope transit to the splenic flexure, but slow transit distal to that.

We believe that the failure of progression of radioisotope was related to lack of colonic response rather than because of hypersegmentation. In the patients in whom transit was delayed from the right colon there was little or no abdominal cramping, unlike those patients and all the controls in whom there was rapid transport of isotope. Furthermore, in an earlier study<sup>8</sup> in which a similar group of patients had bisacodyl instilled into the sigmoid colon, the patients exhibited either a normal peristaltic response or no motor activity at all. Further studies could address this question by the use of simultaneous pressure recordings, and the more frequent acquisition of frames in the early part of each study.

Particular care has been taken in this study to ensure that there was no artefactual cause for slow colonic transport either by reduced contact of the bisacodyl with the mucosa due to dilution or by obstruction to forward passage due to faecal loading. Only patients with a normal diameter colon (on barium enema) were studied to ensure a similar area of mucosal contact with the stimulus. Colonic loading with faecal residue was excluded by giving purgatives two days before the test and its absence checked by x-ray screening. The even distribution of isotope at the time of infusion did not give the appearance of a loaded colon. Finally, the scan was repeated in a patient whose colon had been thoroughly emptied and results were similar to the first test.

Patients with severe idiopathic constipation are almost exclusively women and usually of childbearing age.<sup>1</sup> Although these patients appear to form a homogeneous clinical group, the results of this study tend to suggest that the colonic defect is variable. Some patients have a defect in transport throughout the colon, while others have an abnormality confined to the left colon or even rectosigmoid. The colonic abnormality in these patients could be one originating in the pelvis, with variable proximal involvement. The major motor innervation to the left colon derives from the sacral parasympathetic supply *via* the nervi erigentes, and damage to this supply can cause left sided colonic inertia.<sup>15</sup> Impulses from the pelvic nerves may pass via the 'long colonic nerves', which are thought to traverse most of the length of the colon.<sup>16</sup>

Alternatively, it is possible that the defect we have shown is caused by a disorder of the myenteric plexus or colonic smooth muscle. Silver staining of the myenteric plexus in these patients does show a decrease in number and a morphological abnormality of neurones,<sup>17</sup> but whether these changes are uniform throughout the colon is unknown.

Two of the patients in this study had normal or near normal whole gut transit as assessed using radioopaque shapes. Patients with normal transit may

experience abdominal pain and difficulty with rectal evacuation similar to those with slow transit.<sup>2-5</sup> This study shows that there may indeed be a colonic motor defect in these patients which is not demonstrable by other methods.

The effective treatment of severe constipation remains a formidable problem. Patients usually present having tried a large range of laxatives, often in enormous doses. They not only suffer from infrequent bowel actions, but also from difficult defecation, abdominal pain, and bloating. The severity of these symptoms is such that some patients come to colectomy, but even this extreme step is not always successful in relieving all their symptoms.<sup>18</sup> It is hoped that a test such as this one, which uses a powerful local stimulus, will enable motor function in different regions of the colon to be defined.

M A Kamm was supported by the St Mark's Research Foundation.

The authors wish to thank Ms L Bingham, Ms E Walker and the Staff of the Department of Nuclear Medicine at the London Hospital for technical assistance, Mr J Northover and Dr K Britton for their encouragement, and the Imperial Cancer Research Fund for permission to use their gamma camera.

## References

- 1 Preston DM, Lennard-Jones JE. Severe chronic constipation of young women: 'idiopathic slow transit constipation' *Gut* 1986; **27**: 41-8.
- 2 Turnbull GK, Lennard-Jones JE, Bartram CI. Failure of rectal expulsion as a cause of constipation: why fibre and laxatives sometimes fail. *Lancet* 1986; **i**: 767-9.
- 3 Preston DM, Lennard-Jones JE. Anismus in chronic constipation. *Dig Dis Sci* 1985; **30**: 413-8.
- 4 Barnes PRH, Lennard-Jones JE. Balloon expulsion from the rectum in constipation of different types. *Gut* 1985; **26**: 1049-52.
- 5 Read NW, Timms JM, Barfield LJ, Donnelly TC, Bannister JJ. Impairment of defecation in young women with severe constipation. *Gastroenterology* 1986; **90**: 53-60.
- 6 Womack NR, Williams NS, Holmfield JHM, Morrison JFB, Simpkins KC. New method for the dynamic assessment of anorectal function in constipation. *Br J Surg* 1985; **72**: 994-8.
- 7 Hardcastle JD, Mann CV. Study of large bowel peristalsis. *Gut* 1968; **9**: 512-20.
- 8 Preston DM, Lennard-Jones JE. Pelvic motility and response to intraluminal bisacodyl in slow-transit constipation. *Dig Dis Sci* 1985; **30**: 289-94.
- 9 Hinton JM, Lennard-Jones JE, Young AC. A new method for studying gut transit times using radioopaque markers. *Gut* 1969; **10**: 842-7.

- 10 Kerlin P, Tucker R, Phillips SF. Rapid intubation of the ileo-colonic region of man. *Aust NZ J Med* 1983; **13**: 591-3.
- 11 Trotman IF, Price CC. Bloating irritable bowel syndrome defined by dynamic <sup>99m</sup>Tc bran scan. *Lancet* 1986; ii: 364-6.
- 12 Krevsky B, Malmud LS, D'Ercole F, Maurer AH, Fisher RS. Colonic transit scintigraphy. *Gastroenterology* 1986; **91**: 1102-12.
- 13 Schang JC, Hemond M, Hebert M, Pilote M. Changes in colonic myoelectrical spiking activity during stimulation by bisacodyl. *Can J Physiol Pharmacol* 1986; **64**: 39-43.
- 14 Spiller RC, Brown ML, Phillips SF. Decreased fluid tolerance, accelerated transit, and abnormal motility of the human colon induced by oleic acid. *Gastroenterology* 1986; **91**: 100-7.
- 15 Devroede G, Lamarche J. Functional importance of extrinsic parasympathetic innervation to the distal colon and rectum in man. *Gastroenterology* 1974; **66**: 273-80.
- 16 Christensen J, Schulze-Delrieu K. Nerves in the colon: discovery and rediscovery. *Gastroenterology* 1985; **89**: 222-3.
- 17 Krishnamurthy S, Schuffler MD, Rohrmann CA, Pope CE. Severe idiopathic constipation is associated with a distinctive abnormality of the colonic myenteric plexus. *Gastroenterology* 1985; **88**: 26-34.
- 18 Preston DM, Hawley PR, Lennard-Jones JE, Todd IP. Results of colectomy for severe idiopathic constipation in women (Arbutnot Lane's disease). *Br J Surg* 1984; **71**: 547-52.