

Complement activation within the coeliac small intestine is localised to Brunner's glands

R B GALLAGHER, C P KELLY, S NEVILLE, O SHEILS, D G WEIR,
AND C F FEIGHERY

From the Departments of Immunology, Histopathology and Clinical Medicine, Trinity College, Dublin, Ireland

SUMMARY Complement activation may play an important role in the pathogenesis of coeliac disease. In the present study immunohistochemical localisation of C3 and of a neoantigen exposed only on the terminal C5b-9 complement complex has been performed on small intestinal biopsy sections from newly diagnosed untreated coeliac patients, from coeliac patients on long-term gluten-free diet and from disease controls. Levels of C3 were markedly increased in treated coeliac patients compared with controls. Staining of C3 was concentrated subepithelially and within the centre of the lamina propria. No staining was detected at these sites using antibody to the neoantigen, however, strongly suggesting that the increased levels of C3 seen in the coeliac patients was the result of increased extravasation of serum proteins rather than complement activation. Surprisingly, complement activation was detected within the glands of Brunner. Positive staining using anti-C5b-9 neoantigen was found in all coeliac patients, both treated and untreated. Three of the 13 disease controls also showed reactivity with this antibody. This novel finding suggests that Brunner's glands, hitherto largely neglected structures, may play an important role in the development of coeliac disease.

Although the pathogenic mechanism in coeliac disease is not yet fully understood, involvement of the immune system is generally accepted. Antibody,¹⁻³ complement,^{4,7} T cell,⁸⁻¹⁰ and mast cell^{11,12} responses at the site of disease activity have all been reported but the relative contribution of each of these factors remains unclear. Evidence for participation of complement in the disease process comes from the finding of reduced levels of serum concentrations of some complement components⁴ and from immunohistochemical localisation of large quantities of complement within the coeliac small bowel.^{5,7} It is not known, however, whether the complement detected in the coeliac intestine is activated, and therefore involved in damaging processes, or is present in native form, simply as a result of increased

extravasation of serum proteins. In this study we have addressed this question by using a monoclonal antibody which detects a neoantigen exposed only on formation of the terminal C5b-9 complex. Thus complement activation in the coeliac small bowel, through either classical or alternate pathway, is detectable using this antibody.

Methods

SMALL INTESTINAL BIOPSIES

Intestinal biopsies, taken at endoscopy from the distal duodenum, were obtained from 10 coeliac patients and 13 disease controls. Five of the coeliac patients were newly diagnosed, with characteristic histological abnormalities which showed improvement on subsequent gluten free diet. The other five coeliac patients were on longterm gluten free diet (Table 1). The diagnosis of the 13 disease controls are shown in Table 2. The tissues were embedded in OCT, snap frozen and stored at -70°C until used.

Address for correspondence: Dr Richard B Gallagher, Department of Immunology, Trinity College Medical School, St James' Hospital, Dublin 8, Ireland.

Accepted for publication 1 March 1989.

Table 1 Dietary and histological status of treated coeliac patients

Patient	Dietary compliance	Duration	Histology
1	Strict	1 year	Normal
2	Strict	17 years	Normal
3	Fair	12 years	Subtotal villous atrophy
4	Strict	2 years	Minimal villous blunting, no inflammation
5	Strict	3 years	Normal

IMMUNOHISTOLOGICAL STAINING OF TISSUE SECTIONS

Cryostat sections (5 µm) were cut, air-dried overnight and fixed for four minutes in acetone. When staining, tris-buffered saline (TBS) 0.5 M, pH 7.6 was used as the buffering system throughout and each step was followed by a wash in TBS.

To study complement activation, slides were incubated for 20 minutes in 1/50-diluted ascites fluid containing monoclonal antibody against a neoantigen on the C5b-9 complex (clone 3B1), a gift from Dr S Bhakdi, University of Giessen, FGR. Omission of the primary monoclonal antibody served as a

Table 2 Diagnoses of control group

Patient	Endoscopic findings
1	Duodenal ulcer
2	Duodenal ulcer
3	Duodenitis
4	Duodenitis
5	Duodenitis
6	Gastric ulcer
7	Antral gastritis
8	Normal*
9	Normal*
10	Normal*
11	Normal*
12	Normal*
13	Normal†

*Clinical diagnosis: irritable bowel syndrome; †Investigated for recurrent, severe aphthous stomatitis, duodenal biopsy normal.

negative control. The nature and specificity of the 3B1 antibody have been previously confirmed.^{13,14} Binding of the antibody was visualised using either the immunoperoxidase (according to Kelly *et al.*, 1987)¹⁵ or alkaline phosphatase¹⁶ staining methods. Results obtained by the two methods were identical.

On some sections polyclonal rabbit antisera

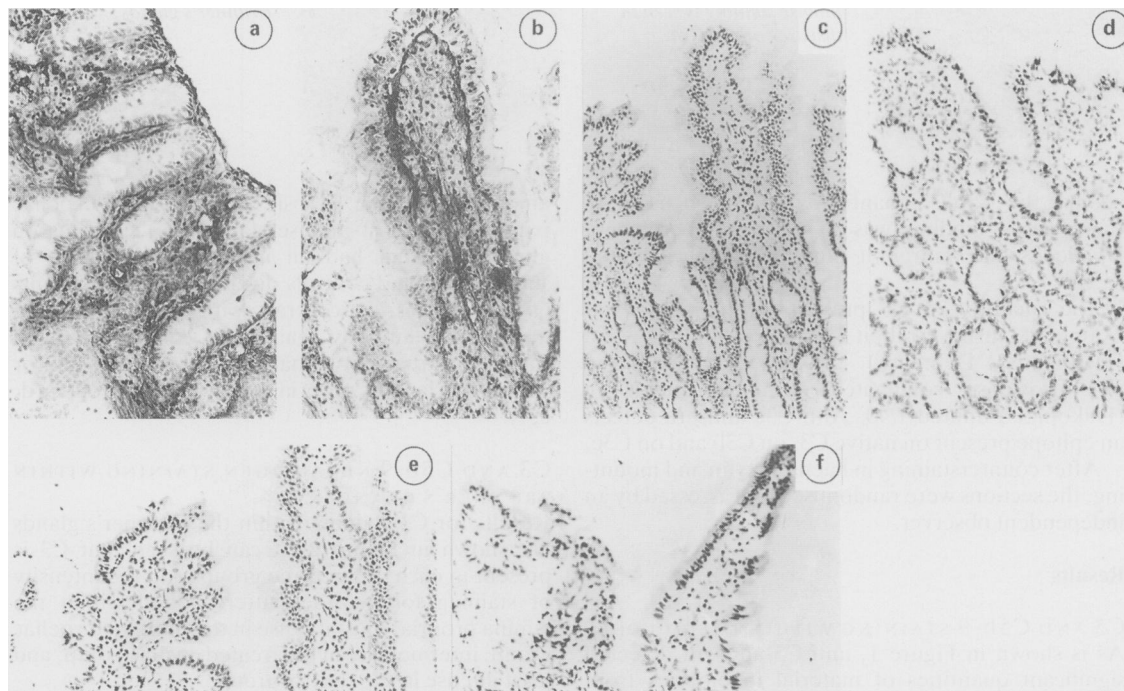


Fig. 1 C3 and C5b-9 neoantigen deposition in the small intestine. Strong C3 staining was found subepithelially in untreated coeliac disease (a) and both subepithelially and within the lamina propria of treated coeliac disease (b). In disease controls much less intense C3 staining subepithelially and within the lamina propria was observed (c). C5b-9 staining was completely absent in untreated coeliac disease (d), coeliac patients on gluten free diet (e), and disease control patients (f).

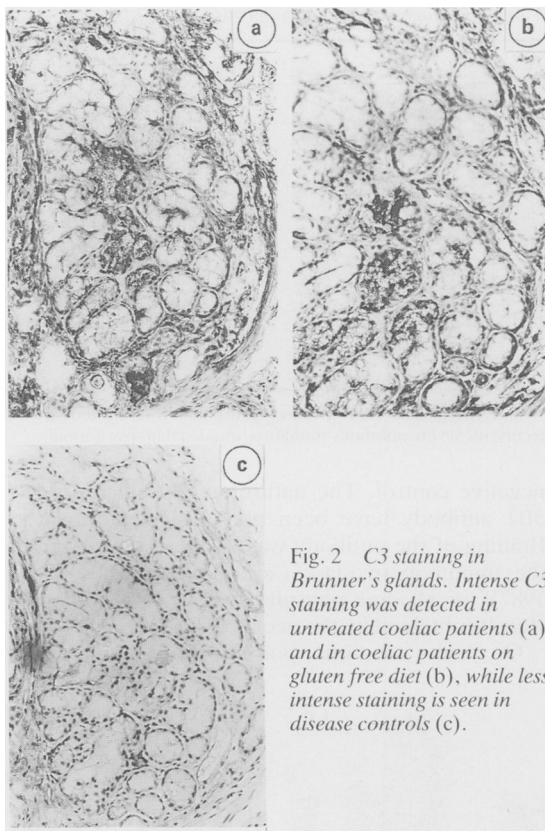


Fig. 2 C3 staining in Brunner's glands. Intense C3 staining was detected in untreated coeliac patients (a) and in coeliac patients on gluten free diet (b), while less intense staining is seen in disease controls (c).

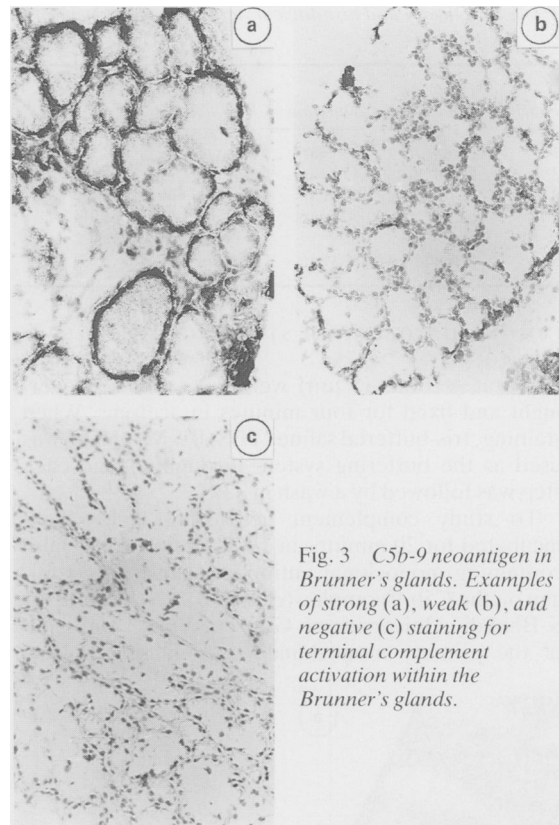


Fig. 3 C5b-9 neoantigen in Brunner's glands. Examples of strong (a), weak (b), and negative (c) staining for terminal complement activation within the Brunner's glands.

against the C5b-9 neoantigen¹⁷ were also used. In these cases binding was assessed by peroxidase labelled swine antirabbit immunoglobulin, diluted 1/20.

The quantity of C3 present in the tissue was examined using rabbit antihuman C3c sera (Dakopatts, Denmark) diluted 1/60, followed by peroxidase conjugated swine antirabbit Ig (Dakopatts) diluted 1/40. Anti-C3c antisera detects an epitope present on native C3, on C3b and on C3c.

After counterstaining in haematoxylin and mounting, the sections were randomised and assessed by an independent observer.

Results

C3 AND C5b-9 STAINING WITHIN THE MUCOSA

As is shown in Figure 1, anti-C3 antisera detected significant quantities of material in biopsies from all three groups studied. The pattern of staining, subepithelially and down the centre of the lamina propria was similar in every case. There were, however, marked quantitative differences in the

amount of staining; biopsies from untreated coeliac patients had most intense staining (a), patients on gluten free diet had an intermediate amount of staining (b), and controls displayed lowest amounts of staining (c). In contrast with C3 staining, the monoclonal antibody against the C5b-9 neoantigen showed no reactivity whatsoever subepithelially or within the lamina propria in any of the groups (d, e, f).

C3 AND C5b-9 NEOANTIGEN STAINING WITHIN BRUNNER'S GLANDS

Results for C3 staining within the Brunner's glands are shown in Figure 2. It can be seen that C3 is present in each of the three groups and the intensity of staining follows the pattern found within the lamina propria; most intense in the untreated coeliac group, intermediate in the treated coeliac group, and least intense in the control group.

Examination of staining by the monoclonal antibody to the neoantigen of the C5b-9 complex revealed a distinct and unique selectivity for the glands of Brunner in coeliac patients (Fig. 3 and

Table 3 C5b-9 neoantigen staining within Brunner's gland

Group	Staining		
	Negative	Positive	
		Weak	Strong
Disease controls (n=13)	10	2*	1†
Combined coeliac patients (n=10)	0	5	4
Untreated coeliac patients (n=5)	0	2	3
Treated coeliac patients (n=5)	0	4	1‡

*Patients 8 and 13, Table 2; †Patient 6, Table 2; ‡Patient 1, Table 2.

Table 3). In all 10 biopsies from coeliac patients neoantigen was detected within the glands. The intensity of staining varied and was assigned as being either strong (Fig. 3a) or weak (Fig. 3b). The extent of staining was also variable, though in each case between one third and two thirds of all lobules of the gland were affected. Of the 12 disease controls examined three had evidence of complement activation, one staining strongly (patient no 6, Table 2) and two weakly (patients 8 and 13, Table 2).

Using the polyclonal antisera to the complement neoantigens on a limited number of samples, identical findings to those for the monoclonal antibody were obtained (results not shown).

Discussion

The two major findings of this report are that (i) there is no activation of complement within either the epithelial or lamina propria compartments of the coeliac small intestine and (ii) complement activation, exquisitely restricted to the glands of Brunner, is detectable in coeliac patients.

The involvement of complement in the disease process was proposed a number of years ago on the basis of immunohistochemical staining showing C3 deposition in conjunction with IgA (5), IgA plus IgG (7), or IgM (6). In all of these studies the suggested mechanism was complement activation secondary to immune complex deposition in the basement membrane zone and lamina propria. IgA, the most frequently reported isotype in the immune complexes, was said to activate complement via the alternate pathway. IgA, however, has only been found capable of complement activation under very artificial conditions, such as chemical or interfacial aggregation of human myeloma IgA^{18,19} while naturally occurring IgA immune complexes and cross linked IgA oligomers are incapable of complement activation either *in vivo* or *in vitro*.²⁰ An alternative explanation for the immunohistochemical findings in

coeliac disease is that greater non-specific extravasation and retention of C3, along with other serum proteins, is occurring. This is the case in other heavily inflamed tissue with exudation and oedema, such as in Crohn's disease, where considerably increased quantities of serum proteins have been shown to accumulate extravascularly.²¹

In this study we have repeated C3 staining in the coeliac lamina propria and obtained results consistent with previous studies, namely that there is a quantitative increase in the amount of C3 within the coeliac lamina propria. Resolution of the question of whether or not this complement is activated was made possible by the development of monoclonal and polyclonal antibodies against neoantigens present only on the activated C5b-9 complement complex. Using such reagents we have shown that no complement activation occurs either subepithelially or within the lamina propria in the coeliac mucosa despite the larger increase in concentration of C3. This strongly suggests that complement activation plays no part in the disease process at these sites and accumulates by non-specific mechanisms.

Complement activation was, however, detectable at a different site in coeliac biopsies: all 10 patients examined had deposition of the C5b-9 complex within the glands of Brunner. In contrast, complement activation at this site was found in only three of 12 disease controls.

Brunner's glands are located in the submucosa of the duodenum, being most numerous in the proximal portion. Interestingly, the mucosal abnormalities of coeliac disease are also most marked in the proximal duodenum.²² Brunner's glands have been shown to secrete mucus, bicarbonate and epidermal growth factor (EGF), agents which are important in mucosal defence and repair processes.²³ Thus complement-mediated attack on these glands may seriously compromise mucosal defence by interfering with secretion of these factors. This possibility is currently under investigation.

Deposition of the terminal complement complex occurs within Brunner's gland, not only in untreated coeliac patients but also in patients on long term gluten free diet in whom marked clinical and histological improvement has been noted. This suggests that continuing complement activation occurs in spite of strict adherence to gluten free diet. An alternative explanation is that the complement was deposited while the patients were still on gluten containing diet. This is very unlikely as the half life of terminal complement complexes on the surface of nucleated cells is measured in minutes.^{24,25}

At present there is no obvious explanation for the finding of complement activation in three of the controls with no apparent duodenal abnormalities. In

two of these staining was very faint but in the third it was strong.

The pathway by which the complement is activated within the Brunner's glands remains to be elucidated. Possible mechanisms include (i) entrapment of immune complexes within the gland with subsequent activation of the classical pathway, (ii) deposition of a complement activating autoantibody, and (iii) alternate pathway activation. Immune complexes have been described in the circulation of patients with coeliac disease, including those on gluten free diet, and in the majority of cases they can fix complement.⁴ Sequestration of these complexes within the Brunner's glands is therefore potentially important to the disease process. Unfortunately, at present, there is no information on the antibody or antigenic component of these complexes. An alternative explanation, that an autoantibody directed against an antigen on Brunner's gland is responsible for complement activation, is currently under investigation. Such an antibody would raise the possibility that coeliac disease, in common with many other HLA DR3-associated diseases, is initiated by a tissue specific autoimmune attack. Whatever the mechanism we are left with the intriguing possibility that damage to Brunner's gland leading to loss of mucosal defence and repair capability is an important factor in the development of gluten sensitive enteropathy.

The gift of monoclonal antibody 3B1 from Dr Sucharit Bhakdi, University of Giessen, FRG, is gratefully acknowledged. Thanks also to Dr Alex Whelan for stimulating discussion and to Drs D Nunes, V Pippet, and K Trimble for biopsy material. SN was funded by the Health Research Board of Ireland. RBG is a Wellcome Trust lecturer.

References

- Baklein K, Braentzig P, Fausa O. Immunoglobulins in jejunal mucosa and serum from patients with adult coeliac disease. *Scand J Gastroenterol* 1977; **12**: 149-59.
- Scott H, Ek J, Baklein K, Braentzig P. Immunoglobulin-producing cells in jejunal mucosa of children with coeliac disease on a gluten-free diet and after gluten challenge. *Scand J Gastroenterol* 1980; **15**: 81-8.
- Scott BB, Goodall A, Stephenson P, Jenkins D. Small intestinal plasma cells in coeliac disease. *Gut* 1984; **25**: 41-6.
- Mohammed J, Holborrow EJ, Fry L, Thompson BR, Hoffbrand AV, Stewart JS. Multiple immune complexes and hypocomplementaemia in dermatitis herpetiformis and coeliac disease. *Lancet* 1976; **ii**: 487-90.
- Shiner M, Ballard J. Antigen-antibody reactions in jejunal mucosa in childhood coeliac disease after gluten challenge. *Lancet* 1972; **i**: 1202.
- Doe WF, Henry K, Booth CC. Complement activation in coeliac disease. In: Hekkens WThJM, Pena AS, eds. *Coeliac disease*. Leiden: 1980: 189.
- Scott BB, Scott DG, Losowsky MS. Jejunal mucosal immunoglobulins and complement in untreated coeliac disease. *J Pathol* 1976; **121**: 219-3.
- Ferguson A, Murray D. Quantitation of intra-epithelial lymphocytes in human jejunum. *Gut* 1971; **12**: 988-94.
- Marsh MN. Abnormal behaviour of epithelial lymphocytes in sprue. *Gastroenterology* 1980; **78**: 1218.
- Kelly J, O'Farrelly C, O'Mahony C, Weir DG, Feighery C. Immunoperoxidase demonstration of the cellular composition of the normal and coeliac small bowel. *Clin Exp Immunol* 1987; **68**: 177-88.
- Marsh MN, Hinde J. Inflammatory component of celiac sprue mucosa. I. Mast cells, basophils and eosinophils. *Gastroenterology* 1985; **89**: 92-101.
- Wingren U, Hallert C, Norrby K, Enerback L. Histamine and mucosal mast cells in gluten enteropathy. *Agents Actions* 1986; **18**: 266-8.
- Hugo F, Jenne D, Bhakdi S. Monoclonal antibodies to neoantigens of the C5b-9 complex of human complement. *Biosci Rep* 1985; **5**: 649.
- Schafer H, Mathey D, Hugo F, Bhakdi S. Deposition of the terminal C5b-9 complex in infarcted areas of human myocardium. *J Immunol* 1986; **137**: 1945-9.
- Kelly J, Whelan CA, Weir DG, Feighery C. Removal of endogenous peroxidase activity from cryostat sections of immunoperoxidase visualisation of monoclonal antibodies. *J Immunol Meth* 1987; **96**: 127-32.
- Cordell JL, Felini B, Erbes WN, et al. Immunoenzymatic labeling of monoclonal antibodies using immune complexes of alkaline phosphatase and monoclonal anti-alkaline phosphatase (APAAP complexes). *J Histochem Cytochem* 1984; **32**: 219.
- Bhakdi S, Mihly M, Roth M. Isolation of specific antibodies to complement components. *Methods Enzymol* 1983; **93**: 409.
- Gotze O, Muller-Eberhard HJ. The C3-activator system: an alternative pathway of complement activation. *J Exp Med* 1971; **134**: 905.
- Boakle J, Pruitt KM, Mesteskey J. The interactions of human complement with interfacially aggregated preparations of human secretory IgA. *Immunochemistry* 1974; **11**: 543.
- Imai H, Chen A, Wyatt RJ, Rifai A. Lack of complement activation by human IgA immune complexes. *Clin Exp Immunol* 1988; **73**: 479-83.
- Baklein K, Braentzig P. Immunohistochemical localization of complement in intestinal mucosa. *Lancet* 1974; **ii**: 1087-8.
- Thompson H. Pathology of coeliac disease. In: Morson BC, ed. *Current topics in pathology-pathology of the gastrointestinal tract*. Berlin: Springer-Verlag, 1985: 49-75.
- Shorrock CJ, Rees WDW. Overview of gastroduodenal mucosal protection. *Am J Med* 1988; **84** (suppl 2A): 25-34.
- Ramm LE, Whitlow MB, Koski CL, Shin ML, Mayer MM. Elimination of complement channels from the plasma membrane of U937, a nucleated mammalian cell

- line: temperature dependence of the elimination rate. *J Immunol* 1983; **131**: 1411-5.
- 25 Carney DF, Koski CL, Shin ML. Elimination of terminal complement intermediates from the plasma membrane of nucleated cells: the rate of disappearance differs for cells carrying C5b-7 or C5b-8 or a mixture of C5b-8 with a limited number of C5b-9. *J Immunol* 1985; **134**: 1804-9.