

## SHORT REPORTS

### Disturbance of sensation after mastectomy

Clinicians may dismiss disturbance of sensation after mastectomy in the follow up of patients with breast cancer, but symptoms such as numbness of the upper arm and phantom breast are a common cause of anxiety for these women,<sup>1</sup> who have often received inadequate preoperative counselling.<sup>2</sup> We have therefore studied the nature and prevalence of postmastectomy symptoms and their relation to disease staging.

#### Patients, methods, and results

Eighty two patients (age range 33-97) who had undergone unilateral simple mastectomy and axillary node sampling with a single transverse incision were interviewed by either RD or CWO during attendance at a general surgical follow up clinic. A form was completed for each patient, which recorded age, date of mastectomy, disease stage at interview (Manchester classification), postoperative radiotherapy, and whether cancer had recurred. Local recurrence was diagnosed histologically, but chest radiology and skeletal scintigraphy were performed at the clinician's discretion. Patients were designated "symptomatic" if they admitted to experiencing phantom sensations of the breast or nipple (phantom symptoms) or pain and altered sensation around the mastectomy scar, chest wall, or ipsilateral arm (non-phantom symptoms). Patients denying these specific symptoms were grouped as "asymptomatic." Results were analysed with Student's *t* test.

The 54 (66%) patients who were symptomatic were younger than the 28 asymptomatic patients (mean age (SD) 58.5 (11.6) *v* 64.1 (13.7)), but this difference was not statistically significant ( $t=1.93$ ;  $p<0.1$ ). The interval between mastectomy and interview was similar in both groups (symptomatic 2.5 (2.1) years; asymptomatic 2.7 (2.3) years). Twenty five patients had experienced phantom sensation, which was related to the breast in 12 patients, the nipple in two patients, and both the breast and nipple in 11 patients. Phantom breast pain was described by only six patients. Numbness or pain of the medial aspect of the upper arm was described by 19 patients, and pain or irritation around the scar was described by five. Symptoms also included shoulder pain (one patient) and chest pain (two patients). There was no significant difference in the mean age of patients who described phantom (58.2 (11.3)) and non-phantom (58.8 (11.9)) symptoms, but the percentage of those with phantom symptoms decreased with increasing age at mastectomy (43% of patients aged less than 50, compared with 16% of patients aged over 69). There was no difference in the distribution of symptomatic and non-symptomatic patients according to disease stage (see table).

*Distribution of symptomatic and non-symptomatic postmastectomy patients according to disease stage at interview*

Groups	No of patients	Disease stage							
		I		II		III		IV	
		No	(%)	No	(%)	No	(%)	No	(%)
Symptomatic	54	39	72	12	22	0		3	6
Phantom	13	10	77	2	15	0		1	8
Non-phantom	29	20	69	8	28	0		1	4
Both	12	10	83	2	17	0		0	
Asymptomatic	28	20	71	7	25	1	3.6	0	

#### Comment

Mastectomy is associated with undoubted morbidity, which includes not only the complications of surgery but also the common psychological sequelae to this disfiguring operation. In addition, we have found that over 60% of patients described symptoms which arose from disturbed somatic sensation. Non-phantom symptoms were described by half the patients and consisted predominantly of pain or numbness of the upper arm. Sensory disturbances in the arm after mastectomy probably result from damage to the intercostobrachial nerve, although the carpal tunnel syndrome and brachial plexus entrapment have been reported in association with lymphoedema.<sup>3</sup> Half of the patients had experienced phantom breast sensations, which were rarely painful and affected the entire breast more often than the nipple alone. Phantoms occurred more commonly in younger patients, and previous studies have shown that they occur typically in premenopausal women who have adjusted poorly to mastectomy and who often have an underlying psychological disturbance.<sup>1,4</sup> We found no evidence to suggest that either phantom or non-phantom symptoms occurred more com-

monly in advanced disease, although a systematic search for occult dissemination was not undertaken in every patient.

These common symptoms, particularly phantoms, may cause considerable anxiety for patients, who rarely mention them to their medical attendants.<sup>1</sup> It would seem advisable to include their description in the preoperative counselling of women undergoing mastectomy, who should be reassured that they do not indicate a late stage of the disease.

<sup>1</sup> Jamison K, Wellisch DK, Katz RL, Pasnau RO. Phantom breast syndrome. *Arch Surg* 1979;114:93-5.

<sup>2</sup> Feeley TM, Peel ALG, Devlin HB. Mastectomy and its consequences. *Br Med J* 1982;284:1246.

<sup>3</sup> Ganel A, Engel J, Sela M, Brookes M. Nerve entrapment associated with post-mastectomy lymphedema. *Cancer* 1979;44:2254-9.

<sup>4</sup> Weinstein S, Vetter RJ, Sersen EA. Phantoms following breast amputation. *Neuropsychol* 1970;8:185-97.

(Accepted 28 February 1984)

Department of Surgery, Worcester Royal Infirmary, Worcester WR5 1HN

R DOWNING, BSC, FRCS, registrar

C W O WINDSOR, CHM, FRCS, consultant

Correspondence to: Mr C W O Windsor.

### Asthma inhalation devices: what do we know?

The correct technique for using aerosols has recently received critical appraisal<sup>1</sup> and there are now several devices less prone to errors of technique. Correct instruction is often emphasised<sup>1,2</sup> and is valuable,<sup>3</sup> but there have only been two studies of the competence of staff to teach.<sup>4,5</sup>

#### Subjects, methods, and results

Twenty three doctors and 20 nurses from the medical and paediatric departments of two local hospitals were questioned. The doctors were of senior house officer grade or above and included all six consultants. Nineteen local general practitioners from six practices were also questioned. They were asked to demonstrate the use of an aerosol inhaler, a Spinhaler, and a Rotahaler. For each device the demonstrator scored one mark if some medication would be delivered by the method he showed and a second for showing refinements of technique. Thus the extra mark was awarded for the inhaler for shaking the aerosol before use and breath holding after use; for the Spinhaler if some indication was given of the force of inspiration needed; and for the Rotahaler for loading with the device vertical to ensure that the powder entered the clear portion of the capsule and rotation with the device horizontal to avoid spillage. Thus a maximum of six points were available. The doctors were then asked about the degree of instruction given—for example, verbal instruction only or a full demonstration.

The general practitioners scored significantly better than all the other groups except the paediatric nurses ( $p<0.05$  with Student's *t* test) (see table). The general practitioners also taught and checked technique more often ( $p<0.05$  using the  $\chi^2$  test), whereas the hospital doctors were more inclined to delegate. Twenty doctors (of whom only three were general practitioners) sometimes delegated tuition to other staff, usually to nurses. Senior hospital doctors also delegated to their juniors, and six doctors mentioned physiotherapists (though the local physiotherapists do not see teaching of aerosol technique as one of their roles). Five general practitioners claimed that they always checked technique and eight usually, whereas no hospital doctors claimed that they always checked technique and only eight stated that they usually did so.

#### Comment

Most striking was the poor level of scoring. Even with the aerosol inhaler only 36% of the doctors and 30% of the nurses remembered two important refinements. These figures correspond well with Frew and MacFarlane's figures of 28% and 22%, respectively.<sup>5</sup> With few exceptions those who scored two marks with the aerosol also scored well with the Rotahaler and the Spinhaler. Eight people

Scores achieved by each group with each device

	No	Rotahaler			Aerosol			Spinhaler			Mean total score (max 6)
		No scoring:		Mean score	No scoring:		Mean score	No scoring:		Mean score	
		1 pt	2nd pt		1 pt	2nd pt		1 pt	2nd pt		
Paediatricians	10	3	0	0.30	9	4	1.3	3	2	0.50	2.10
Physicians	13	4	0	0.31	12	2	1.08	6	2	0.62	2.00
General practitioners	19	11	0	0.58	19	9	1.47	14	5	1.00	3.05
Paediatric nurses	10	6	0	0.6	10	3	1.30	7	2	0.90	2.90
Medical nurses	10	2	0	0.2	10	3	1.30	2	1	0.30	1.80
	62	26	0	0.42	60	21	1.31	32	12	0.71	2.44

The numbers shown for those scoring one point include those who also scored the additional, second, point.

scored the top mark of five out of six: four were general practitioners and only one was a nurse (from the medical department). The paediatric nurses' scores were relatively high but they scored relatively few marks on refinements of technique.

Nobody appreciated that any powder remaining in the opaque portion of the Rotacap does not emerge however hard the patient inhales. Although the instruction leaflet depicts loading the device with the mouthpiece down it does not say why and 62% of those who could load the device kept it horizontal throughout, expecting spillage.

Delegation may sometimes be appropriate, but it was usually done without awareness of the competence of the delegate to teach. The general practitioners may have been more familiar with the devices because they had less opportunity to delegate. Follow up is usually performed by doctors and we will continue to be given clues by patients that their technique is poor. We must be competent enough ourselves to pick up these clues. Unless we handle and talk about these devices regularly with patients who use them day in and day out we will not remain familiar with the host of possible errors.

<sup>1</sup> Newman SP. The correct use of inhalers. In: Clark TJH, ed. *The correct use of inhaled steroids in asthma*. Auckland: Adis Press, 1983.

<sup>2</sup> Crompton GK. Problems patients have using pressurised aerosols. *Eur J Respir Dis* 1982;63 (suppl):101.

<sup>3</sup> Self TH, Brooks JB, Lieberman P, Ryan MR. The value of demonstration and role of the pharmacist in teaching the correct use of pressurised bronchodilators. *Can Med Assoc J* 1983;128:129-31.

<sup>4</sup> Kelling JS, Strohl KP, Smith RI, Altose MD. Physician knowledge in the use of canister nebulisers. *Chest* 1983;4:612-4.

<sup>5</sup> Frew AJ, MacFarlane JTM. Are medical staff any better at using inhalers than their patients? *Proceedings of the British Thoracic Society* 1982; 37:780.

(Accepted 16 February 1984)

#### Bourne End, Buckinghamshire

A J BURTON, MB, DCH, general practitioner trainee

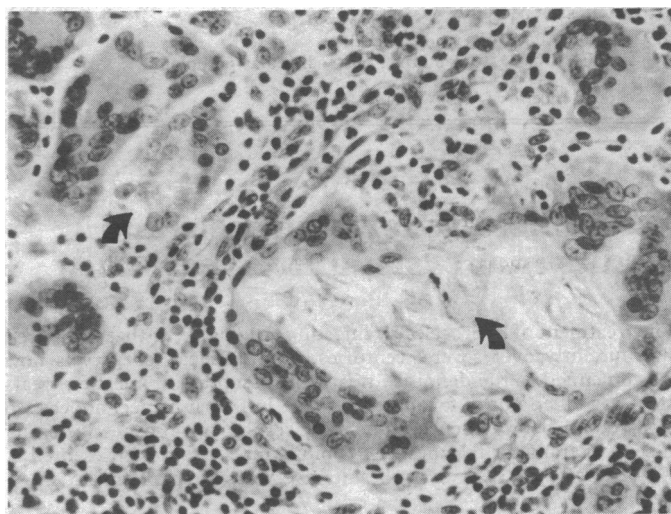
Correspondence to: 8 Ralph's Retreat, Hazlemere, Nr High Wycombe, Bucks.

## Aerosol antiperspirants and axillary granulomata

Preparations containing aluminium or zirconium, such as vaccines, cosmetics, and antiperspirants, produce occasional inflammation and granulomas. Both the patients described here developed chronic axillary granulomas after using an underarm deodorant spray containing aluminium.

### Case reports

**Case 1**—A 20 year old woman, previously healthy except for well controlled epilepsy, complained of recurrent painful swellings in both axillae. These had been treated with occasional courses of antibiotics, but the response had been unsatisfactory. On examination she had a tender lump about 2 cm in diameter in the left axilla. The diseased skin was widely excised along with extensive underlying granulation tissue. When questioned at follow up the patient confirmed that she was in the habit of shaving her armpits and admitted using the antiperspirant preparation Arid Extra Dry underarm powder spray.



Case 1. Giant cells containing talc (arrowed). Haematoxylin and eosin  $\times 800$ .

**Case 2**—A healthy 31 year old woman presented with a painful subcutaneous nodule in the right axilla, surmounted by a small pigmented naevus. The lump was excised. The patient admitted using the same antiperspirant as the first patient, spraying it from close range after shaving her armpits.

In both cases light microscopic examination of the lesions showed a granulomatous response within the dermis and subcutaneous tissues. Examination with polarised light showed that giant cells contained doubly refractile crystals. Some of these cells, and others which did not contain crystals, stained positively for aluminium with solochrome azurine at pH 5. When examined by wavelength dispersive electron probe analysis the crystals were shown by their mineral content to be talc. The presence of aluminium in histiocytes and giant cells was confirmed.

### Comment

Granuloma formation in these two cases occurred in response to a mixture of talc and aluminium salts. Subcutaneous granuloma formation has been reported after injection of triple vaccine,<sup>1,2</sup> and x ray crystallography has shown that the agent responsible was the aluminium hydroxide adjuvant. Although recent work has refuted the traditional indictment of depilation and deodorants as a cause of hidradenitis suppurativa,<sup>3</sup> certain spray preparations may provide a jet injection of aluminium salts, a known cause of granulomas.<sup>4</sup>

The manufacturers of Arid Extra Dry describe its active constituent as talcum powder coated with aluminium trichloride. The latter hydrolyses to aluminium hydroxide in physiological conditions.

Savage has suggested that the presence of elemental aluminium within such lesions could be detected by electron probe analysis,<sup>2</sup> and this was possible in both of our cases.

Granulomas of the axillae have been reported in a German patient who used deodorants containing zirconium but did not shave.<sup>5</sup> Shaving the axillae is endemic among British women, as is the use of underarm deodorants. Entry of particles from the deodorant is probably facilitated by the mild abrasion of shaving, and the manufacturers of Arid Extra Dry state on the canister that the product should not be applied to broken, irritated, or sensitive skin, and should be discontinued if the skin becomes irritated or a rash develops. Our cases illustrate the possible consequences of using this type of pressurised powder antiperspirant, particularly if the manufacturer's instructions are not rigidly followed.