

Chronic campylobacter colitis and uveitis in patient with hypogammaglobulinaemia

Campylobacter jejuni and *coli* are recognised causes of enteritis, and self limiting diarrhoea is a common symptom.¹ Occasionally the disease resembles Crohn's disease and ulcerative colitis. Chronic infection occurs rarely but has been reported in children and patients with immunodeficiency.² We report on a patient with immunodeficiency with chronic diarrhoea in whom *C jejuni* was repeatedly isolated and acute anterior uveitis occurred.

Case report

The patient, a woman, had undergone splenectomy for thrombocytopenia at age 34. In 1974 hypogammaglobulinaemia was diagnosed and treated by gammaglobulin replacement. In 1976 she developed haemolytic anaemia, which was controlled with steroids and two short courses of vinca alkaloids. At that time she started complaining of watery diarrhoea four to six times a day, for which no microbiological cause was found but which improved whenever her steroid dose was increased to control the anaemia. By 1978 she was passing up to 15 watery motions a day, and stool cultures showed *C jejuni* sensitive to erythromycin and tetracycline. She was given erythromycin 500 mg four times a day for three weeks, with no effect on her symptoms or the stool cultures. Her haemolytic anaemia remitted in 1979, and the steroids were gradually withdrawn; her diarrhoea worsened simultaneously. In 1981 she had an episode of acute unilateral uveitis, which was treated with oral steroids, and again her diarrhoea improved.

She was later investigated in hospital several times. *C jejuni* was isolated from her stool on five occasions; two isolates were serotyped and shown to be identical. No giardia, cryptosporidia, or other pathogens were found, and electron microscopy of the stool showed no virus particles. A small-bowel enema was normal apart from the appearance of backwash ileitis. Colonoscopy showed diffuse colitis with multiple small ulcers. Histological examination of the mucosa showed mild inflammation with aphthoid ulceration, neutrophils, no plasma cells, and incipient crypt abscesses, which suggested an infectious cause. Total white cell count was $1660 \times 10^9/l$ (lymphocytes $700 \times 10^9/l$, eosinophils $200 \times 10^9/l$). The urinary concentration of indicans and faecal fat excretion were normal. A Schilling test showed abnormally low vitamin B₁₂ uptake, which was not altered by intrinsic factor. Culture of jejunal biopsy tissue showed moderate growth of commensal bacteria (10^5 organisms/g tissue), as is commonly found in patients with hypogammaglobulinaemia,³ and *C jejuni* (5×10^4 organisms/g tissue). Immunofluorescence techniques using rabbit antibody to *C jejuni* showed organisms on the surface of the colonic mucosa but no submucosal penetration.

She was treated with one 15 day course of tetracycline 500 mg four times daily, five courses of oral erythromycin with doses up to 500 mg four times daily for four weeks, and intravenous gammaglobulin (Sandoglobulin, Sandoz) 9.3 g fortnightly for two months, which did not clear the organism from her stool. On her last admission to hospital in 1982 her diarrhoea was worse and she had lost weight. She was given intravenous erythromycin 600 mg thrice daily for two weeks followed by 500 mg four times daily by mouth for two weeks. Within two days of the start of treatment her bowel frequency had fallen from six to two motions a day. Stool cultures were negative for *C jejuni* and she had no diarrhoea over nine months follow up.

Comment

This case is of interest because uveitis has not been reported in association with *C jejuni* colitis and is not a recognised complication of hypogammaglobulinaemia. Some clinical and radiological features in our patient such as her symptomatic response to steroids were consistent with Crohn's colitis, but the histological findings indicated an infectious cause.⁴ Despite her immunodeficiency and steroid treatment our patient had apparently harboured *C jejuni* infection for about six years without evidence of systemic spread, which confirms that the organism's pathogenicity is mediated by production of enterotoxin.⁵ We suggest that high dose intravenous erythromycin may be effective treatment for chronic watery diarrhoea in patients with hypogammaglobulinaemia.

We thank Dr J L Penner, department of medical microbiology, University of Toronto, for carrying out the serotyping.

¹ Butzler JP, Skirrow MB. *Campylobacter* enteritis. *Clin Gastroenterol* 1979;8:737-65.

² Ponka A, Tilvis R, Kosunen TU. Prolonged campylobacter gastroenteritis in a patient with hypogammaglobulinaemia. *Acta Med Scand* 1983;213:159-60.

³ Webster ADB. The gut and immunodeficiency disorders. *Clin Gastroenterol* 1976;5:323-40.

⁴ Price AB, Day DW. Pseudomembranous and infectious colitis. In: Anthony PP, MacSween RNM, eds. *Recent advances in histopathology*. Edinburgh: Churchill Livingstone, 1981;11:99-117.

⁵ Ruiz-Palacios GM, Torres J, Torres NI, Escamilla E, Ruiz-Palacios BR, Tamayo T. Cholera-like enterotoxin produced by *Campylobacter jejuni*. *Lancet* 1983;ii:250-3.

(Accepted 2 November 1983)

Clinical Research Centre, Harrow, Middlesex

A M L LEVER, BSC, MRCP, research registrar

J M DOLBY, PHD, senior scientist (microbiology)

A D B WEBSTER, FRCP, senior scientist and consultant physician

Northwick Park Hospital, Harrow, Middlesex

A B PRICE, FRCPATH, consultant histopathologist

Correspondence to: Dr A M L Lever, Division of Immunological Medicine, Clinical Research Centre, Watford Road, Harrow, Middlesex HA1 3UJ.

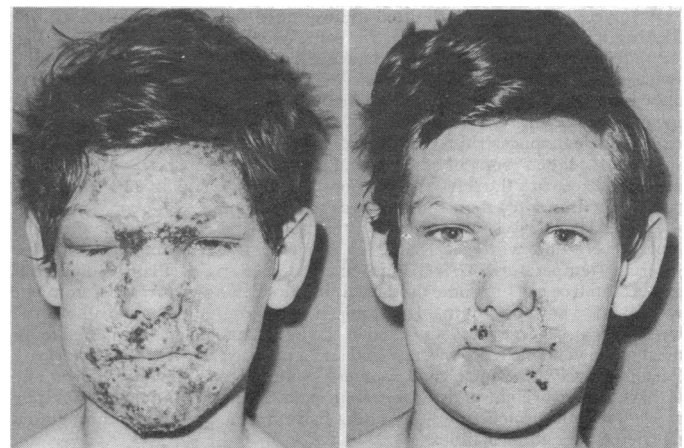
Oral acyclovir in eczema herpeticum

Eczema herpeticum is one type of Kaposi's varicelliform eruption. It usually affects patients with atopy who suffer from active eczema, but those whose eczema is in remission may also contract it. People with rare disorders such as pemphigus foliaceus or Darier's disease (keratosis follicularis) are also susceptible. The severity of the infection ranges from localised and mild to widespread and fatal. Patients may die of viraemia, organic complications, or massive secondary bacterial infection, although most recover.

The growth in public awareness of infection with *Herpesvirus hominis* and the increasing incidence of certain varieties of the infection¹ will lead to widened use of the antiherpetic drug acyclovir. I report on two children with eczema herpeticum who were treated with oral acyclovir.

Case reports

Case 1—An 11 year old Sikh boy with lifelong, severe atopic eczema and asthma was admitted to hospital acutely ill with fever, enlarged glands, and widespread impetiginised fissured plaques of eczema, which were most pronounced on his face, neck, and upper trunk. Blood cultures showed contamination with *Staphylococcus epidermidis*, and multiple skin swabs showed heavy growth of *S aureus* and β haemolytic streptococcus group G. He was treated with intramuscular erythromycin, potassium permanganate soaks, and sodium fusidate ointment. With this treatment the crusting slowly cleared and underlying groups of herpetic vesicles could be detected. Because of the degree of sepsis only a scanty quantity of vesicular fluid was obtained for viral culture, but this confirmed a diagnosis of herpes simplex infection. After 48 hours' observation the groups of vesicles seemed to be spreading and he was given oral acyclovir 100 mg every four hours five times daily for five days. This dose was equivalent to 25 mg/kg body weight/day. No



Case 2. Herpetic eruption before (left) and after (right) treatment with acyclovir.