

# Sphincteroplasty for Recurrent Pancreatitis \*

## A Second Report

S. AUSTIN JONES, M.D., LOUIS L. SMITH, M.D., GEORGE GREGORY, M.D.

Los Angeles, California

*From the Department of Surgery, College of Medical Evangelists and the  
Los Angeles County General Hospital, Los Angeles, California*

SPHINCTEROPLASTY, a procedure in which a wedge of the lower end of the common duct and duodenal wall is excised transduodenally, has been previously described by the authors in a preliminary report.<sup>8</sup> This procedure was originally intended to be a method of producing a more permanent and complete sphincterotomy, and its benefit was thought to be dependent primarily upon the presence of a common channel. This is not in accord with our present thinking. The common channel theory fails to explain many cases of pancreatitis. The constricting effect of the duodenal wall on the intramural portion of the common and pancreatic ducts was briefly mentioned in the preliminary report. We now consider this to be of prime importance as a mechanism which may produce pancreatic duct obstruction. Such an obstruction, if combined with stimulation of the gland to secrete, seems a more plausible explanation for the occurrence of pancreatitis in the majority of cases than does the common channel theory. This constricting effect of the duodenal wall musculature is not eliminated by sphincterotomy, as the advocates of this operation have demonstrated.

The object of this paper is to present a possible mechanism which can produce recurrent pancreatitis that to our knowledge has not been stressed in the past, to outline our current management and surgical technique and to report the first 28 cases of recur-

rent pancreatitis treated by transduodenal sphincteroplasty. The differences between sphincteroplasty and sphincterotomy will be stressed.

### Etiology

The most obvious proof that the cause of pancreatitis is obscure lies in the fact that so many explanations have been advanced. It is possible that the same factor is not responsible in each case, and that in certain instances more than one factor is at work. We have previously reviewed some of the concepts of etiology. More recently vascular disturbances and deficiency in protein utilization have been considered.<sup>7, 14</sup>

We have been very impressed with the work of Lium and Maddock in demonstrating that pancreatitis can be produced regularly in animals by a simultaneous obstruction of the pancreatic duct and stimulation of the gland.<sup>9</sup> Obstruction alone or stimulation alone will not produce the disease. The common channel theory which has many adherents fails to explain certain facts which appear well proven. In some cases pancreatitis develops there is not a common channel on autopsy examination.<sup>1</sup> Others show little or no evidence of bile regurgitation into the pancreatic ductal system. Pancreatitis has been reported in aberrant or ectopic pancreatic tissue.<sup>11</sup> Furthermore, the differential in secretory pressure between the pancreas on one hand, and the gallbladder and liver on the other, makes regurgitation difficult to explain. Experi-

---

\* Submitted for publication May 13, 1957.

mental production of pancreatitis by injection of bile into the pancreatic duct requires a higher than physiologic pressure to rupture the intrapancreatic ductal system and initiate the cycle.<sup>12</sup>

The pancreas can be stimulated through nervous and hormonal mechanisms. The ingestion of a heavy meal or alcohol will activate these physiologic functions. Obstruction of the pancreatic duct can occur from occlusion of the pancreatic duct itself or indirectly by obstruction of the common duct or ampulla of Vater below a common channel. *Intrapancreatic* ductal obstruction usually occurs from calculi within the gland, but neoplasm, ductal metaplasia, or postinflammatory fibrosis may produce the same result. *Extra pancreatic* ductal obstruction may occur from calculi, neoplasm, chronic fibrous constriction of the pancreatic duct, trauma, or acute inflammation. *However, these causes of extra pancreatic ductal obstruction are frequently not demonstrable in people with recurrent pancreatitis upon whom surgery or autopsy is performed.* Classically, an exacerbation of chronic relapsing pancreatitis follows a dietary or alcoholic indiscretion. The ingestion of a heavy meal or alcohol will explain stimulation of the gland, but, excluding intrapancreatic ductal obstruction, how can we account for the extra pancreatic ductal obstruction in the absence of one of the obvious causes listed above? Anatomic studies suggest one mechanism which may produce obstruction of the pancreatic duct outside of the gland, *a mechanism which would not be demonstrable at surgery or autopsy.*

Fifty dissections of the lower end of the common duct were done to determine the relationship of the duodenal muscle fibers to the pancreatic and common ducts and the anatomic arrangements of the ducts to each other. The common and pancreatic ducts run parallel in close juxtaposition and pass obliquely through the duodenal wall. The intramural course of the common duct

was found to average 11.12 mm. in length and that of the pancreatic duct 9.34 mm. A common channel with an average length of 6.58 mm. was found in 25 cases. In 24 cases the pancreatic duct entered the common duct just proximal to the ampulla of Vater, making obstruction by duodenitis with ampullary spasm and edema possible. In one case, the pancreatic duct entered the duodenum separately. In the 49 dissections where the pancreatic duct entered the common duct, the junction occurred on the posterior or medial wall of this structure.

In this oblique intramural course, the pancreatic and common ducts are surrounded by muscle fibers which are contiguous with those of the duodenal wall. Anatomically it appears that contraction of the duodenal musculature will cause compression of both common and pancreatic ducts (Fig. 1). It also appears that destruction of the fibers encircling the common duct in its intramural course will markedly disrupt the integrity of the contracting mechanism which surrounds the pancreatic duct, as the fibers running between the two ducts are small and few in number. We feel that the close anatomic relationship described justifies the assumption that pressure variations in the common and pancreatic ducts produced by duodenal wall constriction should parallel each other, and that any alteration of the musculature which results in a lower common duct pressure should be accompanied by a lower pancreatic duct pressure. Conversely, contraction of the normal duodenal wall should produce a rise in pressure in both the common and the pancreatic ducts. This could be confirmed most accurately by catheterizing the caudal portion of the main pancreatic duct and comparing pressures obtained with the duodenal wall relaxed with those recorded when the wall is in spasm. We have not utilized this method because of its potential hazards, but have studied common duct pressure changes with the duodenal wall in spasm and in a relaxed

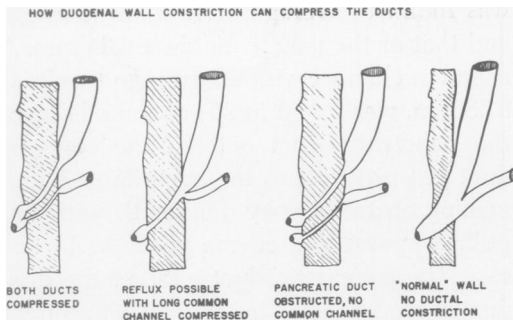


FIGURE 1

state, feeling, as stated, that the pancreatic duct pressures will parallel those in the common duct.

Constriction of the pancreatic duct by the duodenal wall would offer an explanation for the rise in blood amylase frequently observed after the administration of morphine as this drug produces contraction of intestinal musculature.<sup>2, 6</sup> A pancreatic duct obstruction, so produced, if combined with simultaneous stimulation of the gland, could initiate an exacerbation of pancreatitis with any cause of obstruction that would appear at surgery or autopsy. The same mechanism could produce pancreatitis in the absence of a common channel. The object of sphincteroplasty is, therefore, not only to destroy the sphincter function at the outlet of the common duct, but to destroy the constricting action of the duodenal wall muscle fibers on the pancreatic duct. Obviously this operation is of no benefit in the treatment of pancreatitis due to intrapancreatic ductal obstruction.

### Surgical Procedure

The abdomen is routinely explored, following which the hepatoduodenal ligament is incised and the common duct exposed and opened. A Bake's dilator is passed into the duodenum in order to locate the level of duodenostomy. Following the mobilization of the duodenum by the Kocher maneuver and downward displacement of the transverse colon, a longitudinal duodenostomy incision is made over the previously

placed probe in order to visualize the ampullary region. Babcock forceps are placed in a radial fashion in the periampullary mucosa and narrow Deaver retractors are used to expose the ampulla of Vater (Fig. 2). If visualization is difficult, the ampulla can be elevated into more direct view by placing the index finger of the operator's left hand behind the mobilized duodenum. A dilute solution of adrenalin can be injected into the region to be dissected in order to aid in hemostasis. The tip of the dilator previously passed through the ampulla of Vater is grasped by a Kocher forcep and retracted medially, and two mosquito forceps are placed to include the duodenal and common duct walls (Fig. 2). *Care must be taken to place these clamps as far laterally as possible to avoid injury to the pancreatic duct*, since, as previously stated in our dissections the duct entered medially or posteriorly in every instance. We believe that if this technic is followed the pancreatic duct will not be occluded or damaged. The wedge of tissue between the forceps is excised and interrupted sutures of 000000 arterial silk are placed approximating duodenal to common duct walls prior to the removal of the mosquito forceps. The two sutures at the apex are not cut but are used as retractors, while a second pair of mosquito forceps are placed so as to continue the upward excision of the wall of the duodenum and common duct (Fig. 4). Sutures are again placed prior to removal of the small clamps. Usually a minimum of four such applications of mosquito forceps are necessary to totally excise the constricting portion of the duodenal wall. The upper limit of the dissection can be determined by palpating behind the mobilized duodenum and locating the point of junction of the common duct with the duodenum. The resulting trough-like stoma averages 2 to 3 centimeters in length (Fig. 5). Special care must be taken to carefully approximate the duodenal and common duct walls at the upper portion of the trough to avoid any

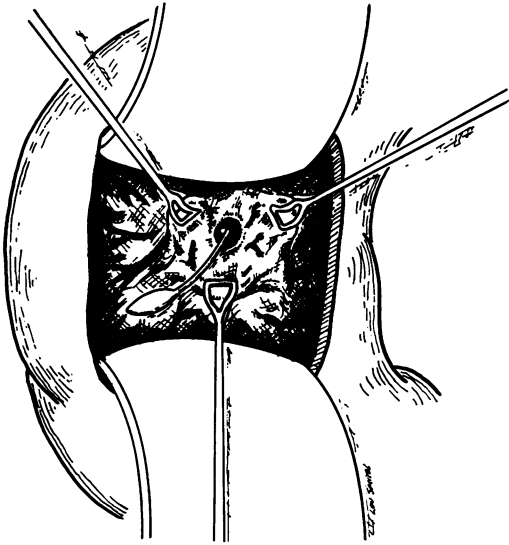


FIGURE 2

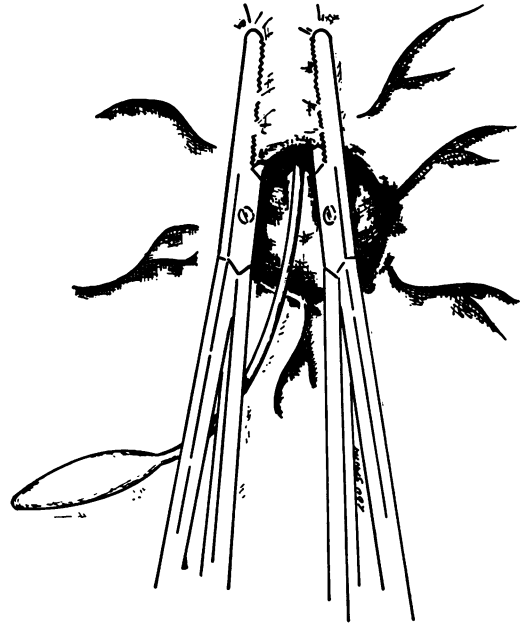


FIGURE 3

possibility of leakage of duodenal contents. The operation is demonstrated in cross section (Figs. 6-10), the level shown being 1 centimeter proximal to the ampulla of Vater.

Obviously the procedure described will be of no benefit in patients having intra-

pancreatic ductal obstruction. It is imperative that an operative pancreatogram be obtained to exclude this possibility. Consequently, it has been our policy to search for the pancreatic duct following the opening of the ampulla between the first pair of mosquito forceps. In most instances the

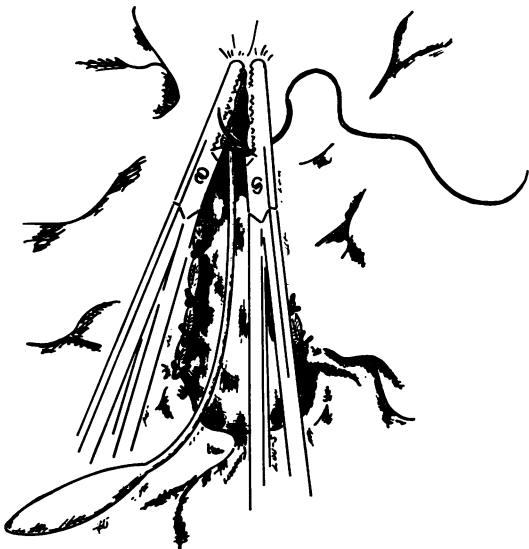

FIGURE 4

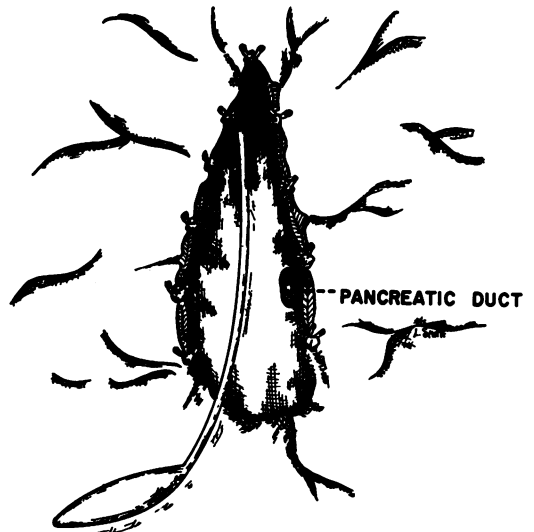


FIGURE 5

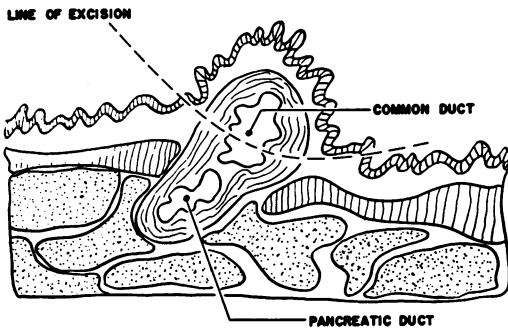


FIGURE 6

duct can be located by the presence of pancreatic secretion but in some cases intravenous secretin must be utilized. A small polyethylene catheter is inserted as far as possible into the pancreatic duct, 2 to 3 cc. of 50 per cent hypaque are injected into the catheter, and an x-ray obtained. If there is no evidence of intrapancreatic ductal obstruction, the operation is completed as described. Occasionally it has been possible to perform the same type of procedure on the pancreatic duct at its termination in addition to the routine sphincteroplasty described.

The duodenostomy opening is closed in a longitudinal direction using running 000 catgut sutures in the mucosa reinforced by an outer interrupted layer of 000 silk. A short limb T-tube is placed in the common duct. We do not advise the use of a long limb T-tube since obstruction of the pancreatic duct can occur with resulting pancreatitis.<sup>15</sup> The gallbladder is removed whether it is diseased or not as destruction of the sphincter function results in non-filling of this organ and as it no longer functions it seems wise to remove it. Morrison's pouch is drained through a stab wound in the flank and the abdomen closed in a routine fashion. The short limb T-tube is left in place seven to ten days at which time the postoperative studies to be described are obtained.

#### Postoperative Studies

Does this operation eliminate the constricting mechanism described, and does it differ from simple sphincterotomy? In an effort to answer these questions we have recorded postoperative common duct pres-

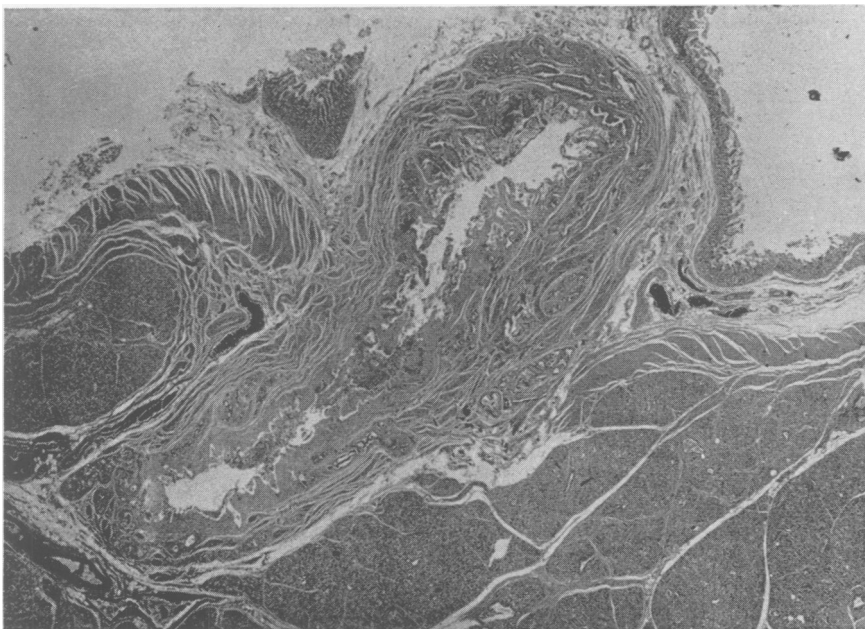


FIGURE 7

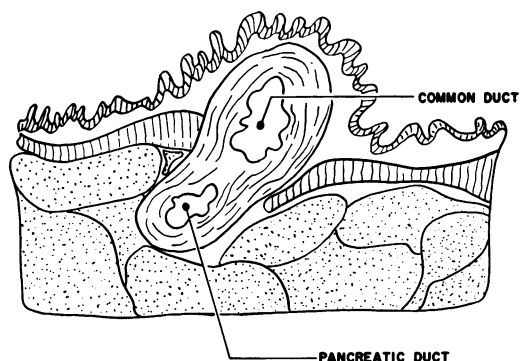


FIGURE 8

tures and taken postoperative cholangiograms before and after morphine sulfate administration. The ability of morphine sulfate to produce smooth muscle contraction is well known. These results will be compared with similar studies made on patients who have undergone sphincterotomy. We are indebted to Drs. Henry Doubilet and J. H. Mulholland for permitting us to reproduce some of their findings on the sphincterotomy group.<sup>3-4, 5, 13</sup>

### Common Duct Pressure Studies

On the eighth to tenth postoperative day, common duct pressures were recorded by a water manometer or an electronic recording device before and after the injection of intravenous morphine. The results are given in Figure 11. The common duct pressure following simple common duct exploration or common duct exploration combined with sphincterotomy rises slowly after the intravenous injection of morphine. A maximum pressure is reached in an average of 19 minutes and falls to the baseline pressure in 60 to 240 minutes. It will be noted that the rise in pressure is less following sphincterotomy than after simple common duct exploration. Following sphincteroplasty the pressure rises rapidly and irregularly, reaches a maximum in 9 minutes, and returns to the pre-injection baseline in 15 minutes. In this sphincteroplasty group, food particles or indigo carmine dye in-

stilled into the stomach by a Levin tube prior to the test were frequently noted to escape from the T-tube. This suggested that the fluctuation of pressure within the common duct following sphincteroplasty was due, at least in part, to the contractile peristaltic action of the duodenum with reflux of duodenal contents and that the rise in pressure was not necessarily due to any constriction of the lower end of the common duct.

The careful work of Doubilet and Mulholland has demonstrated that the response to morphine following sphincterotomy is limited to its action on duodenal musculature. It is their feeling that this preservation of the duodenal musculature surrounding the bile duct following sphincterotomy is desirable in preventing ascending cholangitis.<sup>3, 5</sup> Anatomically, the stimulation of this preserved duodenal musculature could produce constriction and, hence, obstruction of the pancreatic duct as well. If this obstruction were combined with stimulation, a recurrence of pancreatitis might develop. Therefore, we feel that this constricting mechanism should be eliminated. We do not believe that preservation of the duodenal musculature is necessary to prevent ascending cholangitis since in the absence of obstruction of the common duct this complication should not develop.<sup>16</sup> We have had no cholangitis in any of our cases, although postoperative upper gastro-intestinal films have shown a reflux of barium into the hepatic ducts in the majority of cases.

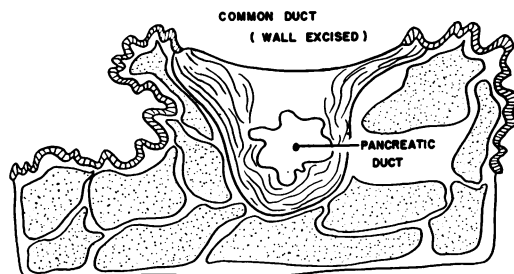


FIGURE 9

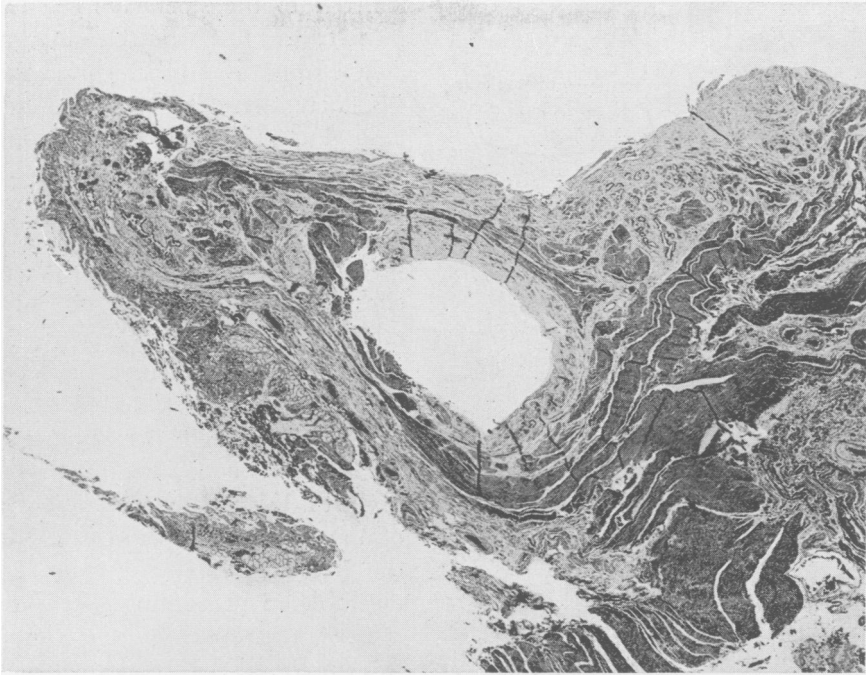


FIGURE 10

### Postoperative Cholangiographic Studies

Postoperative cholangiograms have been made before and after intravenous morphine sulfate on patients who have had sphincteroplasty. These films have been compared with those obtained by Doubilet and Mulholland in their postsphincterotomy group so studied. The x-rays demonstrate that morphine sulfate produces duodenal wall contraction with resultant obstruction of the common duct in the postsphincterotomy patient (Figs. 12 and 13). In the

sphincteroplasty group, the administration of morphine has not produced any reduction in the common duct lumen, the pre- and postmorphine films being essentially identical (Figs. 14 and 15).

These studies would indicate that sphincterotomy and sphincteroplasty differ in that following the latter procedure the constricting effect of the duodenal wall on the common duct has been functionally eliminated. Considering the anatomic evidence available, we believe that the common duct pressure changes described will be paralleled in some degree by pressure changes within the pancreatic duct.

### Case Reports

This report will cover the first 28 cases with recurrent pancreatitis treated by sphincteroplasty. The longest period of follow up is five years and the shortest four months. There were 17 males and 11 females in the group, the oldest being 81 years and the youngest being 27 years with

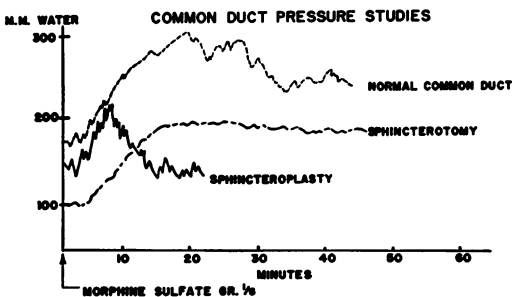


FIGURE 11

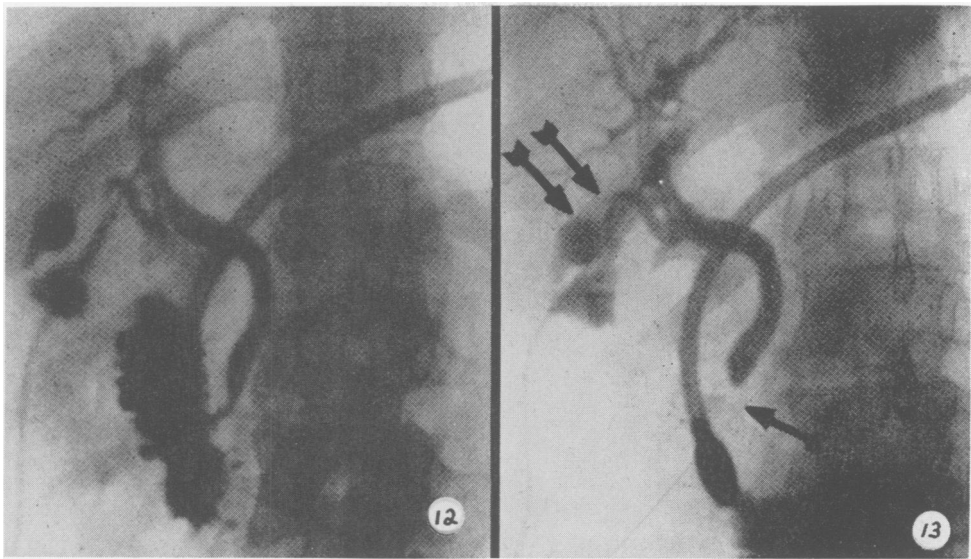


FIG. 12. Postsphincterotomy before morphine sulfate administration, showing normal narrowing of intramural portion of common duct.

FIG. 13. Postsphincterotomy patient after morphine sulfate, showing occlusion of the distal common duct lumen by constriction of the duodenal wall.

an average age of 42 years. The average number of hospital entries with proven pancreatitis was 3.1 or a total number of 88 entries for the group. On each of these entries, symptoms and findings included severe upper abdominal pain with typical radiation, nausea with vomiting, marked upper abdominal tenderness and shock in some instances. All cases demonstrated a significant elevation of amylase and urinary diastase levels. Acute attacks occurring at home or undocumented hospital entries were not included in this tabulation. Either cholelithiasis, malfunction of the gallbladder on dye study, or microscopic diagnosis of cholecystitis was found in 12 of the 28 patients. Sixteen of the cases were severe alcoholics, two drank moderately and ten denied the use of alcohol in any form. At operation every case showed evidence of pancreatic disease as indicated by enlargement of the gland, fibrosis and old or recent inflammation as indicated by peripancreatic adhesions, fat necrosis or calcinosis. Three patients had fibrous constriction at the lower end of the common duct. One patient

had Laennec's cirrhosis of the liver without portal hypertension, one had an old inactive duodenal ulcer and a third had normal ectopic pancreatic tissue located in the antral region of the stomach. The pancreas in this patient was enlarged and showed chronic inflammation with marked fibrosis.

Twenty-five of the 28 cases were adequately followed. The present status of these 25 cases will be discussed under the four headings given below.

#### 1. No Recurrence of Pancreatitis Postoperatively—19 Cases

Of this group, 13 patients are living and completely well. Eight patients were alcoholics prior to surgery and seven had associated gallbladder disease. Four continued heavy drinking following operation.

Three patients experienced no postoperative pancreatitis, but died due to other causes. They were followed for an average of 30 months following operation and all were severe alcoholics both before and following operation. None of the patients in this group had gallbladder disease. The



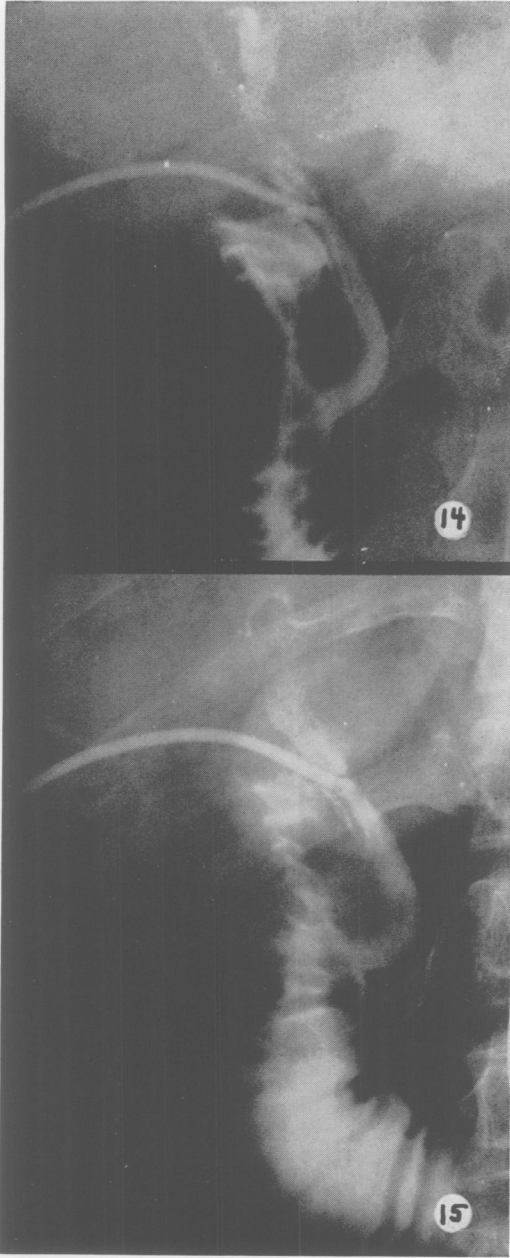


FIG. 14. Postsphincteroplasty before morphine sulfate.

FIG. 15. Postsphincteroplasty after morphine sulfate. Note that there is no reduction in the common duct lumen by duodenal wall constriction.

causes of death were alcoholic psychosis, cirrhosis and esophageal carcinoma. It is of interest to note that the patient who died of cirrhosis was a 40-year-old Caucasian male

who drank an average of a fifth of whiskey per day until he succumbed of advanced cirrhosis of the liver 28 months after surgery. Repeated examinations carried out during hospital entries for the treatment of delirium tremens and progressive cirrhosis with ascites failed to demonstrate any clinical or chemical evidence of pancreatitis. At autopsy the liver showed advanced portal cirrhosis with superimposed hepatitis. There was no evidence of recent pancreatitis and the sphincteroplasty site was widely patent.

A third group of cases have experienced no postoperative pancreatitis but have had abdominal symptoms due to other causes. There were three such patients all of whom were severe alcoholics prior to surgery. All of these patients have continued to drink following sphincteroplasty. One patient had associated gallbladder disease at operation. Abdominal symptoms in this group have been produced by a bleeding duodenal ulcer in one patient and severe alcoholic gastritis in the other two.

## 2. Solitary Attack of Pancreatitis Postoperatively—3 Cases

The average follow up on these patients was 18 months. Two patients have continued heavy drinking following surgery and two had chronic cholecystitis at surgery. One of these patients is a 34-year-old non-alcoholic woman who had a single episode of epigastric pain, nausea and vomiting 28 months postoperatively. Examination at this time showed moderate epigastric tenderness, amylase studies of 266 and 255 and a diastase of 1,600. Following this single episode she has remained well.

The second patient is a 48-year-old negro male, a chronic alcoholic with cholecystitis, cholelithiasis and diabetes mellitus in addition to his recurrent pancreatitis. Fifteen months following sphincteroplasty he experienced a solitary episode of abdominal pain radiating to the back and

associated with an amylase of 286 and a urinary diastase of 3520. In the seven months since this attack he has had no abdominal symptoms, feels very well, and has gained 14 pounds in weight. A third patient, a 35-year-old female alcoholic, experienced one episode of acute pancreatitis associated with a blood amylase of 300. This attack occurred seven months after sphincteroplasty and followed a two-week period of excessive alcoholic consumption. She has had no further abdominal symptoms.

### 3. More Than One Episode of Pancreatitis Postoperatively Patient Much Improved—Two Cases

These two patients, both severe alcoholics, have been followed for an average of 46 months since operation. They have had more than one episode of pancreatitis during this time, each attack occurring only after prolonged and excessive drinking. One of these patients, a 46-year-old Negro male, has gained ten pounds of weight since surgery, eats well and is completely asymptomatic except when he drinks. The second patient, a 30-year-old Negro male, has no abdominal symptoms except following excessive alcoholic ingestion.

### 4. More Than one Episode of Pancreatitis Postoperatively Patient Unimproved—One Case

One intractable alcoholic, a 49-year-old Negro male, has been followed 16 months and continues to have severe attacks, each one preceded by an alcoholic indiscretion. He did not have associated gallbladder disease. At the present time he has permanent residence at a local veteran's hospital. He states that he has been unimproved by the surgery.

### Discussion

The procedure we have described is designed to treat chronic relapsing pancreatitis caused by extra pancreatic ductal ob-

struction. Sphincteroplasty has also been used for the treatment of chronic fibrous constriction of the common duct, biliary dyskinesia and following common duct exploration where multiple small stones were lodged in the hepatic ducts out of certain reach. In pancreatitis cases where the obstruction is in the pancreas *per se*, other approaches must be considered. We have utilized partial pancreatectomy successfully for segmental disease, pancreatico-duodenectomy for pancreatitis confined to the head, and caudal pancreatectomy with Roux en Y drainage as advocated by DuVal for disease localized in the tail. In the far advanced cases where the entire pancreatic architecture has been destroyed, total pancreatectomy as reported by Longmire should be considered.<sup>10</sup>

### Summary

1. Twenty-eight patients with proven chronic pancreatitis have been presented and their surgical therapy discussed. Obstruction plus stimulation of the gland to secrete seems important in the etiology of the disease.

2. A type of extra pancreatic ductal obstruction caused by duodenal wall constriction has been considered. This obstruction cannot be demonstrated at surgery or autopsy.

3. Such an obstruction could be responsible for pancreatitis in a patient with no common channel and could explain amylase elevation after morphine administration. It might also account for pancreatitis occurring after unrelated surgery.

4. Pancreatic ductogram is utilized to determine the presence of intrapancreatic ductal obstruction. If no obstruction is demonstrated, sphincteroplasty, an operation devised to destroy the constricting effect of the duodenal wall musculature, is performed.

5. Sphincteroplasty has been compared with simple sphincterotomy using common duct pressures and cholangiograms before

and after the administration of intravenous morphine. These studies show a definite physiologic difference in the two operations when common duct pressures are compared.

6. Anatomically it appears that common duct pressure changes produced by alterations in duodenal wall tonus should be paralleled by pancreatic duct pressure variations.

7. When pancreatic ductogram demonstrates intrapancreatic ductal obstruction, caudal pancreatectomy with retrograde drainage is advised.

8. In patients with segmental involvement, local resection of the diseased portion of the gland is recommended. In far advanced diseases where the normal architecture of the gland has been destroyed, total pancreatectomy, as advocated by Doctor Longmire, should be considered.

9. Of the total group followed postoperatively 76 per cent have experienced no further attacks of pancreatitis and 93 per cent have been improved by the surgical program outlined.

### Bibliography

1. Aird, I.: *A Companion in Surgical Studies*. Baltimore, Maryland, Williams and Wilkins, Publisher, 837, 1950.
2. Bennett, I. C. and R. O. Burgess: *Acute Morphine Poisoning with Manifestations of Pancreatitis*. *J. A. M. A.*, 148:930, 1952.
3. Doubilet, H. and J. H. Mulholland: *Etiology and Treatment of Pancreatitis*. *N. Y. State J. Med.*, 49:2938, 1949.
4. Doubilet, H. and J. H. Mulholland: *Recurrent Acute Pancreatitis: Observations on Etiology and Surgical Treatment*. *Ann. Surg.*, 128:609, 1948.
5. Doubilet, H. and J. H. Mulholland: *Surgical Treatment of Calcification of the Pancreas*. *Ann. Surg.*, 132:876, 1950.
6. Gross, J. B., M. W. Comfort, D. R. Mathieson and M. H. Power: *Elevated Values for Serum Amylase and Lypase Following the Administration of Opiates: A Preliminary Report*. *Proc. Staff Meeting Mayo Cl.*, 26:81, 1951.
7. Ivy, A. C. and G. E. Gibbs: *Pancreatitis: A Review*. *Surgery*, 31:614, 1952.
8. Jones, S. A. and L. L. Smith: *Transduodenal Sphincteroplasty for Recurrent Pancreatitis*. *Ann. Surg.*, 136:937, 1952.
9. Luim, R. and S. Maddock: *Etiology of Acute Pancreatitis*. *Surgery*, 24:593, 1948.
10. Longmire, W. P., P. H. Jordan and J. D. Briggs: *Experience with Resection of the Pancreas in the Treatment of Chronic Relapsing Pancreatitis*. *Ann. Surg.*, 144:681, 1956.
11. Longmire, W. P. and M. A. Walner: *Pancreatitis Occurring in Heterotopic Pancreatic Tissue*. *Surgery*, 40:412, 1956.
12. Mann, A. C. and A. S. Giordano: *The Bile Factor in Pancreatitis*. *Arch. Surg.*, 6:1, 1923.
13. Mulholland, J. H.: *Personal Communication*.
14. Radakovich, M., H. Pearse and W. Strain: *Study of the Etiology of Acute Pancreatitis*. *Surg., Gynec. & Obst.*, 94:749, 1952.
15. Smith, S. W., W. F. Barker and L. W. Kaplan: *Acute Pancreatitis Following Transampullary Biliary Drainage*. *Surgery*, 30:695, 1951.
16. Walters, W. and J. Cameron: *Studies of Biliary Strictures and Their Surgical Treatment in 184 Patients*. *Proc. Staff Meeting Mayo Cl.*, 25:150, 1950.