

# An Evaluation of Biopsy-Frozen Section of the Ampullary Region and Pancreas:

## A Report of 68 Consecutive Patients \*

HARLAN J. SPJUT, M.D., AUGUSTO J. RAMOS, M.D.\*\*

St. Louis, Missouri

*From the Department of Surgical Pathology of the Washington University School of Medicine and Barnes Hospital*

HOW VALUABLE is a biopsy with frozen section in determining the nature of lesions of the ampullary region and pancreas? Are the complications of biopsy of the pancreas inevitable? One is soon enveloped in clouds of gloom when justification for biopsy of the ampullary region and pancreas is sought in the literature. To either confirm or dispel this feeling by seeking the answer to the two questions proposed, 68 patients with biopsy-frozen section at Barnes Hospital were reviewed. This paper concerns only those biopsies upon which a frozen section was done at time of abdominal exploration.

Several authors have condemned pancreatic biopsy; few have supported its value. Shackelford<sup>17</sup> believes that pancreatic biopsy is important in distinguishing benign and malignant pancreatic lesions but feels that frozen sections of the pancreas are "notoriously difficult to interpret correctly." In 1951, Cattell and Warren<sup>7</sup> stated that it was the consensus of opinion that biopsies of the pancreas are "generally futile and are not worth the risks involved." Bowden<sup>5</sup> has stated that "even when successfully accomplished, biopsy is often non-informative or frankly erroneous." Maingot<sup>14</sup> believes that it is not "justifiable to remove a portion of the hardened gland

(pancreas) for microscopic investigation" because of difficulty encountered in suturing the biopsy wound and danger of implantation of malignant cells in cases of cancer. He does suggest, however, the use of needle biopsy in the diagnosis of pancreatic lesions. Most recently Dennis and Varco<sup>9</sup> have observed that biopsy at time of exploration for lesions of the ampulla and pancreatic head had not been helpful. They stated that the surgeon could not "fruitfully delegate" to the pathologist the decision of whether or not to resect a lesion. Whipple<sup>19</sup> has said that he had "been unable to get valuable information from biopsies in doubtful cases. A negative biopsy does not mean that the radical procedure should not be undertaken." One group of authors, Probst and associates,<sup>15</sup> furnish cases to illustrate to some degree the difficulty of pancreatic biopsies. Of 28 biopsies of masses in the head of the pancreas, 18 were negative for cancer. Subsequently 11 of the 18 were proved to have cancer. The authors feel, however, that pancreatic biopsy should not be considered useless, as occasionally the biopsy demonstrated cancer. No frozen sections were done in their series.

Few, indeed, are those who support biopsy of pancreatic or ampullary lesions. Ackerman and Wheat<sup>2</sup> (Barnes Hospital) feel that a biopsy of a lesion in these two regions is imperative before radical surgery. The danger of implantation of neoplastic

\* Submitted for publication April 15, 1957.

\*\* Present address: Department of Pathology, Santo Tomas University School of Medicine, Manila, Philippine Islands.

cells is ever-present; one such case is cited. Elman<sup>18</sup> (Barnes Hospital) states that biopsy with frozen section "is mandatory when faced with a mass in the head of the pancreas." This statement was made in comment on a case in which a frozen section diagnosis of carcinoma had been successfully accomplished from a needle biopsy of the head of the pancreas.

It seems important that when one is dealing with a lesion as deadly as carcinoma of the pancreas or of the ampullary region which is being treated by a surgical procedure that carries an operative mortality that has been reported as 14 per cent, 25 per cent, 33 per cent, and 45 per cent,<sup>3, 5, 6, 8</sup> every means available should be used in order to arrive at a definitive diagnosis prior to the radical resection. At present the best method would appear to be biopsy of the diseased area. Frozen section, if accurate, can be an important complement of the biopsy in terms of immediate knowledge and time saved.

#### Presentation of Data

The 68 patients with biopsy and frozen section represent consecutive cases from the surgical pathology files of Barnes Hospital. They were done from July 1948 through 1955. During this interval one pathologist, Lauren V. Ackerman, M.D., supervised the frozen section procedure while the resident in surgical pathology was directly responsible for the frozen section. Prior to 1948, very few frozen sections were attempted on lesions from the area under discussion.

Among the 68 patients were 49 with neoplasm and 19 with a non-neoplastic disease. The neoplasms included 39 carcinomas and three islet cell adenomas of the pancreas, six carcinomas of the ampulla and one carcinoma of the common duct (Figs. 1 and 2). The non-neoplastic lesions consisted of chronic inflammation and fibrosis of the pancreas, pseudocysts of the pancreas, two abscesses of the body of the pan-

creas, and a benign proliferative lesion of the ampullary epithelium. Thirty-three of the cancer patients and 11 of the non-neoplastic cases were men; women constituted 16 and eight of the cases respectively. The immediate accuracy of the frozen section process was approximately 91 per cent (six errors in 68 cases). All of the errors occurred in the cancer group and in each instance represented an under-diagnosis of the lesion. One counted as an error was thought to be cancer but could not be definitely diagnosed as such. No benign lesions were diagnosed as malignant. Every frozen section was followed up with a permanent paraffin section of the block of tissue used for the frozen section. Seventeen radical resections were carried out for cancer on the basis of frozen section confirmation of surgical findings of a neoplasm. Two resections were done for carcinoma in cases listed as frozen section errors (Table I).

Reluctance to biopsy of the pancreas is founded on the complications encountered during the operation and in the postoperative course. Troublesome bleeding, fear of precipitating acute pancreatitis, pancreatic fistulae, and possible implantation of tumor<sup>10</sup> are cited as reasons given for avoiding pancreatic biopsy when possible. From our group of 68 patients three had complications attributable to the biopsy. Two patients in whom complications occurred did not have neoplasms; the third had carcinoma of the head of the pancreas. Review of the operative notes on all of the patients failed to mention undue bleeding from the biopsy site. Pancreatitis, as far as the postoperative clinical records were concerned, was not encountered. Two of the complications were pancreatic abscesses and one a fistula. These appeared 30, eight and 14 days after biopsy respectively. One implant of carcinoma following resection occurred: eight months after radical resection of an invasive carcinoma of the ampulla of Vater in a 79-year-old woman, a nodule appeared in the skin of the abdo-

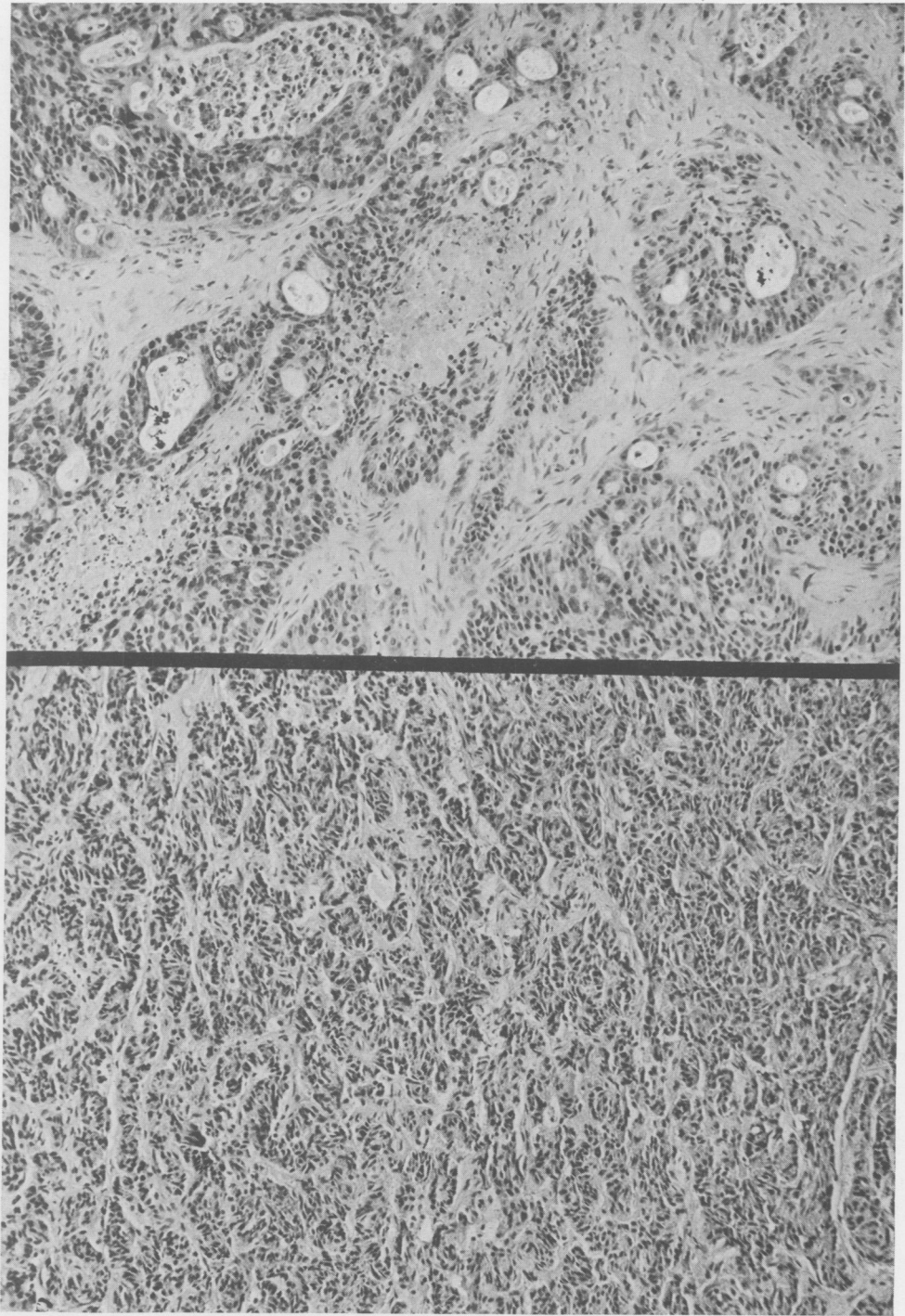


FIG. 1. (Above) A permanent section of the frozen section biopsy block from the ampulla of Vater showing the adenocarcinoma interpreted as such by frozen section. H-E. 150  $\times$ .

FIG. 2. (Below) A permanent section of the frozen section biopsy block from a tumor of the head of the pancreas diagnosed as islet cell adenoma. The patient was a 40-year-old woman with intermittent attacks of hypoglycemia. The resected specimen contained 14 separate adenomas. H-E. 150  $\times$ .

TABLE I. *Compilation of Results*

| Cases        |          | Total No. Biopsies |          | Errors       |          | Complications |          |
|--------------|----------|--------------------|----------|--------------|----------|---------------|----------|
| 68           |          | 124                |          | 6*           |          | 3             |          |
| Non-Neoplasm | Neoplasm | Non-Neoplasm       | Neoplasm | Non-Neoplasm | Neoplasm | Non-Neoplasm  | Neoplasm |
| 49           | 19       | 91                 | 33       | 6            | 0        | 1             | 2        |

\* All false negative reports.

men. It was near the surgical scar. This was histologically diagnosed as carcinoma. Suture granulomas were seen adjacent to tumor (Fig. 3). The patient is living and apparently free from disease 34 months (February 1957) after resection of the primary tumor. Thus, in our group of patients (not counting the 19 who had resections) the incidence of complications of biopsy was 6.1 per cent (three of 49 cases).

### Discussion

Any examination is only as good as the reliability of the results. The over-all accuracy of frozen sections at Barnes Hospital approximates 98 per cent.<sup>1</sup> That for the group of pancreatic biopsies is 91 per cent, a respectable figure. For the surgeon this degree of dependability may be transformed into therapeutic decisions and peace of mind. This is of great importance

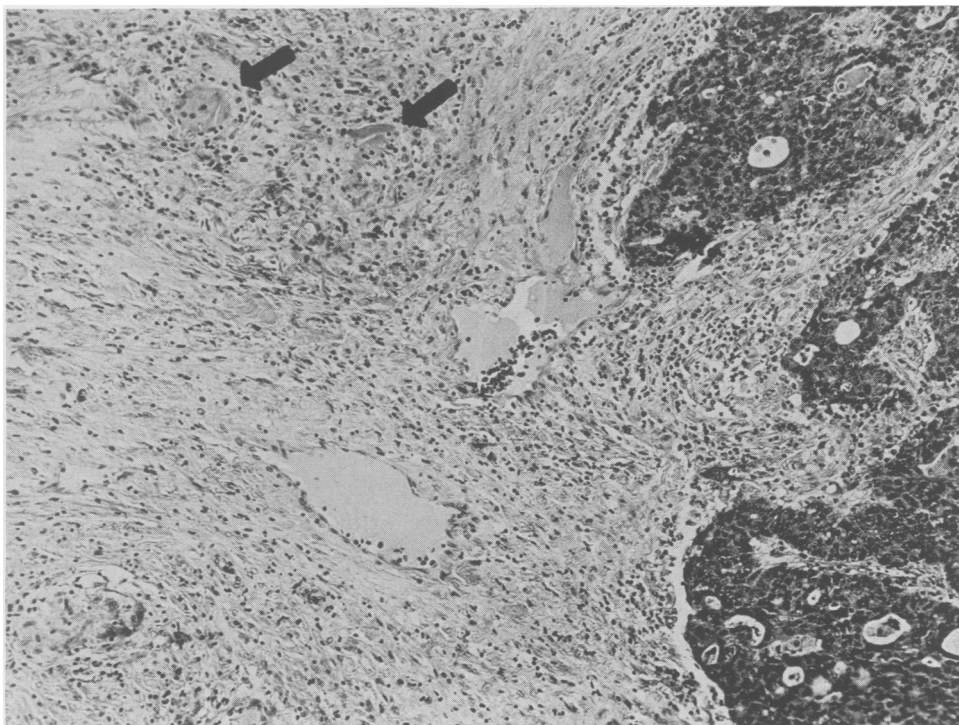


FIG. 3. Illustrates the implanted carcinoma in the abdominal wall. (Same patient as Fig. 1.) Foreign body granulomas are observed. The arrows indicate suture fragments; one fragment is within a multinucleated giant cell. H-E. 135 X.

when one considers that even in highly experienced hands<sup>6</sup> radical resections have been done with resultant mortality for benign lesions with a diagnosis based upon gross impression of cancer.

Despite the numerical success of the procedure, frozen section interpretation of pancreatic and biliary tract tissue is not easy. The pathologist's uncertainty or dissatisfaction with a given specimen is reflected in the fact that from the 68 cases, 124 biopsies were submitted with request for frozen section examination. As many as six separate biopsies with frozen section have been done on one case, before satisfactory interpretation could be made. It must be stated that on occasion false negative diagnoses have been made in cases in which more than one biopsy was received. The ultimate diagnosis was correct, but intervening biopsies were incorrectly interpreted as shown by permanent section. Herein lie two drawbacks to biopsies of the pancreas and biliary tract: (1) prolongation of the operative procedure, and (2) difficulty of interpretation of pancreatic lesions. The former would seem to be a risk that must be assumed by the patient and surgeon for purposes of accurate diagnosis to form an intelligent basis for therapy. This is particularly true with cancer, a deadly disease that might possibly be controlled by a procedure carrying a high mortality and high morbidity. Bartley<sup>4</sup> reports serious complication in over 50 per cent of patients surviving resection. The deadliness of carcinoma of this area is indicated by the few cases, 26, of five-year survivals after pancreaticoduodenectomy gleaned from the literature by Dennis and Varco.<sup>9</sup> The cases included carcinoma of the head of the pancreas, ampulla and duodenum and one islet cell tumor. Repeat biopsies until satisfactory diagnosis is obtained seem indicated. This position has been advocated by Puestow.<sup>16</sup>

Concerning interpretation, much depends on the surgeon; does he obtain the speci-

men from the correct area? Two frozen sections were done in one of our patients, one from the head and one from the body of the pancreas. These were diagnosed as being chronic inflammation and confirmed so on permanent section. Re-exploration of the abdomen two months later revealed a mass in the body of the pancreas and metastatic carcinoma in the liver. In a second and similar case, two frozen sections (body and head of pancreas) were done, neither of which demonstrated carcinoma. A biopsy of the head of the pancreas done just before closing (frozen section not requested) did reveal carcinoma. A third case had carcinoma of the ampulla at autopsy. Two biopsies and frozen sections of the head of the pancreas had been made; the ampulla was not biopsied. For deep-seated lesions of the pancreas needle biopsy may prove successful.<sup>11</sup> We have accomplished frozen sections and accurate interpretation on three needle biopsies submitted to us.

Three of our errors (with adequate tissue) were made in the face of extensive fibrosis and chronic inflammation associated with the carcinoma of the pancreas (Fig. 4). One error was made on a carcinoma with abundant mucin production; no carcinoma could be seen with the frozen section but was readily apparent with the permanent section (Fig. 5). The fifth error was made in the failure to recognize an islet cell adenoma from the body of the pancreas. Fibrosis, chronic inflammation, fat necrosis, duct proliferation, accessory pancreatic ducts<sup>12</sup> and epithelial proliferation contribute to the difficulty of pancreatic biopsies but do not detract from their value.

Of importance in the evaluation of pancreatic biopsies is the follow up information on those patients with a "no cancer" diagnosis. Seventeen of our 19 patients have such follow up information. Two of the 17 subsequently proved to have carcinoma (reported in first part of discussion).

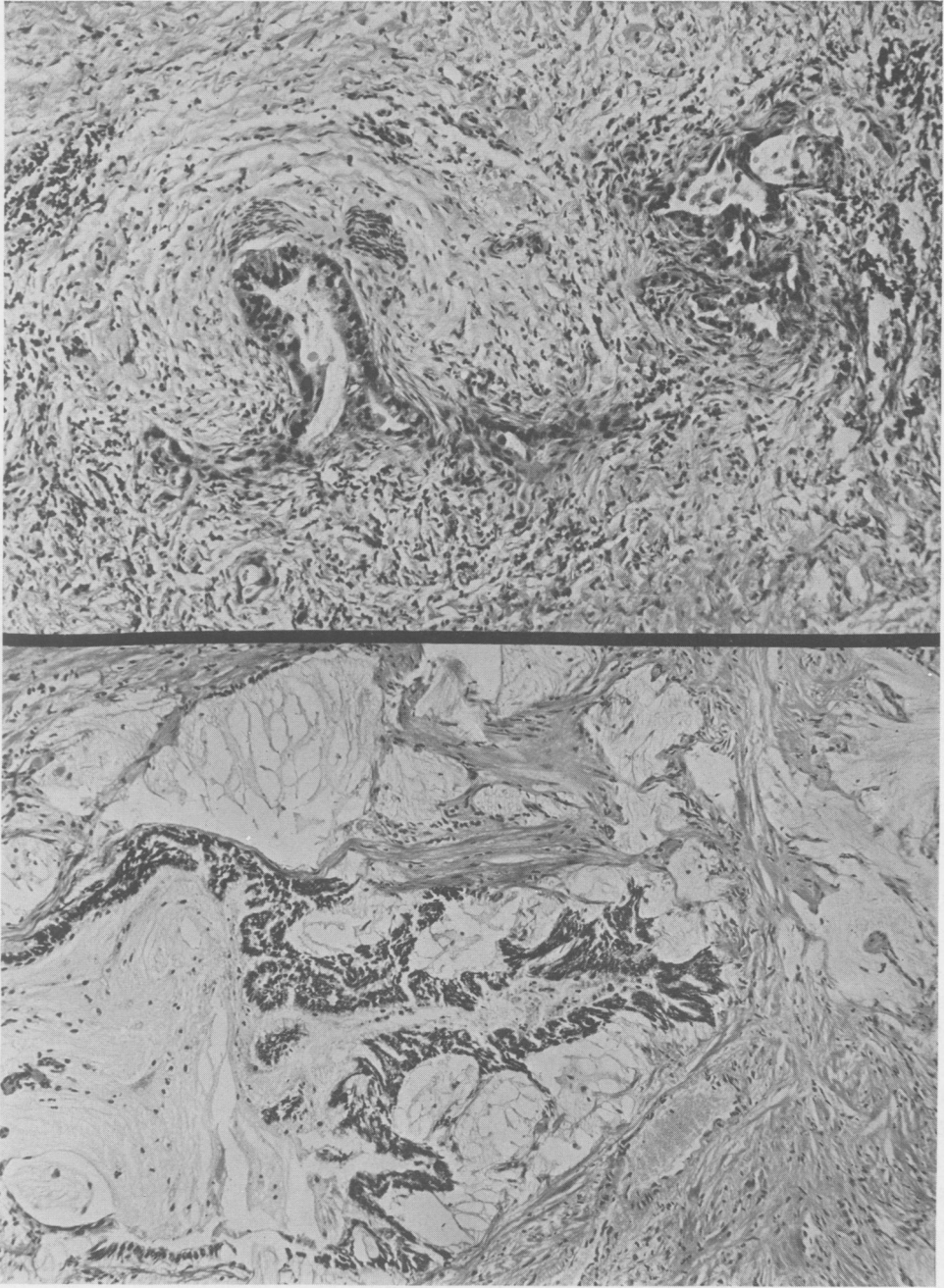


FIG. 4. (Above) A permanent section of a frozen section biopsy block from the head of the pancreas mistakenly diagnosed as "fibrosis and no cancer" because of the extensive fibrosis and the sparsely scattered neoplastic glands. Illustrated are neoplastic glands and fibrosis. H-E. 150 X.

FIG. 5. (Below) A permanent section of a frozen section biopsy block from the head of the pancreas mistakenly diagnosed "no cancer." The large quantity of mucin and the scant epithelial component made frozen section interpretation difficult. Here one observes a mucin producing adenocarcinoma. H-E. 150 X.

The follow up information includes autopsies, re-explorations and letters from patients or their physicians. The shortest period of follow up was three months in a patient clinically a typical acute pancreatitis. All others have been followed for a year or more. Of the two lost to follow up, one is likely a carcinoma of the head of the pancreas as at abdominal exploration the gallbladder and common duct were greatly dilated associated with a mass in the head of the pancreas. The second patient by abdominal exploration had normal viscera except for an atrophic pancreas. Evidence of neoplasm was not seen. In all, then, there are three patients with a "no cancer" diagnosis who actually did have carcinoma. This approximates 16 per cent.

Complications of the method of biopsy are, of course, important. As far as could be determined, death did not directly result from a complication among our three patients. One patient, a 76-year-old man, died 11 days following drainage of a pancreatic cyst; it had appeared one month following biopsy. At autopsy no residual of the cyst was noted, only focal fat necrosis. Widespread carcinoma primary in the head of the pancreas was demonstrated. Each of the other patients recovered from their complications. Our experience with a low percentage of complications is not unique. Lukens and Dyer<sup>18</sup> reported only two pancreatic fistulae among 68 patients on whom pancreatic biopsy had been carried out.

The hazard of implantation of tumor has been discussed. Of perhaps equal importance in successful control of the disease is manipulation of cancer-bearing tissues. Willis<sup>20</sup> found after careful review of the literature that ambitious manipulation or massage of tumors was instrumental in their dissemination. On the other hand, careful incisional biopsies did not increase the chance of metastases from a given tumor. These observations are mentioned as additional information to be considered

in the decision for or against biopsy. To us the value received from biopsy of the pancreas and ampullary region far outweighs the disadvantages and the few complications.

### Summary

1. Sixty-eight patients having biopsies with frozen section of the pancreas and ampullary region are evaluated. Six errors in frozen section diagnosis were made.

2. The errors were in underdiagnosis of cancer. No false positive diagnoses were made.

3. Only three complications attributable to biopsy were encountered.

4. Three of the 19 patients with a "no cancer" diagnosis were subsequently shown to have carcinoma.

5. Biopsy with frozen section of the pancreas and ampullary region is considered to be an accurate, informative and reasonably safe procedure.

### Acknowledgments

The authors wish to express their appreciation to Dr. Lauren V. Ackerman of the Department of Surgical Pathology, and Drs. Myron W. Wheat, Jr., and Harvey R. Butcher, Jr., of the Department of Surgery for their helpful suggestions.

### Bibliography

1. Ackerman, L. V., G. A. Ramirez de Arellano and J. D. Keye, Jr.: (To be Published.)
2. Ackerman, L. V. and M. W. Wheat, Jr.: The Implantation of Cancer: An Avoidable Surgical Risk? *Surgery*, 37:341, 1955.
3. Bartlett, M. K.: The Status of Pancreaticoduodenal Resection. *Surg. Clin. N. Am.*, 27:1032, 1947.
4. Bartley, T.: Results of Radical Operation for Carcinoma of the Pancreas and Peri-ampullary Region Performed at Barnes Hospital. (To be Published.)
5. Bowden, L.: The Fallibility of Pancreatic Biopsy. *Ann. Surg.*, 139:403, 1954.
6. Cattell, R. B. and L. J. Pyrtek: An Appraisal of Pancreatoduodenal Resection: A Follow up Study of 61 Cases. *Ann. Surg.*, 129:840, 1949.

7. Cattell, R. B. and K. W. Warren: Pancreatic Surgery. *N. Eng. J. Med.*, 244:975, 1951.
8. Clifton, E. E.: Carcinoma of the Pancreas. *Arch. Surg.*, 65:290, 1952.
9. Dennis, C. and R. L. Varco: Survival for More than Five Years after Pancreatoduodenectomy for Cancers of the Ampulla and Pancreatic Head. *Surgery*, 39:92, 1956.
10. Harper, D. V.: The Diagnosis of Diseases of the Pancreas. *Surg. Clin. N. Am.*, 36:141, 1956.
11. Kirtland, H. B., Jr.: A Safe Method of Pancreatic Biopsy. *Am. J. Surg.*, 82:451, 1951.
12. Loquvam, G. S. and W. O. Russell: Accessory Pancreatic Ducts of the Major Duodenal Papilla. *Am. J. Clin. Path.*, 20:305, 1950.
13. Lukens, F. D. W. and W. W. Dyer: The Relation between Appearance and Behavior of the Islands of Langerhans in Man. *Am. J. Med. Sci.*, 231:313, 1956.
14. Maingot, Rodney: *Abdominal Operations*. 3rd Ed., Appleton-Century-Crofts, Inc., New York, 1955, pp. 632-633.
15. Probst, J. G., L. A. Sachar and W. Rindskopf: Biopsies of Pancreatic Masses. *Surgery*, 27:356, 1950.
16. Puestow, C. B.: *Surgery of the Biliary Tract Pancreas and Spleen*. Yearbook Publishers, Chicago, 1952, p. 350.
17. Shackelford, R. T.: *Surgery of the Alimentary Tract*. Vol. II, W. B. Saunders Co., Philadelphia, 1955, p. 943.
18. Thorpe, J. D. and R. Elman: Presentation of Case and Comment. *J. A. M. A.* 159:32, 1955.
19. Whipple, A. O.: In Discussion of M. Behrend and A. Behrend: Chronic Pancreatitis Causing Complete and Incomplete Obstruction of the Common Bile Duct. *Arch. Surg.*, 57:51, 1948.
20. Willis, R. A.: *The Spread of Tumors in the Human Body*. C. V. Mosby Co., St. Louis, 1952.

