

Pseudo Hirschsprung's Disease *

MARK M. RAVITCH, M.D.

From the Departments of Surgery of The Baltimore City Hospitals, The Johns Hopkins Hospital, and The Johns Hopkins University School of Medicine

THE DEVELOPMENT of a successful surgical treatment for Hirschsprung's disease¹¹ and the establishment of a sound pathologic and etiologic basis³ for the disease have been among the most gratifying events in Pediatric Surgery of the last decade. The result has been to render accurate diagnosis possible with precision. At the same time the knowledge that an effective surgical treatment is available has perhaps led to rather more frequent early surgical consultation in children with obstinate constipation.

In true Hirschsprung's disease, as Hirschsprung⁵ reported (in his original two cases, difficulty with defecation is noted from birth), there may be delay in the first passage of meconium. If a reliable history in the obstetric nursery is available, distention, constipation, and the necessity for enemas will be noted regularly. The condition persists or progresses. The children develop large protuberant abdomens. The costal margins flare. Fecal masses are regularly palpable in the abdomen. The children rarely have spontaneous stools and then only hard scybali. Flatus is passed annoyingly frequently, and in large amounts. A successful enema yields enormous quantities of stool followed for perhaps a day or two by inadequate evacuations and then obdurate constipation. Pain is not common. Distention may be so extreme, as in infants, to cause death from respiratory embarrass-

ment, with diaphragm so high that the diagnosis of eventration has been made. Repeated hospital admissions are required for crises of constipation. With assiduous home care and regular enemas such crises may be made infrequent but are rarely altogether eliminated. *Incontinence does not occur.* At times ulceration of the distended bowel—described and correctly interpreted by Hirschsprung as secondary to stasis and erosion by fecal masses—results in bloody diarrhea in the face of continued distention and palpable abdominal fecal masses. Ordinarily sphincter tone is normal, the rectal ampulla is empty, and not remarkable. The radiographic picture, clearly described by Neuhauser and Swenson,¹⁰ invariably demonstrates a normal sized or narrow rectal segment, and a dilated proximal sigmoid or descending colon. Hirschsprung, once more, plainly described at autopsy the normal sized or narrowed rectum, and the sharp transition to a huge sigmoid. If doubt remains as to the diagnosis, biopsy of the rectal wall will show an absence of the ganglion cells in the myenteric plexus.

We have encountered four types of patients referred for treatment of megacolon in whom the difficulty lay elsewhere than in the congenital absence of ganglion cells of the myenteric plexuses of a segment of the rectum or of the colon and rectum.

- 1) Pseudo Hirschsprung's disease on a psychogenic basis in otherwise organically normal children.
- 2) Megacolon and obstinate constipation in mentally defective children.
- 3) Megacolon and obstinate constipation associated with organic anal obstruction.

* Presented before the Southern Surgical Association, White Sulphur Springs, West Virginia, December 10-12, 1957.

4) Megacolon and obstinate constipation in congenital cretins.

Such confusion was perhaps inevitable before the advent of the modern understanding of Hirschsprung's disease and the grotesque errors in the older experience should not be repeated today, certainly with regard to groups 2 and 3. It remains distressing to see children of group 1 referred for consideration of operation—often with long histories of travel from pediatrician to pediatrician without accurate diagnosis and without the relief which is so readily available for their distressing condition. Group 4 represents a condition rarely reported.

1. Pseudo Hirschsprung's Disease on a Psychogenic Basis in Otherwise Normal Children

This is far commoner than the organic disease due to absence of the ganglion cells of the myenteric plexus. It is fleetingly referred to in some discussions, well discussed by Swenson,⁹ Stephens,³ and by Lee,⁷ among surgeons, and by Garrard *et al.*⁴ and by Bell *et al.*² among pediatricians. These patients are those still often classified as having "idiopathic megacolon." Lee's attack on this term is classic. Discussions of the therapy of this condition are rare. Lee has described an effective if rather ritualistic treatment for these children, and a quite different, but apparently effective regimen more psychiatrically oriented has been described by Bell and Levine. For the rest, the condition is either described as "extremely difficult to cure" or is totally neglected.

The patients characteristically present at ages of three to four years or thereafter. The history is usually clearly obtainable, of constipation beginning in the third or fourth year, or later. A vague initial statement that the child has "always" been constipated, will, on patient questioning concerning the history of the neonatal period

and infancy, be found inaccurate. On one occasion when the father who brought a child in gave this history, a long distance call to the mother brought a clear statement that the child had no difficulty with defecation during the first years. The pathognomonic giveaway—almost regularly occurring, and frequently forming the presenting complaint jointly with constipation—is fecal incontinence. Fecal incontinence never occurs in Hirschsprung's disease and its occurrence as a regular or recurring phenomenon eliminates the possibility of that diagnosis. In the group of children under discussion distention is moderate, as compared to the situation in Hirschsprung's disease, or entirely absent. Flatus is not conspicuous. Fecal masses, quite as large and hard as may be found in Hirschsprung's disease are also found in this condition. Abdominal pain is a common event. The peri-anal region is often found smeared with feces. The anus and sphincter are normal, and the rectal ampulla is filled with a mass of feces, often filling the pelvis. The most superficial questioning readily elicits rich evidence of tension, hostility, neurotic difficulties in parents and child. Oddly enough, while the mother is usually mortified by the encopresis, the child often appears to accept it calmly, matter-of-factly, without evidence of shame or agitation. This will obviously depend to some extent upon the degree to which the mother impresses her reaction upon the child and the degree to which the child has withdrawn into a shell. Quite often there is a sharp history of extremely early habit training. Some of these children "fought the pot" and successfully resisted such premature attempts. Others apparently surrendered gracefully and tractably and their subsequent relapse into repulsive delinquency is all the more harrowing and perplexing to the obsessive mothers who took such pride in their earlier triumphs. Huschka,⁶ who has been interested in the psychiatric as-

pects of this problem, states that the infant shows its awareness of the need to defecate by physical signs—grunting and wriggling—usually between the ages of eight and 15 months. She estimates that “training” can usually be completed by the ages of 18 months to two years. In a study of 213 disturbed children, as might be expected, she found a high incidence of coercive bowel training and evident response by the child to it. As coercives she mentions premature institution of training methods (infants can actually be taught a sort of reflex continence at two to three months), rigidity of schedule, unduly frequent placement on the toilet, employment of shame as punishment for failure, psychologic pressure by placing a “high love premium” on success, strapping the child to a seat until success is achieved, use of suppositories for stimulation, forcing a child to “speak up” and announce his wants when he is just learning to talk, etc. Threats, bribes, punishment are obvious coercive methods. The primary problem of the children in her study was not constipation or encopresis, yet in a group of 30 with adequate history of the use of coercive methods in whom the reaction could be reliably elicited, 21 had responded by constipation, loose stools, rage, incontinence, obsession with excessive cleanliness, etc. This type of response is natural and understandable. The encopresis may vary from regular overflow soiling of the clothes when the child is finally unable to restrain defecation, through regular and complete evacuation into the clothes at long intervals, to bizarre habits of defecation about the house. It has been noted that many of these children defecate when standing—evidence perhaps of an unyielding wish to avoid defecation. It has been said⁴ that the encopresis represents failure of inhibition of defecation. At times it has seemed apparent to us and presumably to the children at some level of consciousness that encopresis represented as effective a

weapon against authority as did constipation.

Roentgenograms show a large redundant atonic colon which may well mimic Hirschsprung's disease in regard to size and to quantity of retained stool. Proper studies will show the dilatation to involve the rectum and reach the anal canal. The narrowed segment of Hirschsprung's disease is never seen. The diagnosis can be made on history alone as demonstrated by the following cases. In some cases the reason for fixing attention on the bowel are obvious, in others less so.

Case Report

Case 1. A 5½-year-old white boy with progressive constipation from the seventh month. He had had no difficulty up to that time, sat up at 5½ months, walked at 12 months. Habit training was begun at 5½ months and was said to be difficult because the child would sit indefinitely. He began to rebel against sitting on the toilet, crying, struggling, etc. The constipation was progressive until he could go five to seven days without a stool. On the fifth or sixth day he might vomit. He rarely complained of pain. Abdominal distention was never marked. Fecal impaction required manual disimpaction about once in six months. No treatment had been given, the mother waiting until he had a stool “and he usually does”—with manual assistance from her, if necessary. The child had always been hard to feed. A cardiac murmur was discovered at the age of four weeks and led to proscription of much normal physical activity. At the time of examination the child was deliberately and repeatedly hysterical, screaming or complaining in rapid succession of hunger, abdominal pain, etc. He cried, jumped about, beat his face with his hands, pulled at his mother. He could be made to calm down by a show of quiet firmness and with his mother out of the room was completely tractable. The abdomen was not protuberant, there was a fist sized freely movable fecal mass in the right upper quadrant and several smaller, very hard masses, throughout the abdomen. Rectal examination showed good sphincter tone and a capacious ampulla filled with feces. Barium enema showed a voluminous redundant colon which evacuated poorly.

The mother was extremely obsessive. It was obvious from her account that every minute of the child's life had been planned and sharply ob-

served, that perfection had been expected of him and absolute regularity of performance in all respects.

The home situation seemed so difficult that the child was admitted to the hospital. Enemas were given twice daily for one week, productive each time of large amounts of soft brown stool. At the end of this week the enemas were stopped and the child continued to have one or two large movements per day, without any difficulty at all. He stayed in the hospital for two more weeks, having normal and regular bowel movements.

In this instance an obsessive mother smothered her child with care, perhaps because of his cardiac murmur, and premature attempts at bowel habit training focussed the child's rebellion in that direction.

Obviously the relief obtained by therapy was no more than symptomatic relief. The fundamental problem would probably require prolonged psychotherapy of the mother. However, both the mother and child were convinced that the child could have daily bowel movements without any continued treatment.

Case 2. This 10-year-old boy was said to have been habit trained with no difficulty, and neither late nor early. In 1955, a week after a poliomyelitis vaccine injection he complained of pain in the leg and it was feared he had developed poliomyelitis. The following week he developed intractable "diarrhea." He lost 17 pounds and was constantly incontinent, wearing rubber pants even during the daytime and at times having 10 or more watery stools in 24 hours. After about a year the "diarrhea" ceased, but, although the stools were thick and pasty, he remained incontinent. A series of extensive medical studies were begun in another city and the barium enema showed a tremendously dilated colon which was interpreted as Hirschsprung's disease. A biopsy of the rectal musculature was undertaken and was reported as showing normal "nerves." An enema regimen was begun 6 weeks before we saw him. The boy fought the enemas violently and became intractably constipated. At the same time his incontinence disappeared. His constipation was so severe that when he was first seen it was actually a week since his last bowel movement. During all the time of his diarrhea and incontinence and constipation he continued going to school. On examination, the abdomen was distended and contained numerous large fecal masses. Rectal examination showed a

firm sphincter tone and an ampulla filled with a great hard fecal mass down to the sphincter.

The history of incontinence, the fact that the bowel habit disturbance did not appear until he was 8 years old, the presence of a fecal mass down to the sphincter, x-rays which showed a tremendously dilated colon down to the anal canal, pretty well eliminated the possibility of true Hirschsprung's disease. It seemed fairly obvious that the difficulty started during a time when the family was intensely concerned that the boy had acquired poliomyelitis from his injection of Salk vaccine.

The situation was presented in precisely these terms to the family and the boy at the same time, they were told firmly that he did not have Hirschsprung's disease and that normal habit would be restored. He was placed on the therapeutic regimen which will be described below. In the course of the next 3 months he began to go for progressively longer periods, 6 days, 9 days, 19 days, without requiring an enema, having daily stools in the interval. Incontinence had not returned. It is interesting that the mother kept a defecation chart, although she had not been requested to, and that she was reluctant to part with the chart for inclusion with his hospital record until she could make a copy. He has now had a daily bowel movement for over 3 months without an enema.

In this instance, without a psychiatric investigation, no obvious factors are found to explain why a sudden fear of poliomyelitis in the patient at the age of eight caused incontinence and constipation. The diagnosis of Hirschsprung's disease had been made elsewhere but not confirmed by rectal biopsy. The mother was travelling about for definitive diagnosis and treatment. Response to treatment was prompt and satisfactory.

Case 3. This was a 6½-year-old boy who had been born one of two premature fraternal twins. His twin was larger, more athletic, more aggressive. The patient was smaller, less well co-ordinated, had a marked squint and required glasses. The patient had been born with a thin membrane over his anus which was opened by a surgeon. Since childhood the patient had had trouble with defecation and numerous remedies had been tried. Repeated x-rays had shown an enormous colon. The boy was able to go a week or more without a stool. At times he had abdominal pain, and rarely he vomited. On the other hand he would at times go as long as 2 or 3 months without missing

a day's defecation. His underclothing was frequently heavily soiled. Interestingly enough the mother stated that on repeated occasions when she and the father were away travelling the child evacuated daily and on the other hand the difficulty with constipation was likely to be aggravated at any time when his twin brother achieved some new talent like swimming or riding a bicycle before the patient did.

Examination showed an obviously bright little fellow with thick lensed glasses. The abdomen was full and filled with numerous loops of feces packed bowel and several large hard fecal masses. Rectal examination showed an anus which admitted the finger easily. The sphincter tone was good. Immediately within the sphincter there was a great mass of moderately firm feces.

Review of the numerous barium enema examinations which had been made over the past several years in the attempt to diagnose or exclude Hirschsprung's disease, showed a greatly dilated colon, particularly the sigmoid, which was very large and never seen empty. There was no narrow segment.

The family and the boy were told together that with the proper management this condition could be entirely corrected. On the prescribed regimen he began having spontaneous stools almost at once, with occasional brief periods of constipation, usually coinciding with deviations from the planned program. By the end of a month he was having very little difficulty. He had never soiled since his first visit. It was actually ten months before a perfectly normal bowel habit was firmly established. At the end of 14 months the family and boy were told he was perfectly well, that his bowel could be totally ignored just as would be a fractured leg which had healed. He has had no abnormality of bowel habit since.

In this instance the physically less fortunate member of a pair of fraternal twins reacted to difficulties by constipation and incontinence. The presence at birth of an anal membrane and the family's subsequent preoccupation with the possible significance of this anomaly amply explains the form in which the patient expressed his reactions.

Case 4. This boy was first seen at the age of 9 years. Recommendation for operation having

been made at another hospital, he was referred to the dispensary by the Salvation Army, this being the only record of an abnormal or difficult family background. It was noted "he does not control movements of his bowels, soils himself in his clothes. Doesn't seem to realize when he has to go to the toilet, this has happened every day since day of birth. He has a good movement every day without cathartics. Very active child. Plays and runs around with complete control of his hands, legs and other parts of his body, including bladder."

Examination disclosed a moderately prominent abdomen distended with gas and tympanitic. There was a lower midline mass about 6 cm. in diameter quite hard and movable. It was felt that he had Hirschsprung's disease and the barium enema demonstrated that the colon was large and dilated and was interpreted as compatible with the diagnosis of Hirschsprung's disease. On a regimen of mineral oil retention enemas he gradually improved, his abdomen became flat, and his incontinence disappeared. The treatment was so effective that within 2 months his bowel habit was essentially normal and the comment was made in the chart "apparently not bothered particularly by the megacolon."

Despite the classical history of psychogenic constipation and incontinence it was apparently assumed that this was Hirschsprung's disease which had been well managed by enemas.

Interestingly enough we sent for this boy some ten years after his first visit, at which time he stated that his bowel habit was perfectly normal and had been for as long as he could remember. He was a neat, quite attractive boy of 19, tall and slender, with flat abdomen.

It is interesting that there is no note in the history as to when his constipation began nor any as to when bowel training was first attempted. Inasmuch as the mother reported on the first visit that the child had had no control of his bowels "from the day of birth," it is quite possible that training was begun very early.

Case 5. White female—10 years old. Chief complaint—"chronic constipation of one year. Refuses even to try to defecate." Normal development. Normal intelligence. At the age of 9 the child became chronically and severely constipated; this

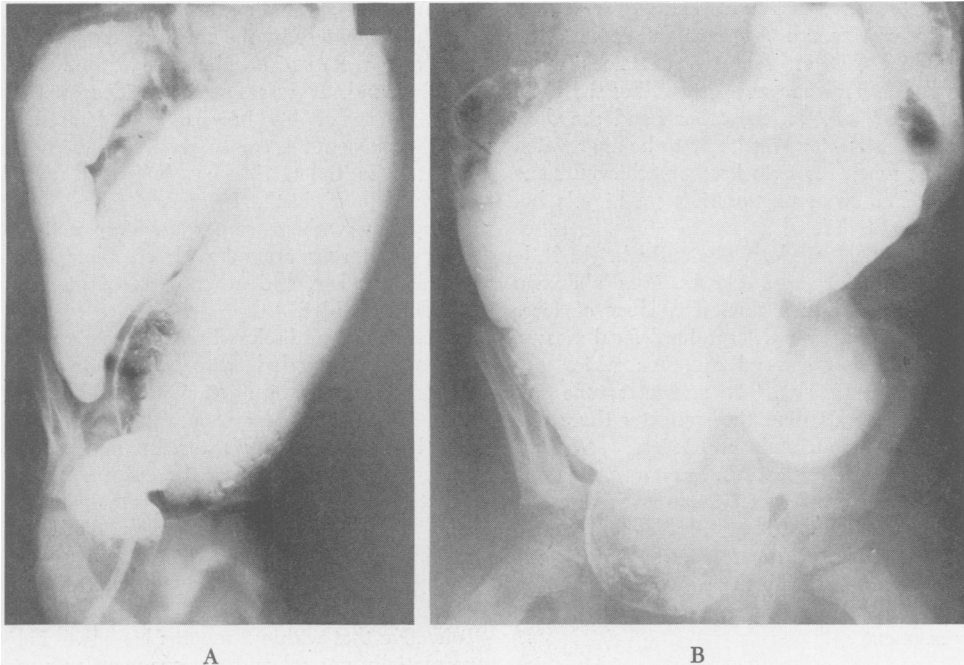


FIG. 1. Hirschsprung's disease in a four-year-old girl with symptoms dating from birth and relieved by operation. A. (Left) Typical barium enema of true Hirschsprung's disease. Note the sharp transition from a normal sized rectum to a huge sigmoid and descending colon. B. (Right) Pseudo Hirschsprung's disease in a boy of eight with severe constipation, incontinence and "marked nervousness" developing some time in childhood. Note the dilatation of the rectum down to the anus. The onset well after the neonatal period, usually three to four years later, and the history of incontinence eliminate the possibility of Hirschsprung's disease, and the absence in the barium enema of a narrow distal segment is further evidence.

progressed until, finally, cathartics and suppositories became ineffectual. When first seen she had not had a bowel movement for 5 days. Her appetite had been good, there had been no vomiting. She had not complained of pain. The stools when passed were thought to be normal. The abdomen was moderately full over the descending colon, sphincter tone was good, the admission of the finger into the rectum was barred by a hard fecal mass which filled the ampulla. On the next visit the child had not had a stool for 11 days and stated that she never used school toilets because "the doors are open, there is no paper, and the seats are dirty." There was palpable a large fecal mass in the abdomen, and again rectal sphincter tone was good and there were several large, hard, fecal masses in the rectum. She was admitted to the hospital for study and it was now noted that she was an only child, and, according to the mother, got everything she wanted. She had always defecated regularly until a year before she was seen. She had stated before being admitted to the hospital that it was not necessary for her to go, that admission was not necessary—"I can

train myself." Volume of stool when passed was likely to be enormous. No note is recorded in the history as to when habit training was begun at home or as to how it was accomplished. On the wards she had no stool for 6 days following which she was given an enema, evacuated well, and thereafter had one or more bowel movements daily.

The patient was followed for a year during which there was never any trouble with evacuation. It is interesting that in spite of a voluminous psychiatric history there is no information as to when bowel training was begun or the methods by which it was pursued. There is the vague suggestion that constipation began abruptly after a school-girl discussion of sexual matters. In this intelligent child, constipation was abandoned as soon as she was hospitalized.

Case 6. This was a 12-year-old female—family history unknown. The child lived with her 15-year-

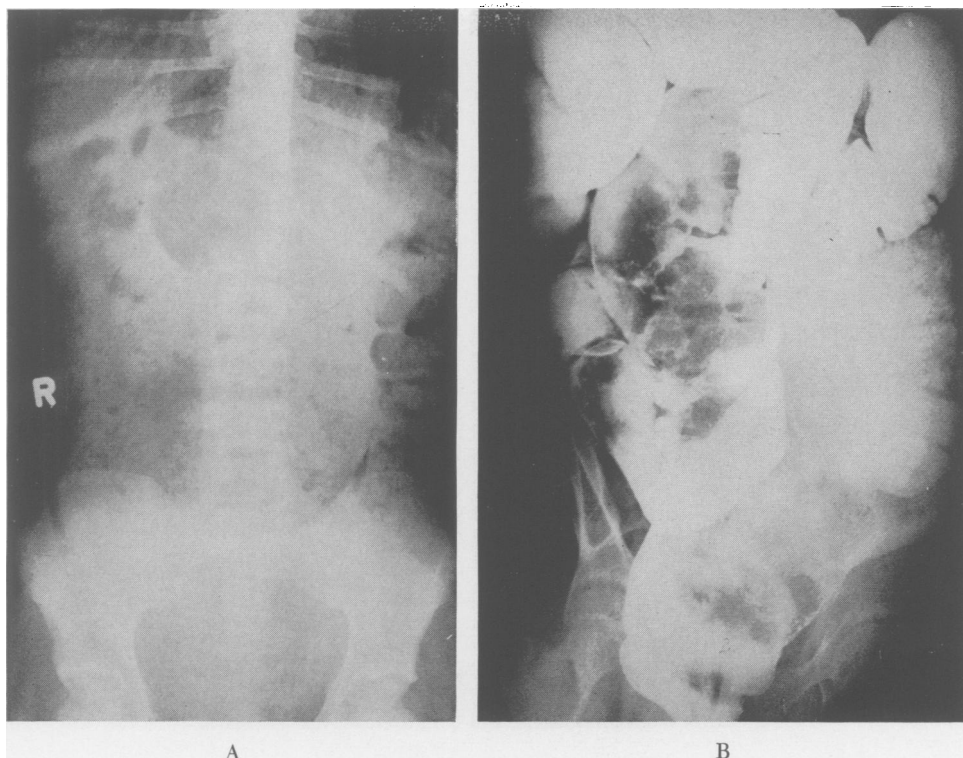


FIG. 2. Girl of nine admitted to the hospital with obstinate constipation since early childhood and two episodes of urinary retention. A. (Left) Plain film showing huge feces filled loop. B. (Right) Barium enema showing voluminous redundant, greatly dilated colon and rectum down to anus. Child was placed on regimen of daily enemas and within a short period of time was having a spontaneous daily evacuation.

old sister and an aunt. She had been constipated "most of her life," and was admitted to the hospital at the age of 8 for fecal impaction. She had an episode of urinary retention at the age of 8 requiring catheterization and another, 2 weeks before the present admission, when she failed to urinate for 36 hours, and 1,000 cc. of urine was withdrawn by catheter.

Examination repeatedly showed large fecal masses in the abdomen, a normal sphincter tone and a rectum filled with a mass "the size of a grapefruit."

Figure 2B shows an original barium enema before a regimen of daily enemas and nightly oil retention enemas. After two weeks of this regimen Figures 2C and D show an entirely normal looking colon which obviously contracts very well. She was followed for a year after and had one or two spontaneous bowel movements every day.

The ludicrous ease with which the entire situation can be elucidated, or at least its nature clearly indicated, is apparent in the following instance.

Case 7. The patient was a 7-year-old white girl who was referred from another large metropolitan city for operation for Hirschsprung's disease. She was brought in by her mother who very rapidly and with practically no prompting told the following story. The patient was an only child and the mother had started training her to stool before she was 6 months old. The child very promptly responded and was completely habit trained and clean within a few months. Ever since she had been 4 years old, however, she had become increasingly constipated and at the same time had soiled her clothing. She would go days without a stool and then would run outside the house and evacuate in her clothing. The only way in which the child would defecate on demand would be if the mother would move the kitchen table into the middle of the kitchen and spread a newspaper upon the floor, whereupon the child would defecate on the paper. The mother stated that she had tried every form of threat, persuasion and punishment without avail. The mother stated that the child was very fond of the mother's sister and loved to visit her at her farm home. When the con-

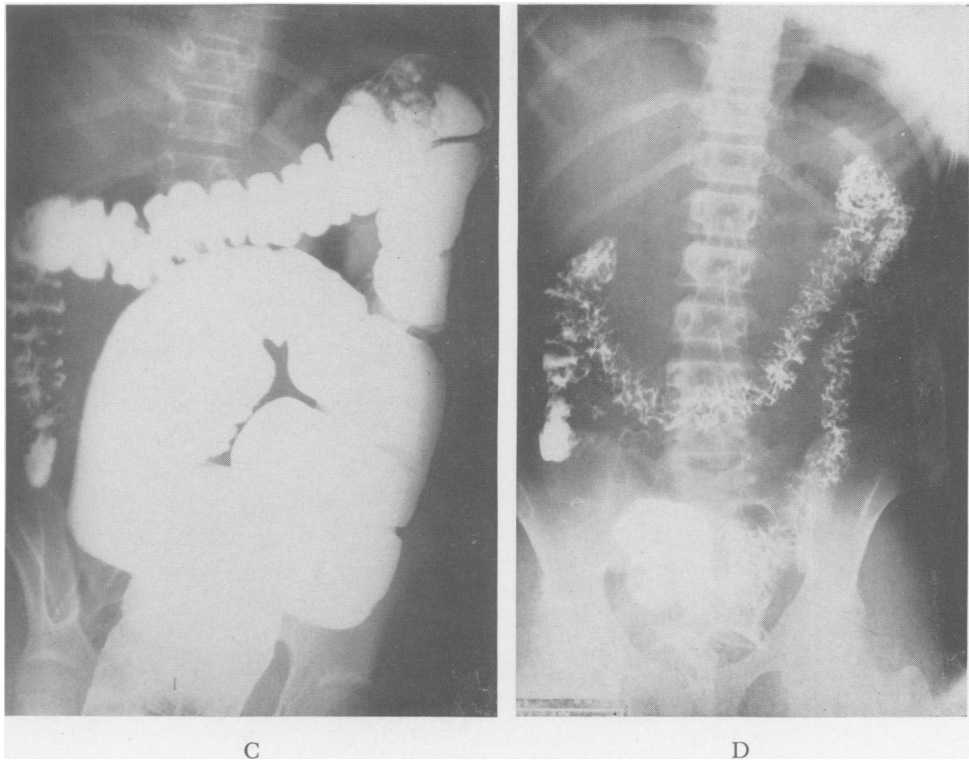


FIG. 2C. (Left) Barium enema three weeks after B shows much less dilatation of colon, and D. (Right) In the evacuation film, the bowel is seen to empty completely. The child had no further difficulty with evacuation.

stipation and the soiling began the aunt told the child that if she wished to continue her visits to the farm she would have to behave naturally. The mother volunteered that she couldn't understand why the child had normal stools when she was at the farm.

Examination showed a slender child with a slightly distended abdomen in which were easily palpable large fecal masses. The peri-anal region was smeared with feces, the sphincter tone was normal, the rectum was distended with great masses of putty-like feces.

The mother was told that no operation was required, that the child's bowel habit could be corrected and a regimen was prescribed. The mother failed to keep further appointments.

Without prompting, this mother told a story of premature and coercive training, of incontinence as well as constipation, and of freedom from difficulty away from home, a classical account of psychogenic pseudo-Hirschsprung's disease.

It will be seen from these case histories, which are typical of the wide variation in the group, that it takes more than poor training methods to produce a reaction of this type in a child. A number of the children come from broken homes, and others come from homes in which there is severe tension. The poor training methods appear, if anything, to be no more than symptomatic of the maladjusted parental personality, and it is, therefore, not surprising that a number of these children show substantial deviations from standard behavior in other respects than bowel habit. It can hardly be disputed therefore that proper treatment of these children would require extensive psychiatric work with both parents and children. Of first importance, however, is the necessity for immediate recognition of the diagnosis, and the separation of this

condition from true Hirschsprung's disease. The sooner and the more firmly such a distinction is made and the fact impressed upon parents and patients that operation is out of consideration, the sooner rehabilitation can start.

The psychiatrists take the attitude that the constipation and incontinence are merely symptoms which not only can be ignored, but should be ignored, in order not to focus further attention on the anus and the act of defecation.

Undoubtedly excellent results can be obtained purely by psychiatric treatment of the patient and family. On the other hand, where several years of intensive family concern have been concentrated on the act of defecation it is unlikely that a few weeks or months of further attention in the form of treatment such as we prescribe, will alter the picture in any harmful way. Furthermore the symptom itself is an extremely annoying and disturbing one always to the parents, and sometimes to the patients. Direct relief of the symptoms may very well facilitate the problem of psychiatric handling of the patient and family.

Most of the children we see are five or six years old or older, although symptoms have usually been recognized from the age of three or four, or occasionally a little earlier. This permits us to talk with the children as well as with the parents. We make a point of speaking to patient and parent jointly and explicitly and do not have additional side conversations with either. They are told that this is a matter of habit training, that it can be corrected by proper training, and that there is no organic abnormality of the bowel and that operation will not be considered at all. They are told that a precise regimen will be prescribed, that deviation from it will not be tolerated and that responsibility for the regimen is taken entirely out of the hands of the parent who has no discretion in following the orders of the physician. This, in itself, is extremely important, since

once the child understands that the parent is merely a passive agent of the physician he finds less profit in thwarting the parent. At the same time, once the parent knows, and is aware that the child knows, that primary responsibility has been shifted from the parent to the physician, the parent is in a position to follow instructions without responding to pressure from the patient, and without feeling that there has been any surrender to the patient.

In a few instances where the home situation is extremely disturbed, or where patients come from a distance so that the child cannot be followed, or when parents are so loath to believe that the condition is non-organic and does not require an operation, that it is feared they will not be capable of cooperating with the prescribed regimen, it is necessary to admit the children to the Hospital. Hospitalization alone is frequently all that is required to straighten out the bowel habit of such children, at least for the period of hospitalization, and one frequently obtains in the history accounts of symptom-free periods when the parents are away from home or when the children are visiting relatives. The principal virtue of hospitalization lies solely in the fact that the mother can be convinced that the child can achieve normal bowel habits and that the child can be convinced that the physician knows this.

In most cases successful treatment can be carried on an out-patient basis, with substantial success within a period varying from two or three weeks to two or three months. As many large tap water enemas are given initially, as are required to empty the colon completely of the inspissated fecal masses. After consultation with the parent and discussion of the whole situation, a decision is made as to the most convenient time in the family schedule for the child's daily bowel movement. Usually this will be immediately after breakfast. Occasionally circumstances will suggest that it will be more convenient immediately

after the evening meal. Parent and child are instructed that for the first two weeks daily at the appointed time and without any preliminary discussion and without threats, bribes, or rewards or postponement, a one quart enema of warm tap water is to be given. This is to be given whether the child has spontaneous bowel movements in the interim or not. At the end of two weeks the child and mother are seen again. If the regimen has not been strictly adhered to they are instructed to do so and to return in a week. Once the parent and child are convinced that there is no recourse but to follow instructions implicitly, improvement will follow readily. For the next two weeks the child goes to the toilet seat at precisely the same time that the enemas have been given. He and his mother are instructed that at the end of ten minutes the mother will inspect the toilet bowl. If there is a large and copious stool no more need be done. If there is no stool, or only a small one, a one quart warm tap water enema is given at once. Again this is without discussion of any sort, but entirely automatic and it is made plain that no delays for further efforts are to be considered. Usually within two to four weeks the child will be found to be evacuating daily without an enema. Once this pattern is established, both parent and child are strongly encouraged and the occasional lapses are found to be farther and farther spaced. Once regularity is apparently firmly achieved, mother and child are instructed to forget all about the problems of defecation on the basis that the child has a normal bowel, now has a normal bowel habit, and needs no more attention to his defecation than does anyone else.

It is perfectly true that there is no valid reason for requiring everyone to have a bowel movement every day. On the other hand the above method has proved to be a simple and effective method of treatment. No drugs of any kind are employed. If habitual constipation is too long neglected

there may finally emerge a habit of chronic constipation which is not correctable and requires a lifetime of enemas and cathartics.

2. Megacolon and Obstinate Constipation in Mentally Defective Children

There is certainly no reason to suppose that there will not be an occasional child with Hirschsprung's disease who also has an organic cerebral defect. On the other hand, this will manifestly be a great rarity, while more commonly chronic constipation, occasionally with encopresis, will be prominent in mental defectives. Among such cases which we have in our records are a four and one half year old child with agenesis of the right cerebral hemisphere, and another who was a microcephalic.

Case 1. This child was admitted to the hospital at the age of 4½ years because of large, infrequent bowel movements. The question of Hirschsprung's disease had been raised. There was a history of normal development up to the age of 6 months when he experienced a convulsive episode after which there had been no mental development. He had continued to have repeated convulsions and, at the age of 6 months, a craniotomy was performed and marked atrophy of the right cerebral hemisphere was found. He had been constipated since birth and always required auxiliary measures to produce even an infrequent bowel movement which usually proved to be remarkably large. In addition to the neurologic findings, it was noted that the abdomen was distended and that the colon could be outlined filled with semi-hard fecal material. Sphincter tone was normal. The rectum was filled with a huge mass of putty-soft feces. The diagnosis of mental retardation was obvious. Barium enema showed a greatly dilated colon with a redundant sigmoid. It was felt that this was an acquired megacolon, secondary to constipation.

Case 2. This girl was first noted to be constipated when she was 2 years old. When she was 3 years old she was seen with a greatly distended abdomen, had not had a bowel movement in 2 weeks, and had been markedly distended for a month. She was an undernourished child, obviously microcephalic and had a huge tensely distended abdomen requiring a gastric tube as well as repeated enemas. She was noted to be an air swallower and x-rays showed an enormous colon. It is

interesting that this patient seen in 1925 was brought into the hospital to be shown in Dr. John Howland's clinic as an example of Hirschsprung's disease. On the day the child was brought in she was not markedly distended—the condition was thought not to be striking enough for the child to be shown on that day.

The therapeutic problem in children such as this resolves itself into one of enemas given daily with absolute regularity. These serve the purposes of emptying the colon, avoiding retention of feces and avoiding the nuisance of encopresis on the one hand, and of ultimately being likely to establish the kind of automatic bowel training which can be obtained even with abdominal colostomies.

3. Megacolon and Obstinate Constipation Associated with Organic Anal Obstruction

One would suppose that in the presence of a straightforward history of an imperforate anus with surgical repair at birth, later constipation and incontinence would be attributed to this condition and to the operation and not to Hirschsprung's disease. The fact is that even though very good continence is achieved with successful repair of an imperforate anus, it is not always easy to establish a good bowel habit. Whether this is due to psychologic reasons, with heavy concentration on the abnormal area by the anxious family, (as demonstrated in Case 3 under psychogenic constipation, above), whether it is due to organic stricture, as it surely is in some cases, or whether it is due, as Swenson postulates, to the fact that the bowel, which is brought down to the anus, is not normally innervated, the fact remains that regular bowel habit is frequently difficult to establish. We were astonished to find, in not extremely old records, five cases of imperforate anus with surgical correction subsequently seen at the hospital for "megacolon." These patients came to the hospital

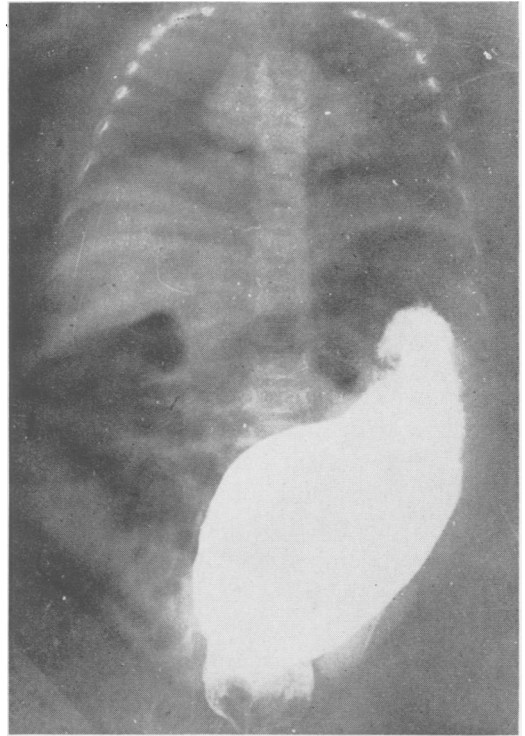


FIG. 3. This child had an imperforate anus repaired when she was one day old. She returned a year later with severe constipation and great abdominal distention with the story that she had hard stools about every third day. She was emaciated, dehydrated and enormously distended. The colon was filled with hard, round fecal masses. Rectal examination showed a tight stricture entirely at the mucocutaneous junction. Note the great dilatation of the rectum and sigmoid, down to the anus. Regularity of bowel habit may be difficult to establish after repair of an imperforate anus but the condition is readily separable from Hirschsprung's disease and there are no reports of the two diseases existing in conjunction.

complaining of constipation, distention, encopresis and fecal impactions due to failure to prevent stricture formation (Fig. 3). It is embarrassing to report that one of these patients had actually had a sympathectomy for putative Hirschsprung's disease (this was before 1948) and that another was advised to have a sympathectomy. This patient refused, and at another hospital a plastic operation upon his anus was entirely successful. A letter from him many years later reports that he is normal, married, has a perfectly normal bowel habit, despite

the fact that his colon had been perfectly enormous.

4. Megacolon and Pseudo-Hirschsprung's Disease in Congenital Cretins

Intestinal disturbances in association with myxedema are well known and constipation is the commonest. Abdominal distention and functional megacolon and dolichocolon have been described, with great dilatation of the entire intestine and even of the stomach. These changes respond to treatment with thyroid extract and are reversible if treatment is not too long delayed.

In newborns and infants in whom the diagnosis of cretinism may not be readily apparent, abdominal distention and obstipation may be the presenting symptoms. The clinical picture may strongly resemble that of Hirschsprung's disease and in the case reported by Salmi and Lakesmaa⁸ was indistinguishable from Hirschsprung's disease.

Case 1. This little girl of 4½ years had been diagnosed as having Hirschsprung's disease at another hospital and was referred for treatment with the additional note that her development was moderately retarded. She was said to have been born with a large abdomen, had had normal bowel movements for about four to six weeks and then became severely constipated, requiring laxatives and enemas constantly. Her abdominal girth had been steadily increasing. She was noted to be small, suggestively cretinoid, and mentally retarded. The abdomen was filled with visible intestinal patterns and palpable feces filled the loops. While there seemed to be no doubt that she had Hirschsprung's disease and the barium enema showed a greatly dilated colon compatible with Hirschsprung's disease, hypo-thyroidism was suggested in addition. Her blood cholesterol determinations were 273 mg. per cent and 244 mg. per cent. The diagnosis of cretinism was strengthened by the radiologic demonstration of marked retardation of epiphyseal development. She was placed on a variety of treatments for constipation and also given thyroid extract ¼ to ½ a grain a day, rapidly raised to 2 grains daily. A year later it was noted that she only needed 6 enemas in 9 months, but that when the thyroid extract was reduced, her constipation returned and that with the dose increased again the symptoms receded. The barium enema was felt no longer to support

the diagnosis of Hirschsprung's disease, although the bowel was still redundant and smooth. Sixteen months after she had been started on thyroid extract her bowels were well regulated on no other medication at all, and the cathartics, which previously had been required to produce stools, now produced diarrhea if they were employed. Her blood cholesterol level was 127 mg. %.

In this instance of undoubted congenital cretinism the distended abdomen and the constipation and enlarged colon all strongly suggested Hirschsprung's disease, the diagnosis with which the child was referred, and were accepted as such in spite of the probability that the child was a cretin. It was only after the dramatic response of the constipation and the abdominal swelling to thyroid extract that it became obvious that these symptoms were entirely secondary to the thyroid deficiency.

Case 2. This child was born in December 1903, and was first seen in September 1915, with the complaint that she had a large abdomen and had had obstinate constipation for a year. She was pale, with coarse, dry skin, short spade-like hands, showed retarded sexual development, and a bradycardia of 70. The thyroid isthmus was palpable, but the lateral lobes were not. She had an extremely prominent abdomen and doughy masses were felt in it. Two contrast enemas were performed. The first reported dilated redundant colon confined chiefly to the rectum and sigmoid, with spastic descending and transverse colon. The second, 3 days later, was flatly reported by Dr. Baetjer as "Hirschsprung's disease." This child presented with obstinate constipation and abdominal distention and her x-rays were accepted in that day as showing Hirschsprung's disease. However, it appears to have been recognized that she was a cretin. A note is recorded in the history that she was seen by Dr. Halsted and was discharged on two grains of thyroid twice daily. There is no further record of her course.

It seems fairly clear that this patient was, in fact, a mild cretin, and it is fairly obvious from the record that for some time she was considered to have Hirschsprung's disease and it was only some time later that the diagnosis of thyroid insufficiency was made.

The patient of Salmi and Lakesmaa⁸ is of special interest. This was a female infant who became constipated at the age of 3 weeks and was first

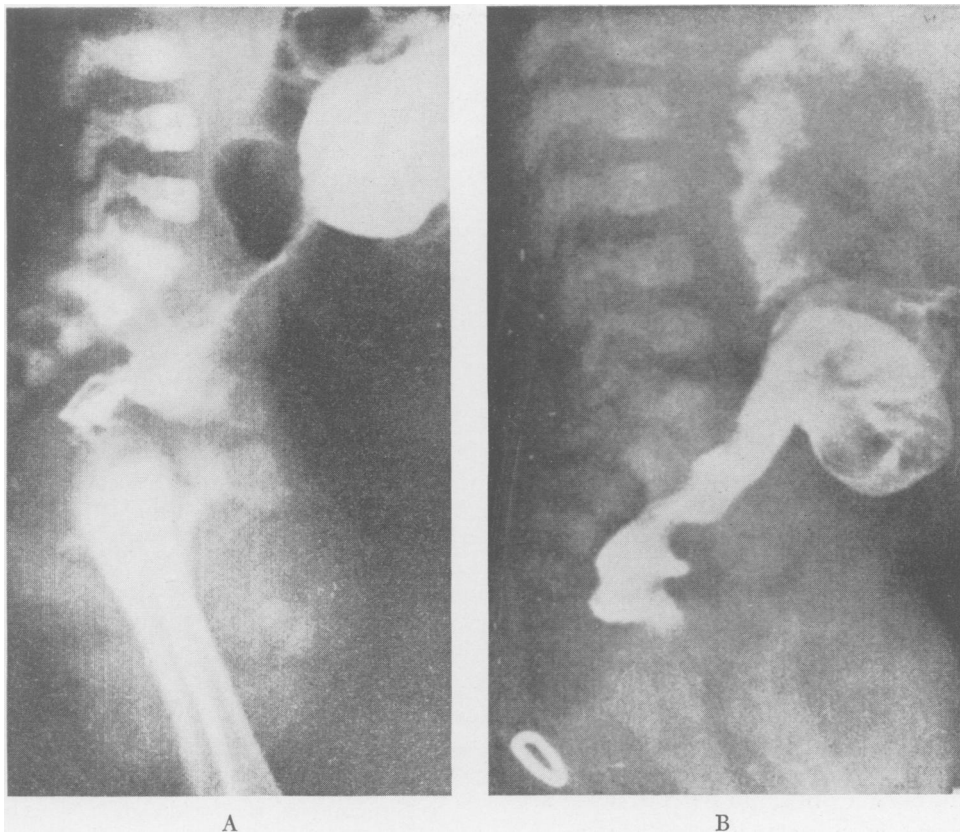


FIG. 4. Megacolon in case of severe constipation in a congenital cretin. (From Salmi and Laksmäa, *Acta Paediatrica*, 45: 1956). This child presented with stubborn constipation and severe distention dating from the age of three weeks. A. (Left) Barium enema at six weeks showing dilated sigmoid and a narrow rectal segment much like that seen in Hirschsprung's disease—actually narrower than most. The child was recognized to be a cretin when she was three months old. Thyroid hormone therapy was begun and three weeks later, B. (Right) The barium enema was essentially normal and the child was having regular spontaneous evacuations.

seen at the age of 4 weeks. A plain film showed distended intestines. At 6 weeks there was great distention of the colon and the barium enema was typical of Hirschsprung's disease (Fig. 4A). At this time there was suggestive physical evidence of myxedema but a diagnosis of Hirschsprung's disease was made and non-operative therapy prescribed. When she was 3 months old she was having stools at three to four day intervals but now appeared typically myxedematous. Laboratory investigations were equivocal, with a cholesterol of 185 mg. per cent. On the basis of the clinical diagnosis therapy with thyroid extract was begun. The child promptly lost its myxedematous appearance. In 3 weeks the barium enema was essentially normal (Fig. 4B) and the bowel functioned regularly. Another barium enema a year later was normal.

In this case of congenital cretinism, constipation appeared at three weeks and the

barium enema looked like that of Hirschsprung's disease with a narrow segment. Thyroid therapy reversed the cretinoid changes, restored normal evacuations, and a normal barium enema picture.

Obstinate constipation may also be a symptom secondary to hypo-thyroidism in adults.

Bacharach¹ cites the instance of an Army nurse of 35 who had been severely constipated for 3 years, was finally referred to the surgical service of an Army Hospital for treatment of a megacolon. She had had a thyroidectomy for hypo-thyroidism 8 years before, and five years after the thyroidectomy, noted the onset of progressive constipation, until finally no stools were produced without enemas and laxatives. She functioned well as a nurse on an active surgical ward although inclined to be

somewhat lethargic and to prefer heated rooms. Her BMR was -32 and -42 , her PBI 2.5 mu grams per cent. Her barium enema showed redundancy and fullness of the colon. On $\frac{1}{2}$ a grain of thyroid daily, rapidly increased to 6 grains daily, in 2 weeks she had her first spontaneous bowel movement and thereafter required no more laxatives and was having a bowel movement daily on thyroid therapy alone. Her barium enema now looked perfectly normal. Her lethargy had disappeared.

Congenital cretinism is sufficiently uncommon so that it is sometimes not readily thought of, particularly in children who present exaggerated manifestations of one symptom—severe constipation.

Summary

Hirschsprung's disease may be mimicked in children with:

1. Psychogenic constipation—pseudo Hirschsprung's disease. Unlike Hirschsprung's disease, symptoms do not appear at birth, encopresis is common, and the barium enema shows no narrow distal segment.
2. Mental retardation and cerebral defects.
3. Corrected imperforate anus—on the basis of stenosis, imperfect innervation, or poor habit training.
4. Cretinism—severe constipation and intestinal dilatation may be the presenting symptoms.

Treatment in these four groups is:

1. Open discussion with parent and child, assumption by the physician of full control of the details of treatment, and relegation of parent to the role of the physician's agent in following the prescribed regimen.
2. Regular enema regimen, in the less severe cases, one identical with that used in Group 1.

3. Enema regimen much as in 2 and dilatation of strictures, or anoplasty. Whereas fairly rapid restoration of normal bowel habit can be expected in Group 1, and persists, the basic defect in Groups 2 and 3 may require indefinite continuance of treatment.

4. Thyroid hormone therapy relieves the constipation of hypothyroidism and causes reversion of radiographic changes in the colon and rectum.

Bibliography

1. Bacharach, T., and J. R. Evans: Enlargement of the Colon Secondary to Hypothyroidism. *Ann. Int. Med.*, 47:121, 1957.
2. Bell, A. I. and M. I. Levine: The Psychologic Aspects of Pediatric Practice. I. Causes and Treatment of Chronic Constipation. *Pediatrics*, 14:259, 1954.
3. Bodian, M., F. D. Stephens and B. C. H. Ward: Hirschsprung's Disease and Idiopathic Megacolon. *Lancet*, 1:6, 1949.
4. Garrard, Sterling D. and Julius B. Richmond: Psychogenic Megacolon Manifested by Fecal Soiling. *Pediatrics*, 10:474, 1952.
5. Hirschsprung, H.: Stuhlträgheit Neugeborener in Folge von Dilatation und Hypertrophie des Colons. *Jahrb. Kinderh.*, 27:1, 1888.
6. Huschka, M.: The Child's Response to Coercive Bowel Training. *Psychosomatic Medicine*, 4:301, 1942.
7. Lee, C. M. and K. C. Bebb: The Pathogenesis and Clinical Management of Megacolon with Emphasis on the Fallacy of the Term "Idiopathic." *Surgery*, 37:762, 1955.
8. Salmi, T. and P. Lakesmaa: Pseudo-Hirschsprungsche Erkrankung bei einem Myxödem-Säugling. *Acta Paed.*, 45:428, 1956.
9. Swenson, O.: Classification and Treatment of Children with Severe Chronic Constipation. *Am. J. Surg.*, 86:497, 1953.
10. Swenson, O., E. B. D. Neuhauser and L. K. Pickett: New Concepts of Etiology, Diagnosis and Treatment of Hirschsprung's Disease. *Pediatrics*, 4:201, 1949.
11. Swenson, O. and A. H. Bill, Jr.: Resection of Rectum and Rectosigmoid with Preservation of the Sphincter for Benign Spastic Lesions Producing Megacolon, *Surgery*, 24:212, 1948.