

Traumatic Rupture of the Bronchus *

A Clinical and Experimental Study

RICHARD M. PETERS, M.D., WILLIAM E. LORING, M.D.,**

WILLIAM H. SPRUNT, M.D.

From the North Carolina Memorial Hospital and School of Medicine, University of North Carolina, Chapel Hill, North Carolina

THIS PAPER is designed to present experimental and clinical data to clarify some of the pathologic and physiologic changes that occur following rupture of a major bronchus. The acute problems of tension pneumothorax, etc., are common knowledge to people dealing with such trauma. The mechanism of injury is less well understood. The ultimate functional result following early or late repair of a fractured bronchus likewise is unclear particularly in patients with chronic atelectasis.

The discussion and presentation of data will attempt to answer the following questions:

1. What is the nature and mechanism of injury that leads to rupture of a bronchus?
2. Is early surgical repair associated with return to normal function?
3. In chronic atelectasis: a) What portion of the pulmonary blood flow goes to the unventilated lung? b) How can one distinguish whether return of function may be expected after repair of a torn bronchus? c) If late repair is carried out and re-expansion occurs, what is the ultimate function of the re-expanded lungs?

Animal Experiments

Four dogs were studied four to nine months after transection of the right or

left main stem bronchus. The mean blood oxygen saturations demonstrated that the blood flow to the atelectatic lung was reduced to 14.5 per cent of the total flow from a normal of 45 per cent to 55 per cent. The dogs appeared perfectly normal and had an arterial oxygen saturation of 94 per cent. Angiocardiograms showed a marked decrease in the amount of contrast material in the pulmonary arteries of the collapsed lung with a decrease in size of the pulmonary arteries themselves (Fig. 1). The vessels on the nonoperative side were better visualized than normal and particularly in the periphery of the lung were more tortuous and wider than normal. No bronchial arterial collateral circulation was demonstrated.

When the dogs were sacrificed there was no evidence of infection and the mediastinal structures were shifted toward the operative hemithorax. The atelectatic lung was small. Vinyl plastic casts of the bronchial arteries, pulmonary arteries, pulmonary veins and bronchi were made after the method of Liebow.¹⁰ These casts showed a decrease in size of all elements in the collapsed lung and no evidence of increased bronchial arterial collateral. These studies demonstrated that there is marked decrease in flow to an atelectatic lung and that this decrease is not dependent on any increase in bronchial arterial collateral circulation. The relationship of the finding to some of the vascular dynamics of the lung are discussed in detail in another paper.¹⁵

* Submitted for publication February 3, 1958.

** Present address: Department of Pathology, New York University, Bellevue Medical Center, New York City.

This study aided by U.S.P.H.S. Grant No. H 1257.

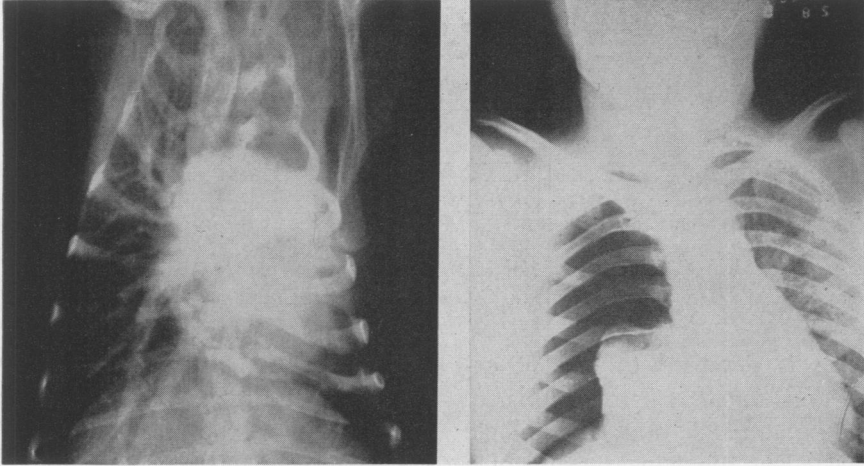


FIG. 1 (left). Angiogram of a dog six months after ligation of the left main stem bronchus. The right main pulmonary artery is two or three times normal size, while the left is not seen. The peripheral pulmonary arteries are proportionately enlarged also. Note the small left descending pulmonary vessel, seen through the cardiac shadow, and compare it with the one on the right.

FIG. 2 (right). Case 1. March 1953. The first roentgenogram revealed a right pneumothorax but no evidence of rib fracture.

Patients

Four patients with traumatic rupture of the bronchus have been seen at North Carolina Memorial Hospital.

Case Reports

Case 1. The patient, an 11-year-old negro male, was well until March 1953, when he fell

off the back of a mule that he was riding into the path of a loaded wagon, and a wheel passed over his chest. When admitted to a hospital in his community, he had a right pneumothorax but no rib fractures (Fig. 2). The lung re-expanded rapidly.

He was next seen by his physician in September 1953, with fever and a white blood count of 12,500. X-rays revealed a dense shadow occupying the region of the right upper lobe, the

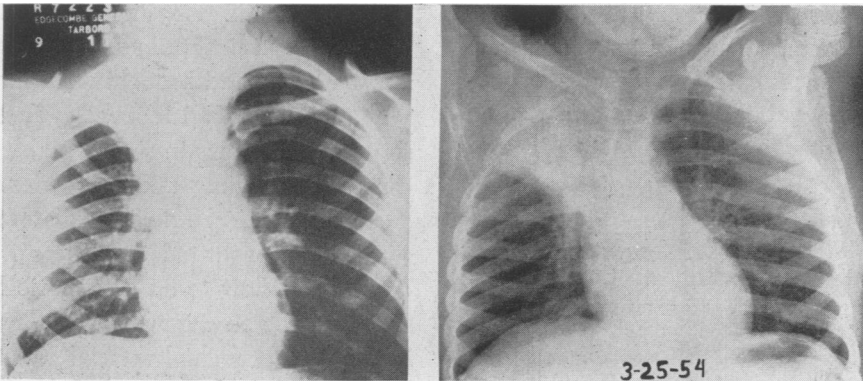


FIG. 3 (left). Case 1. September 17, 1953. Films this date showed the dense shadow in the right upper lung field.

FIG. 4 (right). Case 1. March 25, 1954. Again a right upper lung field density, larger than previously, was seen.

lower margin of which was sharply defined, evidently representing the minor fissure (Fig. 3). On administration of penicillin, a sulfa compound and later tetracycline this area cleared slowly. By the end of October 1953, the "lung was practically normal in appearance" according to his physician.

He was well for a time but returned to his physician on March 8, 1954, and x-ray again revealed the shadow in the right upper lobe area. On this occasion the temperature was 102.8° and the white count was 16,800. After the administration of tetracycline and later "neo-penzine" the child's fever subsided but the x-ray appearance remained unchanged.

He was referred to the North Carolina Memorial Hospital on March 25, 1954, for further study. An x-ray film revealed atelectasis of the right upper lobe and mediastinal shift to the right (Fig. 4). He appeared mildly ill and the only significant physical findings were dullness and absent breath sounds in the right upper lobe area.

At bronchoscopy a stenosis of the right upper lobe orifice was visualized. A thoracotomy was performed on April 2, 1954. Dissection was difficult because of scar tissue and because of the presence of large inflammatory lymph nodes with rich arterial supply. The right upper lobe bronchus was found to be completely transected, the ends healed except for one pinpoint opening. A right upper lobectomy was done. No other abnormalities were found.

Pathologic Findings: On gross examination the specimen received consisted of a collapsed pyramidal shaped right upper lobe measuring ap-

proximately 12 × 8 × 8 cm. The major bronchial subdivisions were moderately dilated and contained large quantities of a thick muco-purulent material. The bronchial mucosa was congested and replaced in areas by confluent superficial ulceration. Multiple slices through the pulmonary parenchyma revealed not only almost total atelectasis but a firmer random deposition of fibrous tissue. No abscess formation was found.

Microscopically the predominating picture was one of pulmonary fibrosis and organizing pneumonia. Small collections of subpleural alveoli contained air, but the large majority of them were packed with a mucoid material and many macrophages. The entire thickness of some of the bronchial walls was infiltrated by a profuse inflammatory exudate that indicated both a subacute and chronic infectious process. Not infrequently the mucosa had sloughed and granulation tissue was seen in its stead. The bronchial arteries were prominently dilated and packed with red blood cells.

The patient recovered without complication and was discharged on April 14, 1954. Nine months later he had gained 18 lbs. and had grown 4 inches. X-rays showed the right lung to aerate well and to fill the right chest completely (Fig. 5).

Discussion: This boy was run over by a heavily loaded wagon yet his only injury was a ruptured right upper lobe bronchus. This lesion was not diagnosed and he apparently developed nearly complete bronchial stenosis with recurrent infection.

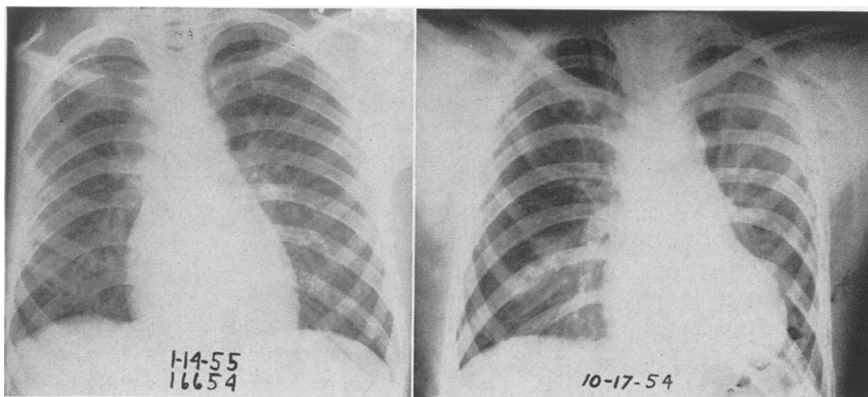


FIG. 5 (left). Case 1. January 14, 1955. This roentgenogram made nine months postoperatively revealed a normally expanded right lung.

FIG. 6 (right). Case 2. October 17, 1954. Films made two days after injury revealed the small left thorax, abnormal pattern of pulmonary arteries, small left pneumothorax, and subcutaneous air in the shoulder region and mediastinum.

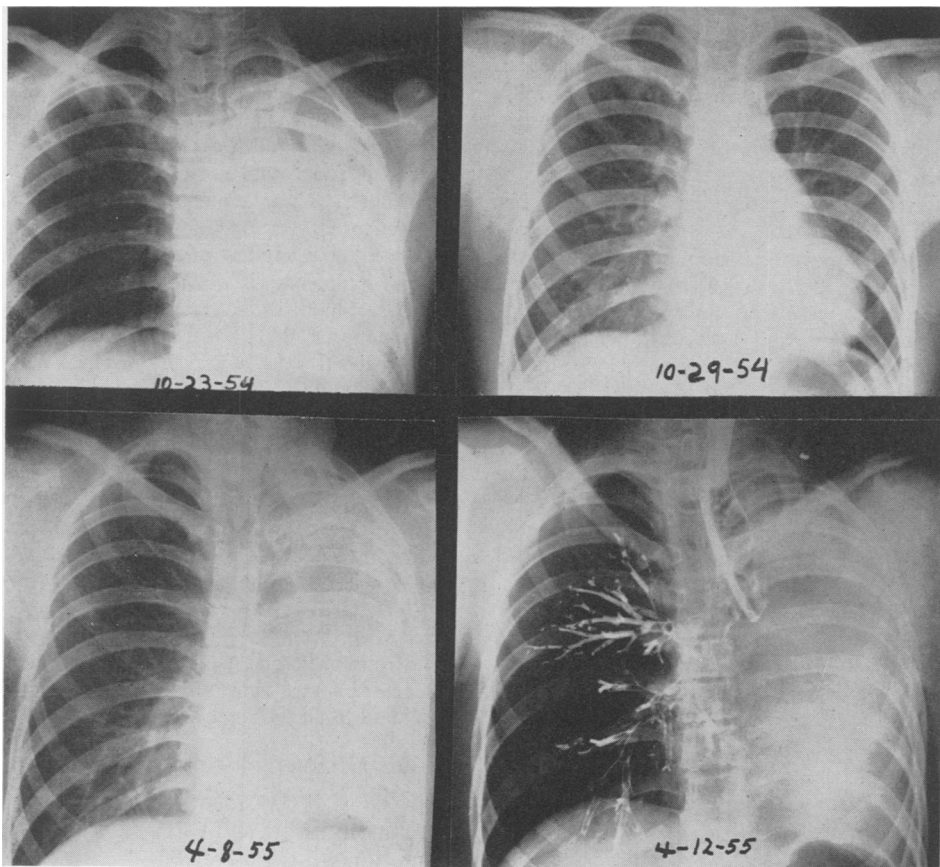


FIG. 7 (upper left). Case 2. October 23, 1954. Left chest was now completely opaque and there was a shift of the mediastinum to the left.

FIG. 8 (upper right). Case 2. October 29, 1954. One week later the left lung had partially re-expanded, though there was still some mediastinal shift and narrowing of the rib spaces.

FIG. 9 (lower left). Case 2. April 8, 1955. On re-admission after an acute episode of shortness of breath, the complete opacification of the left chest was again seen.

FIG. 10 (lower right). Case 2. April 12, 1955. Bronchogram revealed obstruction of the left main bronchus just beyond the carina.

There were many large lymph nodes around the bronchus with rich bronchial arterial supply. This is in contrast to the uncomplicated atelectasis in dogs and Case 2. This increased collateral blood supply is seen after pulmonary suppuration. Resection was considered the therapy of choice in this circumstance because of the history of repeated infections. Pathologic examination confirmed the presence of irreversible inflammatory changes. With early recogni-

tion and repair this lobe might have been saved.

Case 2. On October 15, 1954, the patient, a 15-year-old white male, fell from a tractor and one wheel of a loaded trailer passed over his left chest and shoulder. He developed acute respiratory distress and was taken promptly to Woodard Herring Hospital in Wilson, North Carolina. On admission the patient appeared acutely ill with moderately severe dyspnea and subcutaneous emphysema. No fractures were found. Because a

hurricane had disrupted the source of electric power, no x-rays were taken until 2 days later.

The roentgenograms of the chest revealed a small left thorax with abnormally distributed pulmonary arteries visible in the small portion of aerated lung which was present. The right lung was well expanded, and there was a small pneumothorax and a large amount of subcutaneous air in the neck and supraclavicular areas (Fig. 6).

On October 23 the left chest was homogeneously dense with complete shift of the heart and mediastinum to the left (Fig. 7). Within a week the left lung had partially re-expanded and gradually further aeration occurred, although some mediastinal shift, narrowing of the rib spaces and slight elevation of the diaphragm persisted (Fig. 8). The pulmonary artery distribution seemed to be disorganized and lacked the normal pattern. The patient was discharged as apparently well and told to return for follow up.

He did not return until 6 months later. On that day the patient ran approximately 2 city blocks trying to catch an automobile that had left him behind. He became acutely short of breath and on going to bed that night experienced another such attack. The patient was taken again to the referring hospital and x-ray revealed shift of the heart and mediastinum to the left and complete opacification of the left thorax except for a portion of the right lung which was herniated across the midline (Fig. 9). The patient was then referred to North Carolina Memorial Hospital. The only interim symptom until the acute episode

described above was a "hasseling" in the throat. This was interpreted to be tracheal irritation.

Physical examination showed a somewhat mentally retarded boy who appeared younger than his age and in no acute distress. He had moderate kyphosis and diminished expansion of the left chest with dullness and absent breath sounds on the same side. The rest of the physical examination was within normal limits.

A bronchogram showed complete and sharply defined blockage of the left main bronchus about .5 cm. distal to the carina (Fig. 10). An angiocardio-gram on the following day demonstrated a normal appearing main pulmonary artery (Fig. 11). The right main pulmonary artery appeared enlarged and all of its branches were wider than usual. In contrast the left main pulmonary artery was small, measuring less than half the size of the right, and its major branches were proportionally smaller than the corresponding branches on the right. Bronchial arteries were not seen.

Arterial blood was drawn at rest and during exercise. There was a moderate depression of the oxygen saturation as shown in Table 1 but calculations^{3, 15} showed that the fall was much less than would be expected if the blood flow to the atelectatic lung had been the normal 45% of the total flow.

On April 12, 1955, a left thoracotomy was done. There was complete atelectasis of the left lung. The hilum was dissected out and the left main stem bronchus was separated about 2 cm. from the carina by a fibrous band. A pneu-

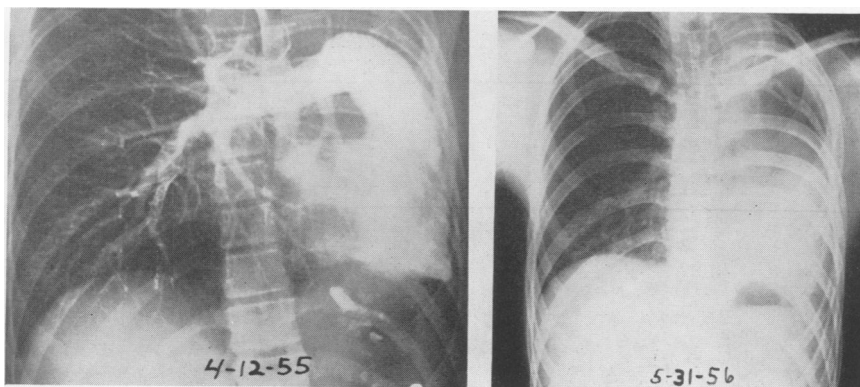


FIG. 11 (left). Case 2. April 12, 1955. A venous angiocardio-gram demonstrated the marked cardiac shift and rotation, with a normal main pulmonary artery, but with a marked discrepancy in the size of the right and left pulmonary arteries and the peripheral vessels.

FIG. 12 (right). Case 2. May 31, 1956. Examination over a year after left pneumonectomy revealed the small left thorax and the over-expanded right lung.

TABLE 1. *Arterial Blood Studies on Patients*

Date	Condition	Oxygen			pCO ₂ mm. Hg	CO ₂ Cont. mEq.	pH
		Cont. Vol. %	Cap. Vol. %	Sat. %			
Case # 2—L. J., 15-year-old male							
6 mos. post injury	Rest	18.2	19.7	92	53	26.4	7.29
6 mos. post injury	Exercise	18.4	20.1	91			
1 wk. post resection	Rest	15.9	17.0	93	46	28.9	7.40
1 yr. post resection	Rest	16.7	17.1	98			
1 yr. post resection	100% O ₂	18.6	17.1	109			
Case # 3—B. W., 23-year-old male							
1 day preop.					42	29.3	7.44
6 wk. post repair	Rest	16.2	16.7	97			
6 wk. post repair	100% O ₂	19.7	18.1	109			
16 mos. post repair	Hyper- ventilation	19.9	19.9	100	21	19.9	7.59
16 mos. post repair	100% O ₂	22.0	19.7	112			
Case # 4—J. T., 23-year-old female							
6 mos. post repair	Rest	17.3	19.0	91			
6 mos. post repair	100% O ₂	18.7	18.0	104			

monectomy was performed rather than a repair of the bronchus which would have required mobilization of the aortic arch. During the resection no bronchial arteries of any significance were encountered. No repair of the stump was necessary.

Pathologic Findings: Gross—The specimen consisted of a normally developed adolescent left

lung weighing approximately 144 Gm. It was completely atelectatic but retained an otherwise normal shape. The bronchial stump measured 2.5 cm. in length and was completely sealed off by a sheet of gray, pliable, fibro-collagenous tissue. The pleural surfaces were smooth, glistening and free of fibrous adhesions. A few minute petechial hemorrhages were present subpleurally in the inter-

TABLE 2. *Incidence of Injuries with Type of Trauma*

Male	Female	Total	Runover	Crushed	Auto Accident	Other	None Except Pneumo- thorax	Fractures about the Chest*
Ages 0-10 years								
20	9	29	17	4	4	4	14	13
Ages 11-20 years								
11	4	15	7	2	3	3	1	10
Ages 21-30 years								
21	5	26	3	5	12	5	2	18
Over 30 years								
14	3	17	2	7	7	0	2	17

* Clavicle, scapula, sternum, ribs.

lobar fissure. Upon opening the bronchial tree, it appeared to be slightly smaller than the anticipated normal and was filled to capacity with a non-purulent, viscid yellow mucus. Although the circumference of the main stem bronchus just distal to the fibrous seal was slightly reduced by scar formation, the previous cartilaginous fracture appeared to be healed. The pulmonary parenchyma was totally collapsed and purplish-gray in color. Serial sections failed to show any evidence of a recent or old infection. The branches of the pulmonary artery and vein were small but normal in distribution. The bronchopulmonary and peribronchial lymph nodes were not remarkable.

Microscopic: The tissue sealing the main stem bronchus was composed of relatively acellular, dense collagen fibers between some of which were scattered deposits of old blood breakdown products. Multiple sections of the bronchial tree and lung parenchyma were taken. The bronchi and bronchioles were distended with basophilic mucus. The epithelium was sometimes absent, sometimes cuboidal and sometimes hyperplastic columnar in type. The proximal plates of cartilage showed evidence of old injury and repair. In these areas the muscle bands were occasionally interrupted by fibrous tissue. The bronchial arteries and veins were easily identified, but showed no tendency toward medial hypertrophy, dilatation or increase in number. In several of the more peripheral sections the mucus secretions had spilled into the alveolar ducts and sacs and in some areas even into the alveoli. The other alveoli were collapsed and their potential spaces were marked only by the presence of hemosiderin-laden macrophages.

No evidence of fibrosis, inflammatory exudate or necrosis was present. The pulmonary arteries, veins and lymph nodes were not remarkable.

The patient had a benign postoperative course. Ten days after surgery the oxygen saturation of the femoral arterial blood was still slightly depressed. This was probably the result of hypoventilation and studies after breathing 100 per cent oxygen would have clarified this problem but were not done.

Examination thirteen months after surgery revealed complete relief of symptoms and normal oxygen saturations with no evidence of shunt. Roentgenograms taken at the same time showed a small left chest with the diaphragm elevated, and the heart was shifted to the left. The right lung was clear and increased in volume, occupying a good portion of the left thorax (Fig. 12).

Discussion: This boy was run over and again the only significant injury was a ruptured bronchus. The diagnosis was not made until late because of the weather and the patient's failure to return for follow up. He had complete atelectasis of the left lung for six months. Despite lack of ventilation of one lung, the oxygen saturation is maintained at near normal levels (Table 1). This is due to a decrease in flow to the atelectatic lung from a normal 45 per cent of the total cardiac output to 9 per cent of the total. (For details of calculation

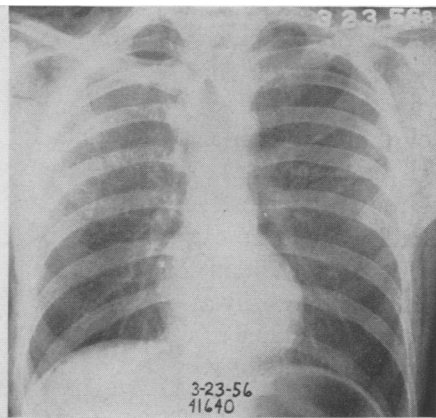
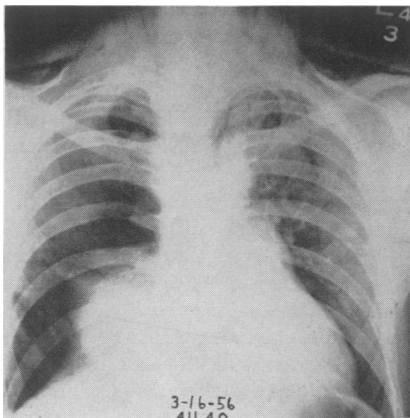


FIG. 13 (left). Case 3. March 16, 1956. Examination immediately after injury revealed a tension pneumothorax on the right.

FIG. 14 (right). Case 3. March 23, 1956. This roentgenogram revealed the rapid re-expansion of the right lung.

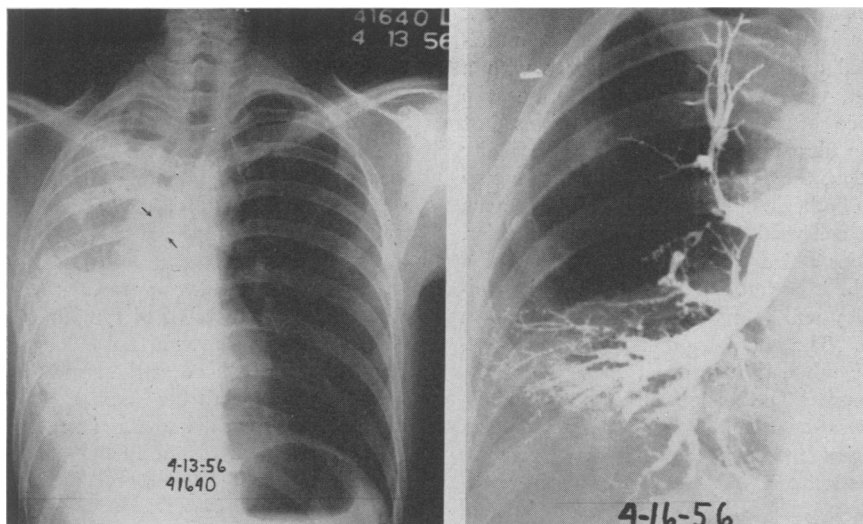


FIG. 15 (left). Case 3. April 13, 1956. After re-admission a bucky roentgenogram demonstrated an irregular narrowing of the right main bronchus just below the carina.

FIG. 16 (right). Case 3. April 16, 1956. A bronchogram confirmed the findings of Figure 15, when it revealed the marked narrowing of the right main stem bronchus.

and further discussion, see 3 and 15.) There are many cases of chronic atelectasis resulting from bronchial fracture. These patients have little difficulty because of the decrease in flow to the atelectatic lung. This decrease in pulmonary artery flow was not associated with the development of any significant bronchial collateral. The failure of collateral to develop despite a marked decrease in flow fails to support the contentions of Liebow *et al.*¹¹ regarding the physiologic importance of bronchial arterial hypertrophy.

The level of amputation of the bronchus was so high that the operator elected not to attempt repair. In most such instances repair probably should be carried out. Unfortunately, the restoration of bronchial continuity is not necessarily associated with return of normal function as demonstrated by Mahaffey *et al.*¹³ If function is limited, leading to poorly oxygenated blood flowing from a re-expanded lung as in Mahaffey's case, then the patient is better off with a resection. Following pneumonectomy the

arterial oxygens are normal and the patient has noted no dyspnea or other symptoms.

Case 3. This patient, a 23-year-old white male, was admitted to North Carolina Memorial Hospital on March 16, 1954. Four hours previously he had been driving an automobile at an estimated 25 mph., and during an attack of epilepsy he lost control of the car and struck a tree. The patient's only injury, except for a small laceration of the wrist, was a crushed chest. No information is available about the exact position of the patient in the car or whether the steering wheel or post was broken. Three other occupants of the car suffered lacerations and 2 children had fractures.

On admission the patient appeared acutely ill and in pain. X-rays revealed a moderate amount of subcutaneous air and some mediastinal air and fractures of the right second through sixth ribs. There were no left rib fractures.

Within an hour after admission, he developed a tension pneumothorax on the right and closed thoracostomy drainage was instituted (Fig. 13). The lung rapidly re-expanded. The patient did well although some subcutaneous and mediastinal air persisted. On the third hospital day the patient became acutely psychotic and was transferred to the psychiatric service. He remained there until discharge with no apparent pulmonary symptoms (Fig. 14).

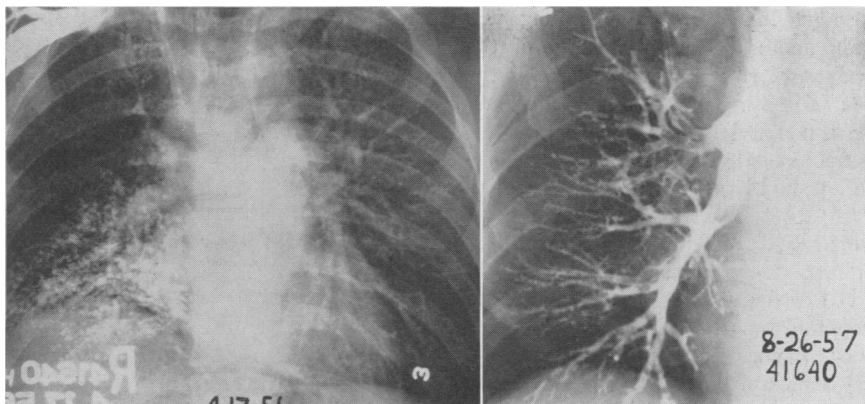


FIG. 17 (left). Case 3. April 17, 1957. A venous angiogram, which unfortunately followed the bronchogram, showed a marked relative difference in size between the right and left main pulmonary arteries and their peripheral branches.

FIG. 18 (right). Case 3. August 26, 1957. Bronchogram revealed the absence of stenosis at the operative site nine months after surgery.

On April 13, 1956, the patient was admitted again with a history of shortness of breath of 18 hrs. duration. The dyspnea was acute and was accompanied by severe pain in the right chest. There was dullness over the right chest and an x-ray revealed marked decrease in volume of the right thorax due to elevation of the diaphragm, narrowed rib spaces and mediastinal shift to the right. The right lung was very poorly aerated and there seemed to be pleural fluid present. A bucky film revealed an irregularity of the right main bronchus just below the carina (Fig. 15).

Three days later a bronchogram (Fig. 16) showed a narrowing of the right main stem bronchus to a width of .5 cm. just distal to the carina. Contrast material did enter the rest of the bronchial tree. The lower lobe was partially collapsed, and alteration in the position of the remaining bronchi was attributed to this.

An angiogram was made on April 17 (Fig. 17). The right main pulmonary artery was normal in size, but there was a marked decrease in the blood supply to the right lung. The peripheral pulmonary arteries on the left were somewhat dilated, tortuous and plethoric.

After these procedures were done, repair of the bronchus was carried out. There were extensive adhesions around the area of the right main stem bronchus and the hilar vessels. When the right main stem bronchus was exposed, an oblique fracture was found to extend from the base of the upper lobe bronchus to the carina. This area was excised and an end-to-end anastomosis was made with interrupted #40 stainless steel wire sutures.

The postoperative course was uncomplicated, and x-rays showed the lung to have re-expanded well.

Nine months after surgery the patient's x-rays appeared essentially normal. On August 26, 1957, bronchoscopy showed a normal tracheo-bronchial tree without stenosis. This was confirmed by bronchograms on the same date (Fig. 18). At the operative site the bronchus measured 1.9 cm.

Arterial oxygen saturation studies were performed and these are listed in Table 1.

Discussion: A late diagnosis was made in this patient because of the development of an acute psychosis. However, bronchial repair one month following injury seems to have restored this lung to normal. The oxygen saturation and x-ray studies confirm the apparently complete clinical recovery. This suggests that the duration of atelectasis may affect the ultimate function of the re-expanded lung following restoration of bronchial continuity.

Case 4. This 23-year-old white female was brought into the emergency room after she was found sitting in a wrecked automobile located in a ditch by the roadside. She had probably been in the car for several hours before she was found. There were extensive lacerations of the scalp and smaller ones of the chin and patella. There were contusions and a puncture wound in the lateral aspect of the right breast and a compound frac-

ture of the right humerus. The left lung was aerated poorly and there was instability of the right upper anterior ribs with crepitation of the tissues in this area. A roentgenogram of the chest (Fig. 19) revealed a large right pneumothorax, multiple rib fractures, displacement of the mediastinum to the left, and large amounts of subcutaneous air.

A #26 soft rubber catheter was used to establish closed thoracostomy drainage. The magnitude and persistence of the air leaks lead to the diagnosis of a ruptured bronchus.

Emergency thoracotomy was performed. A subsegmental branch of the pulmonary vein draining the anterior segment had been torn and the lateral surface of the middle lobe and the medial surface of the anterior segment of the upper lobe were lacerated. The pulmonary artery was isolated and retracted anteriorly to expose a stellate tear in the intermediate bronchus. This tear extended from a point 1 cm. below the upper lobe bronchus into both the middle lobe bronchus and the basilar bronchi of the lower lobe (Fig. 20).

The fragmented portion of the intermediate bronchus, about 1 cm., was resected. The extensions into the middle and basilar segments were sutured with interrupted #40 stainless steel wire and the same material used to re-anastomose the cut ends of the intermediate bronchus. Only a slight leak in the membranous portion of the bronchus remained after this had been done.

The fractures of the ribs were fixed with Kirschner wires used as intramedullary nails. The

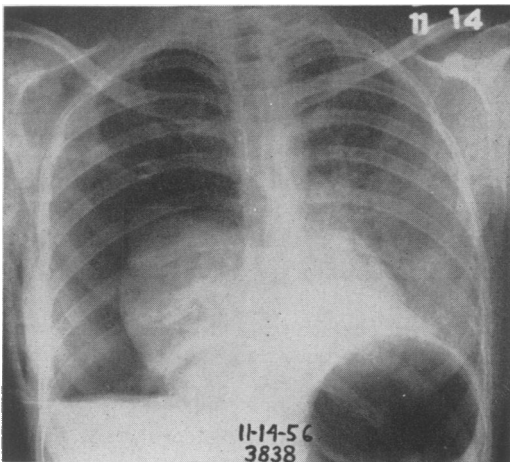


FIG. 19. Case 4. November 14, 1956. Roentgenograms immediately after admission showed the large right pneumothorax, multiple rib fractures, displacement of the mediastinum and a large amount of subcutaneous air.

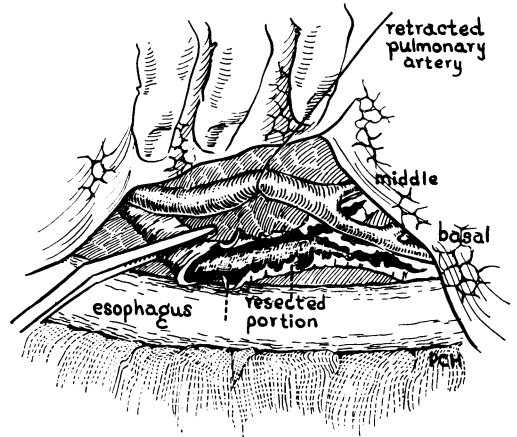


FIG. 20. Case 4. Drawing shows the character and extent of bronchial tear.

postoperative course was essentially benign and x-ray showed the right lung to expand rapidly and well (Fig. 21). The only difficulty encountered was as a result of the humeral fracture.

Seven months after the injury bronchoscopy revealed narrowing in the area of repair but the middle lobe orifice was not stenosed. Bronchograms at the same time showed slight narrowing of the intermediate bronchus, maximal just proximal to the take-off of the middle lobe bronchus. The latter was rotated slightly. Despite the narrowing there was good expansion and contraction of this portion of the bronchial tree (Fig. 22). Although filling of the distal portions of the middle and basilar segments was incomplete, no abnormality was noted in them. Oxygen saturations (Table 1) were normal.

In this patient the diagnosis was made on admission and despite extensive lacerations of the intermediate bronchus, repair was accomplished. Function is fully restored. The patient actually was more disabled by her humeral than her bronchial fracture.

Of particular interest is the anatomy of the laceration which could not conceivably have been due to a shearing force. It led us to postulate that these bronchi are exploded from within.

Review of the Literature

In the third part of this study all cases of traumatic bronchial rupture reported to 1956 were analyzed with special attention to kind of trauma, associated injuries and description of the bronchial injury. Table 2

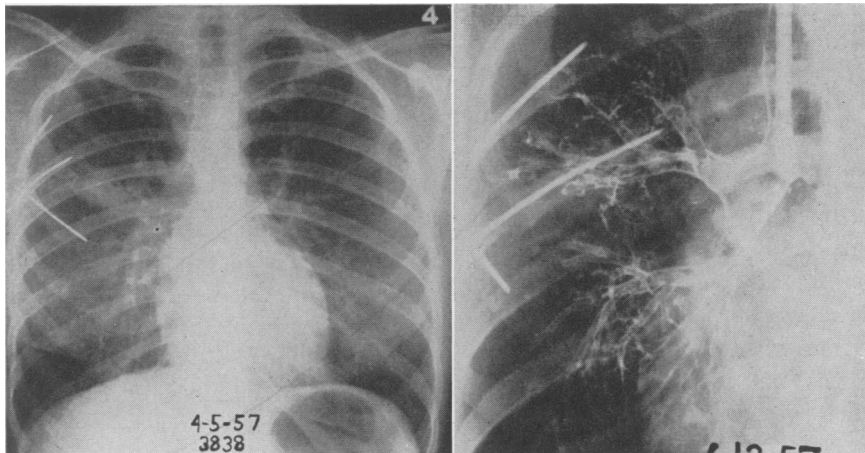


FIG. 21 (left). Case 4. April 5, 1957. Postoperative roentgenogram revealed the right lung to be normally expanded. Wires, used as intramedullary nails for fixing rib fractures, were seen.

FIG. 22 (right). Case 4. June 12, 1957. Bronchogram seven months after surgery revealed slight narrowing of the intermediate bronchus just proximal to the take-off of the middle lobe bronchus, but there was good expansion and contraction of the portion of the bronchial tree distal to this.

lists the age distribution, the manner in which the trauma was inflicted and the associated injuries. Table 3 lists the type of injury in each age group. "Runover" as here defined means that the wheel of a vehicle passed over the patient. Only a few of the cases will be cited in detail, since few authors adequately describe the type of injury to the patient, or the exact shape and extent of the tears in the bronchus.

The cliché used to describe the mechanism of injury is a "shearing force" produced by compression of the bronchus between the chest wall and the spine. Webster's unabridged dictionary defines shear:

Mech. Internal force tangential to the section on which it acts. . . . An action or stress resulting from applied forces, which causes or tends to cause two

TABLE 3. *Types of Bronchial Injuries*

R. Main Bronchus	L. Main Bronchus	R. Main Bronchus and Other Bronchi	L. Main Bronchus and Other Bronchi	Trachea	Trachea and Other Bronchi	R. Minor Bronchus	L. Minor Bronchus
Ages 0-10 years							
14	8	1	1	1	2	2	
Ages 11-20 years							
7	4	1	—	1	—	2	
Ages 21-30 years							
8	8	3	—	1	2	2	1
Over 30 years							
9	5	—	—	3	—	—	

contiguous parts of a body to slide relative to each other in a direction parallel to the place of contact.¹⁸

A "shearing force" is:

Mech. Either of a pair of equal opposed forces causing a shear.¹⁸

Case 4 made us question this theory of the mechanism of injury since the intermediate bronchus appeared to have been exploded from within by a high pressure. Whenever the nature of force could be determined it was a crushing one and not one due to sudden deceleration.

The most frequent site of associated injury in patients with bronchial rupture was the upper thorax. The bronchi were not sheared off transversely but revealed tears which were longitudinal as often as transverse. These facts can be well illustrated by reference to selected case reports.^{1, 4-9, 14, 16}

We postulate, therefore, that a crushing force occluded the trachea and acutely compressed the air within the tracheo-bronchial tree. The intrabronchial pressure became much greater than the intrathoracic pressure and this caused an explosive rupture of the bronchus.

Large bronchi burst rather than small ones because the force acting on the bronchial wall at any given intrabronchial pressure is greater in the large bronchi than in the smaller ones in accordance with well known physical laws. In addition, sudden increase in flow creates turbulence at each point of bifurcation which enhances peripheral resistance and tends to further raise the pressure in the large bronchi. The site of rupture will depend on the exact direction and nature of the compressing force and on the strength of the different areas of the bronchial wall. This may account for tears at bifurcations and at the juncture of membranous and cartilaginous portions of the bronchi.

This explanation has not been tested in

dogs experimentally since the mechanical force required is greater than is readily available in the laboratory. The use of the automobile for this purpose presents obvious practical problems.

Discussion

The question posed in the introduction concerning the nature and mechanism of the injury cannot be absolutely answered but an hypothesis is offered which seems better than attributing this injury to a shearing force.

In our cases early repair resulted in normal function. Little confirmatory information can be gained from the literature because no significant series of function studies are reported. The most valuable single study is an arterial oxygen saturation preferably done while the patient is breathing 100 per cent oxygen. If the normal 1.5 to 2 volumes per cent of dissolved oxygen are present, then no significant amount of unventilated lung is being perfused. This coupled with a normal pulmonary angiogram or bronchspirometry supports the presence of good function in the remaining lung. Our two patients with early repair both have normal oxygen saturations. Bronchspirometry and angiograms were not possible, so we can only say ventilation and perfusion are in equilibrium through the lung.

The arterial blood gas studies in the dogs and Case 2 show that in chronic atelectasis between 10 per cent and 20 per cent of the pulmonary blood flow goes to the unventilated lung as compared to a normal of 45 per cent to 55 per cent. The angiograms illustrate anatomically the decrease in flow calculated from the oxygen saturations. This decrease in flow effectively limits the development of significant arterial unsaturation. We could not persuade our second patient to repeat his exhaustive exercise, but it may well be that his acute

dyspnea was due to an acute increase in flow to the unventilated lung.

While it is hard to be certain how one can determine which lung may be expected to regain normal function following chronic atelectasis, it is not so difficult to say which ones will not. If there has been associated infection and the development of bronchiectasis and/or chronic suppuration, an increased bronchial arterial collateral will be encountered.^{11,12} This increased collateral is definite evidence of complicating suppuration or ischemia. The study of Case 2 and the experimental dogs¹⁵ demonstrates that this collateral will not be found in simple chronic atelectasis. Thus, if bronchial arterial collateral is present, the treatment of choice is resection not bronchial repair.

The ultimate function of the re-expanded lung following late repair of the bronchus cannot be ascertained from the available facts. Webb and Burford¹⁷ have determined the oxygen saturation of the inferior pulmonary vein in dogs which had had bronchial repair carried out following up to three to seven months of atelectasis. The lungs were artificially ventilated with air when the blood samples were obtained. All of the oxygen saturations were moderately depressed. Mahaffey *et al.*¹³ reported a patient who had the left main bronchus repaired 11 years after rupture. Six months later the man's arterial oxygen saturation was still depressed as was the oxygen uptake from the repaired lung. This means blood was passing through the lung without being oxygenated. This was due to perfusion of unventilated lung since the arterial desaturation persisted when 100 per cent oxygen was breathed. The degree of suppression of oxygen saturation is close to that present in our Case 2 before operation. Unfortunately, no preoperative oxygen saturations were obtained on Mahaffey's patient. These authors raise the question whether there is a shunt in the

unoperated or operated lung. The second patient reported here does support the contention that the shunt is in the normal lung, since following pneumonectomy his arterial oxygen saturations were normal. We know of no other reports of postoperative arterial oxygen saturations in this type of case. The failure to ventilate all of the perfused lung tissue in the re-expanded lungs may well be due to loss of elasticity. This would cause uneven ventilation. Webb could have missed this finding in his dogs because he used artificial ventilation. The determination of the arterial saturations in these patients while they breathe oxygen should answer this important question. Benfield *et al.*² produced bronchial stenosis in dogs and repaired the bronchi after 20 weeks of atelectasis. In these animals there was no evidence of perfusion of unventilated lung. However, the dogs apparently did not survive removal of the opposite lung. These findings were not completely reported but it was suggested that this was due to pulmonary vascular damages in the lung that had been chronically atelectatic. Until more such studies are made, there is no certainty that normal function can be restored and if it cannot, resection is probably the treatment of choice.

These problems of chronic atelectasis emphasize the importance of early repair, usually resulting in normal function. There are reports of late stenosis following repair, but these have been apparently less common where wire sutures were used rather than silk. In the two cases of repair reported here, wire was used with excellent results.

These patients offer interesting opportunities to study abnormal physiology of ventilation and perfusion and challenge the surgeon to preserve lung function.

Summary

Four cases of traumatic rupture of the bronchus have been presented. These cases

together with a review of the literature and some dog experiments have been used to illustrate the following points.

1. In the chronic atelectasis unassociated with infection there is a marked decrease in flow to the collapsed lung. No increase in bronchial arterial collateral occurs.

2. If there is increased bronchial collateral following rupture of a bronchus resection of the involved lung is indicated since infection has been present.

3. Following early repair of ruptured bronchus normal function ensues. Following chronic atelectasis the ultimate outcome is not certain.

4. The mechanism of injury is not a shearing force but a rupture of the bronchus due to increased intrabronchial pressure.

References

1. Barford, J. L.: A Case of Extensive Rupture of the Trachea with Complete Detachment of the Left Bronchus without External Injury. *Lancet*, 2:1509, 1906.
2. Benfield, J. R., R. W. Harrison, J. F. Perkins, Jr., G. P. Herman, E. T. Long and W. E. Adams: The Reversibility of Chronic Atelectasis. *Forum*, American College of Surgeons, 8:473, 1957.
3. Comroe, J. H., R. E. Forester, A. B. Dubois, W. A. Briscoe and E. Carlsen: *The Lung; Clinical Physiology and Pulmonary Function Tests*. Chicago, The Yearbook Publishers, 1955, p. 189.
4. Dagleish, H. D., G. M. T. Hazen and W. S. Kinnear: Traumatic Rupture of Bronchus in a Six Year Old Boy Treated by Pneumonec-tomy. *Canad. M. A. J.*, 70: 45, 1954.
5. Dark, J. and P. Jewsbury: Fracture of the Trachea and Bronchus. *Thorax*, 10:62, 1955.
6. Daughtry, D. C.: Discussion of paper by Paulson, D. L. and R. R. Shaw: Bronchial Anastomosis and Bronchoplastic Procedures in the Interest of Preservation of Lung Tissue. *J. Thoracic Surg.*, 29:238, 1955.
7. Henry, G. A.: Traumatic Rupture of the Lower Trachea with Stenosis. *Ann. Otol. Rhin. & Laryng.*, 61:1114, 1952.
8. Kinsella, T. J. and L. W. Johnsrud: Traumatic Rupture of the Bronchus. *J. Thoracic Surg.*, 16:571, 1947.
9. Kirkpatrick, E. R. G.: A Case of Traumatic Avulsion of a Main-Stem Bronchus from Its Lung, Treated by Immediate Pneumonec-tomy. *Brit. J. Surg.*, 37:362, 1950.
10. Liebow, A. A., M. R. Hales, G. E. Linds-kog and W. E. Bloomer: Plastic Demonstrations of Pulmonary Pathology. *Internat. A. M. Museums Bull.*, 27:116, 1947.
11. Liebow, A. A., M. R. Hales, W. Harrison, W. Bloomer and G. E. Linds-kog: The Genesis and Functional Implications of Collateral Circulation of the Lungs. *Yale J. Biol. & Med.*, 22:637, 1949-50.
12. Liebow, A. A., M. R. Hales and G. E. Linds-kog: Enlargement of the Bronchial Arteries, and Their Anastomoses with the Pulmonary Arteries in Bronchiectasis. *Am. J. Path.*, 25: 211, 1949.
13. Mahaffey, D. E., O. Creech, Jr., H. G. Boren and M. E. DeBaKey: Traumatic Rupture of the Left Main Bronchus Successfully Re-paired Eleven Years After Injury. *J. Thoracic Surg.*, 32:312, 1956.
14. Meade, R. H., Jr. and J. B. Graham: Rupture of a Primary Bronchus from Compression of the Thorax without Bone Injury. *Ann. Surg.*, 92:154, 1930.
15. Peters, R. M., W. E. Loring and W. H. Sprunt: An Experimental Study of the Ef-fect of Chronic Atelectasis on Pulmonary and Bronchial Blood Flow. To be published in *Circulation Research*.
16. Thompson, J. V. and E. R. Eaton: Intra-thoracic Rupture of the Trachea and Major Bronchi Due to Crushing Injury. *J. Thoracic Surg.*, 29:260, 1955.
17. Webb, W. R. and T. H. Burford: Studies of the Re-expanded Lung After Prolonged Atelectasis. *Arch. Surg.*, 66:801, 1953.
18. Webster's New International Dictionary of the English Language. Second edition un-abridged, Springfield, G. & C. Merriam Co., 1956, p. 2305.