

A Study of the Circulation in Normal Tendons and Healing Grafts *

ERLE E. PEACOCK, JR., M.D.

From the Department of Surgery, University of North Carolina School of Medicine, Chapel Hill, North Carolina

SUCCESSFUL REPAIR of tissue requires a precise knowledge of vascular channels and metabolic needs. Such knowledge usually is not considered important for fibrous tissues, presumably because respiratory and metabolic activity is small. Nevertheless, relatively acellular tissue such as tendons are living structures containing a few important cells, blood vessels, lymphatics, and collagen that is in a state of dynamic equilibrium with other body protein. Collagen in tendon deteriorates and is continually replaced; requires a lubricated gliding surface for normal function, and perhaps most important to the surgeon, can be successfully united with adjacent collagen under controlled conditions. Living cells and probably ground substances are responsible for dynamic functions. Even nonelastic transmission of force may require expenditure of energy but repair, lubrication, and healing are certainly vital functions requiring transformation of energy by properly nourished intra- and extracellular enzyme systems. If one thinks only in terms of tensile strength, blood supply is unimportant because tendons completely disconnected from the body are as strong for a while as tendons with normal vascular connections. Failure to achieve an adequate functional result, however, may be at least partly due to failure of the surgeon to think in terms other than restoration of a static cable. Tendon surgery designed to preserve physiology must consider blood supply; thus,

circulatory studies may be helpful even for a scantily vascularized structure. Recent enthusiasm for wrapping substances around tendon grafts to prevent postoperative adhesions particularly emphasizes a need for experimental data pertaining to vascular requirements of healing grafts.

During development, tendons are supplied with a rich capillary network (Fig. 1). Young tendons are quite cellular and require more nourishment than mature, relatively acellular ones. Older anatomists such as Kolliker stated that adult tendons have practically no blood supply, but subsequent interest in the problem and the application of injection technics have demonstrated a longitudinally orientated system of intrinsic vessels.¹ Mayer, in 1916, described blood vessels entering long flexor tendons by way of a volar mesotendon.² Bunnell called the disorganized system of vessels nourishing tendons that were not enclosed in a sheath, paratenon.³ Edwards, in 1946, studying normal tendons, and Braithwaite, investigating a human flexor tendon graft, visualized vessels inside tendons.^{4, 5} Edwards injected the intrinsic vessels with sodium nitroprusside-benzidine and was able to demonstrate a remarkably clear, longitudinally oriented vascular network. Unfortunately, after having demonstrated intrinsic vessels he accorded them no importance and finished his paper with a return to the old concept that tendons are static structures with little metabolic activity or vascular requirements. Braithwaite injected colloidal silver iodide solution into an amputated digit containing

* Submitted for publication May 9, 1958.

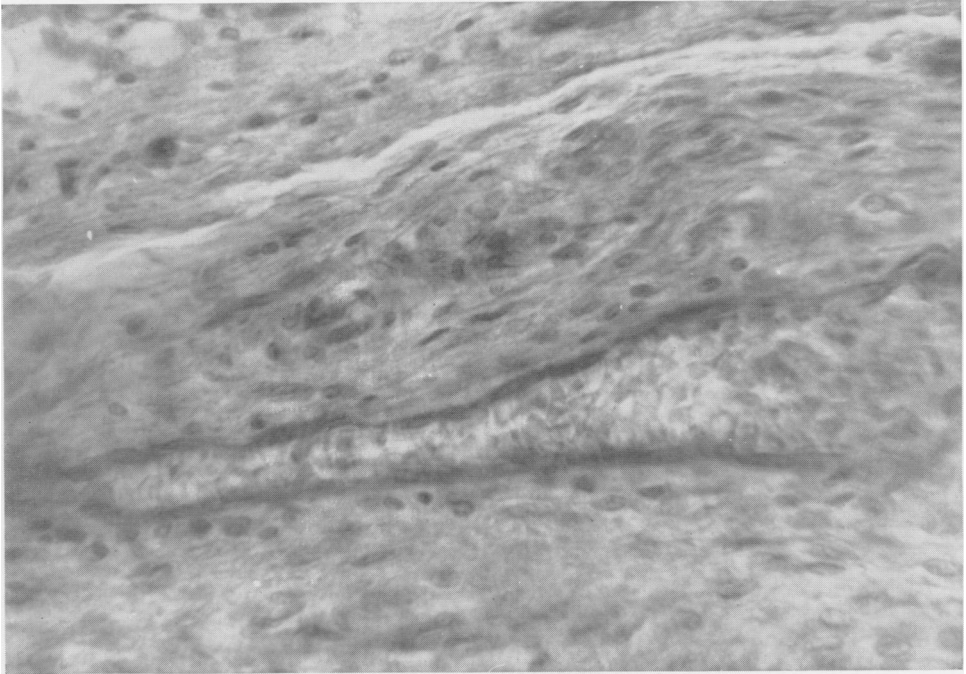


FIG. 1. High power magnification of an intrinsic blood vessel in the flexor profundus tendon of an 8 month embryo. (Courtesy of Dr. W. C. George, Department of Anatomy, University of North Carolina School of Medicine.)

an old flexor tendon graft and was able to demonstrate similar intrinsic vessels supplied by external vessels entering through fibrous adhesions.

Vessels enter tendons at the musculotendinous origin, the tendino-periosteal insertion, and along the longitudinal surface through a mesentery or paratenon. Anatomic demonstration of these vessels challenges the concept that tendons are non-viable cables and continuing enthusiasm to partially isolate grafts by artificial sheaths emphasizes the need for studying individual vessels in the ultimate fate of a graft.

Methods

Adult mongrel dogs were used because of the size of their tendons and similarity of blood supply to human tendons. The flexor digitorum profundus and the flexor digitorum sublimis muscles in the dog have long tendons which pass through fibrous sheaths over the carpus and into the digits.

On the dorsum of the manus, the extensor digiti tertii and quarti, the extensor digitorum communis and the extensor hallucis longus pass through fibrous sheaths in the region of the carpus. The extensor carpi ulnaris is a long, flat tendon nourished by paratenon similar to extensor tendons in human beings. Thus, the forearm of the dog provides tendons which are nourished by disorganized paratenon and tendons nourished by a well developed mesentery.

Four experiments were performed to evaluate individual groups of vessels and the effectiveness of intrinsic anastomosis. In the first experiment tendons were completely detached from the animal with the exception of the musculotendinous origin. The tendons were gently suspended above the wound so that the only vascular connections were those through the muscular origin (Fig. 2). Fine sutures were used to support the tendon just above the wound to prevent contamination by blood and

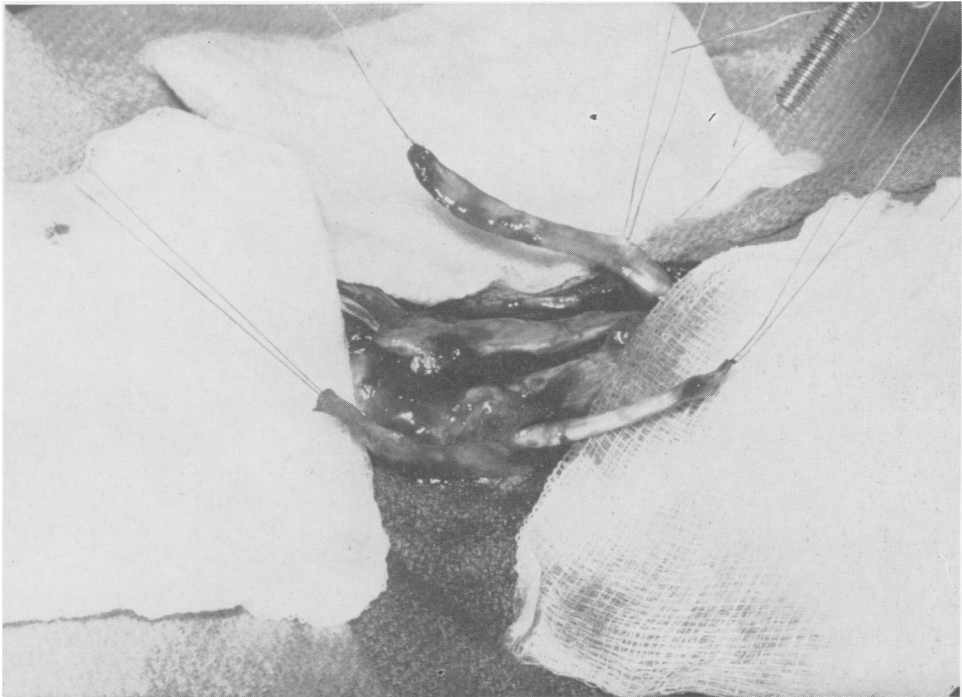


FIG. 2. The upper tendon is the flexor carpi ulnaris which has been suspended out of the wound so that it remains attached to the animal only by its muscular origin. The lower tendon is the flexor pollicis longus which can be seen passing through its fibrous sheath. Both the origin and insertion have been divided so that it remains attached to the dog only by a portion of the central mesentery.

transudates. To avoid kinking at the intact end and abnormal pressures in the vessels, the tendons were elevated only enough to clear the wound surface. A second experiment utilized a similar preparation except that the tendon was suspended only by its periosteal insertion. The third experiment was designed to evaluate central vessels entering through paratenon or mesentery by dividing both the origin and insertion thus leaving the tendon attached by its mesentery. The mesentery of sheath enclosed tendons is similar in development and structure to the mesentery of abdominal viscera. Tendon sheaths have parietal and visceral layers which are continuous with each other to form a ventral mesentery. Between the leaves of the mesentery, blood vessels connect the central intrinsic vessels of the tendon with the general circulation (Fig. 3). In this experiment the

tendon could not be elevated clear of the wound, so another tendon was completely detached and allowed to remain as a control for surface contamination. The difference between radio-activity in the unattached control tendon and the mesentery connected tendon was interpreted as the circulatory contribution of the mesentery. The fourth experiment was designed to evaluate blood supply entering through postoperative adhesions around free grafts. A free tendon graft was performed by excising a long tendon and replacing it in its original bed. End-to-end suture was accomplished with a buried silk technic at the proximal end. The graft was sutured to periosteum at its original insertion. In two weeks these grafts were examined and the origin and insertion divided so that they remained attached only by central fibrous adhesions.

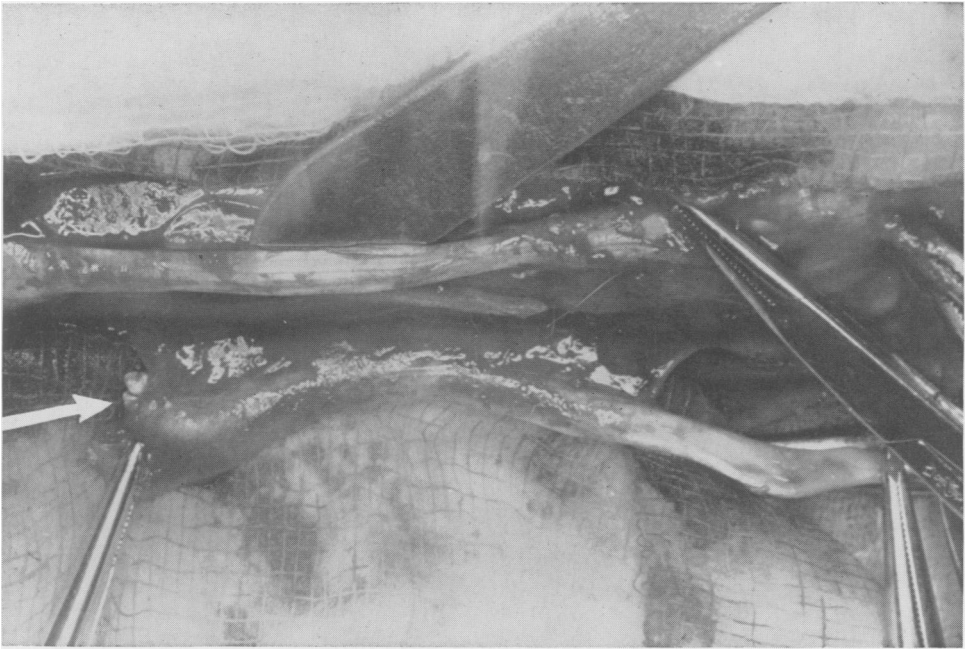


FIG. 3. Dissection of the flexor pollicis longus tendon to demonstrate the volar mesentery. The lower tendon has been detached and will remain free in the wound as a control for Experiment 3.

Following dissection, tendons were kept warm and moist for approximately 30 minutes to allow the circulation to recover from trauma of manipulation. Six microcuries/kilogram body weight of radioactive phosphorus (P^{32}) was injected into a hind leg vein and allowed to circulate for 20 minutes. The dose of phosphorus was also varied between six and 15 microcuries/kilogram and circulation times were extended to one hour with no significant difference in results. The tendons were removed and divided into 8 mm. segments which were analyzed for radioactivity in a utility scaler with a manual sample changer. Samples were not weighed because we were interested only in qualitative results. Either the specimen was significantly active above background count indicating an intact circulation or it was the same level as background activity indicating no effective circulation.

Further experiments were designed to show the morphological effect of occlusion

of central vessels. Polyvinyl tubes were split down one side and wrapped around tendons without disturbing either the origin or insertion (Fig. 4). These tubes were repaired with liquid vinyl forming circumferential sheaths extending the length of the tendons. The only blood supply to these tendons was from vessels entering the origin and insertion. The wounds were closed and at intervals of one, two, and three weeks the sheaths were opened and the tendons removed for study. In a final attempt to learn whether actual vascular connections were needed to nourish a tendon or whether a simple diffusion of gasses and nutrients would suffice, a metal ring was placed around the tendon and attached to long stainless steel wires extending through the skin (Fig. 5). The wounds were closed and daily the wires were pulled to advance the ring along the tendon severing new blood vessels and early adhesions. The small metal ring which served as a knife was polished to eliminate any rough

edges that might damage the tendon mechanically.

Results

1. *Intrinsic circulation through the musculotendinous origin.*

Graph No. 1 in Figure 6 depicts longitudinal spread of radioactivity in the long tendons. A background count of 34 was measured over a 30 minute period before any of the specimens were counted. In order to compare several tendons of different length on a single graft, the unit of longitudinal measurement is quarter lengths of the tendon. The longer the tendon the more 8 mm. specimens could be counted and the more points plotted per unit of tendon length. The longest tendon was the extensor digitorum communis measuring 7 to 9 cm. long. The shortest tendon was the flexor carpi ulnaris which was 4 to 6 cm. long. The variation in counts per minute per 8 mm. segment reflects the difference in diameter of different tendons. Three studies on different animals were made for each tendon and the average pattern of radioactivity is plotted for each. The significant




FIG. 4. Polyethylene sheaths, surrounding flexor tendons in the dog's forearm.

finding in all tendons was that radioactivity above background count was not found distal to the proximal one-third of the tendon. Phosphorus rapidly appeared in the prox-

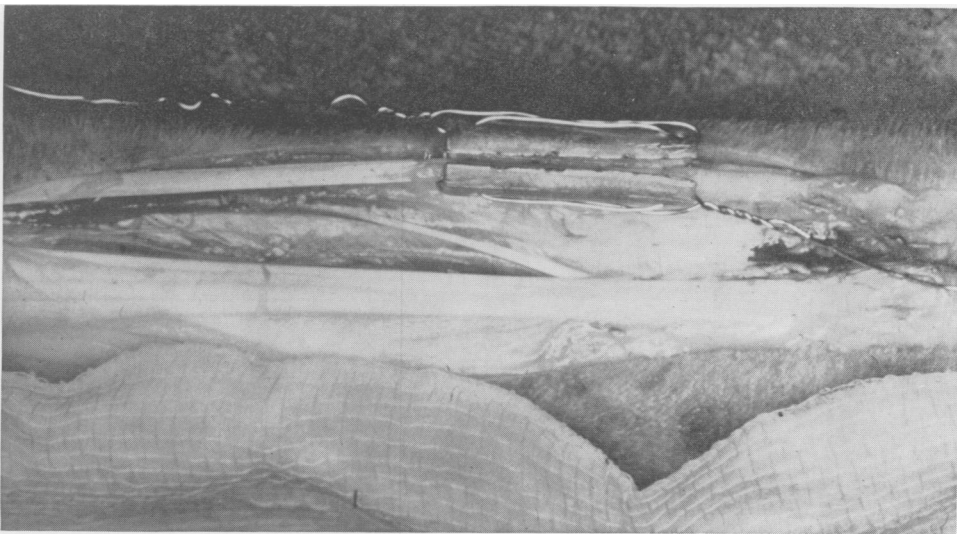


FIG. 5. The small steel cylinder has been slit to allow placement around a tendon with intact blood supply at each end. The slit will be closed and the wires brought through the skin at a distance from the incision.

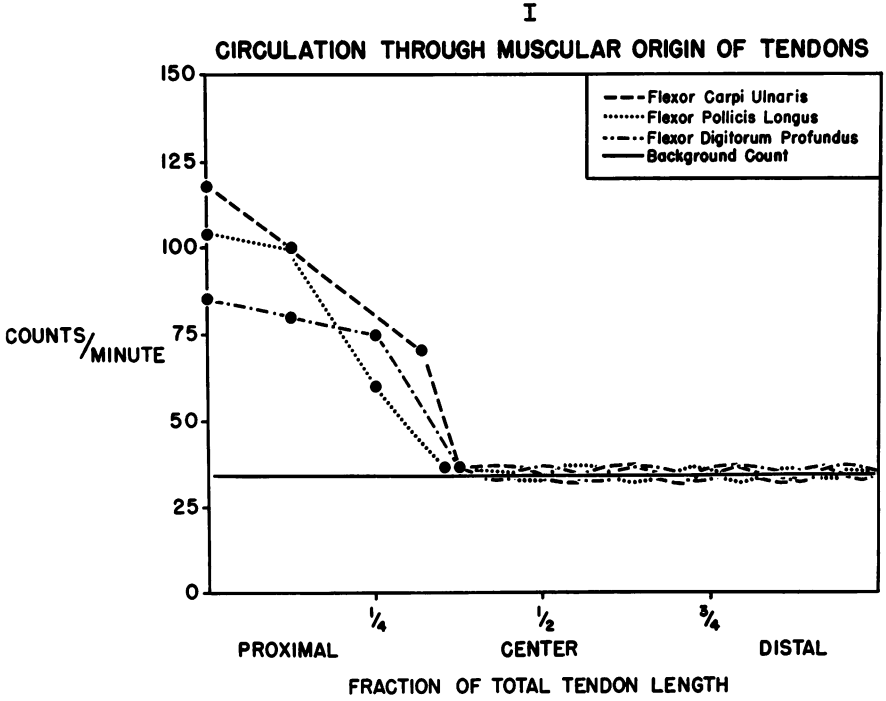


FIGURE 6

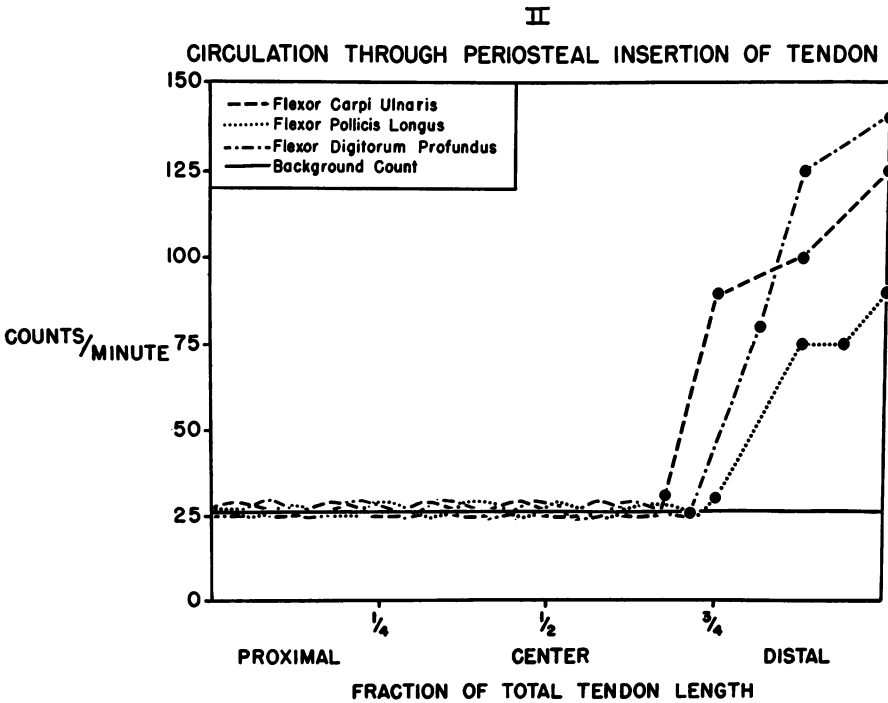


FIGURE 7

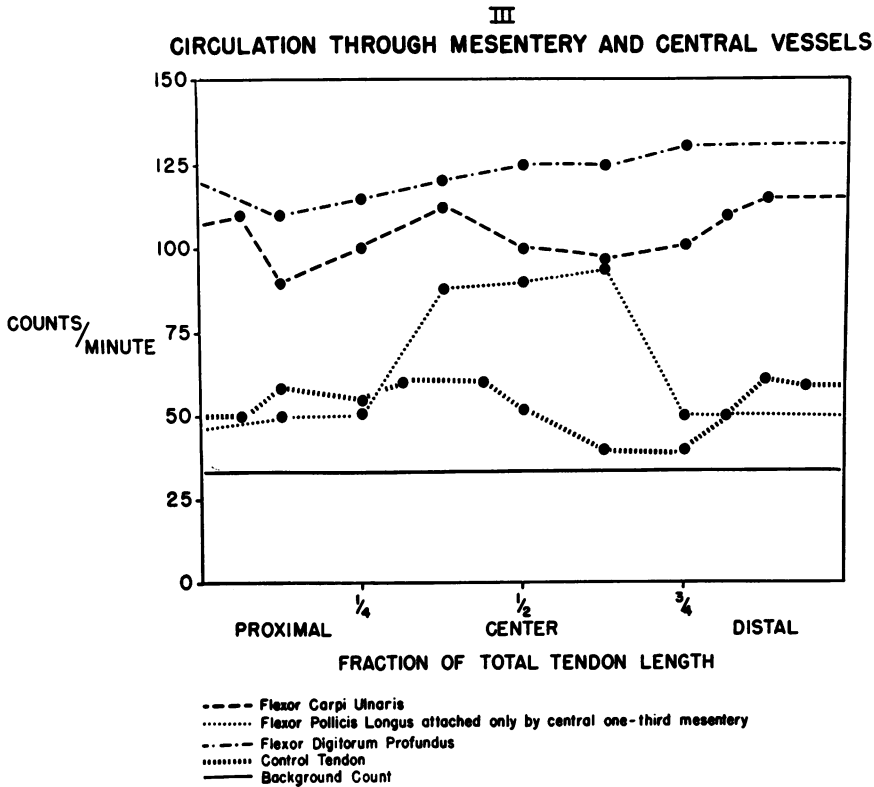


FIGURE 8

imal one-third, but irrespective of dose or time never reached the center or distal segments.

2. *Evaluation of intrinsic vessels entering through the tendinoperiosteal insertion.*

The same three tendons used in the first experiment were studied in different animals during the second experiment. Graft No. 2 in Figure 7 illustrates the spread of phosphorus³² through vessels entering by the periosteal insertion. Apparently these vessels are not as large or numerous as in the muscular end, for in only one of the preparations was phosphorus found proximal to the distal one-fourth of the tendon. The flexor carpi ulnaris consistently transmitted phosphorus farther than the others, presumably because of its short length and broad, flat insertion. The center of the tendon was never active above background count, however, indicating failure of perios-

teal vessels to circulate blood into the center of long tendons.

3. *Evaluation of the central vessels entering through paratenon and mesentery.*

Graft No. 3 in Figure 8 compares radioactivity in the same three tendons with free lying control tendons of same size from the opposite extremity. Radioactivity above background count in control tendons represents surface contamination by blood and serum. Although definitely radioactive, the central tendons were still much less active than tendons attached by central vessels. The difference between these counts is interpreted as due to phosphorus³² transmitted by an intact mesentery. Even distribution of radioactivity throughout the entire tendon suggests ample distribution of central blood vessels connecting the general circulation with intrinsic vessels. A slight variation of this experiment was per-

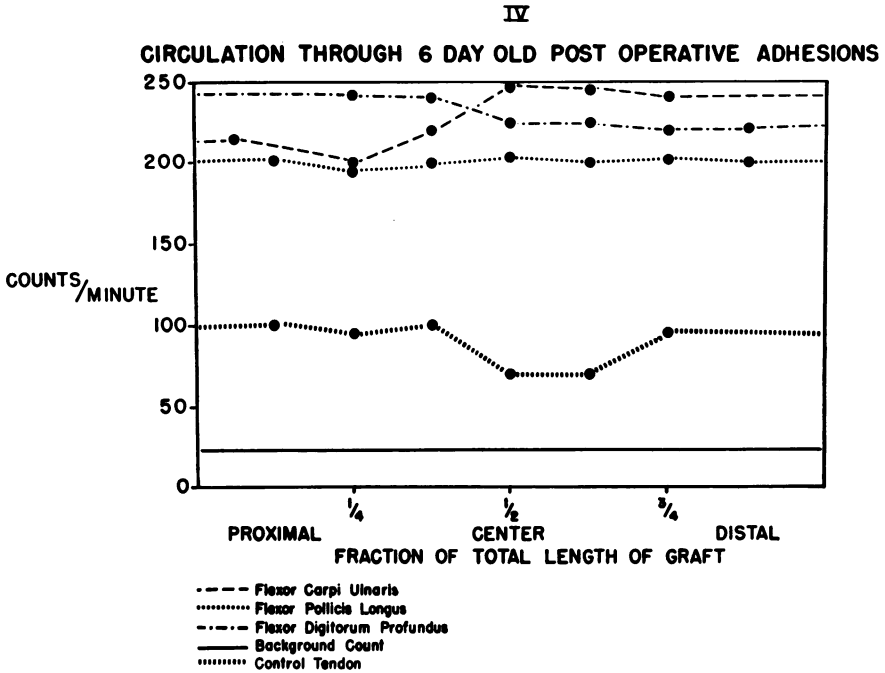


FIGURE 9

formed by dividing all of the mesentery except the portion nourishing the central third of the tendon. The dotted line on graph 3 plots radioactivity in this tendon, and again there is minimal longitudinal circulation as phosphorus is present only in the area opposite intact vessels.

4. Evaluation of circulation in postoperative adhesions.

Graph 4 in Figure 9 shows the same general pattern as experiment three with all counts being considerably higher. Since control tendons and background counts are the same as the previous experiment, elevated counts in the grafts suggest a profuse vascular network during healing and maturation. Increased vascularity probably diminishes with maturation of grafts just as blood supply to embryonic tendon decreases with maturity.

In the second group of experiments, where tendons were denied central vascular attachments, the polyvinyl sheaths did not cause visible soft tissue reaction. Unless in-

fection supervened, in which case the animal was sacrificed, soft tissues healed without complications. Exploration of artificially sheathed tendons was performed at one, two, and three week intervals. When the plastic tube was removed after one week, the tendon appeared practically normal by gross inspection. A thin film of fibrin on the surface was occasionally noted, but after this was removed the tendon appeared normal. A rough estimation of tensile strength seemed normal. On microscopic examination the tendon showed a normal pattern of collagen and fibroblasts (Fig. 10). At two and three weeks the tendon was pearly white or dark grey in the center and after fibrin was removed the surface remained dull compared to the glistening surface of normal tendons. Even more impressive was the marked change in cohesiveness of longitudinal fasciculi. Although tendons still showed fairly good longitudinal strength, the fibrous bundles literally fell apart when subjected to horizontal cross-sectional stress.

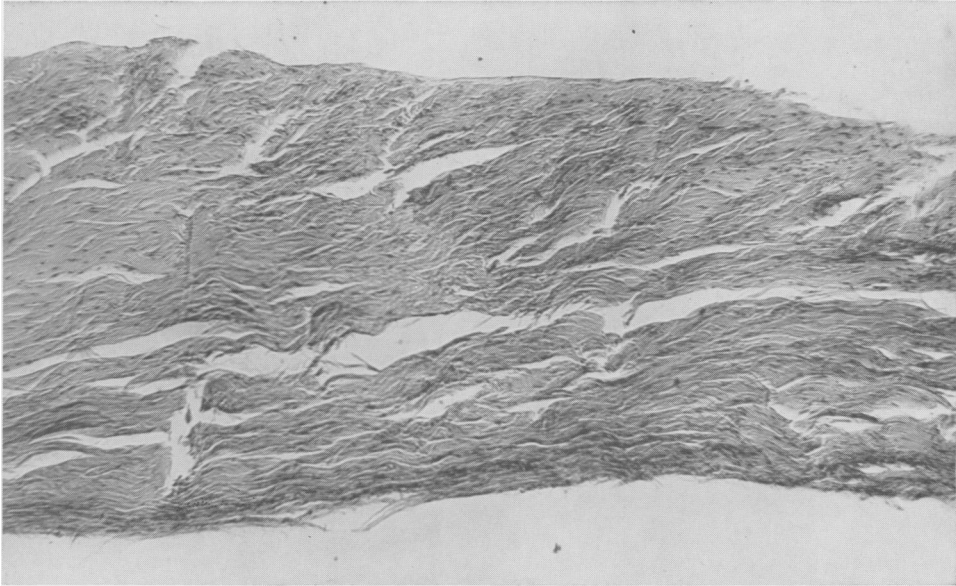


FIG. 10. Medium magnification of the central portion of a tendon surrounded by a plastic sheath for one week. Although the cellular pattern is fairly normal there is a suggestion of lack of cohesiveness between collagen bundles.

Sutures in this segment of the tendon pulled through the collagenous bundles with ease so that repair would have been extremely weak. At three weeks the tendon was distended with fluid and dark in color, resembling an amorphous jell, although individual collagen bundles could be found intact (Fig. 11). Microscopic examination revealed complete acellularity (Fig. 12). Considerable inflammatory reaction was present in the ends of tendon adjacent to the necrotic area but bacterial cultures from these areas were sterile (Fig. 13). Surrounding tissues were not inflamed, having tolerated the artificial sheath with amazingly little reaction. Therefore, we believe that the changes in the center of artificially ensheathed tendons are secondary to ischemia.

The final experiment, daily lysis of new adhesions, was designed to evaluate diffusion as a means of nourishing the center of tendons which were prevented from developing vascular connections. Severe inflammation and frank suppuration spoiled every

attempt to control this experiment so that results would be meaningful. In every instance the center of the tendon underwent similar changes as in the preceding experiment, but suppurative complications pre-

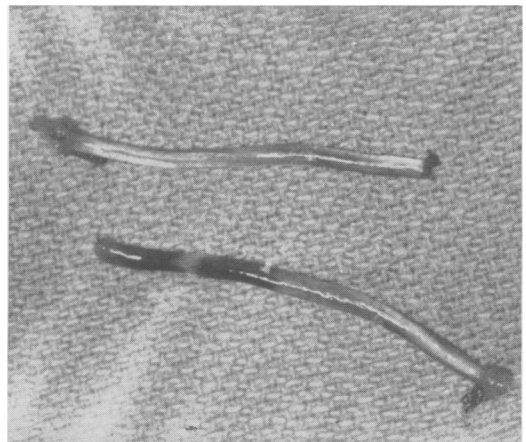


FIG. 11. Same tendons shown in Figure 4 three weeks later. The upper tendon was a graft which failed to heal at one end (dark end) and separated from the periosteum. The lower tendon had intact circulation at the ends and shows early necrosis in the center.

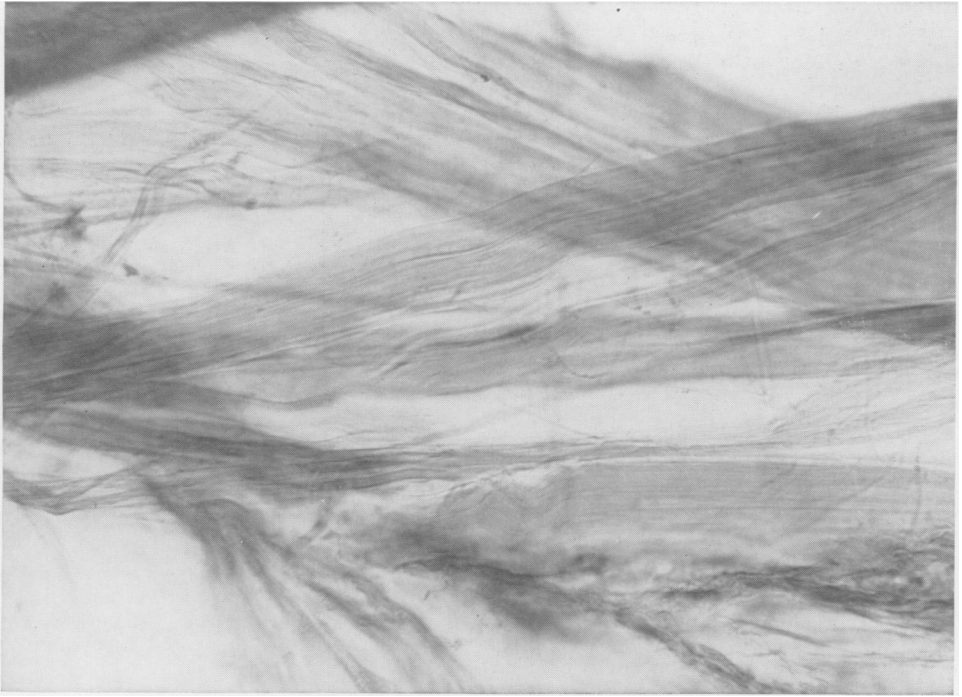


FIG. 12. High magnification of tendon shown in Figure 11. Note complete acellularity and fragmented collagen.

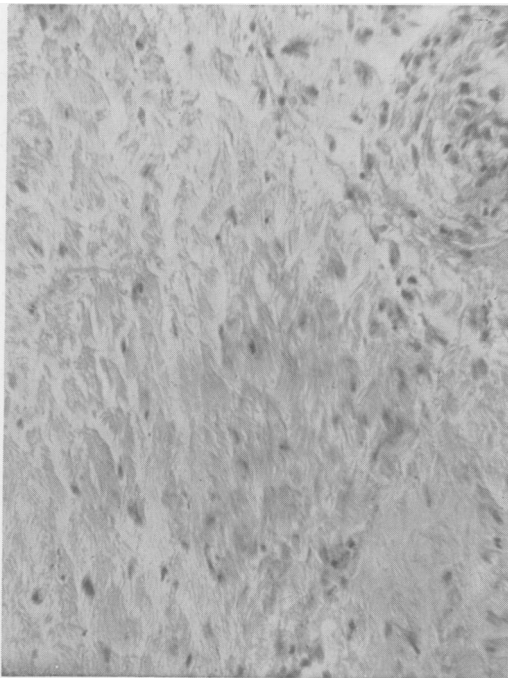


FIG. 13. Photomicrograph showing mild inflammatory reaction in the ends of same tendon shown in Figure 11. Cultures of the tissue and wound were sterile.

vented drawing any conclusions about the effect of pure ischemia (Fig. 14, 15). Infection with its altered pH, abnormal enzyme activity, and marked cellular proliferation is known to cause necrosis in tendons quite apart from any local vascular disturbances. Antibiotics, clean dressings, long draw wires, and several different materials for the cutting ring were tried in unsuccessful attempts to eliminate infection. The external wires could not be kept sterile indefinitely, however, and undoubtedly carried virulent bacteria into an area of mechanical irritation. No valid conclusions on the effect of vascular insufficiency could be made under such circumstances.

Discussion

During the past decade, skin, arteries, veins, plastics, and allantoic and amnionic membrane have been proposed as suitable substances to wrap around flexor tendon grafts to prevent fibrous adhesions. Al-

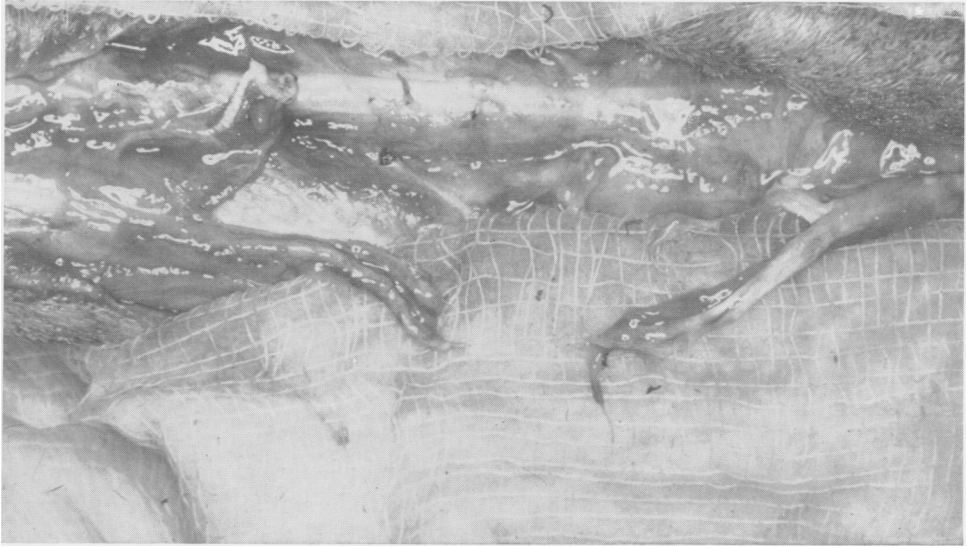


FIG. 14. Photograph of same tendon shown in Figure 5 three weeks later. Pus was found around the tendon and cultures were positive for coloform organisms.

though a few artificial sheaths mimic the gliding surface of a digital tendon sheath, all lack one important item, vascular connections between the systemic circulation and the intrinsic vessels of the tendon. Our experiments were designed to determine the importance of central mesenteric vessels or their counterpart in postoperative adhesions. Only if the intrinsic vessels entering from either end can satisfactorily nourish the entire length of a tendon or if the metabolic requirements of tendon are so small that simple diffusion of gasses and nutrients will suffice, is further research for artificial sheaths likely to be rewarding.

Evidence obtained by using P^{32} as an indicator suggests that longitudinal circulation through intrinsic vessels is nonexistent for distances greater than one-third their length. During early development, intrinsic circulation is profuse, but organization of internal structure is accompanied by such drastic reduction in intrinsic circulation as to make it completely undependable when grafting adult tendons. The centrally located vessels entering through a mesentery or paratenon appear to be of vital impor-

tance and in the case of free grafts are reformed in fibrous adhesions.

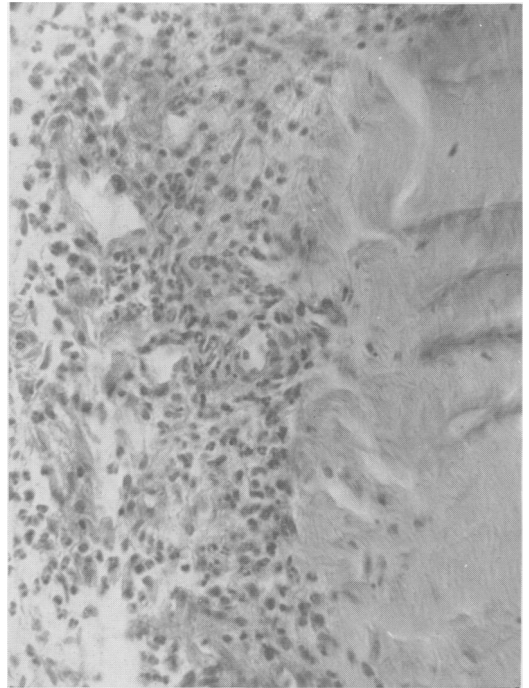


FIG. 15. Photomicrograph of same tendon shown in Figure 14 to show marked suppurative necrosis.

There is other evidence that circulation to the center of tendons is purposeful. Newberger and Slack have measured a small but definite turnover of amino acids in the collagen of adult tendons.¹⁴ Carbon 14 labeled glycine was administered to rats and traced into the molecular configuration of mature tendon collagen. This is not surprising, for nowhere else in the body are amino acids permanently fixed and the dynamic state of protein as described by Schoenheimer undoubtedly includes tendons as well as other supporting structures.¹⁶ The relatively stable collagen molecule with its slow carbon atom exchange probably accounts for the long delay before longitudinal strength alterations are apparent in collagen bundles. Nevertheless, cellular death, abnormal swelling, and loss of a smooth glistening outer surface follow ischemia and are important in over-all function.

Since respiratory quotients for tendon are not available in standard tables, we subjected human flexor and extensor tendons to this analysis in the Warburg apparatus. In as yet unpublished experiments we found respiratory activity to be extremely low (0.1 microliter per unit weight per hour). Compared to more active tissues such as liver or retina, these values are not striking, but they are definite and provide functional significance for Edwards' anatomic demonstration of blood vessels to tendons. Although there are relatively few cells in mature tendon, they have a measurable metabolism and require an intact circulation to survive. Apparently cellular death is followed by gradual collagenous disintegration resulting in absorption and replacement by disorganized cicatrix.

We postulate that free tendon grafts heal somewhat like free split-thickness skin grafts. Because of a low metabolic rate they are able to survive a few days by diffusion of gasses and nutrients from surrounding tissue. For ultimate survival, however, particularly with preservation of a gliding sur-

face, actual vascular connections with the host are necessary. Vessels entering at either end are unable to nourish the center of the graft and this area becomes vascularized through fibrous adhesions. Deep scarring is apparently variable just as superficial scarring varies in amount and consistency between individuals. The adhesions in some patients apparently attenuate and elongate to permit a satisfactory range of motion. Other patients, regardless of how industrious they may have been during the postoperative period or how precisely the operation was performed, do not regain function and when re-explored the graft is hopelessly incarcerated in a dense fibrous cicatrix. These patients may be comparable to superficial hypertrophic scar formers following surface restorations. In our experiments, complete prevention of adhesions by mechanical barrier resulted in death of cells in the center of tendons and eventual disintegration of collagen bundles.

Most experienced surgeons feel that early motion has no place in the postoperative management of tendon grafts. The prevention of adhesions by motion may jeopardize the ultimate survival of a graft by depriving important cells of adequate circulation during a healing phase. There is no evidence to support this, but on two occasions the author has been impressed with complete replacement of a tendon graft by disorganized cicatrix when uncontrolled motion was permitted during the healing period (Fig. 16).

It is difficult to evaluate occasional reports of success following the application of artificial sheaths to fresh tendon grafts.⁹⁻¹⁹ Some may be explained on failure to isolate completely the tendon as when membranes are sutured circumferentially around a graft. Any disruption of the suture line or opening between sutures allows vessels to penetrate to the graft. Homogenous membranes or autogenous connective tissue may be absorbed before the tendon is irreparably damaged. Tendons threaded through

intact artery and vein grafts have been reported to function, yet if one were to pick cells known to stand very little trauma without inflammation and scarring, endothelium would probably head the list. The same reasoning holds for peritoneum which occasionally is recommended for this purpose. Some tendons may survive in spite of artificial sheaths because the sheath is only a small pulley or does not surround a length of tendon too long for intrinsic vessels to nourish. The actual distance of the necrosis may be so short that fibrous scarring still permits transmission of adequate power for limited motion. A similar reaction was occasionally seen in the short extensor carpi ulnaris tendon of dogs. It is important to remember, however, that the healing between tendon ends is possible only by ingrowth of surrounding young connective tissue and if this is successfully prevented by a mechanical barrier, healing between tendon ends will be impossible. With the knowledge that ingrowth of connective tissue is necessary for end-to-end healing and that tendon adhesions appear to carry vessels of vital importance, it appears that investigation and eventual control of the maturation and attenuation of fibrous tissue is more likely to relieve the uncertainty of digital sheath tendon repair than attempts to completely prevent adhesions by unselective mechanical barriers. Another solution to this problem may be to control the location of adhesions so that nourishment is provided without restriction of motion. With this in mind, we have been experimenting with a composite tissue graft of the entire flexor mechanism surrounded by its intact sheath. Theoretical advantages of such a graft are that transfer of tendons, mesentery, vincula, and sheath as a unit will cause adhesions to form between the host and the sheath instead of the recipient bed and the tendon. Revascularization of the tendon would then occur through a normal mesentery leaving the gliding surface between sheath and tendon unviolated. The

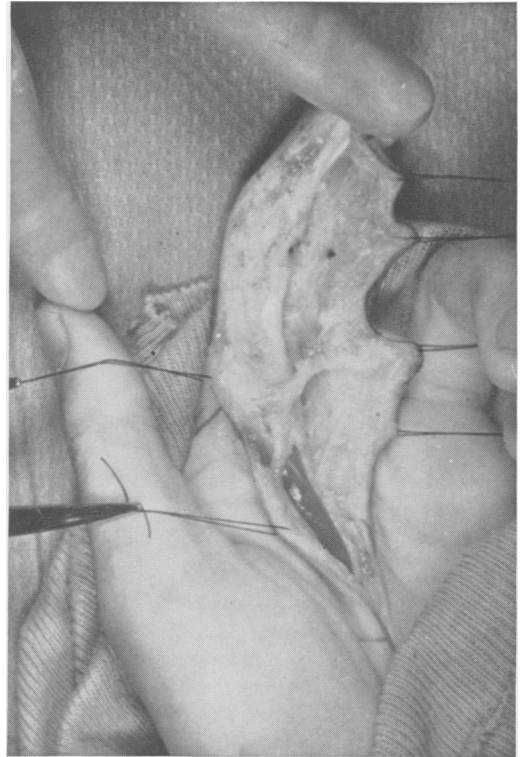


FIG. 16. Operative photograph during exploration of a flexor tendon graft which failed to function following a period of forced early motion. The graft could not be identified and apparently had been replaced by disorganized fibrous tissue.

details of experiments using heterografts in dogs and the account of a successful human homograft of this type are reported in greater detail in another paper.

Summary and Conclusions

1. Blood vessels entering long tendons from the muscular origin and periosteal insertion are able to nourish only the proximal and distal third of the tendon.
2. The intrinsic vessels in long tendons are not capable of nourishing the central third by anastomosis with vessels entering from either end.
3. Circulation to the central third of long tendons is by intermediate segmental vessels entering through disorganized paratenon or a definite volar mesentery. In free grafts this portion of the circulation is restored through postoperative adhesions.

4. Permanent disruption of the central blood vessels to normal tendon or mechanical prevention of postoperative adhesions around free grafts causes cellular death and eventual disintegration of collagen bundles.

5. On the basis of vascular studies a further search for some material to wrap around tendon grafts does not appear likely to be rewarding as the development of post-operative adhesions seems to be a normal process of wound healing necessary for the restoration of adequate blood supply to the graft. Successful shielding of the graft by mechanical barrier produced central necrosis and failure of healing in our experiments.

Bibliography

1. Bowen, Arthur: Development and Surgical Application of an Absorbable Tubular Membrane. *Am. J. Surg.*, 34:122, 1936.
2. Braithwaite, F. and J. G. Brockes: The Vascularisation of a Tendon Graft. *Brit. J. of Plastic Surg.*, 4:130-135, 1951.
3. Bunnell, S.: *Surgery of the Hand*. Philadelphia, J. B. Lippincott Co., 1944, p. 277.
4. Chas, Y. C., S. Humphreys and W. Penfield: *Brit. Med. J.*, 1940, 517.
5. Davis, Loyal and Leon J. Aries: An Experimental Study Upon the Prevention of Adhesions About Repaired Nerves and Tendons. *Surg.*, 2:877, 1937.
6. Edwards, D. A. W.: The Blood Supply and Lymphatic Drainage of Tendons. *J. Anat.*, 80:147, 1946.
7. Gonzales, R.: Experimental Tendon Repair Within the Flexor Tunnel: Use of Polyethylene Tubes for Improvement of Functional Results in the Dog. *Surgery*, 26:181, 1949.
8. Gueukdjian, S. A.: A New Method of Cannulizing Tendon Sutures with Vein Grafts. *Arch. Surg.*, 73:1018, 1956.
9. Ham, A. W.: *Histology*. Philadelphia, J. B. Lippincott Co., 1953, p. 201.
10. Kölliker, A. von: *Mikroskopische Anatomic oder Gewebelehre des menschen*. Leipzig: W. Engelmann (1850).
11. Mayer, L.: Technique of Tendon Transfer. *Surg., Gynec. & Obst.*, 22:182, 1916.
12. Mayer, Leo and N. Ransohoff: Reconstruction of the Digital Tendon Sheath. *J. Bone and Joint Surg.*, 18:607, 1936.
13. McGee, G. K.: Metal Anastomosis Tubes in Tendon Suture. *Lancet*, 1:659, 1945.
14. Neuberger, A. and H. G. B. Slack: The Metabolism of Collagen. *Biochem. J.*, 53:47, 1953.
15. Pinkerton, M. C.: Amnioplastin for Adherent Digital Flexor Tendons. *Lancet*, 242:70, 1942.
16. Schoenheimer, R.: *The Dynamic State of Body Constituents*. Harvard University Press, 1946, p. 25-46.
17. Thatcher, H. Z.: The Use of Stainless Steel Wires to Cannulize Flexor Tendon Sheaths. *South. Med. J.*, 32:13, 1939.
18. Whelden, T. F.: The Use of Cellophane as a Permanent Tendon Sheath. 21:393, 1939.
19. Willmost, C. L.: Tendoplasty of Flexor Tendons of the Hand: Use of Tunica Vaginalis in Reconstructing Tendon Sheaths. *J. of Bone and Joint Surg.*, 19:152, 1937.