

Proliferation and transepithelial migration of mucosal mast cells in interstitial cystitis

F. ALDENBORG,* M. FALL† & L. ENERBÄCK* *Departments of *Pathology and †Urology, University of Göteborg, Sahlgrenska Hospital, Göteborg, Sweden*

Accepted for publication 10 March 1986

SUMMARY

The distribution and abundance of mast cells, as well as their fixation, staining and ultrastructural properties, were studied in the urinary bladders of 16 patients with interstitial cystitis (IC) and in 14 normal subjects. Tissues were fixed in both standard formaldehyde solution and a special fixative, IFAA, optimized for the preservation of mucosal mast cells. An expansion of two distinct mast cell populations was observed in IC. One of these, comprising formaldehyde-sensitive cells, was found only in the mucosa underlying lesions of IC. They were most numerous in the lamina propria but were also frequent in the epithelial layer as well as in the bladder washings, indicating a migratory capacity for these cells. The other mast cell population was visualized equally well irrespective of fixation and staining procedure. In control subjects, such cells were found both in the lamina propria and detrusor muscle, but not in the epithelium nor in bladder washings. In lesions of IC they were increased in the detrusor muscle only. Both types of mast cell contained granules with the highly characteristic lamellar arrays and scrolls, distinguishing human mast cell granules from those of blood basophils. The proliferation and intraepithelial distribution of mucosal mast cells are unusual findings, but prominent features of helminth responses and human mucosal allergic reactions. These findings thus suggest that the mucosal mast cell-IgE system may be involved in the pathogenesis and/or aetiology of IC.

INTRODUCTION

Interstitial cystitis (IC), Hunner's ulcer, is a chronic disabling inflammatory disorder of the urinary bladder, primarily affecting women (Hunner, 1915; Hand, 1949). Its aetiology and pathogenesis are unknown. Infections are probably not of aetiological significance (Hanash & Pool, 1970; Hedelin *et al.*, 1983; Fall, Johansson & Vahlne, 1985), but immune responses and autoimmunity have been implicated because of the finding of immunoglobulin and complement deposits in the bladders in IC (Mattila, 1982).

Drug hypersensitivity and allergic Type I reactions are prevalent in patients with IC (Hand, 1949; Oravisto, 1980; Rosin *et al.*, 1979). Observations of increased eosinophil cationic protein in sera and urine (Lose *et al.*, 1983), and of an involvement of the mast cell system (Rebuck *et al.*, 1963; Smith & Dehner, 1972; Larsen *et al.*, 1982; Kastrup *et al.*, 1983), are in line with this. These observations include the finding of an emigration of mast cells/basophils by the skin window technique, and of high mast cell numbers in the bladder musculature. The constancy of the latter finding has led to the suggestion that a mast cell density in the detrusor muscle above

a certain limit may be used as a diagnostic criterion of IC (Kastrup *et al.*, 1983).

Mucous membranes contain mast cells that appear to be structurally, biochemically, and functionally distinct from the mast cells found in most other tissues (Enerbäck, 1985). Mucosal mast cells respond by proliferation and intraepithelial migration in the intestine (Miller & Jarrett, 1971) and probably also in the urinary bladder (Kirkman, 1950) of rats infected with certain nematodes. These reactions are accompanied by a strong activation of the IgE immune system (Jarrett & Miller, 1982). A similar intraepithelial migration of mucosal mast cells has also been observed in human nasal allergic reactions (see Enerbäck, Pipkorn & Granerus, 1986).

The demonstration of mucosal mast cells is markedly dependent on the fixation and staining technique (Enerbäck, 1966; Strobel, Miller & Ferguson, 1981; Ruitenbergh *et al.*, 1982). Aldehyde fixatives block specific dye-binding sites of mucosal mast cell granules by fixation of structurally associated protein (Wingren & Enerbäck, 1983). This blocking may be overcome by the use of very long staining times (Wingren & Enerbäck, 1983) or by the use of special fixatives, such as an iso-osmotic mixture of 0.6% formaldehyde in 0.5% acetic acid (IFAA) (Enerbäck, 1966). These specific histochemical properties may be used to identify mucosal mast cells in the tissues.

In view of the apparent involvement of the mast cell system

Correspondence: Professor L. Enerbäck, Dept. of Pathology, University of Göteborg, Sahlgrenska Hospital, S-413 45 Göteborg, Sweden.

in IC, we have examined the distribution, density, and histochemical properties of these cells using techniques optimized for the preservation of mucosal mast cells. We now present evidence of an increase of a second mast cell population in IC, with the histochemical properties of mucosal mast cells. These cells are numerous in the lamina propria but are also frequent in the bladder epithelium and in bladder washings. The findings indicate that a transepithelial migration of mucosal mast cells is a distinctive feature of IC, like in the nematode response of rodents and in human nasal allergy, suggesting that the mucosal mast cell-IgE system may be involved in the pathogenesis or aetiology of IC.

PATIENTS AND METHODS

Sixteen patients with IC were studied, 15 women and 1 man, aged 49–85 years (mean age 66 years). The duration of symptoms was 1–30 years (mean 7 years). The patients presented with marked frequency of urination and continuous or intermittent suprapubic, abdominal or urethral pain, sometimes radiating, and decreased or relieved by voiding. Cystoscopy, involving distension of the bladder at a hydrostatic pressure of 70 cm water, revealed oedematous, reddened areas with small ulcers or cracks in the mucosa and punctate haemorrhages with oozing of blood. Patients only displaying punctate haemorrhages after distention were excluded from the study. Fourteen women (mean age 49) with stress incontinence or vesico-urethral reflux, with normal cystoscopy findings and no irritative bladder symptoms served as controls. Urine cultures were negative in all the subjects investigated.

Informed consent was obtained from all the patients taking part in the study, which was approved by the Ethics Committee of the University of Göteborg.

Tissue specimens

Material for histological examination was obtained by transurethral electroresection with a minimum of coagulation from all visible bladder lesions and from areas appearing cystoscopically normal. Care was taken to obtain strips of mucosa including detrusor muscle.

Fixation, tissue processing and staining

Specimens were frozen and stored at -70° until analysed for histamine content. Specimens for light microscopy were fixed in 4% buffered formaldehyde (FA) for 1–2 days or in a mixture of 0.6% formaldehyde and 0.5% acetic acid (IFAA) for 12 hr, followed by immersion in 70% ethanol for 12 hr. Five μ m sections of paraffin-embedded tissue were stained with toluidine blue at pH 0.5 (dye dissolved in 0.5 M HCl) for the specific visualization of mast cells. The staining time was 30 min for IFAA- and FA-fixed material. FA-fixed sections were also stained for 5 days in toluidine blue at pH 0.5 (long toluidine blue staining; Wingren & Enerbäck, 1983). Haematoxylin and eosin staining was used for general evaluation of tissue morphology. The specimens for electron microscopy were fixed in 2.5% glutaraldehyde in 0.1 M cacodylate buffer at pH 7.4 for 2–24 hr and rinsed in 4% sucrose in 0.1 M cacodylate buffer. Postfixation was done in 1% OsO₄ in 0.1 M cacodylate buffer for 2 hr. The specimens were then dehydrated in ethanol, embedded in Epon 812, and cut on an LKB Ultratome III.

Bladder washings

Washings were done before bladder distension. A total of 500 ml was obtained from each patient by collecting fractions of 50–150 ml of cystoscopy fluid (aminoacetic acid, 22 mg/ml in distilled water, pH 6), which was gently flushed into the bladders and then recovered. The fluid was cooled in an ice-bath, centrifuged at 250 g for 5 min and resuspended in phosphate-buffered saline to a volume of 1 ml. Samples of 50 μ l were cytocentrifuged (Shandon Southern Cytospin) at 1500 r.p.m. for 5 min, air-dried for 15 min, fixed in methanol for 10 min and stained with toluidine blue for 2 min at pH 0.5. Pellets were washed with Hanks' fluid and postfixed for electron microscopy as indicated above. The cell suspension was then pelleted by centrifugation for 2 min in 3% agar (800 g) and the pellets dehydrated in ethanol followed by embedding in Epon 812.

Mast cell counts

Mast cells were counted at 400 \times magnification. All the cells containing methachromatic granules were counted, regardless of whether the nuclei could be discerned or not, but the counting of small cell fragments was avoided. Areas damaged by the resection instrument were not screened for mast cells. Mast cells residing in the lamina propria and in the detrusor were counted separately. An eyepiece graticule (covering 0.0729 mm²) was used to define the counting area. At least 15 such areas in each region were surveyed for mast cells and the mast cell density was then expressed as cell numbers per unit area. The use of coded slides was not feasible, owing to obvious histopathological differences among specimens.

Aldehyde blocking of dye-binding

The degree of aldehyde blocking was assessed by cell counting and the determination of the fraction of mast cells that could not be visualized after FA fixation and staining for 30 min, but could be visualized after staining for 5 days or after IFAA fixation and staining for 30 min.

Histamine determination

Weighed samples were homogenized in 0.4 M perchloric acid followed by neutralization of the extracts and precipitation of potassium perchlorate. Histamine was detected and assayed by a sensitive HPLC method as described elsewhere (Allenmark, Bergström & Enerbäck, 1985).

Statistics

Wilcoxon's ranking test was used for the evaluation of differences between samples.

RESULTS

The biopsies from bladder lesions of IC showed acute ulcerations and inflammatory changes as described previously (Hand, 1949; Smith & Dehner, 1972; Jacobo, Stamler & Culp, 1974; Fall *et al.*, 1985). In cystoscopically normal areas, the urothelium was intact and the inflammatory changes less conspicuous than in areas with lesions. Specimens from control patients showed no pathological changes.

Specific mast cell staining with toluidine blue at pH 0.5 resulted in a distinct metachromatic staining of the mast cell granules against a virtually unstained background. Mast cells

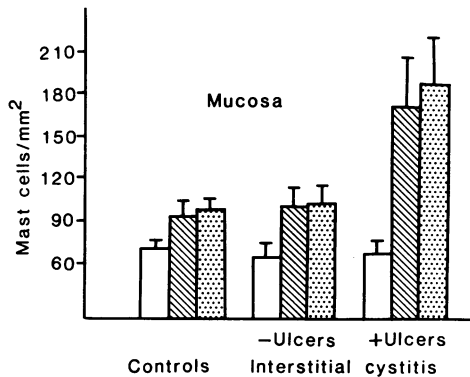


Figure 1. Mast cell density in the lamina propria of the urinary bladder in 14 control individuals without signs of cystitis and in 16 patients with chronic interstitial cystitis, in areas with or without ulcers. Tissues were fixed in 4% neutral buffered formaldehyde (FA, open bars) or in a mixture of 0.6% formaldehyde and 0.5% acetic acid (IFAA, dotted bars) and stained with 0.5% toluidine blue at pH 0.5 for 30 min or 5 days (hatched bars). Standard errors are indicated by vertical bars.

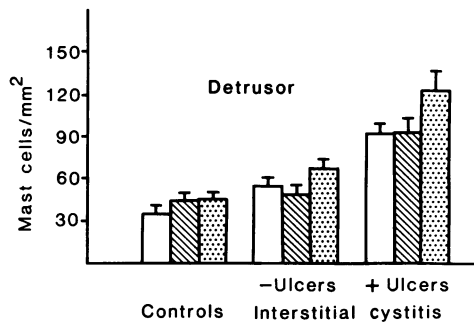


Figure 2. Mast cell density in the detrusor muscle of the urinary bladder of patients with chronic interstitial cystitis and controls as in Fig. 1.

stained for 5 days displayed dark blue granules, while the background remained unstained.

The mast cell density in the mucosa and in the detrusor muscle was affected by the mode of fixation and the staining time. With FA fixation and short staining, mast cells were found in the detrusor muscle and in the lamina propria, but never in the epithelium. The mast cell numbers counted in the lamina propria of the controls and IC (Fig. 1) did not differ significantly. The mast cell density in the detrusor muscle, on the other hand (Fig. 2), was higher in IC than in the controls ($P < 0.01$), the highest numbers being noted in muscle underlying areas displaying acute ulcers and cracks in the mucosa.

More mast cells were detected in the tissue after IFAA fixation and in FA-fixed specimens stained for 5 days ($P < 0.05$). In the lamina propria of the controls this increase in mast cell abundance was of the order of 30%, while the increase in the detrusor was about 25%. In specimens from patients with IC, IFAA fixation and long staining also resulted in an increase in mast cells throughout the bladder wall. The increase in mast cell numbers in the lamina propria in areas with lesions (Fig. 1) was of the order of 90% per unit area in comparison with the controls. In addition, the pattern of distribution of mast cells differed from that of the controls. Thus, mast cells were detected at all levels of the epithelium in 15 out of 16 patients. In cystoscopically normal areas, however, the mast cell numbers in

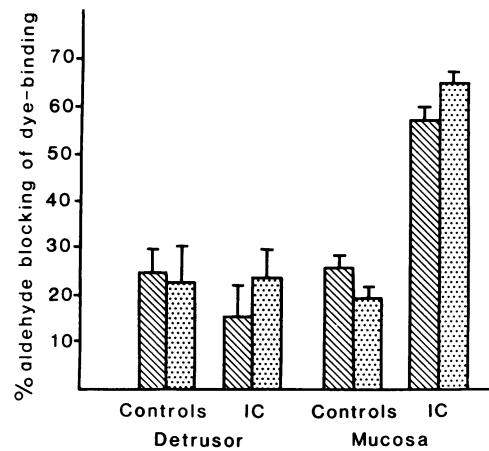


Figure 3. Blocking of dye-binding by aldehyde of mast cells in the detrusor muscle and mucosa of patients with IC and of controls as in Fig. 1. Mast cells were counted in adjacent tissue sections or in sections of adjacent tissue pieces, and the degree of blocking expressed as the number of cells that could not be visualized in FA-fixed tissue by staining for 30 min but after staining for 5 days (hatched bars) or after IFAA fixation and staining for 30 min (dotted bars).

the lamina propria did not differ significantly from that of the controls. In detrusor muscle underlying lesions the mast cell numbers per unit area were more than double, irrespective of fixation and staining (Fig. 2).

The degree of blocking of dye-binding by aldehyde, assessed as indicated in the methods section, is shown in Fig. 3. In the controls, the mast cells of the lamina propria and the detrusor muscle showed a similar degree of blocking of dye-binding, about 24% of the mast cells of both sites being invisible after normal aldehyde fixation and toluidine blue staining. In areas displaying lesions of IC, the degree of blocking of the mucosal mast cells was considerably higher (65%, $P < 0.001$), while the mast cells of the muscular coat showed an unchanged degree of blocking.

Since mast cells occurred frequently in the urothelium in patients with IC, we also performed a screening for mast cells in bladder washings. We found numerous mast cells in such washings in all of the 12 patients studied, while only occasional mast cells were found in one of the eight control subjects. The total number of mast cells recovered from the 500 ml bladder washings in patients with IC was preliminarily assessed as being of the order of 2000–10,000.

Samples from a few cases of IC were studied by electron microscopy as an additional means of identifying the metachromatically stained cells in the epithelium (Figs 4 and 5) and in the bladder washings (Fig. 6). They had the typical appearance of mast cells, containing many large electron-dense granules surrounded by limiting membranes. The granules displayed the characteristic lamellar structures and scrolls distinguishing human mast cell granules from those of blood basophils.

The mean histamine content of bladder samples from control subjects was 12.7 $\mu\text{g/g}$ wet tissue (range 4.5–24.3). In areas displaying lesions of IC, the mean histamine content was 20.3 $\mu\text{g/g}$ wet tissue (range 5.8–48.4; $P < 0.05$).

DISCUSSION

Evidence has accumulated indicating that mucous membranes

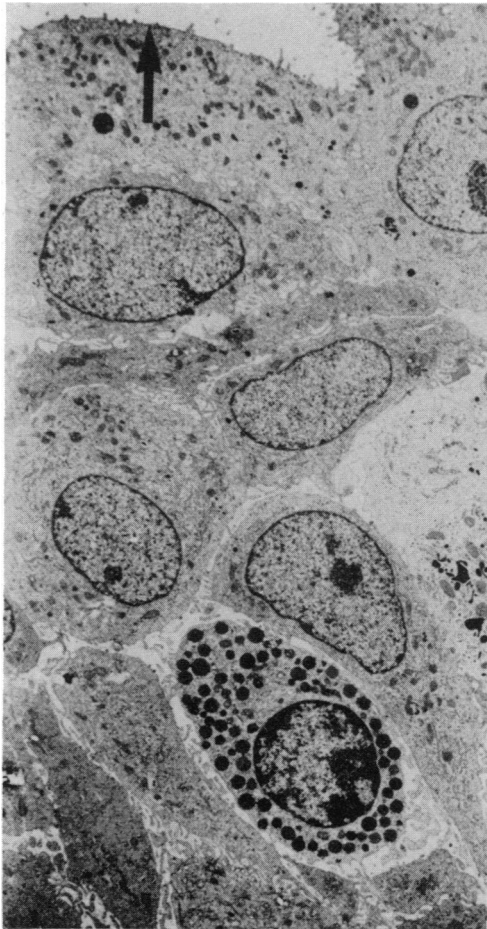


Figure 4. Electron micrograph of an intraepithelial mast cell in a patient with chronic interstitial cystitis. Specimen obtained before distension of the bladder. Arrow indicates surface of bladder epithelium. The mast cell contains many electron-dense granules in its cytoplasm (magnification $\times 3700$).

contain a specific mast cell phenotype different from the mast cells of other sites (see Enerbäck, 1985). Thus, mast cells residing in the mucous membranes of the rat differ in a number of respects from mast cells of the connective tissue of the skin and other organs. Whilst awaiting a more precise nomenclature, these two cell types are commonly referred to as mucosal mast cells and connective tissue mast cells. The major glycosaminoglycan of the intestinal mucosal mast cell is an oversulphated chondroitin sulphate rather than heparin (Enerbäck *et al.*, 1985), and its histamine content is only about 10% of that of connective tissue mast cells (Enerbäck, 1981; Befus *et al.*, 1982). The mucosal mast cell is unresponsive to classic histamine liberators such as Compound 48/80 and polymyxin B (see Enerbäck, 1981, 1985), and anti-allergic compounds such as disodium cromoglycate and theophylline do not modify its secretory response (Pearce *et al.*, 1982). Intestinal mucosal mast cells proliferate during certain nematode infections which are also accompanied by massive IgE production (Jarrett & Miller, 1982; Miller & Jarrett, 1971).

Most current information on mast cell heterogeneity has been derived from studies in the rat, but recent results indicate that mast cells in the human intestine and nasal mucosa share at

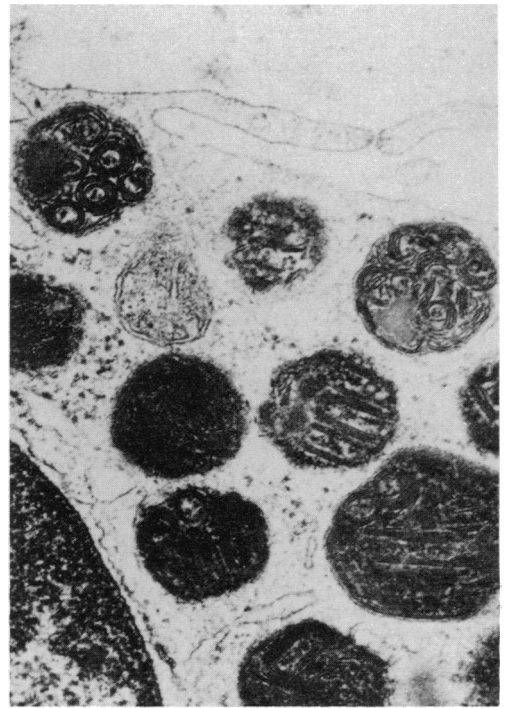


Figure 5. High magnification view of part of an intraepithelial mast cell. The granules show scrolls and lamellar arrays typical of human mast cell granules (magnification $\times 50,800$).

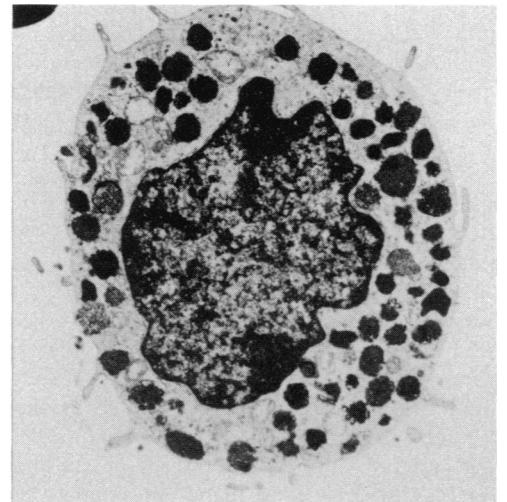


Figure 6. Electron micrograph of a well-preserved mast cell obtained from bladder washing material (magnification $\times 8400$).

least one distinctive histochemical property with those of the rat: they are susceptible to aldehyde fixation and, unlike connective tissue mast cells of other sites, require special fixation to be adequately preserved (Strobel *et al.*, 1981; Ruitenber *et al.*, 1982; Enerbäck *et al.*, 1986).

The present results confirm previous findings that the mast cell system is activated in lesions of IC. They further reveal a heterogeneity among the mast cells of the human urinary bladder, which appear to contain two histochemically distinct mast cell populations. One of these is susceptible to aldehyde fixation and is found in the lamina propria near lesions of IC,

but also within the epithelium and in bladder washings. These cells have not been observed previously since they require special fixation and staining methods for their demonstration. The other population of cells appears to be much less sensitive to aldehyde fixation and is distributed both in the lamina propria of the mucosa and in the connective tissue of the muscular coat. Of the cells belonging to this population, only those that are located in the detrusor muscle increase in number in IC.

Susceptibility to aldehyde fixation thus appears to be a distinctive property of mucosal mast cells both in rodents and in man. The identification of the mucosal mast cell as a distinct phenotype in the rat rested on the fact that the intestinal mucosa appears to contain a single population of cells that are fully blocked by normal aldehyde fixation, while other connective tissue sites such as the skin or peritoneum contain the classical connective tissue mast cell type which is completely insensitive to aldehyde blocking. The situation appears to be more complicated in man. In human connective tissue sites, such as skin (Olafsson, Roupe & Enerbäck, 1986), the degree of blocking, expressed as the fraction of the cells escaping detection by normal aldehyde fixation and staining, is 20–30%. In the intestinal mucosa, on the other hand, the degree of blocking is 70–80% (Strobel *et al.*, 1981; Ruitenber *et al.*, 1982). We have no means as yet of deciding whether the partial blocking of dye-binding at these different tissue sites is an expression of a distinctive property of one single mast cell population at each tissue site, or of a local heterogeneity in the sense that mucosal and dermal mast cells are composed of an aldehyde-sensitive and a non-aldehyde-sensitive population in varying proportions.

In the normal bladder wall, mucosal mast cells in the lamina propria as well as the mast cells of the muscular coat showed the same degree of blocking, about 25% of the cells being undetectable after normal aldehyde fixation and staining. In IC the number of mast cells per unit area of the muscular coat was approximately double. This increase in mast cell numbers could be well visualized irrespective of fixation and staining, the degree of blocking remaining at about 25%. The number of mucosal mast cells was also nearly double in lesions of IC, but the increase could be fully accounted for by cells that were completely blocked by aldehyde fixation. In this case, the increase in the degree of aldehyde blocking of the mucosal mast cells from about 25% in the normal mucosa to about 65% in the mucosa of IC is obviously an expression of a local heterogeneity. Again, we cannot decide if the 25% blocking of the mast cells of the normal mucosa or of the muscular coat in the normal or IC bladders is an expression of local heterogeneity or of an intrinsic property of one single cell population.

The aldehyde-sensitive mast cells were identified as tissue mast cells, rather than blood basophils, by their nuclear morphology and highly characteristic granules containing lamellar arrays and scrolls (Brinkman, 1968). Formation of mast cells from intraepithelial precursors has never been demonstrated; their presence in the epithelium must therefore be interpreted as a result of a migration from the lamina propria. A migratory capacity for these cells is further suggested by the finding of large numbers of mast cells in bladder washings of patients with IC.

The intraepithelial distribution of mucosal mast cells is a very unusual finding both in rodents and man, but is part of the mucosal nematode response both in the intestine (Miller &

Jarrett, 1971) and in the urinary bladder (Kirkman, 1950) of rats. In a recent study of the human nasal mucosa in birch pollen allergy, we found a similar redistribution of mucosal mast cells from the lamina propria into the epithelium with the onset of the pollen season, when a large number of mast cells could also be recovered in mucosal imprints (Enerbäck *et al.*, 1986).

The present findings thus provide additional evidence indicating that the mast cell–IgE system may be involved in the aetiology or pathogenesis of IC. It is of interest in this connection that a distinctive clinical sign in IC is the development of a marked mucosal oedema after distension of the bladder, a change that may very well be ascribed to the release of histamine from mucosal mast cells. The histamine content of the bladder tissue increased by about 60%, while mast cell numbers were approximately double, indicating a lower histamine content per cell in the inflamed mucosa than under normal conditions, a finding consistent with a histamine release from the mast cells.

ACKNOWLEDGMENTS

We thank Dr S. L. Johansson for advice on the histopathological diagnosis of bladder lesions, and Anita Olofsson, Gun Augustsson and Marie Svensson for their skilled technical assistance. This work was supported by grants from the Swedish Medical Research Council, Project No. 2235, and from Ellen, Walter and Lennart Hesselman's Foundation for Scientific Research, Stockholm.

REFERENCES

- ALLENMARK S., BERGSTRÖM S. & ENERBÄCK L. (1985) A selective post column *o*-phthalaldehyde—derivatization system for the determination of histamine in biological material by high-performance liquid chromatography. *Analyt. Biochem.* **144**, 98.
- BEFUS D.A., PEARCE F.L., GAULDIE J., HORSEWOOD P. & BIENENSTOCK J. (1982) Mucosal mast cells. I. Isolation and functional characteristics of rat intestinal mast cells. *J. Immunol.* **128**, 2475.
- BRINKMAN G.L. (1968) The mast cell in human bronchus and lung. *J. Ultrastruct. Res.* **23**, 115.
- ENERBÄCK L. (1966) Mast cells in rat gastrointestinal mucosa. I. Effect of fixation. *Acta Pathol. Microbiol. Scand.* **66**, 298.
- ENERBÄCK L. (1981) The gut mucosal mast cell. *Monogr. Allergy*, **17**, 222.
- ENERBÄCK L. (1985) Properties and function of mucosal mast cells. In: *Frontiers in Histamine Research* (eds C. R. Gannellin & J.-C. Schwartz), p. 289. Pergamon Press, Oxford.
- ENERBÄCK L., KOLSET S.O., KUSCHE M., HJERPE A. & LINDAHL U. (1985) Glycosaminoglycans in rat mucosal mast cells. *Biochem. J.* **227**, 661.
- ENERBÄCK L., PIPCORN U. & GRANERUS G. (1986) Intraepithelial migration of nasal mucosal mast cells in hay fever. *Int. Arch. Allergy appl. Immunol.* **80**, 44.
- FALL M., JOHANSSON S.L. & VAHLNE A. (1985) A clinicopathological and virological study of interstitial cystitis. *J. Urol.* **133**, 771.
- HAND J.R. (1949) Interstitial cystitis: report of 223 cases (205 women and 19 men). *J. Urol.* **61**, 291.
- HANASH K.A. & POOL T.L. (1970) Interstitial and hemorrhagic cystitis: viral, bacterial and fungal studies. *J. Urol.* **104**, 705.
- HEDELIN H.H., MÄRDH P.-A., BRORSON J.-E., FALL M., MÖLLER B.R. & PETERSSON K.G.S. (1983) Mycoplasma hominis and interstitial cystitis. *Sex. Transm. Dis.* **10**, 327.
- HUNNER G.L. (1915) A rare type of bladder ulcer in women: report of cases. *Boston Med. Surg. J.* **172**, 660.
- JACOBO E., STAMLER F.W. & CULP D.A. (1974) Interstitial cystitis followed by total cystectomy. *Urology*, **3**, 481.

- JARRETT E.E.E. & MILLER H.P.R. (1982) Production and activities of IgE in helminth infection. *Prog. Allergy*, **31**, 178.
- KASTRUP J., HALD T., LARSEN S. & NIELSEN V.G. (1983) Histamine content and mast cell count of detrusor muscle in patients with interstitial cystitis and other types of chronic cystitis. *Br. J. Urol.* **55**, 495.
- KIRKMAN H. (1950) A comparative morphological and cytochemical study of globule leucocytes (schollenleucocyten) of the urinary tract and of possibly related cells. *Am. J. Anat.* **86**, 91.
- LARSEN S., THOMPSON S.A., HALD T., BARNARD R.J., GILPIN C.J., DIXON J.S. & GOSLING J.A. (1982) Mast cells in interstitial cystitis. *Br. J. Urol.* **54**, 283.
- LOSE G., FRANDBEN B., HÖJENSGÅRD J.C., JESPERSEN J. & ASTRUP T. (1983) Chronic interstitial cystitis: increased levels of eosinophil cationic protein in serum and urine and an ameliorating effect of subcutaneous heparin. *Scand. J. Urol. Nephrol.* **17**, 159.
- MATTILA J. (1982) Vascular immunopathology in interstitial cystitis. *Clin. Immunol. Immunopathol.* **23**, 648.
- MILLER H.P.R. & JARRETT W.F.H. (1971) Immune reactions in mucous membranes. I. Intestinal mast cell response during helminth expulsion in the rat. *Immunology*, **20**, 277.
- OLAFSSON J.H., ROUPE G. & ENERBÄCK L. (1986) Dermal mast cells in mastocytosis. Fixation, distribution and quantitation. *Acta Dermatovenerol.* **66**, 16.
- ORAVISTO K.J. (1980) Interstitial cystitis as an autoimmune disease. A review. *Eur. Urol.* **6**, 10.
- PEARCE F.L., BEFUS A.D., GAULDIE J. & BIENENSTOCK J. (1982) Mucosal mast cells. II. Effects of anti-allergic compounds on histamine secretion by isolated intestinal mast cells. *J. Immunol.* **128**, 2481.
- REBUCK J.W., HODSON J.M., PRIEST R.J. & BARTH C.L. (1963) Basophilic granulocytes in inflammatory tissues of man. *Ann. N.Y. Acad. Sci.* **103**, 409.
- ROSIN R.D., GRIFFITHS T., SOFRAS F., JAMES D.C.O. & EDWARDS L. (1979) Interstitial cystitis. *Br. J. Urol.* **51**, 524.
- RUITENBERG E.J., GUSTOWSKA L., ELGERSMA A. & RUITENBERG H.M. (1982) Effect of fixation on the light microscopical visualization of mast cells in the mucosa and connective tissue of the human duodenum. *Int. Arch. Allergy appl. Immunol.* **67**, 233.
- SMITH B.H. & DEHNER L.P. (1972) Chronic ulcerating interstitial cystitis (Hunners ulcer). A study of 28 cases. *Arch. Path.* **93**, 76.
- STROBEL S., MILLER H.P.R. & FERGUSON A. (1981) Human intestinal mast cells: evaluation of fixation and staining. *J. clin. Pathol.* **34**, 851.
- WINGREN U. & ENERBÄCK L. (1983) Mucosal mast cells of the rat intestine: a re-evaluation of fixation and staining properties, with special reference to protein blocking and solubility of the granular glycosaminoglycan. *Histochem. J.* **15**, 571.