

Rhabdomyolysis

and

Acute Myoglobinuric Renal Failure

Following Heroin Use

JOHN C. KLOCK, MD, and MICHAEL J. SEXTON, MD, *San Francisco*

RHABDOMYOLYSIS IS USUALLY CONSIDERED a rare phenomenon and most medical textbooks devote little space to describing it. However, recently several observers¹⁻⁵ have pointed out that it occurs probably more frequently than is generally appreciated. Recently Richter et al⁶ described heroin-induced rhabdomyolysis and myoglobinuria in four addicts, a previously unrecognized association. It is the purpose of this report to present two more cases of heroin-induced rhabdomyolysis and discuss its cause and classification as a myoglobinuric syndrome.

Reports of Cases

CASE 1. A previously healthy 20-year-old college student entered the hospital because of an unusual reaction to an injection of heroin. On the evening before admission, he had intravenously injected a drug thought to be heroin, and thereupon became sweaty, nauseated, vomited and fell asleep sitting in a chair. Six hours later he awoke with tinnitus, generalized weakness, and pain in

the lower back and right hip. He noticed that his urine was dark brown and came to the emergency room.

On admission to the hospital, the patient was alert and cooperative and in no obvious distress. The blood pressure was 130/80 mm of mercury, the pulse 68 beats per minute, respirations 18 per minute and temperature 37.1°C (98.8°F). Physical examination, with the exception of subjective muscle tenderness in the posterior thighs, the buttocks and the lower back, and generalized muscle weakness, was entirely normal. The neurologic examination revealed no evidence of focal sensory or motor deficit.

The packed cell volume was 58 percent of the whole blood, with clear plasma, hemoglobin 19 grams per 100 ml, and white blood cell count 17,500 per cu mm with 75 percent neutrophils, 14 percent bands, 5 percent lymphocytes and 6 percent monocytes. Serum sodium was 135 mEq, potassium 7.0 mEq, chloride 107 mEq, bicarbonate 24 mEq per liter. Blood urea nitrogen was 31 mg and creatinine 2.6 mg per 100 ml, glutamic oxaloacetic transaminase 90 international units per liter, aldolase 21.2 milliunits per ml (normal adult 3 to 10). Creatine phosphokinase on days 1, 2 and 3

From the Medical Services of San Francisco General Hospital and the Fort Miley Veterans Administration and the Department of Medicine, University of California, San Francisco.

Submitted December 12, 1972.

Reprint requests to: J. C. Klock, MD, Department of Medicine, University of California, San Francisco, San Francisco, CA. 94143.

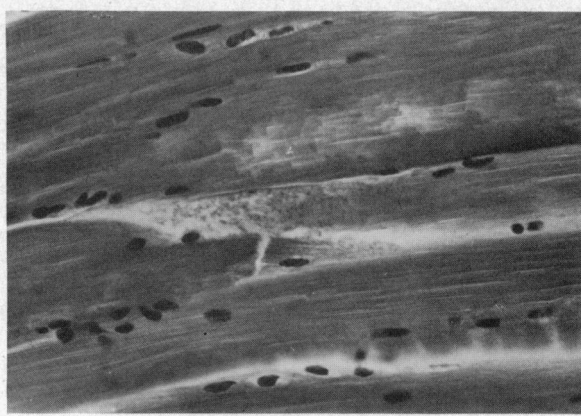


Figure 1.—Biopsy specimen from painful right gluteus muscle (Case 1) showing granular degeneration of muscle fibers. (Hematoxylin and eosin, original X 250.)

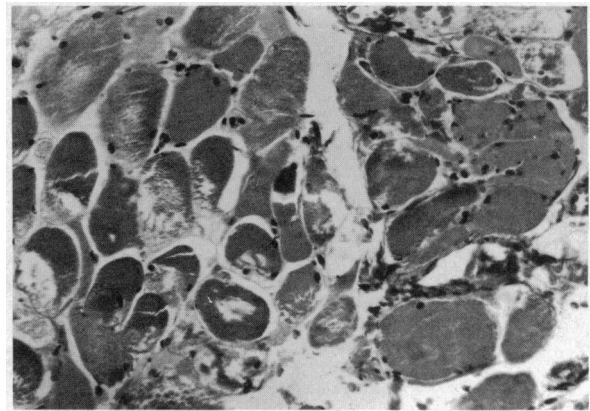


Figure 2.—Biopsy specimen from clinically uninvolved muscle, right quadriceps (Case 1) showing fragmentation of muscle fibers with central nuclei and an inflammatory infiltrate. (Hematoxylin and eosin, original X 250.)

was 36,000, 64,000 and 39,000 IU per liter, with only skeletal muscle fractions present on isoenzyme analysis. Random glucose, total bilirubin, alkaline phosphatase, calcium, phosphorus, whole blood pH and arterial blood gases were within normal limits. The urine was dark brown with a pH of 5, four plus reaction for blood and protein, two plus for glucose and negative for acetone and bilirubin. The urinary sediment contained many hyaline and coarsely granular casts, two to four white blood cells per high dry field and no red blood cells or red blood cell casts. Urine myoglobin by both ultrafiltration and electrophoretic techniques was positive. Urine toxicology was negative for alcohols, heavy metals, ethylene glycol and neutral and alkaline drugs including quinine, and was positive for morphine. A cigarette filter that the patient had used to strain the heroin he had injected was obtained and analyzed. The results showed only the presence of morphine and trace amounts of nickel, iron and nicotine.

The patient was oliguric, hyperkalemic and in obvious acute renal failure. The diagnosis of rhabdomyolysis and myoglobinuric renal failure was made and therapy with insulin, glucose, bicarbonate and oral sodium polystyrene sulfonate (Kayexalate®) was begun immediately. When there was no response to the rapid intravenous infusion of three liters of saline solution, 25 grams of mannitol was given intravenously and a rapid and sustained diuresis followed. The subsequent treatment course was uncomplicated and the patient completely recovered.

Muscle biopsy specimens from two separate sites were obtained on the third hospital day. The

first specimen was obtained from a tender site on the patient's right hip (Figure 1), the second from a non-tender area on the right leg (Figure 2). Both specimens showed scattered areas of necrosis, variation in fiber size, edema and degeneration of muscle fibers. The process was focal, with some areas of normal muscle. However, the changes in the second specimen were more pronounced than those in the clinically more severely affected muscle. The patient was discharged on the fifth hospital day and remained well in a four-month follow-up.

CASE 2. A 30-year-old man who had never previously used drugs entered the hospital with a painful, swollen right arm and acute renal failure. Two days previously he had injected into his right antecubital vein a substance thought to be heroin. Immediately afterward he noted severe pain in the right arm and shoulder. Painful swelling of the right arm, generalized weakness and the passing of dark urine prompted him to visit an emergency room, where he was found to have signs of acute morphinism; systemic vasculitis was diagnosed and he was referred on the following day to San Francisco General Hospital.

Upon arrival, the patient was drowsy but oriented and cooperative. The blood pressure was 130/90 mm of mercury, the pulse 100 per minute, respirations 16 per minute and temperature 37.9°C (100.2°F). Except for a painful, erythematous, swollen right arm, hand and shoulder, no abnormalities were noted on physical examination. Sensory and motor function were normal.

Packed cell volume was 51.5 percent of whole blood. The plasma was clear. Hemoglobin was

16 grams per 100 ml, and the leukocyte count was 24,300 per cu mm with 56 percent neutrophils, 38 percent bands, 2 percent metamyelocytes, 1 percent myelocytes, 2 percent lymphocytes and 1 percent monocytes. Serum potassium was 8.8 mEq per liter. Blood urea nitrogen 40 mg, creatinine 5.7 mg, calcium 6.5 mg, phosphorus 7.1 mg, and magnesium 3.4 mg per 100 ml. Glutamic oxaloacetic transaminase was 1,020 IU, aldolase 760 S-L units (normal adult 3 to 8), creatine phosphokinase 38,300 IU and lactic dehydrogenase 2,905 IU per liter. Two antinuclear antibody assays were negative, and there were normal values for serum sodium, bicarbonate, chloride, bilirubin and random glucose. The urine was dark brown, with a specific gravity of 1.026, pH 5, two plus reaction for protein and glucose, four plus for blood, and negative reaction for acetone and bilirubin. The urinary sediment contained many pigmented granular casts and no white blood cells, red blood cells or red blood cell casts. Urine toxicology was negative for alcohols, neutral and alkaline drugs, heavy metals and quinine and positive for morphine. Urinary myoglobin was not determined. A spoon in which the heroin mixture had been heated was analyzed and the results showed only the presence of opiates with no evidence of quinine or other adulterants. The patient was oliguric and in acute renal failure. Immediate treatment with intravenous fluids, mannitol and furosemide had no effect. Treatment with glucose insulin, bicarbonate, oral sodium polystyrene sulfonate and peritoneal dialysis were begun but the patient remained oliguric. Supportive treatment including a two-week course of hemodialysis resulted in full recovery of renal function. The development of neurologic deficit in the right hand necessitated fasciotomy on the third hospital day. The patient made uneventful recovery and was discharged on the 50th hospital day with some residual sensory and motor loss in the right arm.

Discussion

Rhabdomyolysis, or skeletal muscle necrosis, associated with the use of heroin is pathologically similar to rhabdomyolysis of any other cause. Muscle biopsy in such cases presents a spectrum of changes ranging from structural alterations of fibers without necrosis to severe necrosis of all muscle fibers, edema and focal hemorrhage. Substances released from affected tissues, among them myoglobin, are thought to be responsible for the

clinical syndrome and pathological consequences of rhabdomyolysis.

The presence of a guaiac-positive pigment in urine which contains no erythrocytes in a patient with muscle pain, weakness and normal-colored serum is pathognomonic of myoglobinuric rhabdomyolysis.¹ Patients with this syndrome usually also have fever, leukocytosis, pyuria, hyperkalemia, granular cylindruria, a high ratio of creatinine to blood urea nitrogen, and elevation of serum glutamic oxaloacetic transaminase, lactic dehydrogenase, creatine phosphokinase and succinic dehydrogenase. The detection of myoglobin in the urine and a muscle biopsy confirm the diagnosis, although myoglobinuria is not always associated with light microscopic changes and a normal biopsy does not exclude the diagnosis.

Acute renal failure is the most serious complication of rhabdomyolysis and is the most common cause of death.¹ It is an inconstant feature of the disease and is not always related to the degree of muscle damage, other factors such as systemic acidosis, hypovolemia and dehydration often contributing to its development. Acute elevation of toxic substances released from damaged tissues or hyperkalemia may also cause death, often suddenly. Neurocirculatory embarrassment of affected limbs from severe myoedema remains the most significant cause of morbidity in surviving patients and may necessitate fasciotomy.

The treatment of the acute rhabdomyolysis syndrome is directed toward the prevention of acute renal failure and the complications of severe myoedema. The first can best be done by early recognition and the use of diuretics in most instances. Peritoneal dialysis and hemodialysis may be needed in those patients not responding to diuretics and should be used when necessary. Immediate fasciotomy in patients with severe muscle swelling or at the first sign of neurovascular insufficiency may help in the prevention of permanent neurologic damage^{6,8} and should be used when appropriate.

The cause of rhabdomyolysis following heroin use remains obscure. It may recur in some persons⁶ suggesting an individual propensity for its development, as is seen in exercise-induced rhabdomyolysis.³ Recently Penn and Rowland² emphasized the role of coma and prolonged immobilization in the production of this syndrome. Schreiber et al⁷ reported a similar crush syndrome in comatose patients following heroin use. However, heroin adulterant was suggested as the in-

criminating element in the four patients reported by Richter.⁶ Heroin's role in the production of rhabdomyolysis in our patients cannot be fully explained. As far as can be determined, intra-arterial injection did not take place and we are unable to say whether heroin was directly responsible for the muscle necrosis observed in either case. An idiosyncratic reaction to apparently unadulterated heroin or an unusual susceptibility of the patients seems likely, although the more common role of crush injury seen in most cases of rhabdomyolysis following drug use is recognized and cannot be excluded as a contributing element in Case 1.

Summary

Rhabdomyolysis following heroin use was demonstrated in two non-addicted persons. Evidence is provided that there may be generalized involvement of muscle and that the crush factor may not

be related to the production of rhabdomyolysis in all patients with this syndrome. It is suggested that heroin is only one of many agents capable of producing rhabdomyolysis in susceptible persons and that individual susceptibility may play a major role in the disease. Finally, emphasis should be placed on the early recognition and appropriate management of this syndrome, the complications of which are largely preventable.

REFERENCES

1. Rowland LP, Fahn S, Hirschberg E, et al: Myoglobinuria. *Arch Neurol* 10:537-562, Jun 1964
2. Penn AS, Rowland LP, Fraser DW: Drugs, coma and myoglobinuria. *Arch Neurol* 26:336-343, Apr 1972
3. Smith RS: Exertional rhabdomyolysis in naval candidates. *Arch Intern Med* 121:313-319, Apr 1968
4. Schneider R: Acute alcoholic myopathy with myoglobinuria. *South Med J* 63:485-489, May 1970
5. Kagen LJ: Immunologic detection of myoglobinuria after cardiac surgery. *Ann Intern Med* 67:1183-1189, Dec 1967
6. Richter RW, Challenor YB, Pearson J, et al: Acute myoglobinuria associated with heroin addiction. *JAMA* 216:1172-1176, May 1971
7. Schreiber SN, Liebowitz MR, Bernstein LH, et al: Limb compression and renal impairment (crush syndrome) complicating narcotic overdose. *N Engl J Med* 284:368-369, Feb 1971