

# A Spontaneous Pneumoperitoneum Due to Jejunal Diverticulosis\*

ERIC M. NANSON, F.R.C.S., AND GEORGE E. DRAGAN, M.D.

Saskatoon, Saskatchewan

*From the Department of Surgery, University of Saskatchewan*

SPONTANEOUS ASYMPTOMATIC pneumoperitoneum is not a common condition. It must arise from a gas-filled viscus and, therefore, must arise from the gastro-intestinal tract. Ordinarily, a leak from the gastro-intestinal tract results in pneumoperitoneum together with peritonitis. In order to develop a spontaneous pneumoperitoneum without peritonitis, the leak must be minimal, so that only gas escapes and no bowel contents, and the resistance of the peritoneum to infection must be such that any bacterial soiling is promptly dealt with by the peritoneal defence mechanisms. Such must have been the conditions existing in the case to be described.

Spontaneous pneumoperitoneum is most commonly due to a perforated peptic ulcer, in which case acute symptoms develop due to leak of gastric or duodenal contents. These symptoms may subside, leaving a residual pneumoperitoneum, which, however, will usually absorb within three weeks, the leak having been sealed off. The peritoneum deals with any initial soiling, so that general peritonitis does not result. If a pneumoperitoneum of any degree continues for longer than three weeks, it would presuppose a continued slow leak of gas. The author has seen one such case in an elderly man with pyloric stenosis due to cicatricial duodenal ulcer. This patient perforated one of three ulcers he had on the greater curvature of the stomach, the leak so formed being sealed off by an adherent loop of jejunum. Yet this patient had no

initial acute symptoms, and the spontaneous pneumoperitoneum was a surprise finding by the radiologist who was preparing to do a barium meal to investigate the undoubted pyloric stenosis. The site of the original leak and the anatomical situation was subsequently proven by operation.

Another possible cause of asymptomatic spontaneous pneumoperitoneum is rupture of a gas cyst in pneumatosis of the bowel. Such a case was recently recorded by Kukul<sup>4</sup> *et al.* in 1955. A spontaneous pneumoperitoneum may be the first indication of this unusual condition. Rupture of a colonic diverticulum is unlikely to give rise to an asymptomatic continuing pneumoperitoneum because of the inevitably associated serious peritonitis. Pneumoperitoneum secondary to a laparotomy usually disappears in ten days to three weeks. In the case to be described, the patient had an acute episode two months before admission to hospital, at which time an extensive pneumoperitoneum was found, so that it must be deduced that a pneumoperitoneum had existed for this length of time. On account of the duration and the volume of the pneumoperitoneum, it must be deduced that the patient had a continuing, or intermittent, leak of gas into the peritoneum over this period of two months, and yet no symptoms of peritonitis were found at any time.

*Case History.* J. F. M., a 59-year-old business man, had a routine yearly medical examination in accordance with the practice of his business firm, on November 3, 1954, at which time a routine chest film was taken. To the surprise of the radiol-

\* Submitted for publication April, 1956.

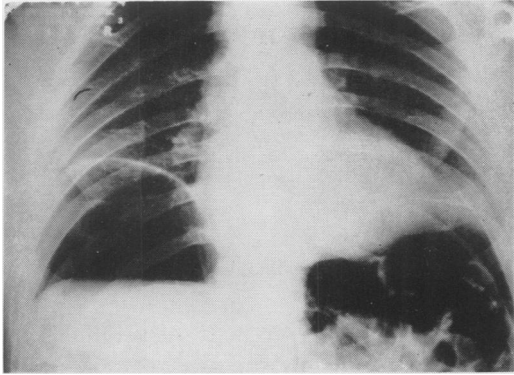


FIG. 1. Extensive pneumoperitoneum, with gas-filled loops of intestine interposed between left leaf of diaphragm and liver.

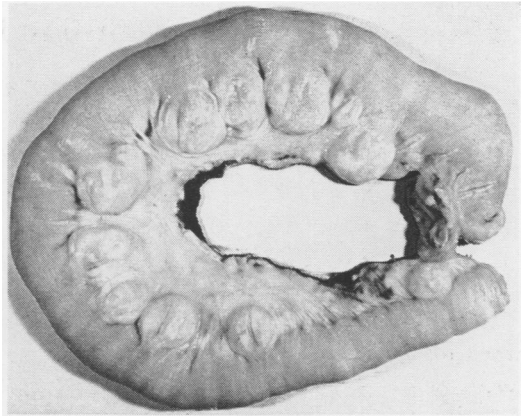


FIG. 2. Proximal jejunum showing diverticula in collapsed state.

ogist, and not less of the patient, an extensive pneumoperitoneum was found. Accordingly, he was referred to one of the authors (G. E. D.). A careful history elicited the fact that he had suffered from epigastric fullness and flatulence over the past year, with excessive borborygmi over the past 2 years. On October 5, 1954, one month previously, he had been watching a hockey match when he experienced the onset of sudden acute upper abdominal pain centered mainly at, and to the left of, the umbilicus, later spreading diffusely over the abdomen. He had to leave the game and walk around to relieve the pain. He then walked back to his hotel, and when nearly there, he vomited once in the street. He had no further vomiting. He went to bed and slept well, and next morning he woke up feeling perfectly well. Since that time he felt reasonably well, but was not quite normal. When seen by G. E. D., the temperature and pulse were normal and the patient looked well. The abdominal examination revealed loss of liver dullness but nothing else. A barium enema revealed a few diverticula of the sigmoid colon and one diverticulum of the transverse colon. A barium meal and follow-through showed a normal esophagus and stomach. The duodenum showed a diverticulum in the ampullary portion, and one in the third portion to the left of the spine. The jejunum and ileum were not remarkable in the follow-through meal. No diverticula were outlined by the barium in the jejunum. Plain films of the abdomen showed extreme pneumoperitoneum. There was much gas either in the intestine or in cysts, mainly in the left upper quadrant interposed between the liver and the diaphragm (Fig. 1). These findings suggested pneumatosis of the bowel.

The red blood cell count, the white blood cell count, and blood sedimentation rates were all

within normal limits. Sigmoidoscopy was unremarkable. On the 13th of December, 1955, a paracentesis of the abdomen was done, and 200 cc. of gas aspirated from the peritoneum. This was analyzed as follows:

Carbon Dioxide .....	6.1%
Oxygen .....	5.8%
Hydrogen .....	11.1%
Methane .....	1.1%
Nitrogen and water vapour ..	76.0%

The gas was odourless and was inflammable. This gas analysis suggested that the gas was of bacterial origin—the absence of hydrogen sulphide and the low methane content suggested that it came from high up in the gastro-intestinal tract.

The provisional diagnosis was, therefore, either pneumatosis of the small bowel, or diverticulosis, with a slow leak. Accordingly, a laparotomy was undertaken on December 17, 1954 (E. M. N.). On

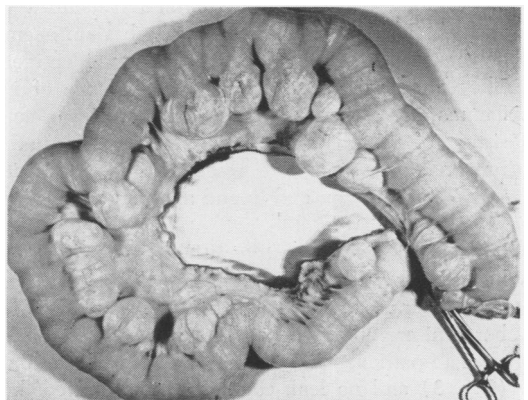


FIG. 3. Proximal jejunum distended with air.



FIG. 4. Wall of diverticulum, consisting of mucosa, submucosa, muscularis mucosae, and fibrous tissue only.

opening the abdomen, the fourth part of the duodenum and proximal portion of the jejunum was found to be grossly dilated and hypertrophied, and numerous large diverticula on the mesenteric border were found (Fig. 2). Some of these diverticula when distended were over two inches in diameter. There were no adhesions, and no evidence of peritonitis, past or present. However, on the summit of the convex surface of 3 of the largest diverticula, which were adjacent to each other, there was evidence of some peritoneal exudate and some hyperemia, suggesting that these were the possible sites of perforation. The distal jejunum and ileum were normal. The diverticula seen in the barium enema on the transverse and sigmoid colon were identified. They were small and showed no evidence of inflammation. Accordingly, 48 inches of bowel, consisting of the 4th part of the duodenum and the proximal jejunum, were resected, and continuity was restored by an end to end anastomosis.

Postoperatively, the patient did well and left hospital on his 9th postoperative day. Since then, he has felt well. It is interesting that he has lost his post-prandial flatulence and dyspepsia. The borborygmi are no longer troublesome.

The pathological specimen was inflated with air (Fig. 3) and no leak could be demonstrated, but the size and number of the diverticula were re-

markable. The specimen consisted of 120 cm. of proximal jejunum, varying in diameter from 4 to 5 cm. Numerous diverticula were present on the mesenteric border, measuring up to 6 cm. in maximum diameter, and 4 cm. in height. Some were bilocular, the division being produced by the *vasa recta* passing to the bowel. Microscopic section of one of the diverticula showed some chronic inflammation.

*Discussion.* Spontaneous symptomless pneumoperitoneum is not commonly referred to in the literature. Ayres<sup>1</sup> *et al.* reviewed the literature in 1950, and pointed out that the diagnosis is usually an accidental radiological finding. They noted that three cases were recorded until 1940, and since then five more cases were reported up to 1950. The authors added a further case. In 1950, Longhead<sup>5</sup> discussed two cases described by Monard *et al.* and by Leys, in which laparotomy gave no indication of the source of the pneumoperitoneum. Mason<sup>6</sup> *et al.* in 1946 described a patient suffering from right basal pneumonia who developed

a spontaneous pneumoperitoneum and referred to another such case reported by Sidel *et al.* in 1944. Five other cases were also mentioned.

Schorr<sup>8</sup> *et al.* (1951) and Gazin<sup>8</sup> *et al.* (1949) described two patients who suffered from pneumatosis cystoides intestinalis who developed spontaneous pneumoperitoneum from rupture of one or more of the air cysts. None of these authors gave an account of the analysis of the gas in the peritoneal cavity.

Diverticulosis of the small bowel has been reviewed from time to time. Edwards<sup>2</sup> in 1936 stated that Astley Cooper in 1807 published the drawing of a specimen from a man of 55 years of age. Osler in 1881 described the finding of jejunal diverticulosis in an autopsy on a man of 65 who had suffered from excessive rumbling noises after meals. It is interesting to note that the patient, herein described, suffered from excessive post-prandial borborygmi and flatulence. Edwards' material consisted of six postmortem studies and three operative cases. He pointed out that the diverticula develop as herniations of the mucous membrane of the jejunum through weakened areas where the mesenteric vessels perforate the muscular wall. In the pathological specimen of J.F.M., the diverticular walls were composed of mucous membrane and the muscularis mucosae covered with serosa (Fig. 4). Edwards further described a series of 4631 radiological barium examinations of the small bowel in which only four cases with diverticula were demonstrated. However, in the present patient a careful radiological study repeated twice failed to demonstrate numerous large diverticula, so that this examination is not infallible. He further described 2820 autopsy examinations in which nine cases of jejunal diverticulosis were found, giving a truer incidence of 0.32 per cent. However, he added that jejunal diverticula were more commonly found in autopsy material in India,

which suggests diet and nutrition may be a factor. He states that post-prandial borborygmi, flatulence and vague upper abdominal pain are the symptoms. Walker<sup>9</sup> (1945) gave a further review in which he pointed out that the upper jejunum is the area of the small bowel most commonly involved other than duodenum. If diverticula occurred in the ileum, they were usually single. The mouths of the diverticula were usually wide, and they rarely occurred under 40 years of age. He also commented on the negative roentgenologic findings. The complications of the condition which usually brought the patient to the doctor were as follows:

1. Acute diverticulitis, with or without perforation, producing acute peritonitis, local abscess formations, adhesions, and acute intestinal obstruction.
2. Concretion formation.
3. Massive intestinal haemorrhage.
4. Volvulus.

Rankin and Martin<sup>7</sup> (1934) presented an essentially similar review. However, none of the authors on this subject record a case developing spontaneous asymptomatic pneumoperitoneum.

Treatment is in general dictated by the complications which arise. Resection of the involved area of bowel would seem to be the treatment of choice in these patients. The complaints of vague epigastric discomfort and borborygmi are generally not of sufficient severity to justify operation, but the patient described in this report has had such complete relief from these symptoms that excision of the involved bowel should be seriously considered. It is important to remember also that jejunal diverticula may be only part of a general diverticulosis involving duodenum, small bowel and colon.

#### CONCLUSIONS

1. Asymptomatic spontaneous pneumoperitoneum is not a common condition. One

of the causes may be a leaking jejunal diverticulum.

2. Analysis of the gas in the peritoneum may be a useful diagnostic procedure.

3. Treatment should be resection of the involved segment of the jejunum.

## BIBLIOGRAPHY

- <sup>1</sup> Ayres, R. W., C. R. Beeson and J. B. Scruggs: Idiopathic Pneumoperitoneum. *Am. J. Digest. Dis.*, **17**: 345, 1950.
- <sup>2</sup> Edwards, H. C.: Diverticulosis of the Small Intestine. *Ann. Surg.*, **103**: 230, 1936.
- <sup>3</sup> Gazin, A. I., W. S. Brooke, H. H. Leoner and P. B. Price: Pneumatosis Intestinalis. *Am. J. Surg.*, **77**: 563, 1949.
- <sup>4</sup> Kukral, A. J., J. R. Plank and J. Denst: Abdominal Cysts Complicated by Intestinal Obstruction. *Ann. Surg.*, **141**: 109, 1955.
- <sup>5</sup> Longhead, J. R.: Pneumoperitoneum. *Gastroenterology*, **15**: 458, 1950.
- <sup>6</sup> Mason, J. M., E. M. Mason and K. F. Kesmodel: Spontaneous Pneumoperitoneum without Peritonitis and without Demonstrable Cause. *South M. J.*, **39**: 620, 1946.
- <sup>7</sup> Rankin, F. W. and W. J. Martin: Diverticulosis of the Small Bowel. *Ann. Surg.*, **100**: 1123, 1934.
- <sup>8</sup> Schorr, S., J. D. Ullmann and S. Laufer: Pneumatosis Cystoides Intestinalis. *Arch. Int. Med.*, **88**: 362, 1951.
- <sup>9</sup> Walker, R. M.: Complications of Acquired Diverticulosis of the Jejunum and Ileum. *Brit. J. Surg.*, **32**: 457, 1945.