

# The Use of Braided Nylon Tubes For Aortic Replacement\*

MILTON M. SELF, M.D., DENTON A. COOLEY, M.D., MICHAEL E. DEBAKEY, M.D., AND  
OSCAR CREECH, JR., M.D.

Houston, Texas

*From the Department of Surgery, Baylor University College of Medicine, and the Veterans Administration Hospital, Houston, Texas.*

BECAUSE OF THE difficulty associated with the procurement of human arterial homografts and the fact that homografts do not survive as living structures but are replaced in large part by tissues of the host,<sup>4</sup> efforts have been directed toward developing a satisfactory vascular prosthesis. Although early attempts to bridge arterial defects with tubes of glass, aluminum, gold-plate,<sup>2,3</sup> and silver<sup>3</sup> were unsuccessful, recent efforts with vascular prostheses have been more encouraging. In 1947 Hufnagel<sup>7</sup> reported the use of methyl methacrylate tubes in bridging defects in the thoracic aorta. In 15 animal experiments, thrombosis of the prosthesis was not encountered in a single instance. Somewhat later Donovan<sup>6</sup> described some successful experiments with polyethylene tubes used for experimental aortic replacement. In 1952 Voorhees and associates<sup>10</sup> reported the experimental use of a porous plastic textile, Vinyon "N" for aortic prostheses, and more recently Blake-more and Voorhees<sup>1</sup> have summarized their clinical experience with 18 cases in which this material was used to bridge aortic defects. Shumacker and King<sup>9</sup> have also employed a plastic textile material for the construction of aortic substitutes. However, these investigators have rendered the cloth impervious by fusing a thin sheet of non-reactive polythene between two sheets of nylon. In both experimental and clinical

trials this material has proven satisfactory for aortic replacements.

## MATERIALS

The prostheses employed in this experiment were hollow tubes of braided nylon with a weave of 90 by 144 strands per square inch. The tubes are woven on a commercial braiding machine, and are produced by braiding around a soft rubber mandril with a hollow center, which, prior to the weaving process, has been filled with sand and each end closed with a wooden plug. When the nylon tube has been woven and while still on the mandril, it is dipped into a liquid vinyl plastic and then allowed to air-dry. The vinyl plastic dries into a thin elastic coat within ten minutes, and is completely free of its solvent within 12 hours. Both the nylon thread and the vinyl plastic solution into which the prosthesis is dipped are completely inert and non-toxic. After 12 hours the ends of the mandril are unplugged, and the mandril emptied of sand, resulting in a decrease in size. The mandril is then elongated by traction from each end, and the plastic-coated nylon tube is removed without difficulty. These braided nylon tubes have a smooth outer surface and a rough inner surface due to the weave of the nylon thread (Fig. 1).

For this study, the tubes were of two sizes, with inside diameters of 0.7 cm. and 1.1 cm. respectively. The diameter of the tube could be readily varied by increasing or decreasing its length. Thus by increasing the length of a tube from 7 cm. to 10 cm. a reduction in diameter from 1.1 cm. to 0.9

\* Supported in part by the Houston Heart Association and the Cora and Webb Mading Fund for Surgical Research.

Submitted for publication January, 1955.




FIG. 1. Photograph showing the braided construction of the nylon tubes. The outer surface is smooth as the result of the vinyl plastic coating, whereas the inner surface is rough due to the weave of the thread.

cm. occurred. It was felt that this property of elasticity was desirable in an arterial prosthesis.

#### METHODS

Mongrel dogs ranging in weight from 11 to 18 Kg. were used for the experiment. The animals were anesthetized with intravenous nembutal sodium in a dose of 10 mg. per pound. For operations on the thoracic aorta, an endotracheal tube was passed and connected to a mechanical respirator. The chest was entered through the sixth interspace, and after insertion of a rib spreader the

descending thoracic aorta was exposed in its mid portion. The aorta was mobilized, and a 1.5 to 2 cm. segment excised. The defect was then bridged with a braided nylon tube with an inside diameter of 1.1 cm. Anastomosis was accomplished by a continuous over-and-over suture of 4-0 arterial silk interrupted in two places. For operations on the abdominal aorta the abdomen was opened through a midline incision. The aorta was mobilized from just below the renal arteries to the trifurcation. The inferior mesenteric artery was ligated and divided, and a 1.5 cm. segment was removed

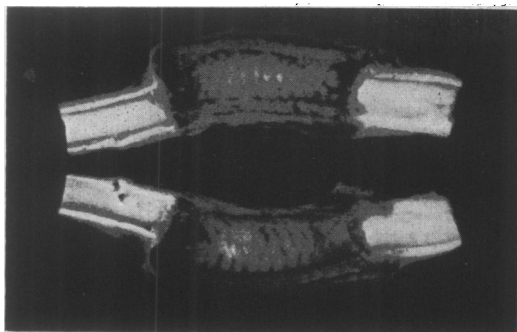


FIG. 2. Photograph of braided nylon prosthesis 132 days after implantation. The prosthesis and adjacent aorta have been opened longitudinally to show the loosely attached, outer fibrous connective tissue sheath and the thin, semi-transparent, adherent inner lining.

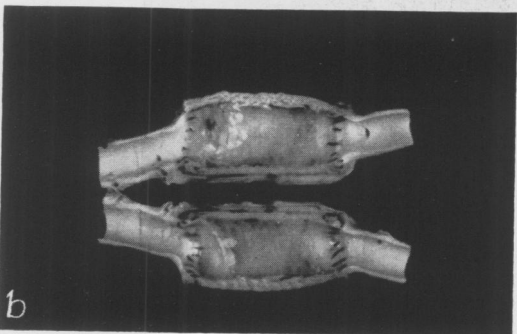
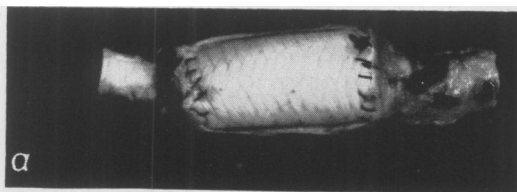


FIG. 3. Photograph of braided nylon prosthesis 196 days after implantation into the thoracic aorta. (A) The outer connective tissue sheath has been peeled away from the prosthesis. (B) The prosthesis and adjacent aorta have been sectioned longitudinally to show the loosely adherent, outer fibrous connective tissue sheath and the smooth adherent inner lining. Moderate disproportion between the prosthesis and aorta is evident.

from the center of the mobilized portion of aorta. The defect was bridged with a braided nylon tube with an inside diameter of 0.7 cm. The anastomoses were accomplished with a continuous over-and-over suture of 5-0 black silk interrupted in two places. No attempt was made to cover the prostheses with a serous layer in either the abdominal or thoracic portions of the aorta. The thoracic




FIG. 4. Longitudinal section from proximal anastomosis. The braided nylon tube had been implanted into the thoracic aorta 196 days. A layer of fibrous connective tissue covers the line of anastomosis, and extends onto the prosthesis and aorta. The prosthesis was partially disrupted during sectioning, and the nylon threads appear as bead-like structures. There are extensive infiltrations of inflammatory cells at the lines of anastomosis and on the inner and outer surfaces of the nylon tube. The external surface is covered with dense hyalinizing fibrous connective tissue that extends into the adventitia of the adjacent aorta. (Photomicrograph  $\times 40$ .)

and abdominal wounds were closed with continuous cotton sutures. The animals were observed from one day to six and one-half months. At necropsy the prostheses and adjacent host aorta were removed and fixed in 10 per cent formalin prior to examination. The specimens were then sectioned sagittally for gross examination, and sections were taken from the proximal and distal suture lines and the center of the prostheses for microscopic examination.

#### RESULTS

Braided nylon prostheses were implanted into the aorta in 13 animals. The tubes were

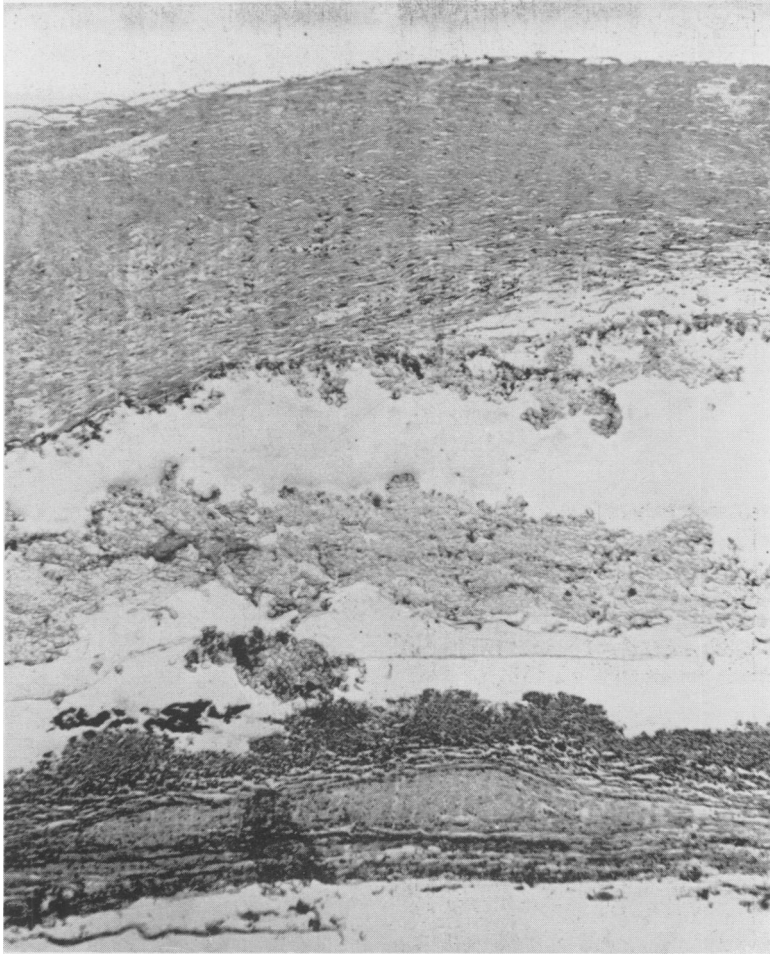


FIG. 5. Cross section from the center of a braided nylon prosthesis 196 days after implantation. The intima is represented by a partly organized fibrin clot that rests on the wall of the prosthesis. External to the prosthesis there is a layer of dense hyalinizing fibrous connective tissue heavily infiltrated with inflammatory cells. (Photomicrograph  $\times 40$ .)

implanted into the abdominal aorta in five, and into the thoracic aorta in eight. The period of survival ranged from one to 196 days. One animal did not recover from anesthesia, and died 24 hours after operation; two animals died from fights with other dogs 10 and 144 days respectively after operation, and ten animals were sacrificed from 77 to 196 days after operation.

The following changes were found at necropsy. The thoracic aortic prosthesis one day old was surrounded by a fresh thrombus that covered the prosthesis completely. This was separated easily from the outer

surface of the nylon tube except at the anastomoses, where it appeared to be continuous, with the thrombus lining the inner surface of the suture lines. On opening the prosthesis it was found to be lined with a fibrin clot approximately 0.05 to 0.1 cm. in width. The suture material was visible in places, and elsewhere was covered by a fresh thrombus. The remaining prostheses, examined 77 to 196 days after implantation, were completely covered by dense fibrous connective tissue so that neither the prosthesis nor the suture lines were evident. The connective tissue sheath commenced

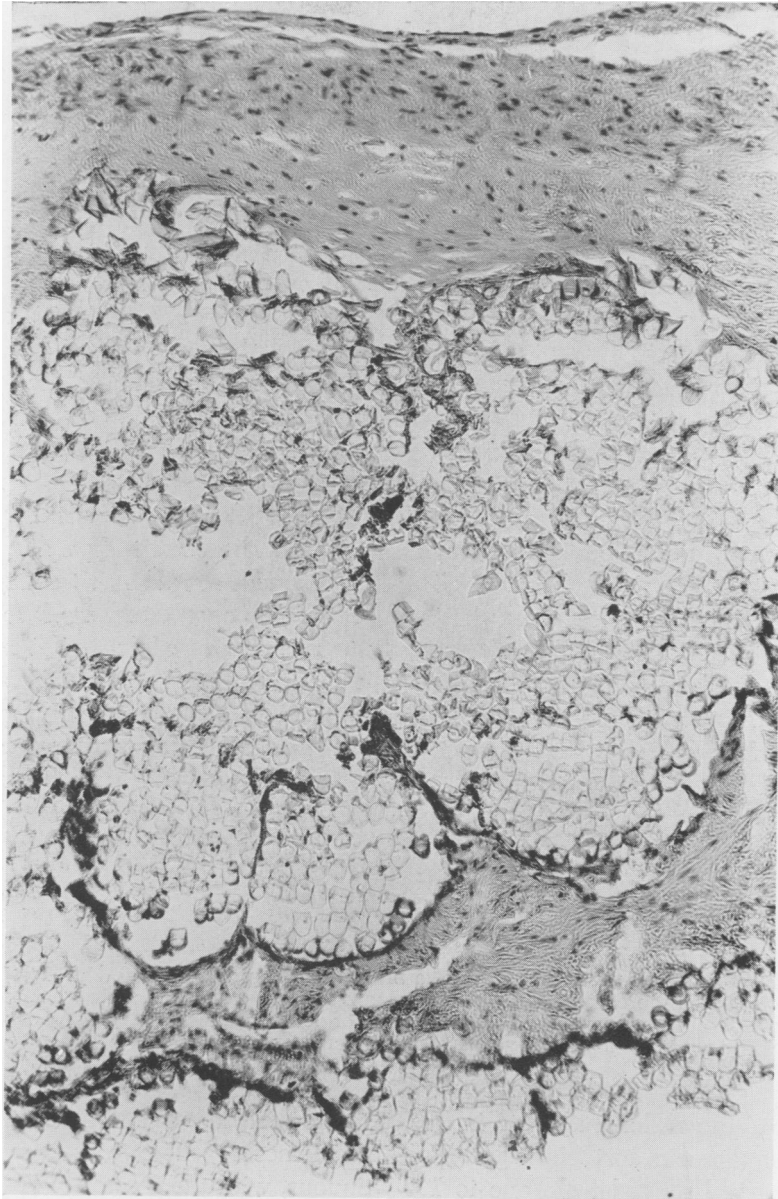


FIG. 6. A section from the mid-portion of a braided nylon prosthesis 146 days after implantation. The connective tissue cells have invaded the fibrin clot lining the inner surface of the prosthesis, and have extended into the wall of the prosthesis between the threads for about half its thickness. (Photomicrograph x60.)

about 0.5 cm. proximal to the upper anastomosis, and extended for about 0.5 cm. distal to the lower end of the prosthesis. It was loosely attached to the surface of the prosthesis everywhere except at the lines of anastomosis, where it was densely adherent (Fig. 2). When this outer sheath was peeled

away, the prostheses were found to be unchanged in color (Fig. 3A) but were semi-rigid, whereas at the time of implantation the tubes were soft and pliable. Upon sectioning the tubes longitudinally, four of those implanted into the abdominal aorta were found to be completely thrombosed,

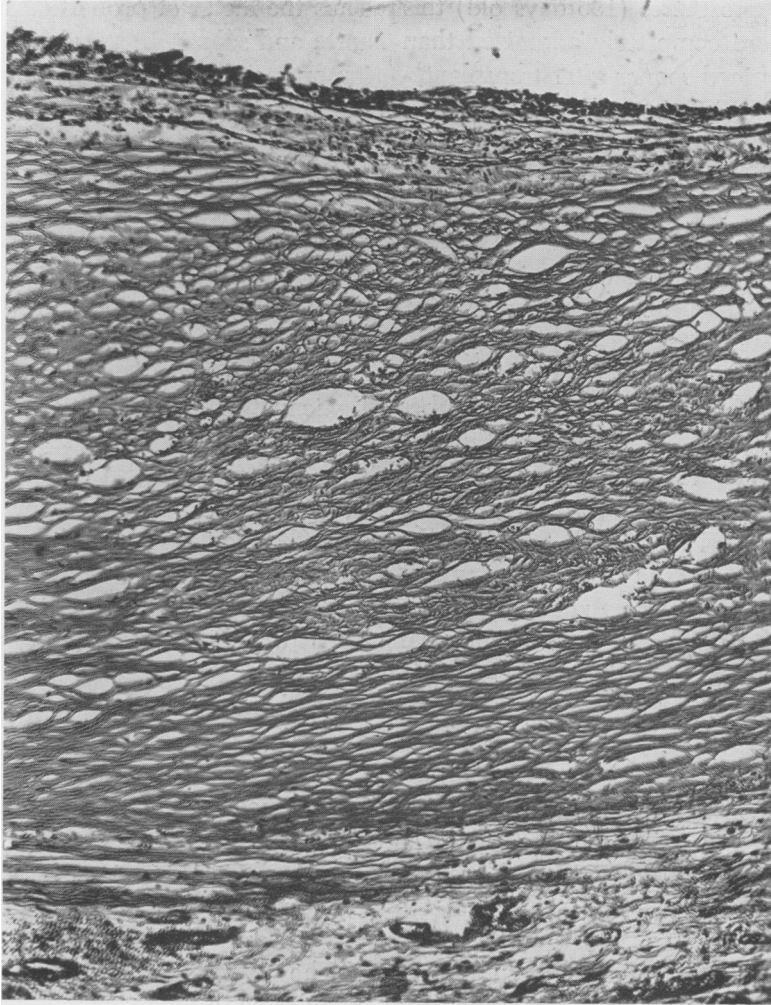


FIG. 7. Section from the center of a braided nylon prosthesis 144 days after implantation, showing a thick layer of dense hyalinizing fibrous connective tissue external to the prosthesis and separated from it by a zone of lymphocytes, plasma cells, large mononuclear cells, and giant cells of the foreign body type. (Photomicrograph x60.)

and in one the lumen was reduced by half, whereas all of the tubes implanted into the thoracic aorta were patent, although there was a moderate degree of constriction at the suture lines in two. The inner surface of the patent prostheses was lined with a smooth, thin, grayish white to brown membrane that completely obscured the suture material in places (Figs. 2 and 3B). This inner layer was intimately adherent to the inner surface of the prosthesis, and was continuous with a similar layer extending onto the host aorta for about 0.5 cm.

Microscopically, the prosthesis examined at one day was lined with a thin layer of fibrin that filled the interstices of the nylon thread and the openings through which the sutures had been placed for the anastomoses. In the specimens examined 77 to 196 days after transplantation, the inner lining was composed of a layer of fibrin clot that had undergone varying degrees of organization. Near the anastomoses this inner layer was very cellular (Fig. 4), whereas toward the center of the prosthesis fewer connective tissue cells were evident (Fig. 5).

In the older prostheses (196 days old) this layer was more completely organized than in those examined sooner after transplantation (77 days old). The fibrin layer infiltrated the interstices of the nylon thread for about half the thickness of the prosthesis, and in the older specimens connective tissue elements had grown into the wall of the prostheses, thus binding the inner layer to the tube (Fig. 6). Dense hyalinizing fibrous connective tissue was loosely adherent to the surface of the prostheses and showed no evidence of invasion of the tubes (Fig. 7). This was due to the fact that the external surface of the tubes had been interstices. On the inner surface of the coated with vinyl plastic, thus sealing the dense connective tissue sheath surrounding the prostheses there was a zone of lymphocytes, plasma cells, and large mononuclear cells and occasional giant cells of the foreign body type (Fig. 7).

At the anastomoses, union between the host aorta and the prosthesis had been accomplished by granulation tissue, which in the older specimens had progressed to the formation of scar tissue (Fig. 4). The inner lining of the prosthesis extended onto the host aorta for a short distance, and where it crossed the lines of anastomosis a wedge-shaped plug of granulation tissue filled the cleft. Aggregations of inflammatory cells were noted in the region of the anastomosis, and occasional giant cells of the foreign body type were seen.

#### COMMENT

These experiments indicate that a braided nylon prosthesis rendered impervious by application of vinyl plastic to its outer surface may function satisfactorily as an aortic substitute. Of five prostheses implanted into the abdominal aorta, four became occluded. In each instance there was marked disproportion between prosthesis and aorta, with the result that the anastomoses were performed with difficulty.

Thus the factor of proportion between host aorta and substitute appears to be of equal importance whether homografts or synthetic materials are used.

It was assumed at the beginning of this study that the elasticity of nylon tubes constituted an advantage in a vascular prosthesis. However, this factor appears to be relatively unimportant in view of the fact that all of the prostheses were firm and unyielding at the time of necropsy.

The reaction of host tissues to this synthetic material is similar to that observed by others using prostheses made of other types of plastic materials. An inner lining membrane is formed by deposition of fibrin clot that fills the interstices of the nylon thread and eventually becomes organized by ingrowth of fibrous connective tissue cells from the host aorta. The prosthesis is "walled off" by the abundant formation of dense hyalinizing fibrous connective tissue that completely covers the tube. The union between host aorta and prosthesis is accomplished by the formation of scar tissue. The presence of inflammatory cells and giant cells about the prosthesis and at the anastomoses is indicative of the reaction produced by this foreign body.

The intimate adherence of the lining membrane to the inner rough surface of the nylon tube is perhaps an important and desirable feature. The connective tissue sheath on the outside of the tube was not adherent, except at the lines of anastomosis, because of the smooth surface produced by the application of vinyl plastic. Thus this layer could be easily separated from the tube. It appears that a loosely attached inner lining would be undesirable because of the likelihood that a break in its continuity would result in separation from the wall of the tube and narrowing or complete occlusion of the lumen.

A braided prosthesis constructed of smaller caliber nylon thread would probably be more satisfactory from a technical

standpoint. The wall would be thinner, hence easier to sew, and anastomosis with host vessels could be accomplished more satisfactorily.

BIBLIOGRAPHY

- <sup>1</sup> Blakemore, A. H., and A. B. Voorhees, Jr.: The Use of Tubes Constructed from Vinyon "N" Cloth in Bridging Arterial Defects—Experimental and Clinical. *Ann. Surg.*, **140**: 324, 1954.
- <sup>2</sup> Carrel, A.: Permanent Intubation of the Thoracic Aorta. *J. Exper. Med.*, **16**: 17, 1912.
- <sup>3</sup> ———: Results of Permanent Intubation of the Thoracic Aorta. *Surg., Gynec. & Obst.*, **15**: 245, 1912.
- <sup>4</sup> DeBakey, M. E., O. Creech, Jr., D. A. Cooley and B. Halpert: Structural Changes in Human Aortic Homografts: A Study of Ten Cases. *Arch. Surg.*, **69**: 472, 1954.
- <sup>5</sup> DeBakey, M. E., D. A. Cooley and O. Creech, Jr.: Treatment of Aneurysms and Occlusive Disease of the Aorta by Resection. *J. A. M. A.*, **157**: 203, 1955.
- <sup>6</sup> Donovan, T. J.: Uses of Plastic Tubes in Reparative Surgery of Battle Injuries to Arteries with and without Intra-arterial Heparin Administration. *Ann Surg.*, **130**: 1024, 1949.
- <sup>7</sup> Hufnagel, Charles A: Permanent Intubation of the Thoracic Aorta. *Arch. Surg.*, **54**: 382, 1947.
- <sup>8</sup> Makins, G. H.: Gunshot Injuries to the Blood Vessels. London, William Wood & Co., 1919.
- <sup>9</sup> Shumacker, H. B., Jr. and H. King: The Use of Pliable Plastic Tubes as Aortic Substitutes in Man. *Surg., Gynec. & Obst.*, **99**: 287, 1954.
- <sup>10</sup> Voorhees, A. B., A. Jaretzki, III and A. H. Blakemore: The Use of Tubes Constructed from Vinyon "N" Cloth in Bridging Arterial Defects. *Ann. Surg.*, **135**: 332, 1952.