

Lymphomas of the Small Intestine and Cecum*

SHELDON OSCAR BURMAN, M.D.

Iowa City, Iowa

AND F. A. K. VAN WYK, M.B., CH.B., M.MED. (CHIR.)

Pretoria, South Africa

From the Department of Surgery, Postgraduate Medical School of London, Hammersmith Hospital, London, England

KUNDRAT²¹ IN 1893 first delineated lymphosarcoma as a distinct lymphoid tumor from the allied lymphomas of the circulating and non-circulating types. In addition to certain histological features of the disease, he described its invasiveness and capacity to metastasize. A review of the relevant literature since that time reveals that the term lymphosarcoma has been variously and ambiguously employed. Lumb²⁶ employs the term to designate the lymphocytic and lymphoblastic variants only, and Willis⁸¹ states that lymphosarcoma means a malignant tumor of lymphoid tissue which is predominantly lymphocytic or lymphoblastic in structure. Although Gall and Mallory¹⁴ do not use the term at all in an histological sense, Marcuse and Stout²⁸ include under the category of lymphosarcoma, giant follicular lymphoma, and reticulum-cell sarcoma (stated by Boyd⁴ to be commonly regarded as a form of lymphosarcoma under the name reticulum-cell lymphosarcoma).

Furthermore, one encounters a general failure of authors to distinguish the sarcomas of intestinal lymphoid tissue from other bowel sarcomas, as well as a failure to classify lymphomas as to their incidence in the various segments of the bowel.

In this paper the authors have adopted the unitarian concept and terminology of Warthin,⁵⁶ whose views have been accepted by most recent students of this subject. He concludes that Hodgkin's disease and the lymphocytic and lymphoblastic sarcomas,

with or without circulating metastases, are genetically related, and that this group properly includes both reticulum cell sarcomas and giant follicular lymphomas (at opposite ends of the scale as regards malignancy).

It will be seen in our discussion of the microscopic pathology of these tumors that transition forms exist between all these groups, and that a single specimen commonly exhibits more than one histological variant. The whole group may thus be properly considered an entity within which, as Willis states, a wide range of structure and behavior justify, only for descriptive purposes, the use of special names for the main variants.

The literature of gastro-intestinal lymphomas in particular has been obscured by the creation of spurious clinico-pathological distinctions created on the quite incidental circumstance of whether the malignant lymphocytes enter the blood stream early, or late, or at all, and whether the gross lymphoid involvement occurs in a single site (leukosarcoma) or is generalized (pseudoleukemia gastro-intestinalis). These terms are misleading, and should be discarded.

Selection of Cases. The cases reported in this paper comprise only those in which the symptom-producing lesion was located in the small intestine or cecum, and does not include cases in which generalized lymphoid sarcomatosis happened incidentally to involve the lymphoid tissue of the intestine. Lymphomas in the region of the ileo-

* Submitted for publication July, 1955.

TABLE I. Site, Sex, Age, Cell Type.

Male Cases.....	17								
Female Cases.....	8								
Site	Cases	Cell Type	Cases						
Duod.....	3	Giant Follicular.....	1						
Jejun.....	4	Lb { Small.....	2						
		{ Large.....	7						
Ileum.....	9	Hodgkins.....	0						
Cecum.....	5	Retic. Cell.....	7						
Cecum and Ileum...	4	Mixed.....	8						
Age of Onset in Decades									
Decade.....	1	2	3	4	5	6	7	8	
Cases.....	1	2	0	2	7	5	4	4	
		Lb =Lymphoblastic { Small cell type.							
		{ Large cell type.							
		Mixed =More than one cell type seen.							

TABLE II. Presenting Signs and Symptoms.

Sign or Symptom	Cases
Palpable Abdominal Mass.....	19
Change in Bowel Habits.....	24
Blood in Stools { Gross.....	0
{ Occult.....	13
Intestinal Obstruction { Partial.....	12
{ Complete.....	6
Weight Loss.....	20
Lymphocytosis.....	1
Anemia.....	1
Pain.....	22

cecal valve often involve both the cecum and the ileum, making it impossible to determine which is the primary site. We have classified this lesion as a combined one, and for this reason have included cecal lymphomas in our discussion of lymphomas of the small intestine.

Sex, Age, Race. As with all the sarcomas of lymphoid tissue, and in common with all other gastro-intestinal neoplasms, lymphomas of the small intestine and cecum are far more common in males than in females, the ratio being 2 to 3.5:1. This disease is known to occur in all age groups, with peak incidence in the fourth and sixth decades, and with a smaller peak in the first decade of life. It affects the Negro as well as the white man, but the published statistics are misleading, since they are not corrected to account for the relative race incidence of patients at hospitals which have produced the statistics. None of the variables such as age, sex, or race of the patient, or the histological type of the tumor, appear to bear a constant relationship to the location of the tumor in the bowel.

Etiology. The etiology is unknown. Attempts in the older literature to relate this disease to tuberculosis and syphilis merely reflect the high incidence of these diseases in the general population. There is an intriguing condition mentioned by de Mon-

breun and Goodpasture,¹¹ known as transmissible lymphosarcoma of dogs, which is generally considered to be a highly contagious venereal disease, world-wide in distribution. Transmission is by coitus, and the primary growth is on the glans penis or the vaginal wall. Metastases, particularly to the retroperitoneal, pelvic, and inguinal nodes, are common. If one assumes, says Symmers,⁴⁶ that transmissible lymphosarcoma of dogs is an infective process, then one might assume that possibly it is transmissible in man, that possibly it is a virus disease. No virus has ever been incriminated, nor has the disease been transmitted from man to man, although neither of these possibilities has been ruled out. On the other hand, living cells possess identical patterns of response to diverse stimuli, and a similarity in microscopical appearance of these tumors in dogs and man clearly need not presume a common etiology of the tumors.

Gross Pathology. Lymphoid tissue in the intestine, as well as elsewhere, consists of a network of reticulum cells and fibers, within the meshes of which are lymphocytes. This tissue occurs chiefly in the *lamina propria*, a reticular layer which forms the core of the villi, extending between the glands and lying between the epithelium and the *muscularis mucosa*. It occurs in three forms: diffuse lymphoid tissue, solitary nodules, and agminate (aggregate) nodules. The follicles are often too large to be contained within the confines of the *lamina propria*, and break through the *muscularis mucosa* to spread in the submucosa. In the lower

TABLE III. Findings at Operation.

Findings	Cases		
Ulceration.....	8		
Perforation.....	5		
Obstruction	{ None..... 7 Partial..... 12 Complete..... 6		
		Intussusception.....	5
		Serosal Extension.....	11
Involvement of Adjacent Nodes.....	20		
Extension to Adjacent Viscera.....	9		
Diffuse (Gross) Lymphoid Hyperplasia.....	5		

ileum and cecum, and to a much lesser extent in the jejunum and distal ileum, are found aggregate nodules (Peyer's patches) which may be seen as dull patches in the otherwise glistening lining of the fresh-opened intestine. Immediately above the nodules, the villi are partly or wholly obliterated, and the epithelium is modified and occasionally wanting. This accounts for the observation of some authors that early lymphoma appears to be primarily a mucosal condition, with the submucosa only later affected (Fig. 1).

In the early stages of lymphoma the involved lymphoid plaque becomes thicker and more prominent. The tumor spreads peripherally along the long axis of the bowel through the submucosa, and gradually invades and replaces the *tunica muscularis*, appearing as a sub-serous tumor. The sub-serosal surface becomes irregularly studded with pea-sized nodules and the tumor frequently penetrates the serosal coat. When palpated, the mass feels hard and rubbery. As the growth proliferates, ulceration of whatever epithelium is present may occur, with erosion into the tumor mass. The tumor characteristically does not evoke a collagenous response, so there is little tendency for stenosis to occur. Fraser¹³ points out that by infiltration the tumor weakens and paralyzes the bowel musculature, and destroys the myenteric nerve plexuses, thus producing dilation and the resulting bowel stasis which plays so prominent a role in the clinical picture (Fig. 2).

TABLE IV. Therapy.

Therapy	Cases
Biopsy Only.....	3
Local Palliative Resection.....	7
Wide Resection with Lymph-Drainage Area.....	5
Irradiation Alone.....	2
Surgery Plus Irradiation.....	8

TABLE V. Results of Follow-ups.

Deceased	Cases	Surviving	Cases
Interval from First Symptom Until Death		Five Years or More Since First Symptom..... 3	
0-5 Months.....	5		
6-11 Months.....	6		
1-3 Years.....	4	Less than Five Years Since First Symptom.. 3	
4-5 Years.....	2		
6-8 Years.....	2		

Typically, the lesion of lymphoma is a more extensive one than that of carcinoma, involving a longer segment of bowel, infiltrating the mesentery early, and producing rather marked alterations in the bowel pattern. The size of the primary lesion found at autopsy or operation varies from 2 or 3 cm. to the size of a human head. It is common for the patient to appear initially with a palpable abdominal mass. The gross lesions can be described as either diffusely infiltrating or polypoid, the former type being the more frequent in the small intestine. Rarely, an annular constricting variant is found. The commonest finding is a nodular, firm, grayish-white lesion, partially occluding the bowel lumen, and with its base infiltrating the bowel wall. Proximal to the tumor, mild to moderate dilatation is present. The majority of patients operated upon already have infiltration of that group of mesenteric nodes draining the affected bowel segment. This by no means precludes a successful result, for cases are recorded where cures of five years and more have occurred following resection of the bowel tumor with the involved nodes.

Microscopic pathology. Lymphomas of the small intestine, as elsewhere, present four main histological variants:

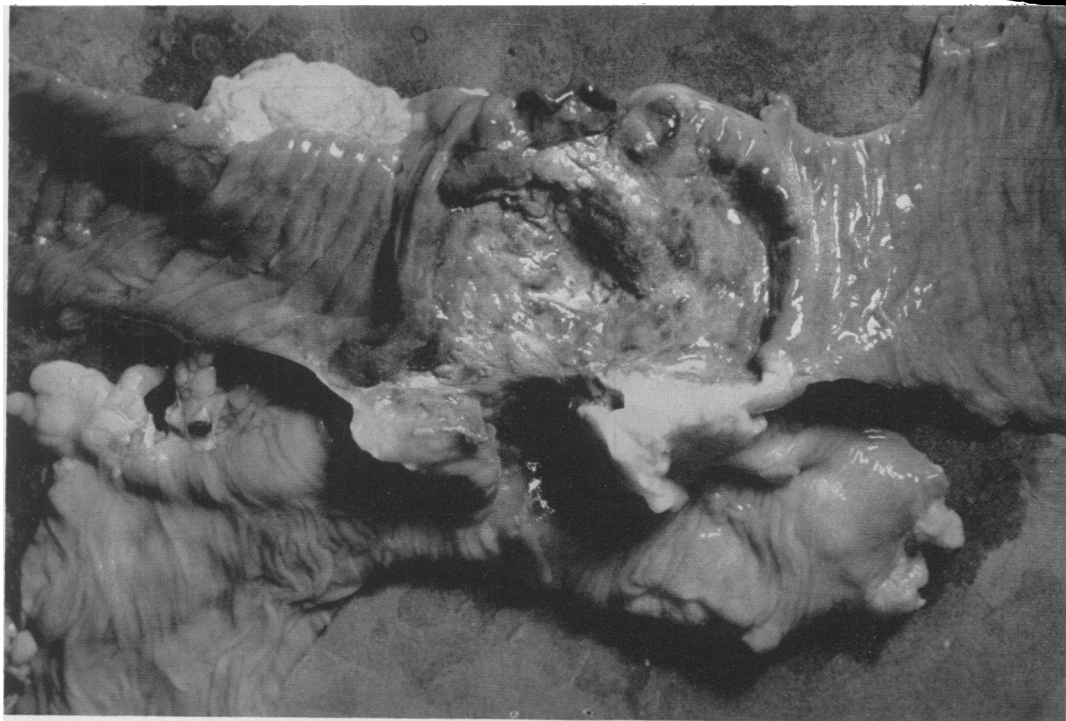

FIG. 1. Photograph, showing duodeno-colic fistula caused by erosion of lymphoma of reticulum-cell type. Uncontrollable diarrhea was presenting symptoms.

1. Lymphocytic or lymphoblastic lymphoma, in which the tumor may arise from lymphoid cells at any stage in their development, such as the large, pale, primitive lymphoblasts, or small, dark, mature lymphocytes, or from any intermediate stage in the lymphoid series between these two.

2. Reticulum-cell sarcoma, where the malignant process arises from the reticulum cell, that component of the reticulo-endothelial system found in the network which forms the frame of all lymphoid tissue. In this type, large, pale-staining cells are predominant, with nuclei of bizarre configuration, most of which are round, kidney, or horseshoe shaped. The nuclei are two to three times the size of those seen in small, round-cell lymphosarcoma, and the cells are larger than immature lymphocytes.

3. Giant-follicular lymphoma, in which the formation of large follicles or germinal centers with pale, uniform cells is the arresting feature, and there is an increase in

the actual numbers as well as the size of the follicles. The fact that occasionally in a lymphocytic lymphoma one can find a few bizarre giant follicles suggests that this giant-follicular type may, in some instances, represent an intermediate stage. Giant follicular lymphoma was formerly regarded as a benign condition. Although now considered as almost invariably pre-malignant, long intervals may elapse before malignancy is manifested.

4. Hodgkin's disease (the eponymic terminology is still the one most commonly accepted) is, according to Willis,⁶¹ a tumor of primitive reticulum cells in which divergent differentiation of both lymphoid and fibro-reticular elements takes place. These two elements are found in varying proportions and varying degrees of differentiation. A prominent diagnostic feature consists of large, conspicuous, irregular or rounded cells measuring $20\ \mu$ to more than $100\ \mu$ in diameter, which contain single or multiple

nuclei numbering up to eight or more per cell, and showing many mitoses. In later stages abundant fibrous tissue develops, unlike the other variants where the collagenous response is usually minimal. Hodgkin's disease of the intestine is exceedingly rare.

As previously indicated, the majority of intestinal lymphomas consist of more than one of these histological types. It would seem superfluous to sub-classify intestinal lymphoma except that those tumors which are predominantly lymphocytic or giant follicular appear to carry a slightly more favorable prognosis than the lymphoblastic and reticulum-cell types with Hodgkin's disease falling into an intermediate position (Fig. 3 A-E).

Two of our 25 cases, like others described by Marcuse and Stout,²⁸ exhibited a striking gross feature, namely, the presence of prominent lymphoid collections in the bowel wall immediately adjacent to the tumor. Sections of those specimens farthest removed from the tumor revealed enlarged but otherwise benign-looking follicles; but, as the tumor was approached, the sections looked increasingly more bizarre until unmistakable malignancy was encountered.

Clinical features and diagnosis. The clinical diagnosis of intestinal lymphoma is made difficult by the failure of the disease to produce a typical syndrome. Certain signs and symptoms are more frequent than others, but at best are merely suggestive (Table II). Pain, almost invariably present, is by far the commonest chief complaint, and is usually mild to moderate in intensity, intermittent, localized over the site of the lesion, and usually non-radiating. Nausea and vomiting are prominent symptoms, and the latter occurs often with the onset of the colicky pain. Hematemesis almost never occurs. Complete intestinal obstruction is uncommon, and when it does occur it is due to intussusception, adhesions to an involved loop of bowel, or complete occlusion of the lumen by growth. The latter occurs rarely

due to the tendency, already noted, for the growth to spread laterally rather than circumferentially. However, the mesenteric lymph nodes, full of malignancy, can, by direct extension, relentlessly occlude the lumen of the bowel. Anorexia, malaise, weakness, and easy fatiguability were present in well over 90 per cent of cases seen and reviewed, but were seldom severe enough to provoke the patient into seeking medical advice. The presence of bright red, brick red, or tarry blood in the stools occurred in less than 20 per cent of these patients, but in our series 50 per cent had occult fecal blood. Earlier authors stressed the importance of anemia in the diagnosis of small intestinal lymphomas. None of our cases, save one to be discussed later, exhibited this, and later authors confirm that anemia is rare. The history of altered bowel habits was elicited from half of our patients, with the most frequent complaints being those of alternating constipation and diarrhea. According to Ullman and Abeshouse,⁴⁸ this is due to an accumulation and stagnation in the dilated and paralyzed pouches which are incapable of peristalsis until the contents of the dilated portion cause contraction of the bowel wall above it, ejecting the contents so that there results a fetid diarrhea. Intussusception occurred in five of our cases, or 20 per cent. Speese⁴² reports an incidence of 18.5 per cent, and six of Liu's²⁵ 12 cases presented as intussusceptions. In Gross's¹⁶ series of 702 cases of intussusception in infants and children, 11 had a demonstrable cause other than a Meckel's diverticulum. Of these, two, or 18 per cent, were due to lymphoma.

Perforation into the peritoneal cavity is said to occur in from 1 to 2 per cent of cases, although this was noted in 20 per cent of our cases. A perforation of a duodenal lesion was the immediate cause of death of one patient. On one occasion extension into the urinary bladder necessitated cystectomy. Another case exhibited invasion of

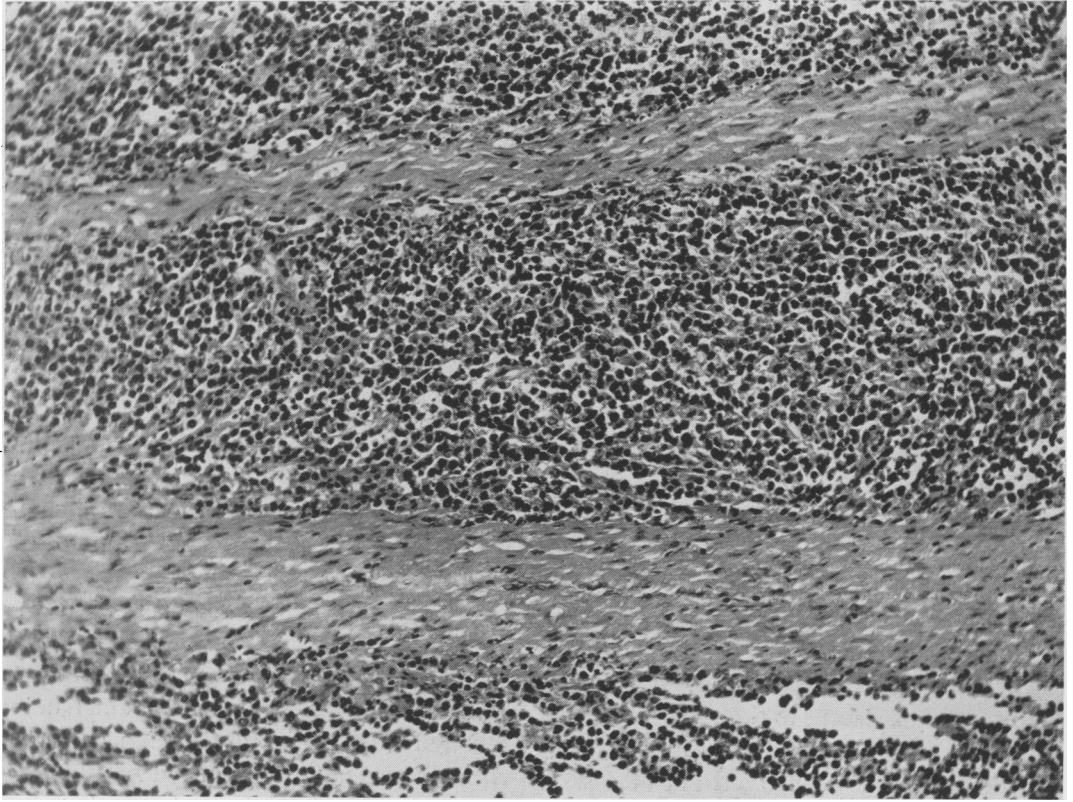


FIG. 2. Photomicrograph demonstrating characteristic lateralward spread of small-cell type tumor between muscle planes of the bowel. For this reason lymphomas seldom grow to encircle the bowel lumen. Hematoxylin and eosin x190.

the descending colon from a mass in the ileum. In still another, the posterior abdominal parietes had served to wall off a cecal erosion. At operation, one patient was found to have a fistula between jejunum and transverse colon which had resulted in severe diarrhea (Table III).

The radiologist, by means of the barium enema and the barium meal, should be able to lend considerable authority to the pre-operative diagnosis, although, as Swenson⁴⁵ points out, localized lymphoma can occur which cannot be distinguished radiographically from carcinoma. Lymphoma usually involves a longer segment of bowel and in-

filtrates the mesentery early, thus producing rather marked alterations in bowel pattern. Also, the lumen is often wider than normal, and the contours of the involved area are more smoothly rounded, almost corrugated in appearance.

Intestinal Lymphoma and Lymphocytosis. The vast majority of patients suffering from intestinal lymphoma exhibit no abnormality in the numbers or the configuration of the leukocytes in the differential smear. Ullman and Abeshouse,⁴⁸ in their review of the entire literature of intestinal lymphosarcoma up to 1932, state, "None of the cases was accompanied by a blood pic-

FIG. 3. Photomicrographs from specimens of small-bowel lymphomas depicting various cell types. (a) Case 4. Reticulum-cell type of terminal ileum. Hematoxylin and eosin x420. (b) Case 16. Large-cell lymphoblastic type of jejunum. Hematoxylin and eosin x420. (c) Case 9. Giant-follicular type of terminal ileum and cecum. Hematoxylin and eosin x460. (d) Case 20. Rather pleomorphic-type Hodgkin's with occasional Reed-Sternberg cells. Also seen are thin-walled sinusoids, strands of fibrous connective tissue, and some inflammatory cells. Hematoxylin and eosin x420. See page 356 for (E).

LYMPHOMAS OF THE SMALL INTESTINE AND CECUM

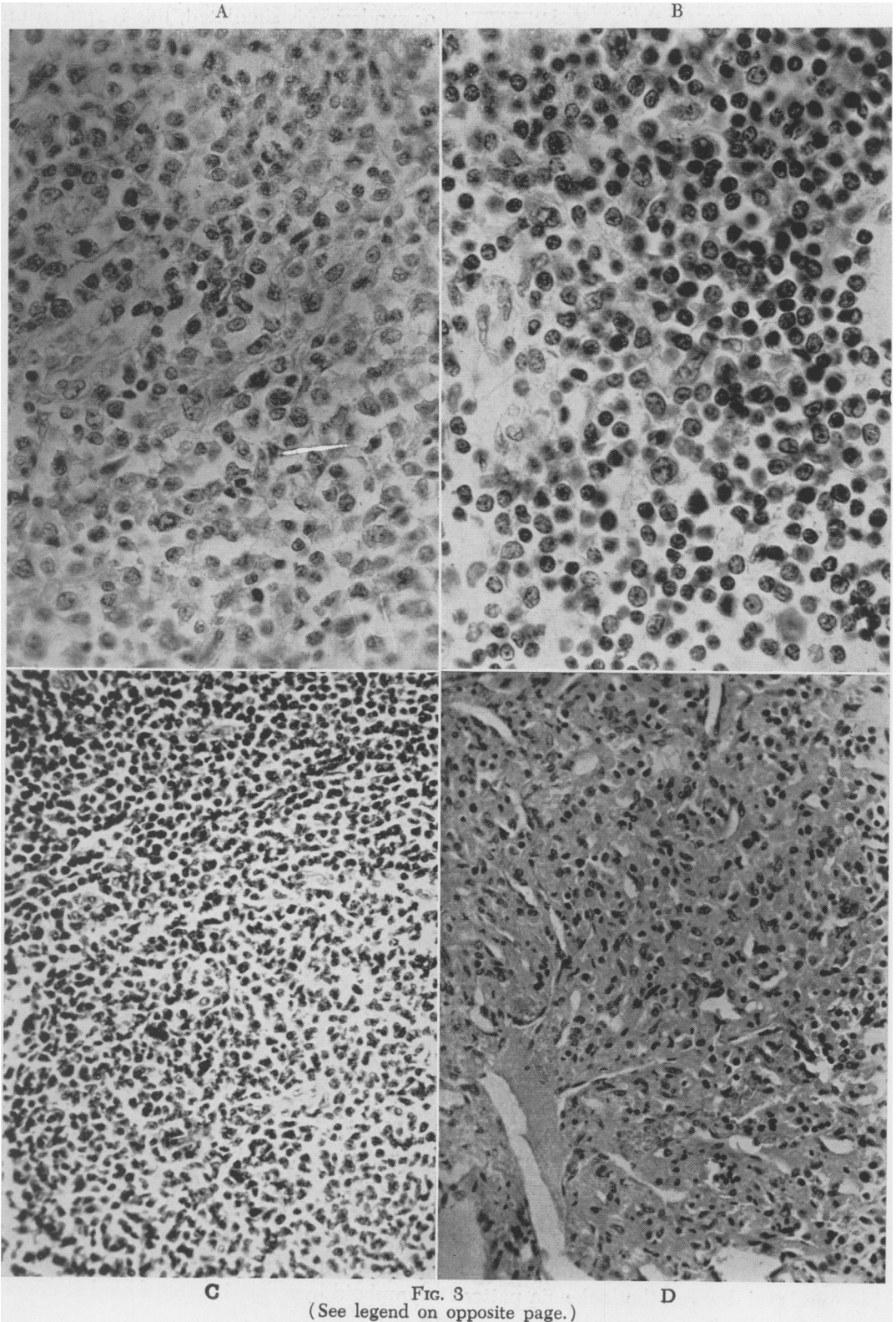


FIG. 3
(See legend on opposite page.)

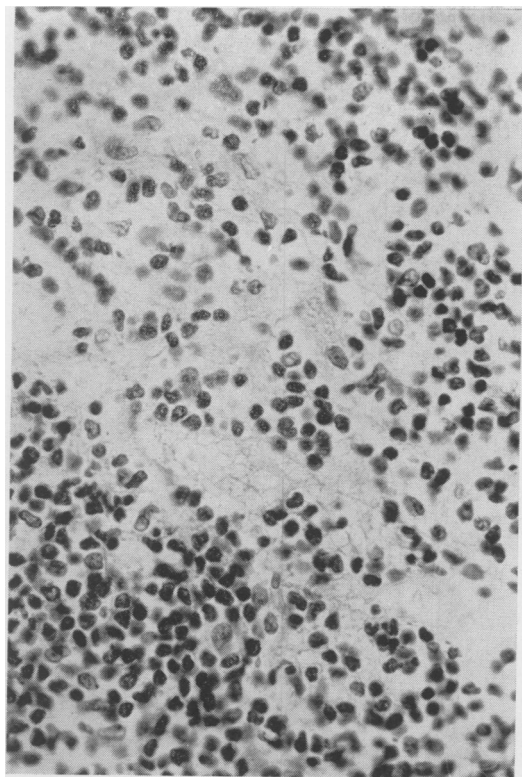


FIG. 3 (E). Case 12. Mixed (large and small cell) type of ileum. Hematoxylin and eosin $\times 420$.

ture associated with lymphatic leukemia." Marcuse and Stout,²⁸ reporting 13 of their own cases and on a series of 179 cases from the literature state, "The differential count showed no characteristic deviations, and no transitions into leukemia were found." However, in one of our cases it was noted that the red cell count was 3.1 million, the hemoglobin 9 Gm., the white cell count varied from 34,000 to 39,000 with 94 per cent immature lymphocytes. Both the liver and spleen were palpable. A bone marrow biopsy was considered typical of lymphatic leukemia. The pathologist, sectioning the ileo-cecal mass, later removed at autopsy, diagnosed a reticulum-cell sarcoma and postulated in retrospect a leukemoid reaction.

Intestinal Lymphoma and the Leukemoid Reaction. When, in the event of a presumably unrelated disease, the leukemia pattern

or syndrome is simulated, this is spoken of as the leukemoid reaction or state. Klee-man's²⁰ recent survey of the literature revealed only six examples of the co-existence of the lymphatic leukemoid state with specific benign or malignant neoplasms. These comprised carcinomas of the sigmoid colon, breast, stomach and lung, and pseudomucinous cyst and papillary adenoma of the ovary. Although in these cases as in the myeloid leukemoid state the bone marrow is usually involved with extensive metastatic deposits, the condition is known to develop in the absence of this occurrence. Unusual as is the myeloid leukemoid state, the lymphatic variant is rarer still. The mechanism by which a neoplasm is able to evoke a leukemoid reaction is obscure. Whitby and Britton,⁶⁰ Ward,⁵⁴ and Morrison³⁰ believe that the leukemoid state can often be differentiated from true leukemia by the presence in the former of nucleated red blood cells in the peripheral blood. Nucleated red cells were not found in the present case; furthermore, it is difficult to believe merely that an intestinal lymph tumor excited a non-specific lymphoid reaction in the peripheral blood, and that this does not, in fact, represent either metastasis or multi-focal origin. The presence of lymphocytosis with visceral lymphomas has been recorded by Boiken,³ Andersen,¹ and others. The co-existence of intestinal sarcomas with the leukemoid state is, as far as we can determine, unknown. Therefore, it is postulated that the two conditions are simultaneous manifestations of the same disease.

It is not within the scope of this paper to discuss whether sarcoma of lymphoid tissue is a multi-focal disease, or uni-focal with a tendency for metastasis to occur after a varying interval. Apparent cures of visceral and peripheral lymphoma have been reported following early and aggressive treatment; this would seem to favor the unifocal theory. On the other hand, the generalized lymphoid hyperplasia often found at opera-

tion for intestinal lymphoma tends to support the multi-focal concept. Whichever is the case, it seems clear that lymphoma of the intestines can occur in association with a true leukemic syndrome. To estimate the frequency of this phenomenon would entail bone marrow studies of every patient with this disease, for it is well recognized that evidence of leukemia may be present in the marrow and not in the peripheral blood in the early stages of this disease.

Prognosis. It was formerly believed that the prognosis of lymphoma of the small intestine and cecum was uniformly bad. There can be found in the more recent literature isolated reports of long-term survivals. Nonetheless, the expected survival for the majority of patients suffering from this disease remains discouragingly brief. Of our 25 cases, 13 died in less than a year following onset of the disease. Five patients remain free of clinical evidence of their disease at 16 years, eight years, seven and one-third years, six years, and four and one-sixth years. Two patients, treated eight months and six months ago, respectively, are still well. The disease in infants and children is particularly lethal, although Raiford,³³ Charache,⁷ and Marcuse and Stout each report one case of apparent cure in children. Usher and Dixon,⁴⁹ reviewing 50 cases of lymphosarcoma of the entire intestine, conclude that the site of the lesion influences the ultimate prognosis with lesions of the cecum entailing an average survival of eight years, and the small intestine nine months. Our small series does not support this conclusion.

TREATMENT

In cases where it is technically feasible to extirpate the entire lesion together with its lymphatic drainage, there is general agreement that this should be done. Where the growth is hopelessly extensive or the patient's condition precarious, a side-track-

ing palliative procedure should be provided. Because of the relatively small series of patients treated with a multiplicity of therapeutic technics, it is difficult to assess the value of irradiation. In the literature one can find examples of long-term survival treated by surgery alone; McSwain and Beal,²⁷ and Rowe and Neely³⁶ report cures effected by radiation alone. Nevertheless, if a definitive operation is performed in hope of a cure, irradiation should later be given in an attempt to eradicate tiny focal lesions which may have eluded the surgeon's detection.

When planning the treatment of this disease certain salient facts should be borne in mind.

1. The disease is not an indolent one, and the life expectancy of the untreated patient is very brief.

2. The prognosis of treated patients in the vast majority of cases is so bad that a five-year survival probably merits a case report in the literature.

3. One encounters repeatedly in reviewing case histories the surgeon's operative note in which he states that he has removed all visible and palpable tumor with the appropriate lymph-draining area only to find in the subsequent out-patient record the notation of a recurrent and inoperable abdominal mass.

Thus, it is obvious that a large number of these lesions, resected in hope of a cure, do, in fact, recur following the initial procedure. The authors have had no personal experience with the "second-look procedure" advocated by Wangenstein and his associates,^{52, 53} but the rationale of this procedure would seem particularly applicable to this disease where, following the initial operation, tumor is left behind in the peritoneal cavity. It is perhaps not unreasonable to believe that by applying the principle of multiple operations, some patients would be saved who would otherwise succumb to their malignancy.

SUMMARY

One-half to one-third of all small bowel tumors are lymphomas. The disease occurs in all age groups, predominantly in males. The etiology is unknown but the conceivable relationship to the infectious venereal lymphosarcoma of dogs, possibly a viral disease, is discussed.

Lymphosarcoma begins usually in the *lamina propria* of the bowel and spreads laterally rather than circumferentially. Superficial ulcerations often occur, and perforation is not uncommon. The disease occurs in four main histological variants: the small or the large cell type, the reticulum cell type, the giant follicular type and the Hodgkin's type, but a single specimen may exhibit more than one of these variants. There is no typical clinical pattern, but pain and a palpable abdominal mass are nearly always present. Partial intestinal obstruction is common, due not so much to actual occlusion or stenosis as to disturbance of bowel motility through invasion of the musculature and destruction of myenteric nerve plexuses. Intussusception occurs in about 20 per cent of cases. Anemia is rare. Neither leukocytosis nor abnormal cell forms are usually present in the blood stream. Intestinal lymphoma, as seen by the clinician, probably is a single disease occurring in several forms and found in different stages, namely, as single or multiple lesions and with or without lymphocytosis.

ACKNOWLEDGMENTS

The authors gratefully acknowledge the aid and encouragement of Dr. R. T. Tidrick and Dr. J. A. Buckwalter of the Department of Surgery, State University of Iowa; Mr. Maurice Ewing, Postgraduate Medical School of London, and Dr. Samuel Berger, Cleveland, Ohio.

BIBLIOGRAPHY

- 1 Anderson, W. A. D.: Textbook of Pathology. C. V. Mosby Co., St. Louis, 1948.
- 2 Boikan, W. S.: Leukemic Changes of the Gastro-intestinal Tract. Arch. Int. Med., 47: 42, 1931.
- 3 Boyd, W.: A textbook of Pathology. Fifth Edition. Lea and Febiger. Philadelphia, 1947.
- 4 Charache, H.: Primary Lymphosarcoma of the Intestine. Am. J. Surg., 27: 171, 1935.
- 5 De Monbreun, W. A., and E. W. Goodpasture: Am. J. Cancer, 21: 295, 1934.
- 6 Eraser, K.: Malignant Tumors of the Small Intestine. A Review of the Literature and Report of 21 Cases. Brit. J. Surg., 32: 479, 1945.
- 7 Gall, E. A., and T. B. Mallory: Malignant Lymphoma. Am. J. Path., 18: 381, 1942.
- 8 Gross, R. E.: The Surgery of Infancy and Childhood. W. B. Saunders, Co., Philadelphia and London, 1953.
- 9 Kleeman, C. R.: Lymphocytic Leukemoid Reaction associated with primary carcinoma of the breast. Am. J. Med., 10: 522, 1951.
- 10 Kundrat, H.: Ueber Lympho-Sarkomatosis, Wien. klin. Wchnschr., 6: 211, 1893.
- 11 Liu, J. H.: Tumors of the Small Intestine with Especial Reference to the Lymphoid Cell Tumors. Arch. Surg., 11: 602, 1925.
- 12 Lumb, G.: Tumors of the Lymphoid Tissue. E. & S. Livingstone, Ltd., Edinburgh and London, 1954.
- 13 McSwain, B., and J. M. Beal: Lymphosarcoma of the Gastro-intestinal Tract: Report of 20 Cases. Ann. Surg., 119: 108, 1944.
- 14 Marcuse, P. M., and A. P. Stout: Primary Lymphosarcoma of the Small Intestine. Analysis of 13 Cases and Review of the Literature. Cancer, 3: 459, 1950.
- 15 Morrison, M.: An analysis of the Blood Picture in One Hundred Cases of Malignancy. J. Lab. and Clin. Med., 17: 1071, 1932.
- 16 Raiford, A. S.: Tumors of the Small Intestine. Arch. Surg., 25: 122, 321, 1932.
- 17 Rowe, E. W., and J. M. Neely: Primary Malignancy of the Small Intestine. Radiology, 28: 325, 1937.
- 18 Speese, J.: Sarcoma of the Small Intestine. Ann. Surg., 59: 727, 1914.
- 19 Swenson, P. C.: X-Ray Diagnosis of the Primary Malignant Tumors of the Small Intestine. Rev. Gastroenterol., 10: 77, 1943.
- 20 Symmers, D.: Lymphoid Diseases. Arch. Path., 45: 73, 1948.
- 21 Ullman, A., and B. S. Abeshouse: Lymphosarcoma of the Small and Large Intestines. Ann. Surg., 95: 878, 1932.
- 22 Usher, F. C., and C. F. Dixon: Lymphosarcoma of the Intestines. Gastro-enterol., 1: 160, 1943.
- 23 Wangenstein, O. H., F. J. Lewis, S. W. Arhelger, J. J. Muller and L. D. MacLean: An Interim Report upon the "Second Look" Procedure for Cancer of the Stomach, Colon, and Rectum, and for "Limited Intra-peritoneal Carcinosis." Surg. Gynec. and Obstet. In press.

LYMPHOMAS OF THE SMALL INTESTINE AND CECUM

- ²⁴ Wangensteen, O. H., F. J. Lewis and L. A. Tongen: The Second Look in Cancer Surgery. *J. Lancet.*, 71: 303, 1951.
- ²⁵ Ward, R. G.: Secondary or Symptomatic Leukemia. *Proc. Royal Soc. Med.*, 7: 126, 1913, 1914.
- ²⁶ Warthin, A. S.: The Genetic Neoplastic Relationship of Hodgkin's Disease, Aleukemic and Leukemic Lymphoblastoma, and Mycosis Fungoides. *Ann. Surg.*, 93: 153, 1931.
- ²⁷ Whitby, L. E. H., and C. J. Britton: Disorders of the Blood, Fourth Edition, Blakiston Co. Philadelphia, 1942.
- ²⁸ Willis, R. A.: Pathology of Tumors, Second Edition, Butterworth, London, 1953.